

Clinical investigation of expansive retroperitoneal lesion suggestive of Frantz's tumor: case report and review of literature

Investigação clínica de lesão expansiva retroperitoneal sugestiva de Tumor de Frantz: relato de caso e revisão de literatura

Thaís Oliveira Dupin¹, Alan de Castro Nunes¹, André Luís de Oliveira Silveira¹,
Paula Fontes Lelis¹, Cirênio de Almeida Barbosa², Weber Chaves Moreira³

Dupin TO, Nunes AC, Silveira ALO, Lelis PF, Barbosa CA, Moreira WC. Clinical investigation of expansive retroperitoneal lesion suggestive of Frantz's tumor: case report and review of literature / *Investigação clínica de lesão expansiva retroperitoneal sugestiva de tumor de Frantz: relato de caso e revisão de literatura*. Rev Med (São Paulo). 2021 Sept-Oct;100(5):508-13.

ABSTRACT: Introduction: Pancreatic neoplasms represents 2% of tumors diagnosed in Brazil and are responsible for 4% of deaths due to neoplasms. About 10 to 15% of cases are cystic pancreatic neoplasms. *Objective:* To present a case of expansive retroperitoneal lesion suggestive of Frantz's Tumor which anatomopathology report showed Mucinous Cystadenocarcinoma. *Case report:* Female, 30 years old, complaining of representative weight loss and obstructive gastrointestinal symptoms manifested progressively within 6 months. There were no comorbidities. Laboratory tests showed nothing abnormal. The computed tomography showed a complex retroperitoneal cystic expansive lesion in mesogastrium and left hypochondrium, with intimal relationship with body/tail of pancreas. She was submitted to tumor resection and Distal Pancreatectomy. The patient had good postoperative evolution with improvement in gastrointestinal symptoms. Anatomopathological analysis evidenced histology compatible with pancreatic mucinous cystic neoplasm, with mild and moderate epithelial dysplasia and areas of mucinous cystadenocarcinoma, moderately differentiated, with high-grade pleomorphic components. *Discussion:* The most common subtype of cystic pancreatic neoplasms is the Mucinous Cystadenocarcinoma, which can either be malignant at the moment of diagnosis or benign, with the possibility of malignization. There are other types as Serous Cystadenoma, Mucinous Cystadenoma, Intraductal Papillary Mucinous Neoplasm and Frantz Tumor. This last type presents with slowly growing and unspecific clinical manifestations, being diagnosed frequently when it has bigger dimensions. *Conclusion:* It was a case of Invasive Mucinous Cystadenocarcinoma with atypical presentation, similar to Frantz tumor. The diagnosis was possible due to the anatomopathological study, that showed to be a fundamental instrument for the differential diagnosis.

Keywords: Mucinous cystadenocarcinoma; Pancreatic neoplasms, Retroperitoneal space.

RESUMO: *Introdução:* As neoplasias pancreáticas representam 2% dos cânceres diagnosticados no Brasil e são responsáveis por 4% das mortes por neoplasia. Cerca de 10% a 15% dos casos são representados por neoplasias pancreáticas císticas. *Objetivo:* É apresentado um caso de lesão expansiva retroperitoneal sugestiva de tumor de Frantz cujo laudo anatomopatológico mostrou cistadenocarcinoma mucinoso. *Relato de caso:* Mulher, 30 anos, com queixa de perda de peso importante e sintomas obstructivos do trato gastrointestinal com evolução progressiva em 6 meses. Não apresentava nenhuma comorbidade. Exames laboratoriais sem alterações. A tomografia computadorizada evidenciou lesão expansiva cística complexa retroperitoneal no mesogástrio/hipocôndrio esquerdo, em íntima relação com o corpo/cauda do pâncreas. Foi submetida à ressecção do tumor com pancreatectomia distal. Paciente apresentou boa evolução pós-operatória, com melhora dos sintomas gastrointestinais. A análise anatomopatológica evidenciou histologia compatível com neoplasia cística mucinosa pancreática, com displasia epitelial leve a acentuada e áreas de cistadenocarcinoma mucinoso, moderadamente diferenciado, de alto grau. *Discussão:* Das neoplasias pancreáticas císticas, o subtipo mais comum é o cistoadenocarcinoma mucinoso, que pode ser maligno ou benigno na avaliação diagnóstica e, às vezes, sugerir possibilidade de malignização. Existem outros tipos como o cistoadenoma seroso, cistoadenoma mucinoso, neoplasia intraductal mucinosa papilífera e o tumor de Frantz. Esse último apresenta crescimento lento e manifestações clínicas inespecíficas, sendo diagnosticado frequentemente quando possui grandes dimensões. *Conclusão:* Tratava-se de um caso de cistadenocarcinoma mucinoso invasor de pâncreas com apresentação atípica, semelhante ao Tumor de Frantz. O diagnóstico tornou-se possível através do estudo anatomopatológico, mostrando-se fundamental para o diagnóstico diferencial.

Descritores: Cistadenocarcinoma mucinoso; Neoplasias pancreáticas; Espaço retroperitoneal.

1. Acadêmicos do curso de medicina da Universidade Federal de São João del Rei campus Centro Oeste – UFSJ CCO. ORCID: Dupin TO - <https://orcid.org/0000-0001-7716-7675>; Nunes AC - <https://orcid.org/0000-0003-2977-3202>, Silveira ALO - <https://orcid.org/0000-0001-8843-1283>, Lelis PF - <https://orcid.org/0000-0002-3193-6739>. E-mail: thaisodupin@gmail.com, alan_castro97@hotmail.com, andre-luis-oliveira@hotmail.com, paulafontesm@gmail.com.

2. Professor adjunto da Escola de Medicina da Universidade Federal de Ouro Preto/MG. <https://orcid.org/0000-0001-6204-5931> Email: cireniobarbosa@gmail.com.

3. Titular do Colégio Brasileiro de Cirurgiões – TCBC. <https://orcid.org/0000-0001-9837-354X>. Email: wcmarthur@gmail.com

Correspondence: Thaís Oliveira Dupin. Rua Vereador Ildeu Alves Ferreira, 185, Dona Tunica, Pará de Minas – MG. CEP: 35661-016. Email: thaisodupin@gmail.com

INTRODUCTION

Cystic lesions of the pancreas comprise a wide spectrum of diseases with varied clinical features and prognosis. Pancreatic neoplasms represent 2% of tumors in general in Brazil, while cystic neoplasms represent 10% to 15% of cases being primarily of cystic origin or resulting from cystic degeneration of a solid tumor¹.

Mucinous cystadenocarcinoma is the most common of these neoplasms and typically occurs in middle-aged women and is usually located in the pancreatic body or tail. Many of these mucinous tumors have malignant features on imaging diagnosis and even those that have a benign appearance sometimes have a high potential for malignancy. The standard treatment consists of surgical resection since the effectiveness of adjuvant treatments is not well defined in the literature^{1,2}.

Pancreatic cystic lesions may be found during the evaluation of patients with abdominal pain and pancreatitis, however there has been an increase in incidental findings during abdomen imaging exams. These lesions can be categorized into pseudocysts, non-neoplastic cysts and neoplastic cysts. Among the cystic neoplasms of the pancreas we can highlight the serous cystadenoma, mucinous cystadenoma, cystadenocarcinoma, mucinous papillary intraductal neoplasm (IPMN) and pseudopapillary solid tumor. The latter, also known as Frantz tumor, is a rare exocrine pancreas tumor with a low degree of malignancy. According to the World Health Organization, it is an epithelial malignant neoplasm with gross pseudopapillary appearance and cystic microscopic appearance^{3,4,5}.

Frantz's tumor represents approximately 1% to 2.5% of all exocrine pancreatic neoplasms and more than 90% of diagnosed patients are young women between the ages of 18 and 35, with an average age of 24. Most are large tumors that are confined to the pancreas, located in the head (26% -34%) or in the body and tail (66% -74%). A significant proportion of carriers may be asymptomatic or present nonspecific symptoms until the tumor becomes voluminous, at which time there is discomfort in the upper abdomen, anorexia, postprandial fullness, weight loss, and a palpable mass upon physical examination. The risk of metastasis to the liver and peritoneum is low (10% -15%) and long-term survival has been observed after surgical resection with excellent prognosis and a high 5-year survival rate^{4,5}.

The aim of this study is to describe the clinical investigation procedure of a suspected case of Frantz's

tumor based on current bibliographic research. Through this approach, it will be possible to establish a comparison between this type of tumor and other correlated ones (belonging to the group of pancreatic cystic neoplasms), bringing together the scarce theoretical publication on this topic in order to provide objective clinical information for other professionals who might come across these nosological entities in their daily practice.

CASE REPORT

A 30-year-old female patient arrives at the Emergency Room of a large Hospital in Belo Horizonte in July of 2019, complaining of significant weight loss and obstructive symptoms of the gastrointestinal tract - nausea, vomiting and gastroesophageal reflux after intake of excessive solid and liquid foods. The clinical features showed a progressive evolution during the last 6 months, rapidly worsening in the two months prior to the initial consultation. The patient reported a weight loss of 20 kg in 6 months. She denied other correlated symptoms. She took Omeprazole 40mg twice a day and Pantoprazole 40mg once a day thereafter, with no improvement in symptoms. Upon physical examination, the patient was emaciated, with no other changes. She denied clinical admissions and previous surgeries. She had no comorbidity. She was using monthly injectable contraceptives. She reported casual use of alcohol.

A computed tomography exam of the abdomen showed the presence of an expansive retroperitoneal complex cystic lesion in the left mesogastrium/hypochondrium, in close relationship with the body/tail of the pancreas, measuring approximately 13.9 x 11.9 x 10.3 cm. Thick septa were reported, some calcified, in addition to presenting a macrocystic aspect, with heterogeneous content, at times spontaneously dense. By means of an intravenous contrast, it was possible to verify a solid component intermingled, with enhancement after ingestion of the intravenous contrast agent. The other pancreatic segments showed a preserved appearance with homogeneous contrast-enhancement and no ductal dilations or gross calcifications. The radiological report described the possibility that it was a cystic neoplastic lesion of the pancreas. These findings can be seen on the computed tomography (CT) in a coronal section (Figure 1) and in an axial section (Figure 2).

Laboratory tests, performed in July of 2019, were not relevant for the diagnosis of the condition in question, but ruled out the presence of comorbidities (Chart 1).

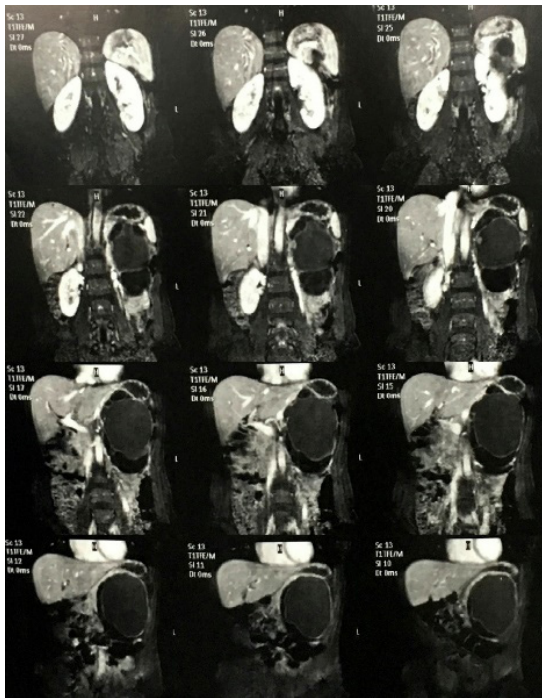


Figure 1 - Coronal computed tomography sections of the abdomen suggestive of a cystic neoplastic lesion in close relationship with the body/tail of the pancreas, measuring approximately 13.9 x 11.9 x 10.3 cm (author's personal file, 2019).

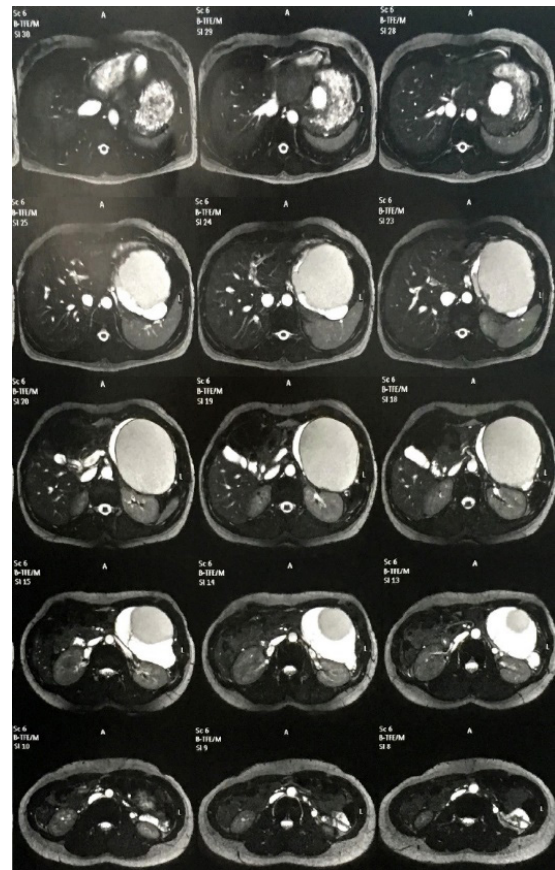


Figure 2 - Axial computed tomography sections of the abdomen suggestive of a cystic neoplastic lesion in close relationship with the body/tail of the pancreas, measuring approximately 13.9 x 11.9 x 10.3 cm (author's personal file, 2019).

Chart 1 - Laboratory tests had no diagnostic relevance (chart prepared by the authors).

Exam Result	Exam Result	Exam Result
Reference Value	Reference Value	Reference Value
Serum amylase	54 U/L	22 a 80
Lipase	22	≤ 68
Blood glucose	94 mg/dL	60 a 99
Red cell	4,04 mm ³	4,1 a 5,2
Hemoglobin	12,6 g/dL	12 a 16
Hematocrit	37,70 %	36 a 46
Global leukocytes	8500 mm ³	5000 a 10000
Platelets	189000 mm ³	150000 a 350000
Serum potassium	3,9 mEq/L	3,5 a 5,1
Serum Sodium	135 mEq/L	135 a 145
Serum creatinine	0,57 mg/dL	0,60 a 1,20
Serum Urea	13,6 mg/dL	17 a 43
CA-125	14,1 U/mL	≤ 35
CA19-9	10 U/mL	2 a 37

In August of 2019, the patient underwent resection of a retroperitoneal tumor in association with a partial pancreatectomy. A median supraumbilical and midline laparotomy was performed (Figure 3). The tumor was removed in its entirety and sent for pathological analysis (Figure 4).

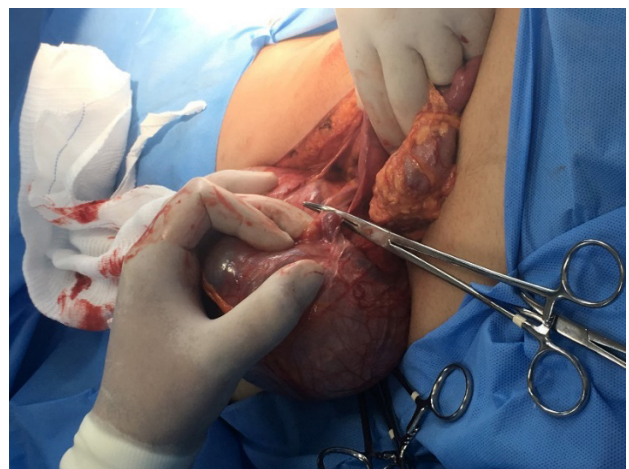


Figure 3 – Resection of a capsulated rounded tumor measuring 13.9 x 11.9 x 10.3 cm (author's personal file, 2019).

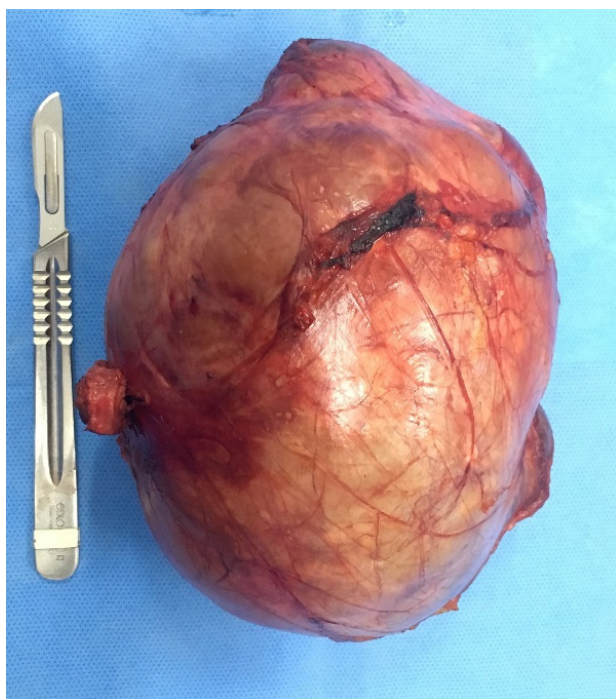


Figure 4 - Surgical specimen: Capsulated rounded tumor measuring 13.9 x 11.9 x 10.3 cm (author's personal file, 2019).

The patient had a good postoperative recovery, with total improvement of the gastrointestinal tract symptoms. The pathology report of the macroscopic analysis reported a solid-cystic nodular formation with a smooth external surface, 14.0 x 10.0 x 7.0 cm and weighing 971g. The cuts showed several cystic cavities, in some cases filled with a gelatinous content, while in others with a translucent liquid content. The internal surface was smooth, with small sparse vegetation and a solid nodular area that infiltrated the wall, measuring 2.0 cm. The presence of a multiloculated cystic neoplasm was also described as having a wall consisting of fibrous tissue covered by mucinous columnar cells with areas of erosion and chronic inflammatory infiltrate with atypia ranging from mild to severe. There were also papillary projections covered by atypical cells associated with areas of wall invasion. The histopathological sections of the tumor showed areas of neoplastic invasion of the wall with the formation of glandular structures associated with high-grade fusocellular and pleomorphic areas with foci of necrosis. The neoplasm did not go beyond the capsule. The presence of the pancreas tail was also described as measuring 3.7 x 2.0 x 0.5 cm. Under microscopy, this fragment of the organ presented ectatic and congested vessels, mild edema and areas of fibrosis.

In conclusion, the histology was compatible with pancreatic mucinous cystic neoplasia with mild to severe epithelial dysplasia and areas of invasive mucinous adenocarcinoma (mucinous cystadenocarcinoma),

moderately differentiated, with a high-grade fusocellular and pleomorphic (sarcomatoid) component. The resection margins were free of disease.

DISCUSSION

Pancreatic neoplasms of epithelial origin, such as ductal adenocarcinoma and its variants, are the most frequent, corresponding to 80% - 90% of the types of tumors in the organ. On the other hand, cystic neoplasms represent only 10% to 15% of cases and may present variable behavior ranging from benign, malignant or borderline forms¹.

Mucinous cystadenoma is the most common pancreatic cystic neoplasm, accounting for about 40% of all cystic neoplasms in this organ. It presents cellular atypia and secretes mucin, which can be benign (mucinous cystadenoma) or malignant (mucinous cystadenocarcinoma). Several series report that 10% to 50% of mucinous pancreatic tumors are malignant⁶.

On the other hand, Frantz's Tumor presents itself as a solid and cystic component and, therefore, it is also called solid-cystic or solid-papillary. It is essentially rare and accounts for less than 1% - 5% of all cystic neoplasms. Neoplastic cells have progesterone receptors and the beta form of estrogen receptors, a fact that indicates the possible influence of these hormones in the development of these tumors⁶.

Clinical manifestations

The symptoms most commonly attributed to Frantz's tumor are abdominal pain, followed by nausea, vomiting and weight loss. Other less common symptoms include gastrointestinal obstruction, anemia, jaundice and pancreatitis. The finding of a palpable mass is more common in pediatric patients⁶.

Symptoms of dyspepsia, nausea, vomiting and weight loss were progressively identified in the patient, suggesting a typical malignant characteristic. There were no obstructive symptoms of the biliary tract at the stage at which the diagnosis was made, nor other findings upon physical examination except for anthropometric alterations conveyed through weight loss.

Epidemiology

Unlike other cystic neoplasms, Frantz's tumor presents itself much earlier and usually occurs in female patients under 35 years of age. Its main differential diagnosis, mucinous cystadenocarcinoma, has an average age of above 40 and shares Frantz's tumor's predilection for females⁶.

The case in study portrays a patient with atypical

epidemiology for mucinous cystic tumors as she was only 30 years old at the time of diagnosis, especially as it was not an accidental finding and presented well-defined dyspeptic and metabolic symptoms. In this context, the clinical suspicion of Frantz's tumor was reinforced, given the early signs of the tumor, a fact normally presented by this type of tumor. However, the fact that the patient was female corroborates the suspicion of either type of tumor.

Laboratory Tests

For the clinical investigation of Frantz Tumor, laboratory tests are of little significance. It is also noteworthy that tumor markers are of little diagnostic aid, as they are rarely altered (occasionally there are minimal elevations in CA19-9), in addition to the absence of alterations in pancreatic or canalicular enzymes^{7,8}.

This statement is reinforced in the casuistry under description, as most of the laboratory parameters presented in the previous section were within the reference values, including the biomarkers CA-125 (14.1U/mL) and CA19-9 (10U/mL) mL), which were within normal limits.

Imaging Exams

Abdominal US or CT have an important role in the diagnostic process. These exams usually show a well delimited mass in the topography of the pancreas containing regular contours and a thick heterogeneous mixed-pattern solid-cystic capsule, sometimes with calcifications or internal septations⁸.

The findings seen on the patient's CT reflect all these characteristics and confirmed the existence of a retroperitoneal mass in the pancreatic topography in close relation to the body/tail of this organ. It is known that there is a predominance of cases of Frantz's tumor in the body-tail region (64% of cases)^{8,9}.

Gross septations in the lesion were also evidenced, some of them calcified, findings that may be present in this subtype of cystic tumor. Finally, the main element that helped confirm the diagnosis of Frantz tumor on the CT was the finding of a heterogeneous aspect, showing simultaneously a cystic content with solid areas in between, a "sine qua non" condition for the definition of a Frantz Tumor, which is fundamentally a solid-cystic neoplasm⁶.

Anatomic Pathology exam

In relation to the macroscopic characteristics, it is known that due to its slow growth and few clinical manifestations, this tumor is frequently diagnosed when it presents large dimensions, generally larger than 10 centimeters⁶. The tumor obtained was within these dimensions, measuring 14 x 10 x 7cm and weighing 971g.

The presence of a solid-cystic nodular macroscopic aspect with an internal surface containing cystic cavities of variable content and sparse vegetation containing a solid nodular area in between was also conclusive with findings compatible with a typical Frantz tumor⁶.

Upon microscopic examination, a lesion with a low mitotic index was typically expected, containing small cells grouped in solid pseudopapillary areas with cystic degeneration, as these are the characteristics of a typical Frantz tumor⁸. It was also expected that these cystic cavities would not consist of true cysts by definition, that is, not having epithelial lining. In this type of tumor, the cystic cavities are due to a necrotic and degenerative process and contain blood, necrotic debris, macrophages and pseudopapillary tumor⁶.

However, the formation of true cysts covered by an epithelium with a columnar and mucinous lining, containing cells with mild to marked atypia, some of them forming papillary projections, but not enough to match the typical architecture of a traditional Frantz Tumor, were observed.

It is also known that, in Frantz's tumor, neoplastic cells have progesterone receptors and the beta form of estrogen receptors⁶. Despite the usefulness of investigating these characteristics, the immunohistochemical study aimed at recognizing these receptors in the cells of the sample was not carried out, a fact that could complement the confirmation of the anatomopathological diagnosis found, and rule out the hypothesis of a Frantz tumor with greater certainty.

Finally, it was possible to confirm the diagnosis of invasive mucinous adenocarcinoma, the most common subtype of malignant cystic neoplasms, albeit presenting itself in a totally atypical way to the usual patterns, closer to the characteristics associated in the medical literature with the Frantz Tumor.

CONCLUSION

The case detailed the investigation of an invasive mucinous adenocarcinoma of the pancreas with totally atypical manifestations. The diagnosis became possible after the anatomopathological study. Thus, anatomical pathology is a fundamental tool in this context, as some studies on this topic suggest that the diagnosis is the fusion of clinical history and imaging exams. This finding reinforces the impression of other authors that the diagnosis and management of cystic lesions of the pancreas remains a clinical challenge.

That said, it is believed that this material can contribute to the study of the topic and also serve as a stimulus for the pursuit of knowledge of other similar cases in the routines of national medical clinics.

REFERENCES

1. Meyer MECS, Dalagnol RC, Brusa MGS, Shiozawa MBC, Paulo GG, Paulo MC. Cistoadenocarcinoma de pâncreas: relato de caso e revisão de literatura. *ACM Arq Catarin Med.* 2010;39(2):79-82. <http://www.acm.org.br/revista/pdf/artigos/806.pdf>
2. Falqueto A, Pelandré GL, Costa MZG, Nacif MS, Marchiori E. Prevalência de lesões císticas pancreáticas em exames de imagem e associação com sinais de risco de malignidade. *Radiol Bras.* 2018;51(4):218-24. doi: <http://dx.doi.org/10.1590/0100-3984.2017.0105>
3. Artifon ELA, Buch M, Bonini L, DPS Aparicio. Lesões Císticas do Pâncreas. *GED Gastroenterol Endosc Dig.* 2013;32(4):111-9. Disponível em: <http://files.bvs.br/upload/S/0101-7772/2013/v32n4/a5007.pdf>
4. Bolaños FB, Bejarano HL, Briceño LR, Alva BS, Flores ES, Rojas LT, et al. Tumor sólido pseudopapilar de pâncreas: tumor de Frantz. *Horiz Med.* 2018;18(2):80-5. doi: <http://dx.doi.org/10.24265/horizmed.2018.v18n2.12>
5. Torres OJM, Rezende MB, Waechter FL, Neiva RF, Moraes-Junior JMA, Torres CCS, et al. Duodenopancreatectomia para o tumor pseudopapilar sólido do pâncreas: estudo multi-institucional. *ABCD Arq Bras Cir Dig.* 2019;32(2):e1442. doi: [/10.1590/0102-672020190001e1442](https://doi.org/10.1590/0102-672020190001e1442).
6. Filho HFM, Goes ACAM. Lesões císticas do pâncreas: uma revisão de literatura. *Rev Med UFC.* 2017;57(3):41-6. doi: [10.20513/2447-6595.2017v57n3p41-46](https://doi.org/10.20513/2447-6595.2017v57n3p41-46).
7. Jakhlal N, Njoui N, Hachi H, Bougtab A. Tumeur pseudopapillaire et solide du pancréas: à propos d'un cas et revue de la littérature. *Pan Afr Med J.* 2016;24:104. doi: [10.11604/pamj.2016.24.104.8301](https://doi.org/10.11604/pamj.2016.24.104.8301).
8. Partezani AD, Mattar GG, Zatz RF, Ijichi TR, Moricz A, Campos T, et al. Tumor de Frantz: um caso raro com características não habituais. *Arq Med Hosp Fac Cienc Med Santa Casa São Paulo.* 2013;58:46-9. Disponível em: <https://arquivosmedicos.fcmsantacasasp.edu.br/index.php/AMSCSP/article/view/221>
9. Nachulewicz P, Rogowski B, Obel M, Woźniak J. Central pancreatectomy as a good solution in Frantz Tumor resection: a case report. *Medicine (Baltimore).* 2015;94(29):e1165. doi: [10.1097/MD.0000000000001165](https://doi.org/10.1097/MD.0000000000001165).

Submitted: 2020, May 08

Aceito: 2021, September 06