

PAIN ABDOMEN AS A PRESENTATION OF CONGENITAL MALROTATION OF GUT: A CASE SERIES

Syed Sajid Hussain Shah¹, Yousaf Aziz Khan², Bibi Aalia³

ABSTRACT:

Malrotation of the gut can present at any age but the majority of patients present in neonatal period or early infancy. Most children present with a history of recurrent colicky abdominal pain, vomiting which can be bilious and failure to thrive. Delay in diagnosis leads to increase in mortality and morbidity. Here we present a series of three patients, one girl aged 6 years, one 10 months old boy and one 10 years old boy, who got admitted at our Pediatric Department in a one month period. Patients had a history of recurrent abdominal pain and occasional vomiting, seen and managed by multiple paediatricians and GP doctors with extensive diagnostic workup but never the accurate diagnosis was made. Thorough history was taken and examination done, planned work up done for diagnosis. High index of suspicion is needed in children presenting with recurrent pain in the abdomen. Targeted work-up should be done and patients be kept on follow-up for diagnosis of late presentation of congenital malrotation of the gut.

KEYWORDS: Recurrent Pain Abdomen, Failure To Thrive, Intestinal Malrotation, Vomiting

How to cite this article:

Hussain SS, Khan YA, Aalia B. Pain Abdomen As a Presentation Of Congenital Malrotation of Gut: A Case Series. J Gandhara Med Dent Sci. 2021;8(4): 65-68

Correspondence:

¹Syed Sajid Hussain Shah, Assistant Professor, Pediatric Nephrology, Institute of Kidney Diseases, Peshawar.

Contact: +92-334-8951184

Email: syed_sajid20@yahoo.com

²Assistant Prof. Pediatric Surgery, Ayub Medical College, Abbottabad.

³Assistant Prof. Pediatrics, Lady Reading Hospital, Peshawar

INTRODUCTION:

During gestation around the fourth week of embryological period, intestinal tract development begins with differentiation of the primitive intestinal tract into foregut, midgut and hindgut. Intestinal loops herniate into the extra-embryonic coelom, due to disproportionate growth and elongation of the midgut. Bowel undergoes 270° counterclockwise rotation along the superior mesenteric artery axis while returning back to the abdominal cavity. Failure to completely rotate along the SMA axis and not becoming fixed in proper position leads to malrotation of the gut. The incidence of symptomatic malrotation of the gut is 1 per 6000 live births.

Patients with malrotation of the gut are at risk for midgut volvulus^{1,2}. Though most cases of malrotation present in neonatal period and infancy yet mostly associated with volvulus of the midgut. It has disastrous consequences if the diagnosis is delayed. In older children, presentation can be with various symptoms including vague abdominal complaints leading to delay in the diagnosis and treatment. The presenting symptoms are usually due to intermittent volvulus, which include bilious vomiting, chronic intermittent abdominal pain, failure to thrive and chronic intestinal blood loss³⁻⁵. We are presenting a series of three patients, a 10 months old boy, a 6 years old girl and a 10 years old boy admitted at the Paediatric B unit, Ayub Teaching Hospital, Abbottabad, within a span of one month, who had a final diagnosis of congenital midgut malrotation. Consent was taken from the parents to include these patients in the case series. The aim of presenting these cases is to increase the awareness and knowledge regarding the timely diagnosis and management of this condition to prevent associated morbidity and mortality.

CASE PRESENTATION - 1:

A 10 months old baby boy presented to the Pediatric Out-Patient clinic with a history of persistent vomiting for six days. Patient remained admitted at one of the DHQ Hospital for 3 days and was discharged home with a final diagnosis of AGE. The mother was not satisfied as the baby was still irritable and vomiting with occasional light greenish in colour. Patient was admitted and a detailed history was taken. Clinical examination showed moderate dehydration with sluggish bowel sounds without any significant abdominal distension. An X-ray abdomen erect showed multiple air-fluid levels. After rehydration workup for congenital malrotation of gut was done which included ultrasound abdomen, computed tomography with oral and intravenous contrast and, barium follow-through, suggestive of malrotation of gut. Paediatric surgeon was taken on board. Intraoperative findings were of classical malrotation involving midgut with a free mobile caecum, congenital Ladd's bands and a narrow base mesentery. Standard Ladd's procedure was done with appendectomy. Post-operative course was uneventful.

CASE PRESENTATION - 2:

A 6-year-old girl with a history of vomiting and pain abdomen on/off for the last three years presented to a private clinic. The patient had visited multiple doctors and at tertiary care hospitals of Rawalpindi and Islamabad for the symptoms but to no avail as every time she was offered symptomatic treatment and sent home. After taking a detailed history, examination showed dehydrated and a malnourished child with a scaphoid abdomen. Patient was admitted to hospital. An initial X-ray erect abdomen showed few air-fluid levels mainly occupying the upper abdomen. A paediatric surgery consultation was sought. After rehydration, workup for congenital malrotation of the gut was done which included ultrasound abdomen, CT with oral and intravenous contrast and barium follow through, suggestive of malrotation of gut. Intraoperative findings were of classical malrotation involving mid gut with a high lying mobile caecum, Ladd's bands obstructing the duodenum at D2-D3 and a narrow base mesentery. Standard Ladd's procedure with appendectomy was performed. In the post-

operative she had prolonged ileus, which gradually settled.

CASE PRESENTATION - 3:

A 10 years old boy presented with a history of pain abdomen on/off for the last six years. There was a history of occasional bilious vomiting associated with pain in the abdomen. This time the patient had severe pain in the abdomen with bilious vomiting, initially remained admitted at one of the district hospitals for five days and with some settlement of symptoms, he was discharged home. The concerned parents took him to a private center where he was readmitted and given anti-emetic and IV fluids. As soon as he had symptomatic improvement, the patient was discharged home on IV antibiotics. As he still had symptoms, he was taken to a private clinic. At time of presentation, the boy had one episode of light greenish vomiting. Thorough history was taken and examination showed a dehydrated patient with a non-distended and non-tender abdomen. Patient was admitted at the paediatric ward and after rehydration further workup was planned. Paediatric surgeon was involved and a provisional diagnosis of midgut malrotation was made. A targeted workup was done, which included US abdomen, CT abdomen with oral and IV contrast, suggestive of malrotation of gut. Intraoperative findings were of classical malrotation involving mid gut, free mobile caecum, Ladd's band and narrow base mesentery. All three patients had uneventful recovery after surgery & were discharged home.

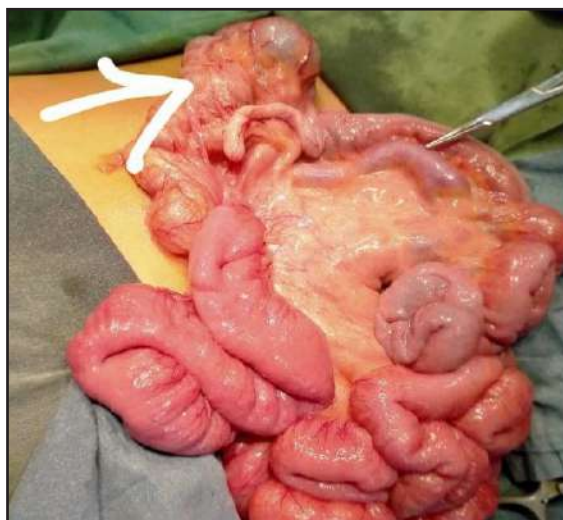


Figure 1: Findings of Malrotation of Gut in Patient - Arrow Shows Caecum on One Side

DISCUSSION:

Congenital malrotation of the gut is one of the major causes of neonatal intestinal obstruction and associated with high mortality and morbidity if not diagnosed promptly and managed on time^{6,7}. It comprises a variety of symptoms in neonates, infants and older children. In neonates and infants, duodenal obstruction and midgut volvulus is the leading complication and patients can present acutely. In older children, chronic abdominal symptoms are there due to intermittent volvulus and gut obstruction⁸. In this case series there is one ten-month-old infant but the presentation was irritable due to pain in the abdomen and vomiting. The other two older children had a history of abdominal pain on/off for a long time. In older and teenage children the diagnosis of malrotation is not straightforward, as the majority of patients can be asymptomatic and some patients may even live their whole life without any issues or complaints⁹. In one of the case series by Adeniyi OF et al¹⁰ children older than one year were included, whose main presenting complaint was abdominal and vomiting. In their study 21.7% children were having malrotation of gut and abdominal pain as the sole presenting feature in 100% of patients. Chacon and Saxena,¹¹ published a case series, which showed that out of nine children with malrotation of the gut, two children were 3 years and 13 years old, who presented with only pain in the abdomen. Midgut volvulus is one of the fatal complications. Due to persistent risk of volvulus and vascular compromise, treatment of congenital malrotation of the gut is exploration and correction either laparoscopic or open method. Prognosis of this condition is excellent with timely diagnosis and intervention.

CONCLUSION:

Though congenital malrotation of the gut commonly presents in neonates and infancy, a high index of suspicion should be there in older children presenting with pain in the abdomen and also if there is associated vomiting.

CONFLICT OF INTEREST: None

FUNDING SOURCES: None

REFERENCES:

1. Jacobs C, Khan FA, Apple C, Larson SD. Duodenal web presenting outside the neonatal period concurrently with malrotation and mid-gut volvulus. *J Pediatr Surg Case Rep.* 2018;39:35-7. <https://doi.org/10.1016/j.epsc.2018.09.005>
2. Mousavi SA, Karami H, Saneian H. Congenital duodenal obstruction with delayed presentation: seven years of experience. *Arch Med Sci.* 2016;12(5):1023.
3. Reddy AS, Shah RS, Kulkarni DR. Laparoscopic Ladd's procedure in children: challenges, results, and problems. *J Indian Assoc Pediatr Surg.* 2018;23(2):61-5.
4. Salim A, Moazzam Z, Ashraf A, Dogar SA, Qazi SH. Congenital absence of the appendix in a child with malrotation. *J Pediatr Surg Case Rep.* 2020;60:101530. <https://doi.org/10.1016/j.epsc.2020.10.1530>
5. Anita L, Rupesh S, Ramana R, Rubee A, Prapti S, Chandra ON. A five years old child with failure to thrive and vomiting presenting as a diagnostic dilemma: a case report. *J Nepal Med Assoc.* 2020;58(228):600-3.
6. Verma A, Rattan KN, Yadav R. Neonatal intestinal obstruction: a 15-year experience in a tertiary care hospital. *J Clin Diagn Res.* 2016;10(2):SC10.
7. Thapa B, Basnet A. Patterns and outcome of neonatal intestinal obstruction in Kanti children's hospital. *J Nepal Paediatr Soc.* 2020;40(2):120-4.
8. Biswas S, Chatterjee I. A prospective comparative study of open verses laparoscopic correlation of intestinal malrotation in paediatric population. *IOSR J Dent Med Sci.* 2019;18(9):1-10.
9. Nakajima Y, Sakata H, Yamaguchi T, Yoshie N, Yamada T, Osako T, et al. Successful treatment of a 14-year-old patient with intestinal malrotation with laparoscopic Ladd procedure: case report and literature review. *World J Emerg Surg.* 2013;8:19.

10. Adeniyi OF, Ajayi EO, Elebute OA, Lawal MA. Intestinal malrotation in the older child: a call for vigilance. J Clin Sci. 2017;14:200-3.
11. Chacon CS, Saxena AK. Approach to intestinal malrotation in children in the laparoscopic era. J Pediatr Endoscopic Surg. 2019;1(4):137-42.

CONTRIBUTORS

1. **Syed Sajid Hussain Shah** - Concept & Design; Data Acquisition; Drafting Manuscript; Critical Revision; Supervision; Final Approval
2. **Yousaf Aziz Khan** - Concept & Design; Drafting Manuscript; Critical Revision; Supervision; Final Approval
3. **Bibi Aalia** - Concept & Design; Drafting Manuscript; Critical Revision; Supervision; Final Approval

