



Establishment and maintenance of donkey-in-mule pregnancy after embryo transfer in a non-cycling mule treated with oestradiol benzoate and long-acting progesterone

Marina Bottrel, Thomaz Fortes, Isabel Ortiz, Manuel Hidalgo, and Jesús Dorado

University of Cordoba, Faculty of Veterinary Medicine, Dept. Animal Medicine and Surgery. Campus Universitario de Rabanales. Ctra. Madrid-Cádiz km 396, 14071 Córdoba, Spain

Abstract

Female mules are considered as infertile; however, they could be used as recipients in interspecific embryo transfer. This study reports for the first time how it is possible to obtain the birth of a live Andalusian donkey foal after transfer a donkey embryo to a non-cycling mule. Two non-cycling mules were used as recipients, oestradiol benzoate was administered when donors showed oestrus and long-acting progesterone after ovulation. The mules also received long-acting progesterone every 7 days until 120 days of gestation. One embryo was collected from the two donor jennies and transferred to one of the mules after 5 days of progesterone treatment. Pregnancy was established and maintained after embryo transfer. The pregnant mule carried to term and delivered a live donkey foal after 375 days of pregnancy. In conclusion, non-cycling mules treated with oestradiol benzoate and long-acting progesterone can be successfully used as recipients of donkey embryos, which open new ways for the conservation of endangered donkey species.

Additional keywords: between-species embryo transfer; donkey embryo; mule recipient; Andalusian donkey.

Abbreviations used: ET (embryo transfer); hCG (human chorionic gonadotropin).

Authors' contributions: Contributed to the study execution: MB and TF. Drafting the manuscript: IO and MH. Conceived and designed the study and wrote the paper: JD. All authors read and approved the final manuscript.

Citation: Bottrel, M.; Fortes, T.; Ortiz, I.; Hidalgo, M.; Dorado, J. (2017). Short communication: Establishment and maintenance of donkey-in-mule pregnancy after embryo transfer in a non-cycling mule treated with oestradiol benzoate and long-acting progesterone. Spanish Journal of Agricultural Research, Volume 15, Issue 4, e04SC01. <https://doi.org/10.5424/sjar/2017154-11653>

Received: 03 May 2017. **Accepted:** 01 Dec 2017.

Copyright © 2017 INIA. This is an open access article distributed under the terms of the Creative Commons Attribution (CC-by) Spain 3.0 License.

Funding: Ministry of Economy and Competitiveness of Spain (Grant AGL2013-42726-R).

Competing interests: The authors declare no conflicts of interest.

Correspondence should be addressed to Jesús Dorado: jdorado@uco.es

Introduction

The population of the Andalusian donkey is estimated at 793 individuals (DAD-IS-FAO, 2014), therefore it is considered as endangered (BOE, 2009). Equine embryo transfer (ET) permits to obtain several foals from a mare each year (Stout, 2006), becoming a valuable strategy for preserving endangered equid species (Summers *et al.*, 1987). However, studies concerning ET in endangered donkeys are scarce and discouraging results have been obtained (Camillo *et al.*, 2010; Panzani *et al.*, 2012). Recipient's pregnancy rate depends on the quality of recipients and their synchronization with donors (Carnevale *et al.*, 2000; Squires *et al.*, 2003). This implies needing a significant number of recipients for each donor, which is difficult to conduct in endangered species. Interspecific ET

and the use of non-cycling recipients could be a successful long-term strategy to increase the number of recipients in ET programs.

The usefulness of cycling mules as recipients of horse (Camillo *et al.*, 2003; Allen, 2005) and donkey (Silva *et al.*, 2013; González *et al.*, 2015) embryos has been previously demonstrated. Besides, intraspecific (Kaercher *et al.*, 2013; Botelho *et al.*, 2015) and interspecific (donkey-in-mare) (Allen *et al.*, 1993; Peña-Alfaro *et al.*, 2014) pregnancies have been established by ET in non-cycling mares. However, non-cycling recipient mules treated with oestradiol benzoate and progesterone before transfer of horse embryos failed to become pregnant (Camillo *et al.*, 2003). To our knowledge, no studies have been conducted to evaluate if non-cycling recipient mules are able to carry a pregnancy to term after transfer of donkey embryos.

Material and methods

The study was started in the Centro Rural Malpica (Palma del Río, Cordoba, Spain) in May 2015. All animal procedures were performed in accordance with the Spanish laws for animal welfare and experimentation (BOE, 2013).

Two fertile Andalusian jennies (7-years-old) served as embryo donors. Estrus was induced with one intramuscular injection of 7.5 mg luprostiol (Prosolvin[®], Virbac, Barcelona, Spain) during diestrus. Ovarian activity was evaluated daily during oestrus by transrectal ultrasound (Aloka SSD 500, ALOKA Co. Ltd., Tokyo, Japan). When a follicle ≥ 35 mm in diameter was detected, ovulation was induced using 1500 IU of human chorionic gonadotropin (hCG; Veterin Corion[®], Divasa-Farmavic S.A., Barcelona, Spain) intramuscularly. Next day, donor jennies were mated with a fertile jack every other day until ovulation.

Two healthy mules (4-years-old and in good body condition) in anoestrus were used as embryo recipients. When the donor jenny was mated the first time, the mule recipients received two intramuscular injections of 5 mg oestradiol benzoate (Sincrodiol[®], Ourofino Saúde Animal, Cravinhos, Brazil) at an interval of 24 h. After the donor jenny ovulated, recipients were given 1500 mg of long-acting progesterone (P4-LA/IM, Brazil) intramuscularly every 7 days until day 120 of pregnancy (Day 0 = day of ET).

Embryo collections were done on day 7 after ovulation (Camillo *et al.*, 2010). Embryos were evaluated under stereomicroscope, washed 10 times in Syngro[®] holding (Bioniche Animal Health, Washington, USA) and loaded into 0.25 ml straws until transferred transcervically to the mule recipients.

Pregnancy diagnosis was performed on days 5 and 25 after ET by ultrasound. Pregnancy was monitored weekly until day 120 after ET and thereafter monthly until parturition. Gender determination was also performed at day 120 (Bucca, 2005).

Results and discussion

Only one embryo (morula stage grade 1 with a diameter of 175 μm) was recovered and transferred to one of the non-cycling recipient mules at day 5 of progesterone treatment. The ET resulted in an ongoing pregnancy. Ultrasonography images of the conceptus at different gestational days are shown in Figure 1. Foetal viability was confirmed by ultrasound each month of pregnancy.

Parturition occurred spontaneously on day 375 of gestation and a live donkey foal was delivered

without the need for assistance. The surrogate mule mother expelled the foetal membranes after birth, and presented strong protective behaviour and large amount of milk in the well-developed udders. Gross examination of the foetal membranes did not reveal any lesions of clinical importance; however, the donkey foal had a congenital osteodystrophy with facial hyperostosis. Similar findings were described by Bryant *et al.* (2012) in a Thoroughbred filly which was born with congenital aneurysmal bone cyst. Although the pathogenesis of these lesions

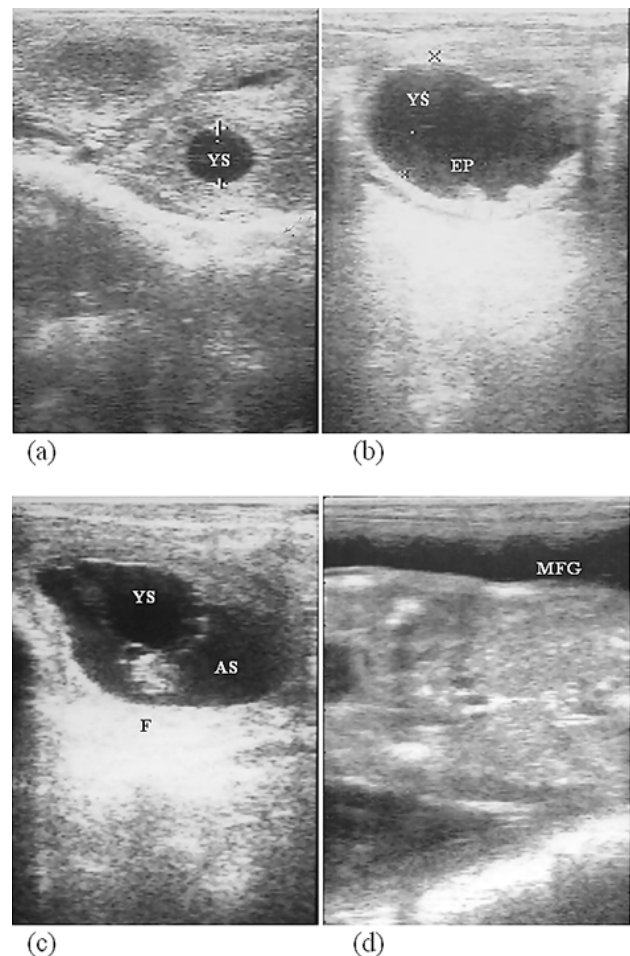


Figure 1. Ultrasonography images (5.0 MHz) of the conceptus from the non-cycling mule recipient at different gestational days: (a) Embryonic vesicle consisting of a yolk sac (YS) at 12 days of gestation (D 0 = ovulation). The shape of the embryonic vesicle was spherical and the diameter was 1.3 mm. (b) Embryo proper (EP) aging 25 days in the embryonic vesicle. The shape of the vesicles was irregular and the diameter was 48 \times 28 mm. (c) Fetus (F) was in the ventral pole at day 40 and the allantoic sac (AS) is observed. The shape of the vesicles was irregular and the diameter was 56 \times 20 mm. (d) At day 120, male foetal gonads (MFG) have a homogeneous texture with a thin central longitudinal echogenic lined vessel.

remains unclear, possible causes are malformation of intraosseous vasculature secondary to trauma, bleeding disorders, fibrous dysplasia, hematomas or underlying neoplasia.

This is the first report of a foal born following transfer of a fresh donkey embryo into a non-cycling mule. Some authors have previously used cycling mule as donkey embryos recipients and obtained pregnancies and/or live donkey foals (Silva *et al.*, 2013; González *et al.*, 2015). Likewise, successful non-surgical transfer of horse embryos into cycling mules has been reported (Camillo *et al.*, 2003), but failed to obtain pregnancies when non-cycling mules were used. These unsatisfactory results have been explained by the lower quality of the endometrium in permanently non-cyclic recipients (Camillo *et al.*, 2003) and the lower fertility rates that have this recipients (Carnevale *et al.*, 2000). The hormonal treatment used in this study showed to be effective for preparing anovulatory mares in deep anoestrus and transitional phase as embryo recipients (Rocha Filho *et al.*, 2004; Botelho *et al.*, 2015). Based on our results, the administration of this treatment to non-cyclic mules would be efficient for establishing and maintaining pregnancy after ET.

The eutocic birth of a live donkey foal suggests a normal development of the placenta (González *et al.*, 2015). Unfortunately, the foal died few hours after the birth due to right-side heart failure, possibly related to asphyxia. In the previous case reported in literature (Bryant *et al.*, 2012) the filly was euthanized, therefore the relationship between the facial lesions and the spontaneous death of the donkey foal cannot be ensured. We could not confirm the excellent maternal ability of mules reported previously (Camillo *et al.*, 2003; González *et al.*, 2015), but a strong protective behaviour and well-developed udders were observed.

We conclude that non-cycling mules treated with oestradiol benzoate and long-acting progesterone can establish and maintain pregnancy after non-surgical transfer of a 7-day donkey embryo. The pregnant mule can successfully carry the donkey conceptus to term and give birth to a mature donkey foal. If this result would be confirmed in further studies using more animals, the use of non-cycling mules in interspecific ET programs could be a good opportunity for the conservation of endangered donkey breeds.

Acknowledgments

We are indebted to the Centro Rural Malpica (Palma del Río, Córdoba) for providing the animals.

References

- Allen WR, 2005. The development and application of the modern reproductive technologies to horse breeding. *Reprod Domest Anim* 40 (4): 310-329. <https://doi.org/10.1111/j.1439-0531.2005.00602.x>
- Allen WR, Kydd DF, Antczak DF, 1993. Intraspecies and extraspecies equine pregnancies. In: *Equine Reproduction*; McKinnon AO, Voss JL (eds.). pp: 536-553. Lea & Febiger, Philadelphia.
- BOE, 2009. Royal decree 2129/2008, of 26 December, that establish the national program for conservation, improvement and promotion of livestock breeds. *Boletín Oficial del Estado [Spain]* No. 23, 27/01/09.
- BOE, 2013. Royal decree 53/2013, of 1 February, that establish the basic rules to protect animals used in experiments and for other scientific purposes, including teaching. *Boletín Oficial del Estado [Spain]* No. 34, 08/02/13.
- Botelho JHV, Pessoa GO, Rocha LGP, Yeste M, 2015. Hormone supplementation protocol using estradiol benzoate and long-acting progesterone is efficient in maintaining pregnancy of anovulatory recipient mares during autumn transitional phase. *Anim Reprod Sci* 153: 39-43. <https://doi.org/10.1016/j.anireprosci.2014.12.014>
- Bryant U, Fallon L, Lee M, Pool R, 2012. Congenital aneurysmal bone cyst in a foal. *J Equine Vet Sci* 32 (6): 320-323. <https://doi.org/10.1016/j.jevs.2011.12.002>
- Bucca S, 2005. Equine fetal gender determination from mid-to advanced-gestation by ultrasound. *Theriogenology* 64 (3): 568-571. <https://doi.org/10.1016/j.theriogenology.2005.05.013>
- Camillo F, Vannozi I, Rota A, Di Luzio B, Romagnoli S, Aria G, Allen WR, 2003. Successful non-surgical transfer of horse embryos to mule recipients. *Reprod Domest Anim* 38 (5): 380-385. <https://doi.org/10.1046/j.1439-0531.2003.00444.x>
- Camillo F, Panzani D, Scollo C, Rota A, Crisci A, Vannozi I, Balbo S, 2010. Embryo recovery rate and recipients' pregnancy rate after nonsurgical embryo transfer in donkeys. *Theriogenology* 73 (7): 959-965. <https://doi.org/10.1016/j.theriogenology.2009.11.024>
- Carnevale EM, Ramirez RJ, Squires EL, Alvarenga MA, Vanderwall DK, McCue PM, 2000. Factors affecting pregnancy rates and early embryonic death after equine embryo transfer. *Theriogenology* 54 (6): 965-979. [https://doi.org/10.1016/S0093-691X\(00\)00405-2](https://doi.org/10.1016/S0093-691X(00)00405-2)
- DAD-IS-FAO, 2014. Information system domestic animal diversity. <http://dad.fao.org/> [Jan 9, 2017].
- González SM, Gomes RG, Souza AK, Silva CB, Silva-Santos KC, Seneda MM, 2015. Evidences of regular estrous cycles in mules and successful use of these animals as recipients for donkey embryos. *J Equine Vet Sci* 35 (10): 869-872. <https://doi.org/10.1016/j.jevs.2015.07.010>

- Kaercher F, Kozicki LE, Camargo CE, Weiss RR, dos Santos IW, Muradas PR, Bertol MAF, de Abreu RA, 2013. Embryo transfer in anovulatory recipient mares treated with estradiol benzoate and long-acting progesterone. *J Equine Vet Sci* 33 (3): 205-209. <https://doi.org/10.1016/j.jevs.2012.06.009>
- Panzani D, Rota A, Crisci A, Kindahl H, Govoni N, Camillo F, 2012. Embryo quality and transcervical technique are not the limiting factors in donkey embryo transfer outcome. *Theriogenology* 77 (3): 563-569. <https://doi.org/10.1016/j.theriogenology.2011.08.032>
- Peña-Alfaro CE, Barros LO, Carneiro GF, Gastal MO, Gastal EL, 2014. Embryo transfer in Pega donkeys (*Equus asinus*) in Brazil. *J Equine Vet Sci* 34 (1): 185. <https://doi.org/10.1016/j.jevs.2013.10.135>
- Rocha Filho AN, Pessoa MA, Gioso MM, Alvarenga MA, 2004. Transfer of equine embryos into anovulatory recipients supplemented with short or long acting progesterone. *Anim Reprod* 1 (1): 91-95.
- Silva AR, Gomes RG, Gonzalez SM, Barreiros TRR, Seneda MM, 2013. Pregnancy after transfer of donkey embryo in cycling mule as recipient. *Anim Reprod* 10 (3): 500.
- Squires EL, Carnevale EM, McCue PM, Bruemmer JE, 2003. Embryo technologies in the horse. *Theriogenology* 59 (1): 151-170. [https://doi.org/10.1016/S0093-691X\(02\)01268-2](https://doi.org/10.1016/S0093-691X(02)01268-2)
- Stout TAE, 2006. Equine embryo transfer: review of developing potential. *Equine Vet J* 38 (5): 467-478. <https://doi.org/10.2746/042516406778400529>
- Summers PM, Shephard AM, Hodges JK, 1987. Successful transfer of the embryos of Przewalski's horses (*Equus przewalskii*) and Grant's zebra (*E. burchelli*) to domestic mares (*E. caballus*). *J Reprod Fertil* 80 (1): 13-20. <https://doi.org/10.1530/jrf.0.0800013>