



## Review Article

## Extreme capsule is a bottleneck for ventral pathway

Ehsan Shekari<sup>a</sup>, Sepideh Goudarzi<sup>b</sup>, Elahe Shahriari<sup>c</sup>, Mohammad Taghi Joghataei<sup>a,\*</sup><sup>a</sup> Department of Advanced Technologies in Medicine, Iran University of Medical Science, Tehran, Iran<sup>b</sup> Department of pharmacology, Faculty of Pharmacy, Tehran University of Medical Sciences, Tehran, Iran<sup>c</sup> Department of Physiology, Faculty of Medicine, Iran University of Medical Science, Tehran, Iran

## ARTICLE INFO

## Keywords:

Extreme capsule  
Uncinated fasciculus  
Inferior occipito-frontal fasciculus  
Ventral pathway of language  
Bottleneck  
Diffusion tensor imaging

## ABSTRACT

As neuroscience literature suggests, extreme capsule is considered a whiter matter tract. Nevertheless, it is not clear whether extreme capsule itself is an association fiber pathway or only a bottleneck for other association fibers to pass. Via our review, investigating anatomical position, connectivity and cognitive role of the bundles in extreme capsule, and by analyzing data from the dissection, it can be argued that extreme capsule is probably a bottleneck for the passage of uncinated fasciculus (UF) and inferior fronto-occipital fasciculus (IFOF), and these fasciculi are responsible for the respective roles in language processing.

## Introduction

The extreme capsule (EmC) is a very thin location of intersect, connecting the frontal and temporal opercula with insula (Bajada et al., 2015). A capsule in neuroanatomy, is an anatomical location for the neural fiber tracts and bundles to pass through, whereas a fascicle (bundle) is a collection of white matter nerve fibers connecting two regions of the brain (Bajada et al., 2015). This poses a doubt on the fact that EmC itself is a nerve bundle involved in language processing (Bajada et al., 2015; Kümmerer et al., 2013; Makris and Pandya, 2009a, 2009b; Ueno et al., 2011; Weiller et al., 2011). It appears that the lingual processes of EmC, are in fact the roles of the bundles coursing the EmC, being a part of the ventral pathway (Axer et al., 2013; Rijntjes et al., 2012). Hence in the present study, we have aimed to search the literature thoroughly on the role and structure of the ventral pathway. At first, a brief overview of anatomy of the EmC and its bundles is provided; then, the role of ventral pathway and its fibers in human cognitive language functions and development are discussed. Next, we review diseases in which these bundles are involved. Finally, we discuss the fact that EmC, in contrast to humans, is only a bundle in monkeys, known as the extreme capsule fiber system.

## Anatomical location of extreme capsule

Extreme capsule and external capsule are two white matter structures, located between insula and putamen. These structures that are

separated by claustrum, connect occipital, temporal, and frontal lobe together (Makris et al., 1999; Makris and Pandya, 2009a, 2009b; Miller et al., 2011). (Fig. 1).

## Dissection

On the lateral surface of the brain, the insula is identified by removal of the frontal, parietal, and temporal lobes (Morino et al., 2002). After removing half of the cortex above the insula, the EmC appears, consisting of association fibers connecting the insula and the operculum. Upon gentle removal of the insular cortex, from internal to external, external capsule, claustrum and EmC could be seen respectively, as well as putamen (Wysiadecki et al., 2019).

EmC is the anchor of the association fibers in the insular cortex itself and the connecting fibers between the insular and the opercular cortex. In angular gyrus, the short association fibers in the EmC become convergent, and form the white matter of short and long insular gyrus (Nachtergaele et al., 2019). Deeper inside, the inferior occipito-frontal fasciculus (IFOF) and the uncinated fasciculus (UF) are seen. The UF is made up of long association fibers that connect the frontal and temporal lobes. It is located deeply in the Insula border beneath the basal cortex of the insula (Baldoncini et al., 2019), and is therefore seen uncinated. The very close anatomical connections between uncinated fasciculus and the IFOF prevents accurate and complete dissection of this area (Baldoncini et al., 2019); however, IFOF connects the superior and posterior temporal and the posterior parietal gyrus to the pars opercularis and pars triangularis in the inferior frontal gyrus and is located above the UF

\* Corresponding author.

E-mail address: [mt.joghataei@yahoo.com](mailto:mt.joghataei@yahoo.com) (M.T. Joghataei).<https://doi.org/10.1016/j.ibneur.2020.11.002>

Received 29 September 2020; Accepted 30 November 2020

Available online 3 February 2021

2667-2421/© 2020 Published by Elsevier Ltd on behalf of International Brain Research Organization. This is an open access article under the CC BY-NC-ND

license (<http://creativecommons.org/licenses/by-nc-nd/4.0/>).

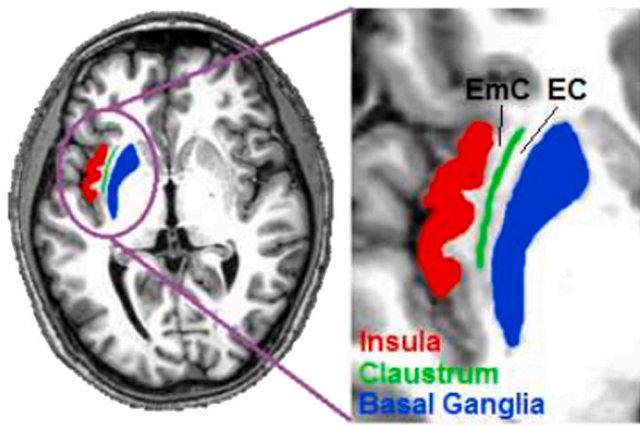


Fig. 1. Anatomical location of the EmC – axial view.

Figure taken from the following manuscript, with permission of both the correspondent author and the publisher: Bajada CJ, Ralph MA, Cloutman LL. Transport for language south of the Sylvian fissure: the routes and history of the main tracts and stations in the ventral language network. *cortex*. 2015 Aug 1;69:141–51. (under the Creative Commons CC-BY-NC-ND license).

(Hugues Duffau, 2015; Martino et al., 2010; Sarubbo et al., 2013). It passes through the extreme capsule internally and caudally, along the middle temporal gyrus (Cloutman et al., 2012). These two form the main bundles in the EmC and are two of the four bundles of ventral pathway.

Stephanie et al. (2018) used different ROIs to distinguish bundles of the ventral pathway. One ROI was placed on the occipital lobe on the coronal plate just behind the parieto-occipital sulcus, the second on the extreme and external capsules' white matter, and the third on the anterior white matter of the anterior temporal lobe. The pathway between the occipital and the ROI of EmC was considered the IFOF, the occipital-anterior temporal pathway was considered the ILF, and the pathway between the anterior temporal and the extreme/ external capsules was considered the UF (Forkel and Catani, 2018). It appears that the IFOF and the UF have an overlap in the area where EmC exists (Fig. 2).

In summary, bundles passing the EmC are short and long association fibers. The long fibers are the IFOF and UF, being the deeper bundles of the ventral pathway, too.

#### Structural connectivity of ventral pathway

Ventral pathway is projected on the ventral-lateral side and includes cortices in the inferior frontal gyrus (IFG), inferior parietal lobe (IPL), superior temporal sulcus (STS) and in the posterior inferior temporal lobe (parts of the middle temporal gyrus (MTG)) and the inferior temporal gyrus (ITG) (Hickok and Poeppel, 2004). The ventral pathway is mostly a pathway of language, proved by its structural connectivity: (Table 1, Fig. 3).

#### Language functions of the ventral pathway

EmC is at a strategic position in the language comprehension network due to the functions of its bundles. Several studies have investigated the results of stimulating ventral and dorsal pathway bundles using intraoperative stimulation (IOP) technique. The results are summarized in Table 2, which are very well in line with their structural connectivity (Table 1). Considering the structural connectivity and IOP stimulation of the IFOF and UF bundles, it can further be hypothesized that the lingual roles known to be due to the EmC fiber system, are eventually the roles of these bundles.

#### Semantic and Comprehension Processing

The fact that ventral pathway is placed in areas involved in language,

indicates its central role in language processing, particularly the connection of the Broca area in the frontal lobe with Wernicke's area in the temporal and parietal lobes. Ventral pathway extends to the primary auditory cortex, the middle and superior temporal gyrus, the anterior superior temporal gyrus, the pars opercularis and triangularis in inferior frontal gyrus and the insula. These structures are involved in many lingual roles (Axer et al., 2013; Venkatasubramanian et al., 2008; Zhang et al., 2018). The IFOF and the UF are the predominant bundles of this pathway in language. In DTI, reduction of FA in IFOF is associated with impairment in many language modalities (J. Zhang et al., 2018).

*IFOF is the main bundle for semantic processing in ventral pathway.* The inferior frontal gyrus is largely involved in lexical and semantic features in word repetition task and plays a role in extracting meaning from the acoustic-phonetic derivations (Ueno et al., 2011; Wilson et al., 2011). In the semantic network of the left hemisphere, the nodes in the middle temporal gyrus are directly connected to the orbital prefrontal nodes. Middle temporal gyrus (and adjacent areas in the inferior temporal gyrus), connected to the prefrontal region via the IFOF, is involved in storing and accessing lexical-semantic representations. Thus, this anatomical relationship between temporal and prefrontal areas, appears to play a role in the choice of lexical information, as well as adjusting linguistic meanings to the stored knowledge about the world (Saur et al., 2010). In the process of learning a verbal stimulus with an image, it is found that the clusters of parietal and temporal regions are related. These two areas are among the ones most of whose connections are via the IFOF.

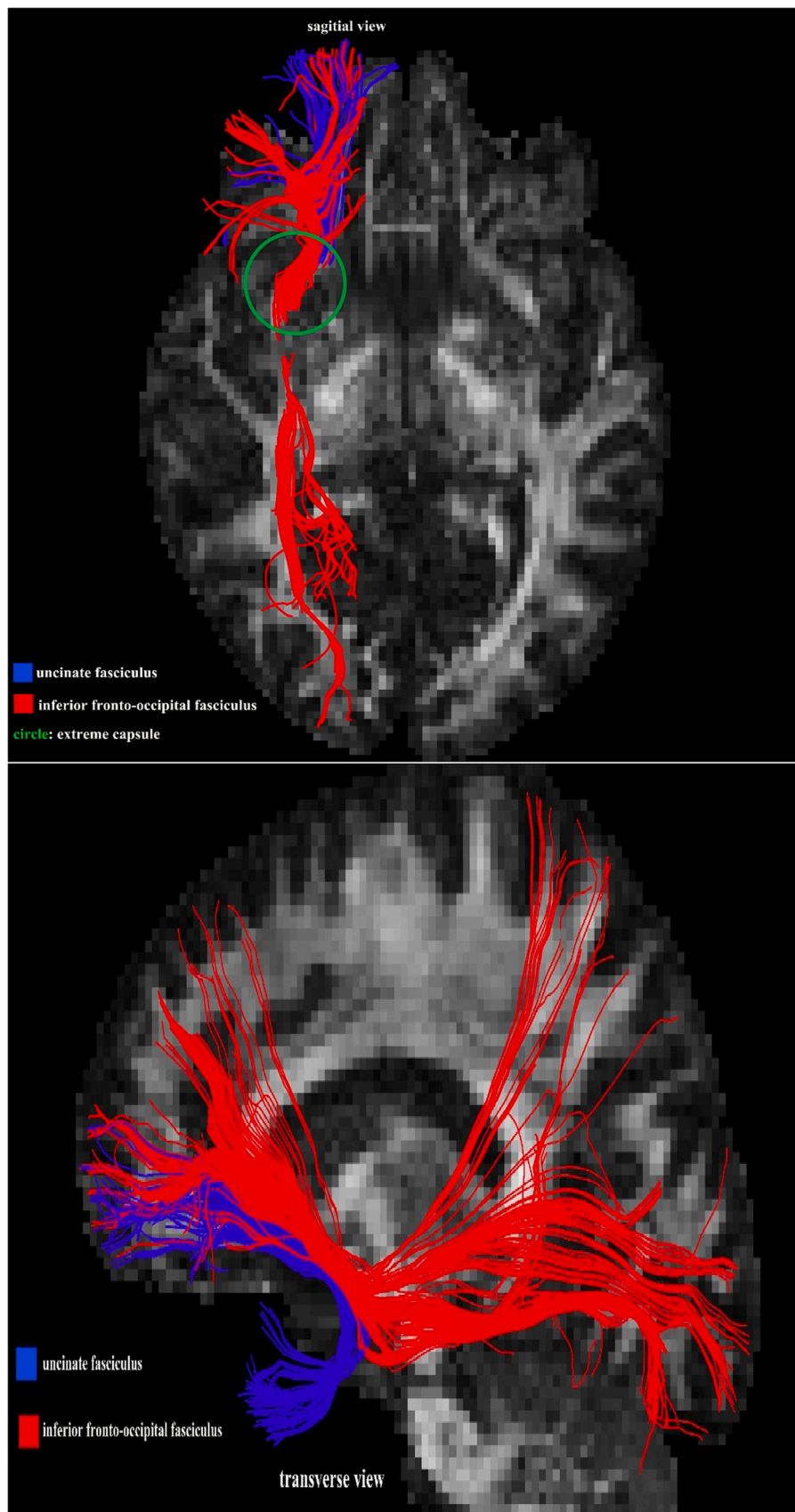
A DTI study placed the seeds both on the white matter below the pars orbitalis and pars triangularis in the inferior frontal gyrus, and in the middle part of the white matter below the superior temporal gyrus. The study found that damage to the UF was neither a good predictor of the level of damage to speech speed and fluency, nor of the person's ability to name (Marchina et al., 2011). Despite this and the fact that in the intraoperative stimulation, the UF did not give any responses, there is evidence that this bundle is also engaged in semantic processing especially by the famous people naming task results (O'Rourke and de Diego Balaguer, 2020; Papagno, 2011). It is further hypothesized that the UF along with the ILF form an indirect pathway of semantic processing which contribute to its role in famous people naming. Moreover, in semantic dementia of famous naming task, the most damaged white matter was that of the UF (Cocquyt et al., 2020; Mangnus, 2020). It is observed that in patients with dementia, UF undergoes impairments sooner than many other, causing proper naming anomia (Cocquyt et al., 2020).

Another possible role of UF is the semantic control (the ability of regulating semantic representation). This might be because of the fact that UF terminates in orbitofrontal cortex (OFC), which is involved in executive functions of cognitive processes (Cocquyt et al., 2020).

*IFOF is the main bundle for comprehension processing in ventral pathway.* IFOF's connection with the two classical regions of language reflects its importance in today's linguistic models and appears to play a role in the comprehension process, naming and reading. Furthermore, part of the IFOF is located in the middle temporal lobe on the roof of the temporal horn. The role of middle temporal gyrus in processing abstract words and lexical and semantic processing, and the ITG in word recognition (Nobre et al., 1994; Visser et al., 2012), allow the IFOF to be of importance in comprehension. Electrical stimulation of the floor of EmC-the anterior IFOF-, can cause semantic paraphasia (Table 2).

#### Phonological and syntax processing

The dorsal pathway contains the arcuate fasciculus (AF) that connects superior temporal cortex to the inferior frontal gyrus (Axer et al., 2013), as well as the superior longitudinal fasciculus (SLF) which connects parts of parietal and temporal lobes with different parts of



**Fig. 2.** Sagittal and transverse views of IFOF and UF and EmC. IFOF originates from posterior parietal and occipital cortex and through temporal lobe, reaches the inferior frontal cortex (red pathway). The UF originates from anterior temporal lobe and goes below the IFOF, reaching the orbitofrontal cortex (blue pathway). The two pathways meet in the EmC (circle).(For interpretation of the references to colour in this figure legend, the reader is referred to the web version of this article.)

**Table 1**  
Structural connectivity of the ventral pathway.

Bundle	Connecting	To	Reference
IFOF	Posterior occipital lobe, Posterior parietal lobe, Inferior temporal gyrus, Middle temporal gyrus, Superior temporal gyrus	Inferior frontal gyrus	(Duffau, 2015; Martino et al., 2010)
UF	Anterior temporal lobe	Ventrolateral prefrontal cortex	(Kier et al., 2004; Von Der Heide et al., 2013)
MLF	Angular gyrus, Supramarginal gyrus	Superior temporal gyrus	(Jouen et al., 2015; Makris et al., 2013)
ILF	Posterior occipital	Anterior Temporal lobe	(Gil-Robles et al., 2013; Panesar et al., 2018)

premotor and prefrontal cortices (Martino et al., 2013; Yagmurlu et al., 2016). Language functions of the dorsal pathway include phonological processing and verbal retrieval. The AF in the dorsal pathway connects IFG to the middle part of the superior temporal gyrus. This nerve fiber is located in the posterior part of the UF and appears to play a role in phonological processing (Axer et al., 2013); on the other side, IFOF connecting these two areas is involved in verbal retrieval. (Frey et al., 2008).

Bilateral reduction in FA of the ventral pathway is seen in adolescents with syntactic and semantic problems (Northam et al., 2012). And damage to the dorsal pathway is also associated with wide dysfunctions

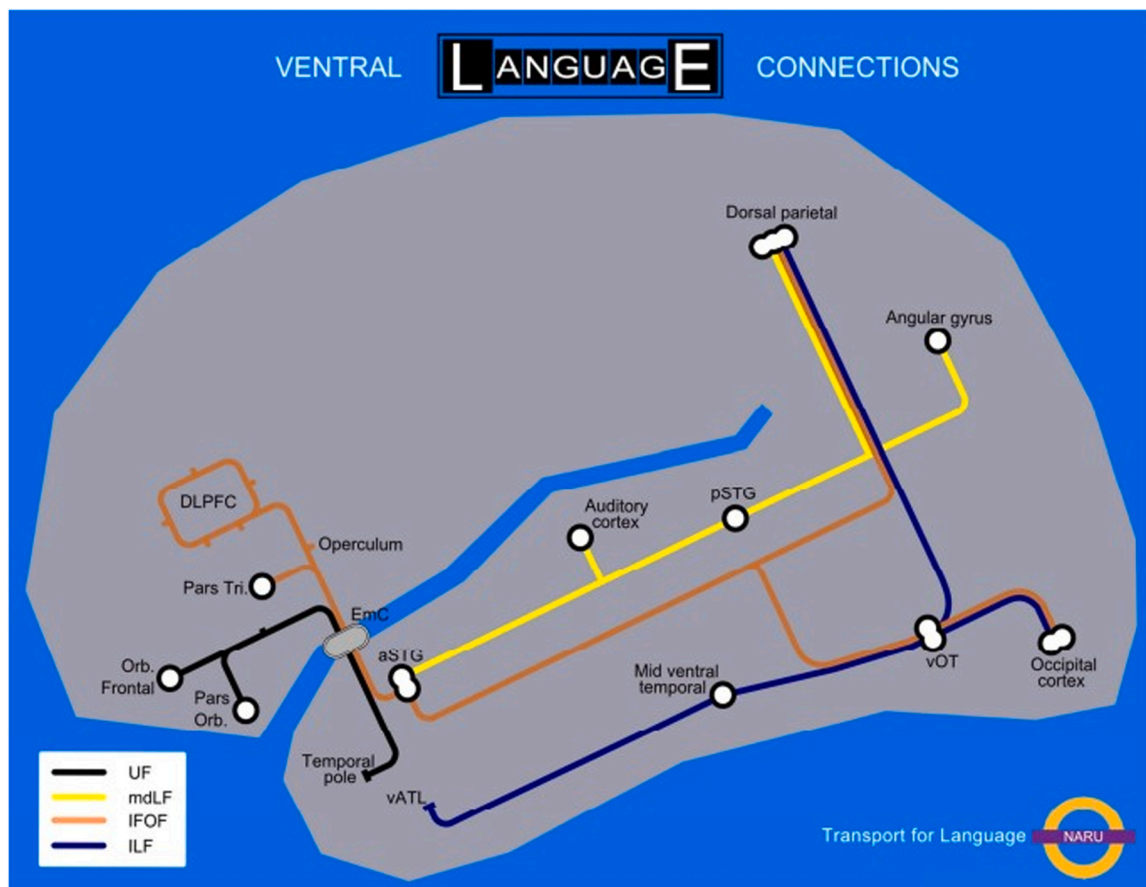
in language (Holland et al., 2018). It therefore seems that both ventral and dorsal pathways are involved in syntax processing. Studies have shown that the Brodmann’s areas 44, 45, 47 are active in this process (Griffiths et al., 2012). This approves the role of IFOF from ventral and AF from the dorsal pathway, concerning their connections with these areas.

*Human language development and cognitive language functions*

Anatomically, human language development is not only due to an increase in the volume of the Broca’s area, but also whole brain growth, particularly proven by presence of long white matter pathways that have spread throughout the brain (Frey et al., 2008). This development happens in stages as of birth.

The IFOF dissection shows that this bundle has two parts. One is a superficial tract involved in the lingual network, which terminates in pars triangularis and pars opercularis; and the second one, is a deep tract ending in three parts of the frontal region: 1) the anterior part of the frontal pole and the orbitofrontal cortex (OFC), 2) the middle part in the medial frontal gyrus and 3) the posterior part in the medial frontal gyrus and the lateral posterior prefrontal cortex. The deep tract moves through the EmC and the superficial tract moves through both the extreme and external capsules (Brauer et al., 2013).

Concerning the development of these pathways in childhood, it appears that the superficial part of the IFOF forms and matures earlier than the other pathways, and the whole bundles of the ventral pathway earlier than the dorsal (Brauer et al., 2013). In order to comprehend a speech, the acoustic input must be transformed into semantic conceptual



**Fig. 3.** Structural Connectivity of the ventral pathway.

Figure taken from the following manuscript, with permission of both the correspondent author and the publisher: Bajada CJ, Ralph MA, Cloutman LL. Transport for language south of the Sylvian fissure: the routes and history of the main tracts and stations in the ventral language network. cortex. 2015 Aug 1;69:141–51. (under the Creative Commons CC-BY-NC-ND license).

**Table 2**  
Intraoperative electrical stimulation of white matter.

Study	Structure	Function
Duffau et al. (2008)	Arcuate fasciculus	Phonemic paraphasia
	Inferior frontooccipital fasciculus (IFOF)	Semantic paraphasia
	Subcallosal fasciculus	Transcortical motor aphasia
	Frontoparietal phonological loop (lateral part of superior longitudinal fasciculus)	Speech apraxia during stimulation
Duffau et al. (2009)	Fibers coming from the ventral premotor cortex	Anarthria
	IFOF	Semantic paraphasia
	Arcuate fasciculus	Phonological paraphasias
Mandonnet et al. (2007)	Stimulation of UF	No response
	IFOF	Semantic paraphasia
Leclercq et al. (2010)	Arcuate fasciculus	Phonological paraphasias
	ILF	No response
De Witt Hamer et al. (2011)	Arcuate fasciculus	Speech arrest/anarthria phonemic/syntactic semantic paraphasia
	IFOF	Semantic paraphasia perseveration
	MLF	No response

representations. On the other hand, the brain must connect the information from speech acoustics to the speech motor system to produce vocals, via the sound pathway. Since there are various actions involved in converting sound mapping to meaning in words, and since sounds are varied in the manner of their acoustic properties, each of these steps has different computational tasks and consequently, particular neural pathways. The dual pathway model shows that ventral pathway which includes structures in the superior and middle parts of the temporal lobe, is involved in the processing of perceptual signals, while the dorsal pathway, which includes structures in the posterior region of the planum temporale, plays a role in converting acoustic signals into productive representations, which is essential for speech production (Hickok and Poeppel, 2004). It is hence hypothesized that the IFOF's development is prior to that of AF, and therefore takes a variety of roles in language processing. After maturation of the AF, the IFOF will dominate in the role of perception and semantic modalities.

It is therefore believed that semantic and comprehension processing happens earlier in a newborn than when they start to put vocals meaningfully together. The dorsal pathway that connects the temporal cortex and the Broca's area is not visible in newborns, standing for the inability of the newborn to speak (Perani et al., 2011). However, in cases of immaturity of the dorsal pathway, the ventral will compensate. (Brauer et al., 2013) For instance, immaturity of the ventral pathway was ameliorated following music therapy (de Almeida et al., 2020). It is also mentioned that in comprehension processing of a sentence, children, unlike adults, use the area 45 which is connected to the superior temporal gyrus and superior temporal sulcus by the IFOF. This use may be due to immaturity of the dorsal pathway (Brauer et al., 2011). Walton et al. (2017) has demonstrated that in preschool children whose AF is immature, the IFOF is involved in phonological processing and word formation (Walton et al., 2018). Furthermore, it is reported that the IFOF is associated with the ability to read in children with dyslexia. (Vanderawera et al., 2017).

In children, increased testosterone levels are associated with increased functional connections and the integrity of the white matter fibers coursing the EmC. The fibers appear to be thicker (shown by higher fractional anisotropy) in boys with higher testosterone levels, and respectively thinner, in those less skilled in language than girls (Hahn et al., 2016).

Comparison of bilingual and monolingual children also showed that in bilingual children, the FA (fractional anisotropy) values in the ventral pathway of language processing are higher than in monolingual children

(Mohades et al., 2012). Also, the fact that myelination of the ventral pathway of the right hemisphere is greater than the left, might be associated with greater comprehension and expression skills in children (O'Muircheartaigh et al., 2013). In summary, there seems to be a necessity for expansion of knowledge in this area.

#### Other cognitive functions of the ventral pathway

Although ventral pathway is mostly involved in language, some other functions are found to be associated with its bundles, including the IFOF and UF in the EmC. It is suggested that future studies further explore these areas.

#### Attention

In the attentional system, the ventral pathway is involved in integrating the perception of space for the intended action and for accurate estimation of the associated stimulus. In the locomotor system, the posterior parietal and prefrontal regions are involved in imaging the movement and pantomime use of objects. We hypothesize that a more general function of the ventral pathway could be to extract and link a set of fixed properties of perceived elements (in a limited number of specific features, e.g. "predecessor" categories) which is related to semantic memory and meaning. Thus, processing of the ventral pathway does not depend on the chronological or spatial sequence of the elements, but is optimized to test compounds in order to extract meaning (Rijntjes et al., 2012). Moreover, the activity of the right hemisphere temporo-parietal regions, including the supramarginal gyrus, the caudal superior temporal gyrus, the anterior insula, and the caudal part of the inferior frontal gyrus, pars opercularis and pars triangularis, is associated with the "attention" network. Pars triangularis is responsible for processing information related to purpose, and filtering and removing the disturbing signal and selecting the appropriate target. This structure along with insula which is responsible for integrating self-awareness and conscious representation, as well as the middle temporal gyrus, are directly connected to each other by ventral pathway involved in spatial visual attention (Umarova et al., 2010).

#### Active visual exploration

In active visual exploration, the superior temporal gyrus, superior temporal sulcus, temporoparietal junction, and the inferior frontal gyrus are very active. Since IFOF and MdLF are parts of the white matter that connects these areas, these two bundles appear to play a role in visual exploration and target search (spatial orientation and attention) (Suchan et al., 2014).

#### Truth recovery

Ventral is involved in truth recovery or recall of mathematical facts, by anterior sections of the rostral IFOF bundle (Klein et al., 2013).

#### Social behavior

The neural circuitry associated with social behavior is more found in frontal and temporal regions. The IFOF appears to be a part of the brain circuit associated with social behavior, along with the ILF, cingulum, and arcuate fasciculus (Noonan et al., 2018).

#### Singing anatomy

In singing, language processing and motor control are both involved. The first includes both of the ventral and dorsal pathways, i.e. SLF, AF, IFOF and the UF (Loui, 2015), and the latter, premotor, anterior insula, inferior parietal, STG and the primary sensory area. Since singing is a combination of a variety of musical, lingual and hearing activities, it could be a proper modality for investigating the evolution of communication processes.

## Diseases in which the extreme capsule is involved

### Huntington's disease

In Huntington's disease, fractional anisotropy (FA) of commissural fibers such as Corpus callosum, fornix, association fibers in the EmC, external capsule and the inferior longitudinal fasciculus is decreased in both hemispheres. In late stages of the disease, degeneration of valerian causes damage to the corpus callosum and the bundles in extreme and external capsules. Investigation of these tracts can help in further discovering the degenerative process of this disease (Della Nave et al., 2010).

### Alzheimer's disease

Analyzing changes in the white matter in healthy elderly, people with mild cognitive impairment and patients with Alzheimer's disease, a significant difference between FA and MD values, in the corpus callosum, from the genu to the splenium, the anterior interface, the external capsule /bundles in EmC/ temporal stem, cingulum and SLF could be observed. In a study by Zhang et al. on AD patients with mild cognitive impairment, the left IFOF and right cingulum cingulate showed significantly lower rates of FA compared with the control (Zhang et al., 2019). These results show that in addition to the association fibers between the hemispheres, examining the ventral pathway can be a helpful marker in diagnosing cognitive impairment (Douaud et al., 2011). In Zhang's study, the significant decrease in FA and increase in MD of the IFOF in AD patients compared with those with mild cognitive impairment and the normal population, was the most distinctive characteristic of AD patients (Zhang et al., 2019). Moreover, between the pathways, IFOF demonstrated highest hypersensitivity rates among all (Taylor et al., 2017).

### Stroke

Stroke lesions in the depth of the white matter including bundles in EmC, between the insular cortex and the putamen, cause impaired comprehension (Freedman et al., 1984; Saur et al., 2010), whereas damage to the arcuate fasciculus causes inability in repetition task in conduction aphasia (Kümmerer et al., 2013). This is because executive semantic processing (choice between several words) involves the lateral ventricle prefrontal cortex. Because the lateral ventricle prefrontal cortex and the anterior temporal lobe are involved in the prefrontal cortex comprehension process, and since their connections are made by the EmC bundles, damage to these bundles appears to disrupt perception. Moreover, electrical stimulation of white matter below the Brodmann area 45, which includes the EmC, causes errors in naming the living objects (Papagno et al., 2011).

Repetition task is normally performed via the phonetic system; however, in conduction aphasia, where the dorsal pathway is damaged, compensatory activation of the ventral pathway will help to repeat the word correctly, particularly real words, by using the semantic system (Ueno and Lambon Ralph, 2013). This happens in cases where ventral pathway is not damaged.

Analyzing the location of injury in the left hemisphere of people with a history of stroke, who were also able to tell routine stories, it was found that damage to the EmC bundles was associated with inability to tell memory-based stories, stories with emotional load and to respond in a normal speed to question "what happened to you during the stroke?". A more detailed analysis revealed that insufficiency of speech speed was not related to damages to putamen, and since the EmC is located near putamen, this insufficiency is probably damage to the ventral pathway (Efthymiopoulou et al., 2017).

In summary, it appears that lesion of ventral pathway causes disruptions in comprehension and semantic processing, affecting many language modalities.

### Developmental language disorders

In children with developmental language disorders, the dorsal

pathway is usually underdeveloped. In such conditions, hyperactivity in ventral pathway and the right AF is observed, which seem to be the compensatory mechanisms. (Verly et al., 2019).

### Autism

In autistic children, both ventral and dorsal pathways seem to have abnormal performance (Stefanatos and Baron, 2011). Improvement in word production in these children is apparently by compensatory activity of arcuate fasciculus of the left hemisphere and EmC bundles of both hemispheres, since increase in the size of these bundles is observed (Chenausky et al., 2017; Radua et al., 2011). Moreover, FA changes in the EmC bundles seem to be associated with IQ (Hirose et al., 2014). Investigating the relationship between IQ and maturation of the bundles in extreme capsule can be effective in determining their role in cognitive processes.

Due to the damage of the pathways connecting the frontal and temporal lobes of autistic children, the use of music-based therapies and other therapies that target the EmC bundles and the arcuate fasciculus of the right hemisphere can enhance their communication skills (Wan and Schlaug, 2010).

### Chromosome 22q11.2 deletion syndrome

The chromosome 22q11.2 deletion syndrome is represented with variety of representations: learning difficulties, poor social skills and intelligence, poor performance, emotional problems and schizophrenia. It is found in these patients that ILF, MLF, and IFOF grow significantly less than normal children (Tylee et al., 2017). In DTI study of this disease, reduction of FA was seen in left IFOF. It seems that there are bilateral axonal alterations in both of the EmC bundles in these children compared with normal people (Kikinis et al., 2013). Furthermore, FA of the UF had bilaterally altered rates in these children (Perlstein et al., 2014). Although psychotic symptoms in both of these diseases have similarities, differences exist in their underlying cause of the damage. In schizophrenia, structural damage is due to myelin disruptions while in this syndrome, due to abnormalities in axon integrity (Kikinis et al., 2013).

### Schizophrenia

People with schizophrenia suffer from a wide range of symptoms, including cognitive problems such as memory, executive function, attention and language deficits. In the study by Surbeck et al. (2020) it appears that IFOF's density is decreased in these patients, which might be the reason for their semantic deficit and the disorganized speech and poverty of speech (Surbeck et al., 2020). Analysis of disruptions in IFOF could be a proper diagnostic tool in predicting semantic deficits (Kubicki et al., 2011). Furthermore, it has been observed that in people with schizophrenia, the right EmC and the left occipital thalamus are significantly distinguishable from the normal group due a lower level of integrity. This reduces the processing speed in these people (Tangmose et al., 2017).

### Investigating extreme capsule anatomy and language pathway in monkey

There are long communication pathways in monkeys, that connect the various parts of the lateral surface of the superior temporal gyrus and the supratemporal plane to the frontal cortex. They consist of two distinct fibers: 1) The extreme capsule fiber system (ECFS) that connects the middle parts of the superior temporal gyrus to the lateral surface of the frontal lobe, and 2) UF that connects the most posterior part of superior temporal gyrus to the dorsal part of the posterior lateral frontal cortex (Petrides and Pandya, 1988). The coding of auditory information related to objects is done by the lateral ventral cortex in the monkey which is connected to the anterior part of the superior temporal gyrus by these fibers (Rauschecker, 2018).

These Fronto-Temporal axons, which form the EmC, are not only from the anterior temporal gyrus but also originate from the following:

multisensory cortex in the superior bank, the depth of the temporal sulcus, the visual communication cortex in the superior temporal sulcus ventral bank and the posterior inferior temporal region. The axons that move through the EmC, and go to the lateral ventral area 12/47, originate from the ventricle bank of the superior temporal sulcus and the adjacent inferotemporal region, while UF terminates in the orbital section of the frontal lobe, including the orbital section 12/47 (Petrides and Pandya, 2009).

In monkeys, ECFS is the principal association pathway in EmC, linking the middle superior temporal region with the caudal parts of the orbital cortex and the ventrolateral prefrontal cortex, including BA 45. These areas are analogous to the Wernicke and Broca language areas in human (Schmahmann et al., 2008); and thus, not only is the ECFS of monkey an important structure in language processing, but is the analogue of IFOF in human.

In monkeys, region 45 (equivalent to pars triangularis in humans) is connected bilaterally through the ECSF with the middle part of the superior temporal gyrus and the superior temporal cortex sulcus. Superior temporal gyrus is involved in the processing of auditory information specific to one modality, and superior temporal sulcus is involved in multi-modality processing.

The ECFS passes below the insula (Cohen et al., 2011). This pathway, normally involved in retrieval of memories stored in posterior association cortex, was adapted during human evolution for controlled retrieval of verbal information in the human left hemisphere (Rilling et al., 2012) and is more related to verbal recovery. In monkeys however, the ECFS is associated with auditory processing and memory recovery. In general, ventral pathway is related to goal-directed observations – observation of an act which reaches a point-, while the dorsal pathway is involved in extracting detailed information from observed actions. Activation patterns of these two pathways vary between chimpanzees, monkeys and humans. While monkeys and chimpanzees have more activations in the ventral pathway, it is the opposite in humans (Reyes and Sherwood, 2014).

## Conclusion

Through our review, it seems that the EmC itself is not a nerve bundle, rather a place for specific white matter nerve fibers to pass through. The two major fibers are the IFOF and UF, responsible for most of the language and other functions generally known as EmC's. It appears that the "extreme capsule fiber system" in monkeys is analogous to the IFOF in humans.

## Ethical statement

This material is the authors' own original work, which has not been previously published elsewhere. The paper properly credits the meaningful contributions of co-authors and co-researchers. All sources used are properly disclosed (correct citation). All authors have been personally and actively involved in substantial work leading to the paper, and will take public responsibility for its content.

## Conflicts of Interest

The authors declare that there were no conflicts of interest.

## References

de Almeida, J.S., Lordier, L., Zollinger, B., Kunz, N., Bastiani, M., Gui, L., Hüppi, P.S., 2020. Music enhances structural maturation of emotional processing neural pathways in very preterm infants. *Neuroimage* 207, 116391.

Axer, H., Klingner, C.M., Prescher, A., 2013. Fiber anatomy of dorsal and ventral language streams. *Brain Lang.* 127 (2), 192–204.

Bajada, C.J., Ralph, M.A.L., Cloutman, L.L., 2015. Transport for language south of the Sylvian fissure: the routes and history of the main tracts and stations in the ventral language network. *Cortex* 69, 141–151.

Baldoncini, M., Campero, A., Cruz, J.C.P., Recalde, R., Parraga, R., Gonzalez, F.J.S., López, P.G., 2019. Microsurgical anatomy and approaches to the cerebral central core. *World Neurosurg.* 129, e23–e34.

Brauer, J., Anwender, A., Friederici, A.D., 2011. Neuroanatomical prerequisites for language functions in the maturing brain. *Cereb. Cortex* 21 (2), 459–466.

Brauer, J., Anwender, A., Perani, D., Friederici, A.D., 2013. Dorsal and ventral pathways in language development. *Brain Lang.* 127 (2), 289–295.

Chenausky, K.V., Norton, A.C., Schlaug, G., 2017. Auditory-motor mapping training in a more verbal child with autism. *Front. Hum. Neurosci.* 11, 426.

Cloutman, L.L., Binney, R.J., Drakesmith, M., Parker, G.J., Ralph, M.A.L., 2012. The variation of function across the human insula mirrors its patterns of structural connectivity: evidence from in vivo probabilistic tractography. *Neuroimage* 59 (4), 3514–3521.

Cocquyt, E.-M., Lanckmans, E., van Mierlo, P., Duyck, W., Szmalec, A., Santens, P., De Letter, M., 2020. The white matter architecture underlying semantic processing: a systematic review. *Neuropsychologia* 136, 107182.

Cohen, J.D., Nichols, T., Brignone, L., Hall, S.S., Reiss, A.L., 2011. Insular volume reduction in fragile X syndrome. *Int. J. Dev. Neurosci.* 29 (4), 489–494. <https://doi.org/10.1016/j.ijdevneu.2011.01.003>.

Della Nave, R., Ginestroni, A., Tessa, C., Giannelli, M., Piacentini, S., Filippi, M., Mascalchi, M., 2010. Regional distribution and clinical correlates of white matter structural damage in Huntington disease: a tract-based spatial statistics study. *Am. J. Neuroradiol.* 31 (9), 1675–1681.

Douaud, G., Jbabdi, S., Behrens, T.E., Menke, R.A., Gass, A., Monsch, A.U., Matthews, P. M., 2011. DTI measures in crossing-fibre areas: increased diffusion anisotropy reveals early white matter alteration in MCI and mild Alzheimer's disease. *Neuroimage* 55 (3), 880–890.

Duffau, H., 2015. Stimulation mapping of white matter tracts to study brain functional connectivity. *Nat. Rev. Neurol.* 11 (5), 255–265.

Duffau, H., Gatignol, P., Moritz-Gasser, S., Mandonnet, E., 2009. Is the left uncinate fasciculus essential for language? *J. Neurol.* 256 (3), 382–389.

Duffau, H., Peggy Gatignol, S.T., Mandonnet, E., Capelle, L., Taillandier, L., 2008. Intraoperative subcortical stimulation mapping of language pathways in a consecutive series of 115 patients with Grade II glioma in the left dominant hemisphere. *J. Neurosurg.* 109 (3), 461–471. <https://doi.org/10.3171/jns.2008.109.9.0461>.

Efthymiopoulou, E., Kasselimis, D.S., Ghika, A., Kyrozi, A., Peppas, C., Evdokimidis, I., Potagas, C., 2017. The effect of cortical and subcortical lesions on spontaneous expression of memory-encoded and emotionally infused information: evidence for a role of the ventral stream. *Neuropsychologia* 101, 115–120.

Forkel, S.J., Catani, M., 2018. Lesion mapping in acute stroke aphasia and its implications for recovery. *Neuropsychologia* 115, 88–100.

Freedman, M., Alexander, M.P., Naeser, M.A., 1984. Anatomic basis of transcortical motor aphasia. *Neurology* 34 (4), 409, 409–409.

Frey, S., Campbell, J.S., Pike, G.B., Petrides, M., 2008. Dissociating the human language pathways with high angular resolution diffusion fiber tractography. *J. Neurosci.* 28 (45), 11435–11444.

Gil-Robles, S., Carvallo, A., Jimenez Mdel, M., Gomez Caicoya, A., Martinez, R., Ruiz-Ocaña, C., Duffau, H., 2013. Double dissociation between visual recognition and picture naming: a study of the visual language connectivity using tractography and brain stimulation. *Neurosurgery* 72 (4), 678–686. <https://doi.org/10.1227/NEU.0b013e318282a361>.

Griffiths, J.D., Marslen-Wilson, W.D., Stamatakis, E.A., Tyler, L.K., 2012. Functional organization of the neural language system: dorsal and ventral pathways are critical for syntax. *Cereb. Cortex* 23 (1), 139–147. <https://doi.org/10.1093/cercor/bhr386>.

Hahn, A., Kranz, G.S., Sladky, R., Kaufmann, U., Ganger, S., Hummer, A., Winkler, D., 2016. Testosterone affects language areas of the adult human brain. *Hum. Brain Mapp.* 37 (5), 1738–1748.

Von Der Heide, R.J., Skipper, L.M., Klobusicky, E., Olson, I.R., 2013. Dissecting the uncinate fasciculus: disorders, controversies and a hypothesis. *Brain* 136 (6), 1692–1707. <https://doi.org/10.1093/brain/awt094>.

Hickok, G., Poeppel, D., 2004. Dorsal and ventral streams: a framework for understanding aspects of the functional anatomy of language. *Cognition* 92 (1–2), 67–99.

Hirose, K., Miyata, J., Sugihara, G., Kubota, M., Sasamoto, A., Aso, T., Takahashi, H., 2014. Fiber tract associated with autistic traits in healthy adults. *J. Psychiatr. Res.* 59, 117–124.

Holland, R., Johns, S.L., Woollams, A.M., 2018. The impact of phonological versus semantic repetition training on generalisation in chronic stroke aphasia reflects differences in dorsal pathway connectivity. *Neuropsychol. Rehabil.* 28 (4), 548–567.

Jouen, A., Ellmore, T., Madden, C.J., Pallier, C., Dominey, P.F., Ventre-Dominey, J., 2015. Beyond the word and image: characteristics of a common meaning system for language and vision revealed by functional and structural imaging. *Neuroimage* 106, 72–85.

Kier, E.L., Staib, L.H., Davis, L.M., Bronen, R.A., 2004. MR imaging of the temporal stem: anatomic dissection tractography of the uncinate fasciculus, inferior occipitofrontal fasciculus, and Meyer's loop of the optic radiation. *Am. J. Neuroradiol.* 25 (5), 677–691.

Kikinis, Z., Makris, N., Finn, C.T., Bouix, S., Lucia, D., Coleman, M.J., Kubicki, M., 2013. Genetic contributions to changes of fiber tracts of ventral visual stream in 22q11.2 deletion syndrome. *Brain Imaging Behav.* 7 (3), 316–325. <https://doi.org/10.1007/s11682-013-9232-5>.

Klein, E., Moeller, K., Willmes, K.F., 2013. A neural disconnection hypothesis on impaired numerical processing. *Front. Hum. Neurosci.* 7, 663.

- Kubicki, M., Alvarado, J.L., Westin, C.-F., Tate, D.F., Markant, D., Terry, D.P., McCarley, R.W., 2011. Stochastic tractography study of Inferior Frontal Gyrus anatomical connectivity in schizophrenia. *Neuroimage* 55 (4), 1657–1664.
- Kümmerer, D., Hartwigsen, G., Kellmeyer, P., Glauche, V., Mader, I., Klöppel, S., Saur, D., 2013. Damage to ventral and dorsal language pathways in acute aphasia. *Brain* 136 (2), 619–629.
- Leclercq, D., Duffau, H., Delmaire, C., Capelle, L., Gatignol, P., Ducros, M., Lehericy, S., 2010. Comparison of diffusion tensor imaging tractography of language tracts and intraoperative subcortical stimulations. *J. Neurosurg.* 112 (3), 503–511. <https://doi.org/10.3171/2009.8.jns09558>.
- Loui, P., 2015. A dual-stream neuroanatomy of singing. *Music Percept. An Interdiscip. J.* 32 (3), 232–241.
- Makris, N., Meyer, J.W., Bates, J.F., Yeterian, E.H., Kennedy, D.N., Caviness Jr., V.S., 1999. MRI-based topographic parcellation of human cerebral white matter and nuclei: II. rationale and applications with systematics of cerebral connectivity. *Neuroimage* 9 (1), 18–45.
- Makris, N., Pandya, D.N., 2009a. The extreme capsule in humans and rethinking of the language circuitry. *Brain Struct. Funct.* 213 (3), 343–358. <https://doi.org/10.1007/s00429-008-0199-8>.
- Makris, N., Pandya, D.N., 2009b. The extreme capsule in humans and rethinking of the language circuitry. *Brain Struct. Funct.* 213 (3), 343–358.
- Makris, N., Preti, M.G., Asami, T., Pelavin, P., Campbell, B., Papadimitriou, G., Shenton, M.E., 2013. Human middle longitudinal fascicle: variations in patterns of anatomical connections. *Brain Struct. Funct.* 218 (4), 951–968.
- Mandonnet, E., Nouet, A., Gatignol, P., Capelle, L., Duffau, H., 2007. Does the left inferior longitudinal fasciculus play a role in language? a brain stimulation study. *Brain* 130 (3), 623–629. <https://doi.org/10.1093/brain/awl361>.
- Mangun, M., 2020. The Role of Ventral Fibre Pathway in Language Production in Health and Disease. *Nijmegen CNS* 15 (1).
- Marchina, S., Zhu, L.L., Norton, A., Zipse, L., Wan, C.Y., Schlaug, G., 2011. Impairment of speech production predicted by lesion load of the left arcuate fasciculus. *Stroke* 42 (8), 2251–2256.
- Martino, J., Brogna, C., Robles, S.G., Vergani, F., Duffau, H., 2010. Anatomic dissection of the inferior fronto-occipital fasciculus revisited in the lights of brain stimulation data. *Cortex* 46 (5), 691–699.
- Martino, J., Hamer, P.C.D.W., Berger, M.S., Lawton, M.T., Arnold, C.M., de Lucas, E.M., Duffau, H., 2013. Analysis of the subcomponents and cortical terminations of the perisylvian superior longitudinal fasciculus: a fiber dissection and DTI tractography study. *Brain Struct. Funct.* 218 (1), 105–121.
- Miller, K.L., Stagg, C.J., Douaud, G., Jbabdi, S., Smith, S.M., Behrens, T.E., Voets, N.L., 2011. Diffusion imaging of whole, post-mortem human brains on a clinical MRI scanner. *Neuroimage* 57 (1), 167–181.
- Mohades, S.G., Struys, E., Van Schuerbeek, P., Mondt, K., Van De Craen, P., Luypaert, R., 2012. DTI reveals structural differences in white matter tracts between bilingual and monolingual children. *Brain Res.* 1435, 72–80.
- Morino, M., Shimizu, H., Ohata, K., Tanaka, K., Hara, M., 2002. Anatomical analysis of different hemispherotomy procedures based on dissection of cadaveric brains. *J. Neurosurg.* 97 (2), 423–431.
- Nachtergaele, P., Radwan, A., Swinnen, S., Decramer, T., Uytterhoeven, M., Sunaert, S., Theys, T., 2019. The temporoinular projection system: an anatomical study. *J. Neurosurg.* 132 (2), 615–623.
- Nobre, A.C., Allison, T., McCarthy, G., 1994. Word recognition in the human inferior temporal lobe. *Nature* 372 (6503), 260–263.
- Noonan, M., Mars, R., Sallet, J., Dunbar, R., Fellows, L., 2018. The structural and functional brain networks that support human social networks. *Behav. Brain Res.* 355, 12–23.
- Northam, G.B., Liegeois, F., Tournier, J.-D., Croft, L.J., Johns, P.N., Chong, W.K., Baldeweg, T., 2012. Interhemispheric temporal lobe connectivity predicts language impairment in adolescents born preterm. *Brain* 135 (12), 3781–3798.
- O’Muircheartaigh, J., Dean, D.C., Dirks, H., Waskiewicz, N., Lehman, K., Jerskey, B.A., Deoni, S.C., 2013. Interactions between white matter asymmetry and language during neurodevelopment. *J. Neurosci.* 33 (41), 16170–16177.
- O’Rourke, T., de Diego Balaguer, R., 2020. Names and their meanings: a dual-process account of proper-name encoding and retrieval. *Neurosci. Biobehav. Rev.* 108, 308–321.
- Panesar, S.S., Yeh, F.-C., Jacquesson, T., Hula, W., Fernandez-Miranda, J.C., 2018. A quantitative tractography study into the connectivity, segmentation and laterality of the human inferior longitudinal fasciculus. *Front. Neuroanat.* 12, 47.
- Papagno, C., 2011. Naming and the role of the uncinate fasciculus in language function. *Curr. Neurol. Neurosci. Rep.* 11 (6), 553–559. <https://doi.org/10.1007/s11910-011-0219-6>.
- Papagno, C., Gallucci, M., Casarotti, A., Castellano, A., Falini, A., Fava, E., Caramazza, A., 2011. Connectivity constraints on cortical reorganization of neural circuits involved in object naming. *Neuroimage* 55 (3), 1306–1313.
- Perani, D., Saccuman, M.C., Scifo, P., Anwander, A., Spada, D., Baldoli, C., Friederici, A. D., 2011. Neural language networks at birth. *Proceedings of the National Academy of Sciences of the United States of America* (2011) 108, 38 16056–16061.
- Perlstein, M.D., Chohan, M.R., Coman, L.L., Antshel, K.M., Fremont, W.P., Gnrirke, M.H., Shenton, M.E., 2014. White matter abnormalities in 22q11. 2 deletion syndrome: preliminary associations with the Nogo-66 receptor gene and symptoms of psychosis. *Schizophr. Res.* 152 (1), 117–123.
- Petrides, M., Pandya, D.N., 1988. Association fiber pathways to the frontal cortex from the superior temporal region in the rhesus monkey. *J. Comp. Neurol.* 273 (1), 52–66. <https://doi.org/10.1002/cne.902730106>.
- Petrides, M., Pandya, D.N., 2009. Distinct parietal and temporal pathways to the homologues of Broca’s Area in the monkey. *PLOS Biol.* 7 (8), e1000170 <https://doi.org/10.1371/journal.pbio.1000170>.
- Radua, J., Via, E., Catani, M., Mataix-Cols, D., 2011. Voxel-based meta-analysis of regional white-matter volume differences in autism spectrum disorder versus healthy controls. *Psychol. Med.* 41 (7), 1539–1550.
- Rauschecker, J.P., 2018. Where did language come from? precursor mechanisms in nonhuman primates. *Curr. Opin. Behav. Sci.* 21, 195–204.
- Reyes, L., Sherwood, C., 2014. *Neurosci. Hum. Brain Evolut.* 11–37.
- Rijntjes, M., Weiller, C., Bormann, T., Musso, M., 2012. The dual loop model: its relation to language and other modalities. *Front. Evolut. Neurosci.* 4, 9.
- Rilling, J., Glasser, M., Jbabdi, S., Andersson, J., Preuss, T., 2012. Continuity, divergence, and the evolution of brain language pathways. *Front. Evolut. Neurosci.* 3 (11) <https://doi.org/10.3389/fnevo.2011.00011>.
- Sarubbo, S., De Benedictis, A., Maldonado, I.L., Basso, G., Duffau, H., 2013. Frontal terminations for the inferior fronto-occipital fascicle: anatomical dissection, DTI study and functional considerations on a multi-component bundle. *Brain Struct. Funct.* 218 (1), 21–37.
- Saur, D., Schelter, B., Schnell, S., Kratochvil, D., Küpper, H., Kellmeyer, P., Lange, R., 2010. Combining functional and anatomical connectivity reveals brain networks for auditory language comprehension. *Neuroimage* 49 (4), 3187–3197.
- Schmahmann, J.D., Smith, E.E., Eichler, F.S., Filley, C.M., 2008. Cerebral white matter: neuroanatomy, clinical neurology, and neurobehavioral correlates. *Ann. N. Y. Acad. Sci.* 1142, 266–309. <https://doi.org/10.1196/annals.1444.017>.
- Stefanatos, G.A., Baron, I.S., 2011. The ontogenesis of language impairment in autism: a neuropsychological perspective. *Neuropsychol. Rev.* 21 (3), 252–270.
- Suchan, J., Umarova, R., Schnell, S., Himmelfach, M., Weiller, C., Karnath, H.O., Saur, D., 2014. Fiber pathways connecting cortical areas relevant for spatial orienting and exploration. *Hum. Brain Mapp.* 35 (3), 1031–1043.
- Surbeck, W., Hänggi, J., Scholtes, F., Viher, P.V., Schmidt, A., Stegmayer, K., Strik, W., 2020. Anatomical integrity within the inferior fronto-occipital fasciculus and semantic processing deficits in schizophrenia spectrum disorders. *Schizophr. Res.* 218, 267–275.
- Tangmose, K., Nielsen, M., Sigvard, A., Jessen, K., Bojesen, K., Bjerregaard, M., Glenthøj, B.Y., 2017. Reward alterations in antipsychotic naïve first episode psychosis before and after treatment with a partial dopamine agonist. *Eur. Neuropsychopharmacol.* 27, S977–S978. [https://doi.org/10.1016/S0924-977X\(17\)31721-2](https://doi.org/10.1016/S0924-977X(17)31721-2).
- Taylor, A.N., Kambeitz-Ilanovic, L., Gesierich, B., Simon-Vermot, L., Franzmeier, N., Caballero, M.A.A., Bürger, K., 2017. Tract-specific white matter hyperintensities disrupt neural network function in Alzheimer’s disease. *Alzheimer’s Dement.* 13 (3), 225–235.
- Tylee, D.S., Kikinis, Z., Quinn, T.P., Antshel, K.M., Fremont, W., Tahir, M.A., Makris, N., 2017. Machine-learning classification of 22q11.2 deletion syndrome: a diffusion tensor imaging study. *Neuroimage Clin.* 15, 832–842. <https://doi.org/10.1016/j.nicl.2017.04.029>.
- Ueno, T., Lambon Ralph, M.A., 2013. The roles of the “ventral” semantic and “dorsal” pathways in conduite d’approche: a neuroanatomically-constrained computational modeling investigation. *Front. Hum. Neurosci.* 7, 422.
- Ueno, T., Saito, S., Rogers, T.T., Ralph, M.A.L., 2011. Lichtheim 2: synthesizing aphasia and the neural basis of language in a neurocomputational model of the dual dorsal-ventral language pathways. *Neuron* 72 (2), 385–396.
- Umarova, R.M., Saur, D., Schnell, S., Kaller, C.P., Vry, M.-S., Glauche, V., Weiller, C., 2010. Structural connectivity for visuospatial attention: significance of ventral pathways. *Cereb. Cortex* 20 (1), 121–129.
- Vanderauwe, J., Wouters, J., Vandermosten, M., Ghesquière, P., 2017. Early dynamics of white matter deficits in children developing dyslexia. *Dev. Cogn. Neurosci.* 27, 69–77.
- Venkataramanian, G., Jayakumar, P., Gangadhar, B., Keshavan, M., 2008. Automated MRI parcellation study of regional volume and thickness of prefrontal cortex (PFC) in antipsychotic-naïve schizophrenia. *Acta Psychiatr. Scand.* 117 (6), 420–431.
- Verly, M., Gerrits, R., Sleurs, C., Lagae, L., Sunaert, S., Zink, I., Rommel, N., 2019. The mis-wired language network in children with developmental language disorder: insights from DTI tractography. *Brain Imaging Behav.* 13 (4), 973–984.
- Visser, M., Jefferies, E., Embleton, K.V., Lambon Ralph, M.A., 2012. Both the middle temporal gyrus and the ventral anterior temporal area are crucial for multimodal semantic processing: distortion-corrected fMRI evidence for a double gradient of information convergence in the temporal lobes. *J. Cogn. Neurosci.* 24 (8), 1766–1778.
- Walton, M., Dewey, D., Lebel, C., 2018. Brain white matter structure and language ability in preschool-aged children. *Brain Lang.* 176, 19–25.
- Wan, C.Y., Schlaug, G., 2010. Neural pathways for language in autism: the potential for music-based treatments. *Future Neurol.* 5 (6), 797–805.
- Weiller, C., Bormann, T., Saur, D., Musso, M., Rijntjes, M., 2011. How the ventral pathway got lost - and what its recovery might mean. *Brain Lang.* 118, 29–39. <https://doi.org/10.1016/j.bandl.2011.01.005>.
- Wilson, S.M., Galantucci, S., Tartaglia, M.C., Rising, K., Patterson, D.K., Henry, M.L., Gorno-Tempini, M.L., 2011. Syntactic processing depends on dorsal language tracts. *Neuron* 72 (2), 397–403.
- De Witt Hamer, P.C., Moritz-Gasser, S., Gatignol, P., Duffau, H., 2011. Is the human left middle longitudinal fascicle essential for language? a brain electrostimulation study. *Hum. Brain Mapp.* 32 (6), 962–973.
- Wysiadecki, G., Clarke, E., Polguj, M., Haładaj, R., Żytkowski, A., Topol, M., 2019. Klingler’s method of brain dissection: review of the technique including its usefulness in practical neuroanatomy teaching, neurosurgery and neuroimaging. *Folia Morphol.* 78 (3), 455–466.



- Yagmurlu, K., Middlebrooks, E.H., Tanriover, N., Rhoton, A.L., 2016. Fiber tracts of the dorsal language stream in the human brain. *J. Neurosurg.* 124 (5), 1396–1405.
- Zhang, X., Sun, Y., Li, W., Liu, B., Wu, W., Zhao, H., Yu, T., 2019. Characterization of white matter changes along fibers by automated fiber quantification in the early stages of Alzheimer's disease. *NeuroImage Clin.* 22, 101723.
- Zhang, J., Wei, X., Xie, S., Zhou, Z., Shang, D., Ji, R., Ye, X., 2018. Multifunctional roles of the ventral stream in language models: advanced segmental quantification in post-stroke aphasic patients. *Front. Neurol.* 9, 89.