



## Case Report

# III cranial nerve cavernous malformation: A case report and review of the literature

Giuseppe Di Perna<sup>1</sup>, Fabio Cofano<sup>1</sup>, Roberto Altieri<sup>1</sup>, Bianca Maria Baldassarre<sup>1</sup>, Luca Bertero<sup>2</sup>, Francesco Zenga<sup>1</sup>, Diego Garbossa<sup>1</sup>

<sup>1</sup>Department of Neurosurgery, Città della Salute e della Scienza di Torino, <sup>2</sup>Department of Pathology, University of Turin, Turin, Italy.

E-mail: \*Giuseppe Di Perna - dr.giuseppediperna@gmail.com; Fabio Cofano - fabio.cofano@gmail.com; Roberto Altieri - roberto.altieri.87@gmail.com; Bianca Maria Baldassarre - baldassarrebianca@gmail.com; Luca Bertero - luca.bertero@unito.it; Francesco Zenga - zengafra@hotmail.com; Diego Garbossa - dgarbossa@gmail.com



### \*Corresponding author:

Giuseppe Di Perna,  
Department of Neurosurgery,  
Città della Salute e della Scienza  
di Torino, Turin, Italy.

dr.giuseppediperna@gmail.com

Received : 16 September 2020

Accepted : 21 November 2020

Published : 22 December 2020

### DOI

10.25259/SNI\_650\_2020

### Quick Response Code:



## ABSTRACT

**Background:** Cavernous malformations generally occur in brain parenchyma but rarely these lesions arise from cranial nerves (CNs).

**Case Description:** This paper described a case of a woman presented with III CN dysfunction due to the presence of a right III CN cavernoma. Surgical treatment with nerve sparing gross total resection was performed. A 3-month follow-up was documented.

**Conclusion:** Only few cases of CNs cavernomas have been described in the literature. These lesions have been described to show a more aggressive behavior compared to intraparenchymal cavernomas, especially in symptomatic patients. Differential diagnosis and surgical treatment could be challenging, especially trying to preserve nerve integrity and function.

**Keywords:** Cavernoma, Cranial nerve, Gross total resection, Nerve sparing, Third nerve palsy

## INTRODUCTION

Cavernous malformations (CMs) are vascular lesions formed by abnormally large collections of vascular channels which are typically characterized by a low flow – then hidden at angiography – and absence of interposed neural tissue.<sup>[8]</sup> Because of their thin-walled capillary structure, CMs usually tend to cause repeated bleeding. Most of them occur in the subcortical brain parenchyma and typically cause headache, seizures, or neurological deficits.

Rarely, these lesions can arise from cranial nerves (CNs) and their incidental detection raises problems due to differential diagnosis (DD) and treatment, since there is a lack of data in literature, especially about asymptomatic patients.<sup>[11]</sup> In this report, a case of a woman with III CN CM is presented and discussed, together with a review of existing evidence in the English literature.

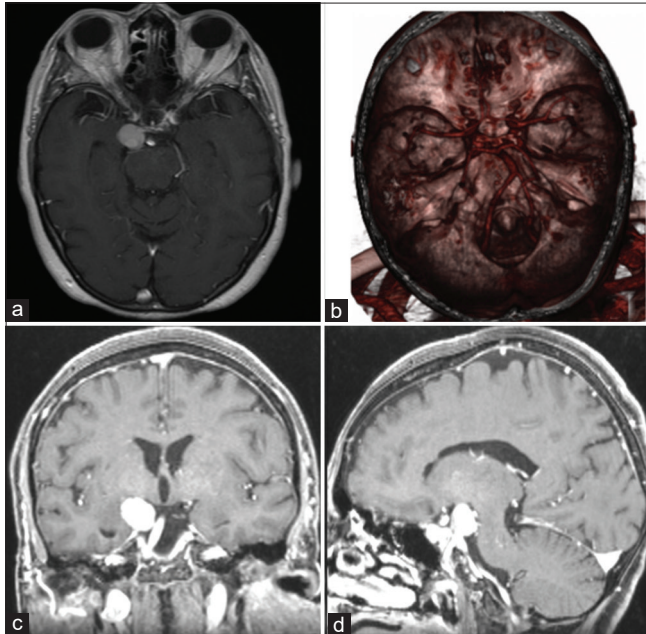
## CASE REPORT

A 67-year-old woman was referred to our institution for incomplete right III CN palsy. Gadolinium magnetic resonance imaging (MRI) showed an enhanced lesion on the right

This is an open-access article distributed under the terms of the Creative Commons Attribution-Non Commercial-Share Alike 4.0 License, which allows others to remix, tweak, and build upon the work non-commercially, as long as the author is credited and the new creations are licensed under the identical terms.

©2020 Published by Scientific Scholar on behalf of Surgical Neurology International

posterior clinoid process region with extension to the interpeduncular and crural cisterns and mass effect on the III CN. T1- and T2-weighted images were characterized by a mixed intensity while the enhancement after gadolinium administration was homogeneous [Figure 1]. An angio-computed tomography (CT) scan excluded an aneurysmatic

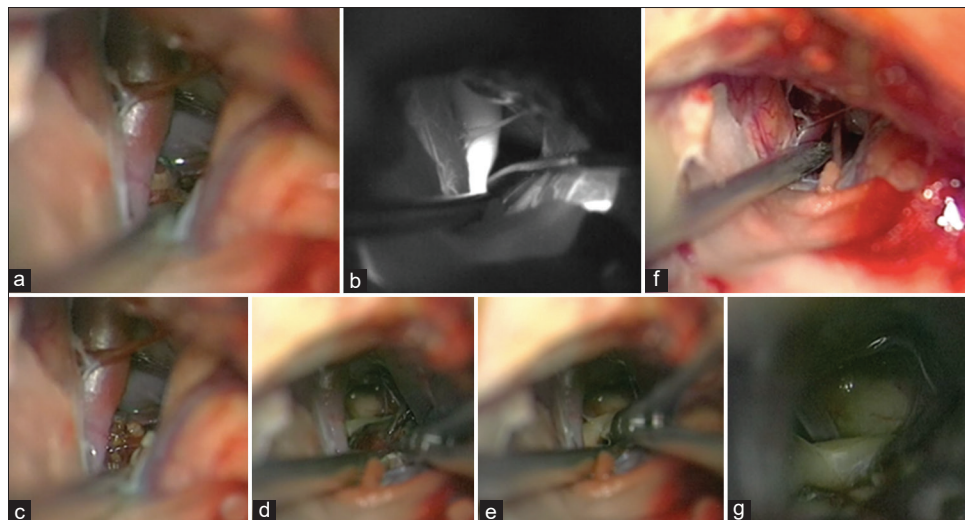


**Figure 1:** (a, b and d) T1 magnetic resonance imaging sequences showing a lesion with contrast enhancement in the crural cistern near the right posterior clinoid process. (c) Angio-computed tomography excluded connections of the lesion with the Willis circle.

origin of the lesion [Figure 1]. No clear dural implant was detected. The hypothesis of CM was considered, also because of the sudden onset of nerve palsy, although in the T2 gradient echo imaging (GRE) sequences, no clear signs of previous bleedings were observed.

Considering symptoms, characteristics, and location, and after thorough discussion with the patient, a surgical exploration was performed. Surgical strategy was characterized by a right pterional approach. Extradural clinoidectomy – using the high-speed drill – was performed, considering the unknown nature of the lesion. Therefore, a wide proximal control of the right internal carotid artery and also a good control of the cavernous sinus were achieved. After dural opening, Sylvian fissure was split in a distal to proximal fashion. After having reached optic-carotid cistern and followed the posterior communicating artery (PCoA), a brown and blackberry-like lesion was found, strictly adherent to the III CN [Figure 2]. The intraoperative fluorangiography confirmed the absence of relationships between the lesion and Willis circle [Figure 2]. The lesion was located superiorly and posteriorly to the roof of the cavernous sinus, namely, in the crural cistern and it followed the third nerve along its course, until it entered the lateral wall of the cavernous sinus. However, the lesion did not have dural attachments and the dissection of its anterior component was easier than the posterior one that was strictly related to the third CN [Figure 2]. Laterally, the lesion was partially covered by the tentorium edge, while the arachnoid plane protecting the IV CN was preserved.

Then, a careful removal of the lesion with anatomical preservation of the III CN was performed [Figure 2]. In the



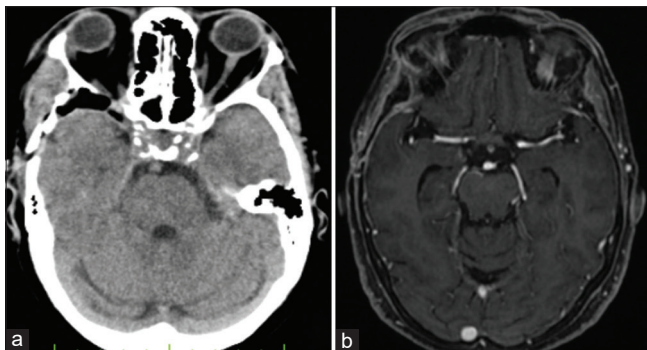
**Figure 2:** Intraoperative images (a-g). (a) A right pterional approach was performed and optic-carotid cistern was opened to identify the right internal carotid artery (ICA). Then, (b) intraoperative green video angiography confirmed that the lesion did not arise from the Willis circle. (c) A blackberry-like lesion was observed behind the medial wall of the right ICA, and, after a sharp dissection of the surrounding arachnoid membranes, (d) the strict relationship of the lesion with the right III cranial nerve was observed. (e) Thus, dissection from the nerve was performed and then the lesion was removed. (f and g) At the end of the procedure, the III cranial nerve was spared.

immediate postoperative period, the right III CN palsy was still present and only minimal improvement was noticed at discharge. Histological diagnosis confirmed the suspicion of III CN CM [Figure 3]. The 3-month MRI did not show recurrence while the last clinical examination, obtained after 12 months from surgery, did not found CN worsening and the patient still presented a Grade 2 right palpebral ptosis, with diplopia due to the ophthalmoplegia [Figure 4].

## DISCUSSION

CMs are considered to be vascular malformations with a prevalence of 0.4–0.9% within the general population and a trend of growth because of their recurrent internal hemorrhages.<sup>[14]</sup> They represent 10–20% of all central nervous system (CNS) vascular malformations considering cerebral and spinal locations<sup>[2,14,15]</sup> and consist of aberrant, immature, thrombosed, low-flow vessels surrounded by a gliotic plan attached to the adjacent nervous tissue (without neural tissue inside the nodule, unlike arteriovenous malformations). Different locations could be registered inside the CNS (80% supratentorial, especially subcortical in the frontal, temporal lobes); both sporadic (75%) and multiple/familial forms (10–30%) are recognized.<sup>[4]</sup> CMs rarely involve CNs or optic pathways (1%).<sup>[14]</sup> The annual rate of bleeding increases from 0.25% to 20%, with a rebleeding rate of 3.8–22.9%.<sup>[14]</sup> In addition to extralesional hemorrhage in the subarachnoid space, clinical symptoms are caused also by intralesional bleeding resulting in a volumetric growth of the CM and mass effect on surrounding structures.<sup>[11]</sup> Even if there is a lack of clear evidence, it is believed that bleeding of CMs involving the optochiasmatic complex (OCMs) induces symptoms more frequently than CMs located elsewhere. For this reason, symptomatic OCMs are considered to deserve a careful neurosurgical attention.<sup>[4,10]</sup>

There are only few cases of CN CMs described in the recent literature.<sup>[4,9,14]</sup> While seizures are the most common presentation of intracerebral CMs, the symptoms of CN CMs



**Figure 3:** (a) Postoperative computed tomography scan showing gross total resection (GTR). (b) Three-month follow-up postoperative magnetic resonance imaging showing GTR with no signs of recurrence.

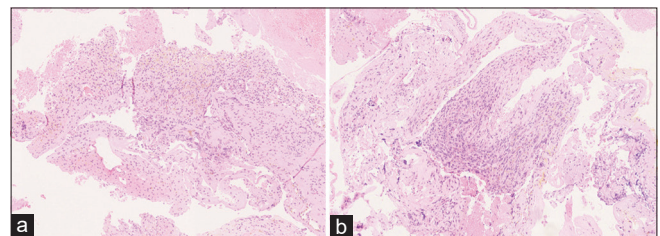
could be different and various.<sup>[8,16]</sup> For example, diplopia, ptosis, and visual disturbances for III CN CMs are described, while hearing loss and vertigo are reported for VII and VIII CNs CMs. The spectrum of signs and symptoms for OCMs could be various, with the most common presentation of acute chiasmatic compression syndrome defined by sudden retro-orbital headache, acute hypovision, and hemianopia (chiasmatic apoplexy).<sup>[8]</sup>

One of the most interesting aspects of this lesion is the fact that radiological images are not always pathognomonic. It makes challenging their DD before surgery, especially when there are no signs of bleeding, since the most frequent lesions along CNs course are schwannomas.<sup>[14]</sup> In this case report, aneurysm was taken in count for DD due to the mass location near the PCoA and its contrast enhancement, but angio-CT excluded connection with Willis circle. Meningioma of the posterior clinoid process was also considered, but no dural tail was visible. As known indeed, T2-weighted GRE is considered to be the gold standard MRI sequence since the typical aspect of these lesions is due to bleeding and characterized as areas of mixed signal intensity, with a central core and peripheral rims of decreased signal intensity (popcorn or target appearances).<sup>[3,13]</sup> Unfortunately, like the case reported in this paper, this is not always true if no bleedings occurred or could be noticed.

Since subtotal resection (STR) can lead to the recurrence of the malformation, gross total resection (GTR) is strongly recommended when possible.<sup>[4]</sup>

The possibility of removing CNs CMs sparing the nerve is debatable and depends on different factors such as clinical presentation, previous bleeding, degree of adhesion to the nerves, and probably the origin of the lesion.<sup>[15]</sup> CN CMs are considered to have a more aggressive behavior with tendency to progression with neurological dysfunction, especially in symptomatic patients at the diagnosis.<sup>[14,15]</sup>

Rotondo *et al.* described 90 cases of CNs CMs from 1979 to 2013. A total number of eight cases of III CN CMs were reported [Table 1], and authors described neurological



**Figure 4:** Medium power (a and b, ×100) HE images showing a vascular lesion comprising dilated vessels with thin walls. Marked signs of recent and past bleeding are present, including widespread hemosiderin globules. These findings were deemed to be consistent with a cavernous hemangioma.

**Table 1:** III cranial nerve cavernomas cases described in the recent literature.

References	Location	Clinical presentation	Treatment	Nerve sparing
Scott (1983)	Right CN III	Diplopia	GTR + nerve transection	No
Yamada <i>et al.</i> (1986)	Left CN III	Diplopia	GTR + nerve transection	No
Matias Guius <i>et al.</i> (1990)	Left CN III	Galactorrhea, amenorrhea, head ache, left temporal quadrantopsia	STR	Yes
Ogilvy <i>et al.</i> (1993)	Right CN III	Diplopia, ptosis	GTR + nerve transection	No
Itshayek <i>et al.</i> (2007)	Right CN III	Neurological facial pain	Explorative surgery	Yes
Wolfe <i>et al.</i> (2011)	Left CN III	Diplopia, ptosis	GTR	Yes
Manjila <i>et al.</i> (2011)	Right CN III	Diplopia, ptosis	GTR	Yes
Rotondo <i>et al.</i> (2013)	Right CN III	Diplopia, ptosis	GTR	Yes

improvement at 12 months follow-up in those cases (the majority) where a nerve sparing GTR was achieved.<sup>[14]</sup> As previously stated by Deshmukh *et al.*, there is evidence that these lesions can be safely resected, with the preservation of CN function.<sup>[4,11]</sup> Maiodna *et al.* have recently reported that surgical treatment of cavernomas involving CNs should not be performed in sharp fibers dissection of the nerve and reanastomosis technique, which can result in incomplete resection and recurrence.<sup>[9]</sup> Sami *et al.* described two different groups of CNs CMs: those arising from the vessels near the nerve and those that grow from vessels inside the CN.<sup>[15]</sup> Probably, the possibility to achieve a nerve sparing GTR depends on the origin of the malformation, resulting to be safer in the first group than in the second group (where dissection should be done inside the nerve).

In 2007, Itshayek *et al.* described a case of a young woman presenting with facial pain controlled by pharmacological therapy. The MRI showed the presence of a CMs in the clinoid region. During the procedure, senior surgeon decided not to proceed with the resection since no relationships with the branches of the V nerve were found, while the proximity to the III nerve was considered risky for new postoperative deficits.<sup>[7]</sup> Gerganov and Samii commented this case suggesting that functional preservation should be the main target in the treatment of benign lesion if the risk of neurological deterioration due to their natural history is less than the risk of morbidity related to surgery.<sup>[7]</sup>

In our case report, the lesion was easily detachable so a GTR with nerve sparing was achieved and also a clinical stability was registered at follow-up.

Another aspect could be the choice of surgical approach. In this case, an extradural anterior clinoidectomy was performed to gain good control to the cavernous sinus and proximal control of the carotid artery in case of intraoperative complications. Another option that could have been taken into account would have been a trans-Sylvian approach to the interpeduncular cistern. The possibility to obtain a wider access to the basal cisterns and to the median aspect of temporal lobe has been described in different studies.

Nevertheless, also the risk of middle cerebral artery injury or vasospasm has been reported.<sup>[1,12]</sup>

To summarize, all symptomatic lesions should be treated.<sup>[14]</sup> Surgical excision is the standard practice and could sometimes be needed as an emergency procedure when the bleeding involves the optochiasmatic complex and requiring urgent operations to preserve visual function.<sup>[4]</sup>

The role of stereotactic radiosurgery, both as an alternative and as an additional option, appears to be problematic in the management of CN CMs.<sup>[6,14]</sup> Cases of lesion enlargement for recurrent hemorrhages have been also described after radiotherapy, and surgical operations were needed.<sup>[6]</sup> Another aspect of uncertainties for the use of radiosurgical treatment is that the risk of rebleeding from CN CMs that are treated by radiosurgery might be significantly higher, due to the sensitivity of the tissue involved, and this would lead to a high morbidity rate.<sup>[4,11]</sup>

A further consideration consists in the use of intraoperative neuromonitoring (IONM) to guarantee better control of CN function during surgery. Hariharan *et al.*<sup>[5]</sup> recently underlined the benefits of using intraoperative spontaneous electromyographic recordings and compound muscle action potentials evoked by electrical stimulation in preventing postoperative neurologic deficits. In the described case, IONM was not used because of the unknown origin of the lesion, being also the aneurysmatic nature hypothesis the major concern of the authors. Hence, this surely could be considered a limitation of this report.

## CONCLUSION

CN CMs are rare lesions, and DD could be challenging. Microsurgical excision could be considered as safe and effective to prevent new deficits or in symptomatic patients with high risk of rebleeding. STR could lead to recurrences, a GTR with preservation of nerve integrity should be the target of the treatment.

**Declaration of patient consent**

Patient's consent not required as patients identity is not disclosed or compromised.

**Financial support and sponsorship**

Nil.

**Conflicts of interest**

There are no conflicts of interest.

**REFERENCES**

1. Campero A, Ajler P, Garategui L, Goldschmidt E, Martins C, Rhoton A. Pterional transsylvian-transinsular approach in three cavernomas of the left anterior mesiotemporal region. *Clin Neurol Neurosurg* 2015;130:14-9.
2. Cofano F, Marengo N, Pecoraro F, Penner F, Bertero L, Zenga F. Spinal epidural capillary hemangioma: Case report and review of the literature. *Br J Neurosurg* 2019;1-4. Doi: 10.1080/02688697.2018.1562034.
3. de Champfleury NM, Langlois C, Ankenbrandt WJ, le Bars E, Leroy MA, Duffau H, *et al.* Magnetic resonance imaging evaluation of cerebral cavernous malformations with susceptibility-weighted imaging. *Neurosurgery* 2011;68:641-7; discussion 647-8.
4. Deshmukh VR, Albuquerque FC, Zabramski JM, Spetzler RF, Steinberg GK, Bricolo A, *et al.* Surgical management of cavernous malformations involving the cranial nerves. *Neurosurgery* 2003;53:352-7; discussion 357.
5. Hariharan P, Balzer JR, Anetakis K, Crammond DJ, Thirumala PD. Electrophysiology of extraocular cranial nerves: Oculomotor, trochlear, and abducens nerve. *J Clin Neurophysiol* 2018;35:11-5.
6. Huang YC, Tseng CK, Chang CN, Wei KC, Liao CC, Hsu PW. LINAC radiosurgery for intracranial cavernous malformation: 10-year experience. *Clin Neurol Neurosurg* 2006;108:750-6.
7. Itshayek E, Perez-Sanchez X, Cohen JE, Umansky F, Spektor S. Cavernous hemangioma of the third cranial nerve: Case report. *Neurosurgery* 2007;61:E653; discussion E653.
8. Iwai Y, Yamanaka K, Nakajima H, Miyaura T. Cavernous angioma of the optic chiasm: Case report. *Neurol Med Chir (Tokyo)* 1999;39:617-20.
9. Maiodna E, Ahmad FU, Morcos JJ. Cavernous malformation of the seventh cranial nerve: Case report and review of literature. *World Neurosurg* 2016;91:676.e13-21.
10. Matias-Guiu X, Alejo M, Sole T, Ferrer I, Noboa R, Bartumeus F. Cavernous angiomas of the cranial nerves. Report of two cases. *J Neurosurg* 1990;73:620-2.
11. Ozer E, Kalemci O, Yucesoy K, Canda S. Optochiasmatic cavernous angioma: Unexpected diagnosis. Case report. *Neurol Med Chir (Tokyo)* 2007;47:128-31.
12. Potts MB, Chang EF, Young WL, Lawton MT. Transsylvian-transinsular approaches to the insula and basal ganglia: Operative techniques and results with vascular lesions. *Neurosurgery* 2012;70:824-34; discussion 834.
13. Robinson RJ, Bhuta S. Susceptibility-weighted imaging of the brain: Current utility and potential applications. *J Neuroimaging* 2011;21:e189-204.
14. Rotondo M, Natale M, D'Avanzo R, Pascale M, Scuotto A. Cavernous malformations isolated from cranial nerves: Unexpected diagnosis? *Clin Neurol Neurosurg* 2014;126:162-8.
15. Samii M, Nakamura M, Mirzai S, Vorkapic P, Cervio A. Cavernous angiomas within the internal auditory canal. *J Neurosurg* 2006;105:581-7.
16. Sürücü O, Sure U, Mittelbronn M, Meyermann R, Becker R. Cavernoma of the trochlear nerve. *Clin Neurol Neurosurg* 2007;109:791-3.

**How to cite this article:** Di Perna G, Cofano F, Altieri R, Baldassarre BM, Bertero L, Zenga F, *et al.* III cranial nerve cavernous malformation: A case report and review of the literature. *Surg Neurol Int* 2020;11:452.