

Case report

Fever and dyspnoea in a tracheostomised patient

A 65-year-old man was referred for evaluation of acute onset of fever, productive cough and dyspnoea. He had previously received a diagnosis of laryngeal carcinoma, which had been treated with laryngectomy and bilateral laterocervical lymphadenectomy, followed by chemotherapy. He underwent plastic surgery of the laryngocutaneous fistula, and a positron emission tomography (PET)-computed tomography (CT) examination performed during follow-up showed 18-FDG (2-fluoro-2-deoxy-D-glucose) lung uptake in the apical right portion. He had a smoking history and his regular medications included dexamethasone, metoclopramide, omeprazole, furosemide, cholecalciferol and pregabalin. He had a history of chronic kidney failure and thyroid goitre, no family history of pulmonary disease or malignancy, nor of drug allergies.

Physical examination findings

The patient's physical examination findings were as follows: respiratory rate 28 breaths·min⁻¹; heart rate 71 beats·min⁻¹; blood pressure 130/80 mmHg; peripheral capillary oxygen saturation by pulse oximeter on ambient air 94%; body temperature 38°C. He was eupnoeic at rest. Physical examination revealed bilateral widespread wheezing and

rhonchi in the lower lobes. The cardiopulmonary evaluation produced unremarkable results. Palpable lymphadenopathy was noted in the right laterocervical region. Peripheral bilateral oedema was also present.

Diagnostic studies

A complete blood count with differential and chemistry panel showed normal results. The blood gas analysis revealed the following findings: pH 7.50, carbon dioxide tension 29.4 mmHg, oxygen tension 62.5 mmHg, bicarbonate 22.4 mmol·L⁻¹, arterial oxygen saturation 94% on ambient air.

A non-contrast CT-scan showed confluent areas of parenchymal consolidation associated with bilateral ground-glass opacities (figure 1). Bronchoscopy with bronchoalveolar lavage (BAL) revealed the presence of *Klebsiella pneumoniae* and *Pseudomonas aeruginosa*; staining for acid-fast bacteria produced negative results. Cytology showed alveolar macrophages and granulocytes without malignant cells. Laboratory tests (blood cultures, urinalysis, Legionella urinary antigen, serological IgM and IgG for cytomegalovirus, Epstein-Barr virus, herpes simplex virus 1-2, *Mycoplasma*, *Chlamydia*) were all negative.

Cite as: Arena C, Scaduto F, Principe S, *et al.* Fever and dyspnoea in a tracheostomised patient. *Breathe* 2020; 16: 200115.



CrossMark

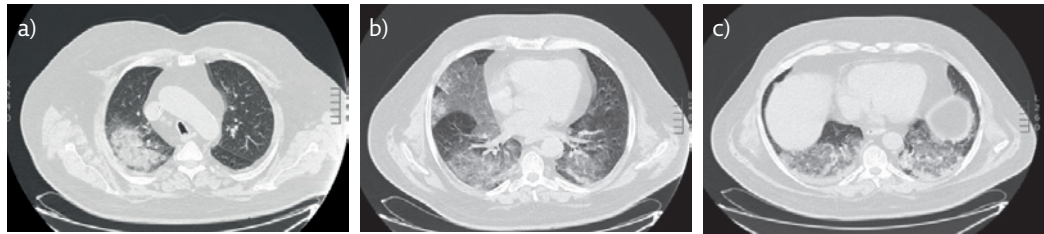


Figure 1 a-c) CT scan of the chest demonstrating multiple confluent areas of parenchymal consolidation associated with ground-glass opacities in both lower lobes, medium lobe and in the posterior segment of the right upper lobe.

Task 1

What is the most likely diagnosis based on the imaging shown in figure 1?

- a) Pulmonary infection
- b) Metastasis of nonpulmonary lung cancer
- c) Acute distress respiratory syndrome
- d) Pulmonary eodema
- e) All the above

Answer 1

a.

The infiltrates seen on the CT are consistent both with a pattern of interstitial lung disease and an endoalveolar refill. Based on the BAL findings, the hypothesis of respiratory infection was the most probable. Therefore, antibiotic treatment with meropenem and linezolid *i.v.* was started. Despite this, the patient remained febrile (body temperature of 39°C) and the cough persisted unchanged. As a consequence, the current regimen was stopped and caspofungin, ceftazidime and ciprofloxacin were added. After 5 days of treatment, the microbiological sputum culture turned negative. However, the clinical conditions remained unchanged, thus ruling out the previous hypothesis of infectious aetiology.

Task 2

Which procedure should be performed?

- a) Transbronchial biopsy
- b) Surgical lung biopsy
- c) Magnetic resonance imaging
- d) Echocardiogram
- e) None of the above

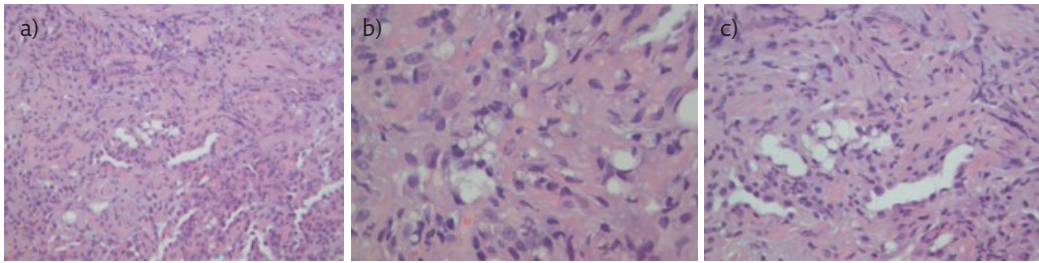


Figure 2 Stained sections obtained from a formalin-fixed paraffin-embedded specimen of transbronchial biopsy treated with haematoxylin-eosin. a) Specimen showing the presence of interstitial fibrosis and mild inflammation with few lymphocytes, alveolar lining cell hyperplasia and some lipid-laden foamy macrophages. Original magnification 200x. b) Specimen showing the presence of some lipid-laden foamy macrophages. Original magnification 600x. c) Specimen showing the presence of interstitial fibrosis and mild inflammation with few lymphocytes, alveolar lining cell hyperplasia and some lipid-laden foamy macrophages. Original magnification 400x.

Answer 2

a.

On the basis of the clinical history and the course of the disease, the occurrence of lung metastasis related to the progression of the primary neoplasia was suspected. Surgical biopsy was excluded because of the invasive nature of the procedure. Bronchoscopy with ultrasound transbronchial biopsy appeared to be the most suitable procedure and was performed. The macroscopic appearance of tracheal aspirate revealed a whitish and turbid fluid. The differential cell count of the BAL revealed alveolar macrophages, granulocytes and epithelial cells, and no evidence of malignant cells. The histological examination is shown in figure 2.

Task 3

Which diagnosis would you suggest?

- a) Diffuse alveolar damage
- b) Pulmonary adenomas
- c) Interstitial lung disease
- d) Lipoid pneumonia
- e) Tuberculosis
- f) Alveolar proteinosis

Answer 3

d.

The histological picture was suggestive of lipoid pneumonia (LP), mainly based on the detection of foamy alveolar macrophages due to the intracellular accumulation of lipid vacuoles. By carefully reviewing the exposure history, we found that the patient had regularly applied oil-based products through the tracheostomy to moisturise the cannula. The patient stopped his use of lubricant oil and oral corticosteroid therapy was initiated at the dose of $0.5 \text{ mg} \cdot \text{kg}^{-1}$ and gradually tapered off. This led to a marked improvement in respiratory symptoms, and the patient was discharged after 20 days. He was instructed to refrain from using oil-based substances, and at the follow-up visit 1 month after discharge his cough and dyspnoea had dramatically decreased.

Exogenous LP is an inflammatory parenchymal condition in response to inhalation or aspiration of oil-based substances [1–5]. LP may occur in subjects that use substances to treat rhinopharyngeal dryness, tracheostomised patients who use endotracheal tube lubrication oils, and patients with chronic use of nasal sprays and decongestants containing mineral oils, mainly children and the elderly [6, 7]. The degree of tissue damage and the consequent severity of this clinical situation are variable and depends on the amount, the frequency and the duration of inhalation and the chemical properties of the oil itself. In the setting of chronic, low-grade aspiration patients may present with no symptoms and incidentally noted abnormal imaging findings. Patients may also present with chronic cough or progressively worsening dyspnoea. Rarely, LP is characterised by an acute onset because of inhalation of large amount of oil substances, which can also be fatal. The CT scan is mandatory for the diagnosis, showing negative adipose density (between -150 and -30 HU) within the parenchymal consolidations, with a predilection

for the lower lobes: the differential includes other fat-containing benign and malignant lesions. In some cases, the radiological findings consist of ground-glass, crazy-paving type areas with or without associated parenchymal consolidation of normal density [8, 9]. Bronchiectasis and fibrosis may characterise the advanced stages, as the result of unrecognised cases. PET-CT can lead to misleading signs because of the occurrence of pathological uptake secondary to the inflammatory component of LP. The diagnosis is confirmed by the BAL and cytological examination which show a differential cell count consisting mainly of alveolar macrophages with large intracytoplasmic vacuoles full of fat material. The histological examination of a transbronchial biopsy may be diagnostic, as in the current case, revealing inflammatory cells and foamy macrophages containing fat material. Diagnosis is sometimes only formulated *post-mortem*, when an autopsy is performed and lipid material is discovered in the alveoli.

When the diagnosis is posed, the elective treatment must obviously involve the discontinuation of the aetiological factor, supplemental oxygen, broad spectrum antibiotic and corticosteroid therapy. There is no specific treatment for this condition, and all of the above answers may be correct. In literature, the use of repeated BALs as a therapeutic strategy has also

Answer 4

e.

been described to remove the caseous material; in some cases, immunoglobulins have been used as a therapeutic option [10–14]. Most patients typically recover over a period of days with supportive care. An emerging form of LP is associated with the increasingly widespread use of electronic cigarettes (e-cigarettes). Electronic vaping pens/e-cigarettes with refillable chambers or interchangeable cartridges that contain tetrahydrocannabinol vaping concentrates or oils, the principal component of cannabis, are most frequently involved in the development of this pathological condition [15, 16].

Conclusion

Larygectomised patients may use a variety of inappropriate tools for tracheostomy cleaning, which may cause complications. There is a wide spectrum of causes for exogenous LP which are often characterised by late diagnosis. The clinical appearances range from acute forms, in which the identification of the exposure to the risk factor helps to reach the diagnosis, to subacute or chronic ones where the hidden history or the underestimation of symptoms and radiological findings lead to a delay in diagnosis. The radiological manifestations vary according to the clinical picture and the stage of the disease, ranging from indirect signs of bronchial or peribronchial inflammation, to the more complex pictures of ground glass or fibrosis. Therefore, the clinician must be aware of this condition to activate appropriate procedures and to establish the best therapeutic approach. This is becoming urgent with the widespread use of e-cigarettes that have been recently demonstrated to be an important cause of LP [15, 16].

Task 4

What is the correct treatment recommended for this patient?

- a) Corticosteroid therapy
- b) Repeated BAL
- c) Antibiotic therapy
- d) Oxygen therapy
- e) All of the above

Affiliations

Cinzia Arena¹, Federica Scaduto¹, Stefania Principe¹, Alida Benfante¹, Riccardo Messina¹, Alba La Sala², Laura Serafino Agrusa², Anna Martorana¹, Daniela Cabibi¹, Paolo Solidoro³, Nicola Scichilone¹

¹Dept of Health Promotion Sciences, Maternal and Infant Care, Internal Medicine and Medical Specialties, University of Palermo, Palermo, Italy. ²Interventional Pneumology Unit, ARNAS Civico Hospital, Palermo, Italy.

³Respiratory Clinic Città della Salute e della Scienza, Turin, Italy.

Conflict of interest

None declared.

References

- Gondouin A, Manzoni P, Ranfaing E, *et al.* Exogenous lipid pneumonia: a retrospective multicentre study of 44 cases. *Eur Respir J* 1996; 9: 1463–1469.
- Laughlen GF. Studies on pneumonia following naso pharyngeal injections of oil. *Am J Pathol* 1925; 1: 407–414.
- Spickard A 3rd, Hirschmann JV. Exogenous lipid pneumonia. *Arch Intern Med* 1994; 154: 686–692.
- Guo M, Liu J, Jiang B. Exogenous lipid pneumonia in old people caused by aspiration: Two case reports and literature review. *Respir Med Case Rep* 2019; 27: 100850.

5. Zanetti G, Marchiori E, Gasparetto TD, *et al.* Lipoid pneumonia in children following aspiration of mineral oil used in the treatment of constipation: high-resolution CT findings in 17 patients. *Pediatr Radiol* 2007; 37: 1135-1139.
6. Tancredi A, Graziano P, Scaramuzzi R, *et al.* Exogenous lipoid pneumonia due to chronic inhalation of oily product used as a lubricant of tracheotomy cannula. *Eurasian J Med* 2018; 50: 125-127.
7. Lu M, Yan W, Zhu X, *et al.* Exogenous lipoid pneumonia induced by long term usage of compound menthol nasal drops: a case report. *Beijing Da Xue Xue Bao Yi Xue Ban* 2019; 51: 359-361.
8. Franquet T, Gimenez A, Bordes R, *et al.* The crazy-paving pattern in exogenous lipoid pneumonia: CT-pathologic correlation. *Am J Roentgenol* 1998; 170: 315-317.
9. Betancourt SL, Martinez-Jimenez S, Rossi SE, *et al.* Lipoid pneumonia: spectrum of clinical and radiologic manifestations. *AJR Am J Roentgenol* 2010; 194: 103-109.
10. Sias SM, Ferreira AS, Daltro PA, *et al.* Evolution of exogenous lipoid pneumonia in children: clinical aspects, radiological aspects and the role of bronchoalveolar lavage. *J Bras Pneumol* 2009; 35: 839-845.
11. Sias SM, Daltro PA, Marchiori E, *et al.* Clinic and radiological improvement of lipoid pneumonia with multiple bronchoalveolar lavage. *Pediatr Pulmonol* 2009; 44: 309-315.
12. Nakashima S, Ishimatsu Y, Hara S, *et al.* Exogenous lipoid pneumonia successfully treated with bronchoscopic segmental lavage therapy. *Respir Care* 2015; 60: e1-e5.
13. Russo R, Chiumello D, Cassani G, *et al.* Case of exogenous lipoid pneumonia: steroid therapy and lung lavage with an emulsifier. *Anesthesiology* 2006; 104: 197-198.
14. Amato GM, Novara V, Amato G. Lipid pneumonia. Favorable outcome after treatment with intravenous immunoglobulins, steroids, cephalosporins. *Minerva Pediatr* 1997; 49: 163-169.
15. Davidson K, Brancato A, Heetderks P, *et al.* Outbreak of electronic-cigarette-associated acute lipoid pneumonia — North Carolina, July–August 2019. *MMWR Morb Mortal Wkly Rep* 2019; 68: 784-786.
16. Schier JG, Meiman JG, Layden J, *et al.* Severe pulmonary disease associated with electronic-cigarette-product use — interim guidance. *MMWR Morb Mortal Wkly Rep* 2019; 68: 787-790.