

AperTO - Archivio Istituzionale Open Access dell'Università di Torino

**Letter-to-the Editor: Focal cerebral arteriopathy and acute ischaemic stroke in children: A diagnostic-therapeutical conundrum**

**This is a pre print version of the following article:**

*Original Citation:*

*Availability:*

This version is available <http://hdl.handle.net/2318/1800820> since 2021-09-10T17:33:49Z

*Published version:*

DOI:10.1016/j.ejrad.2021.109846

*Terms of use:*

Open Access

Anyone can freely access the full text of works made available as "Open Access". Works made available under a Creative Commons license can be used according to the terms and conditions of said license. Use of all other works requires consent of the right holder (author or publisher) if not exempted from copyright protection by the applicable law.

(Article begins on next page)

# **Acute stroke and mechanical thrombectomy in children: “where is the conundrum?”**

Martino Cellerini<sup>1\*</sup>, Ciro Princiotta<sup>1</sup>, Roberto Menozzi <sup>2</sup> Giulia Capurri<sup>2</sup>, Russo R<sup>3</sup>, Mauro Bergui<sup>3</sup>

1 Department of Neuroradiology, Bellaria Hospital, IRCCS Istituto delle Scienze Neurologiche di Bologna, Italy

2 Department of Neuroradiology, AOU Parma, Parma Italy

3 Department of Neuroradiology , Città della Salute University Hospital, Torino , Italy

\* E-mail Corresponding Author: [martino.cellerini@isnb.it](mailto:martino.cellerini@isnb.it)

Martino Cellerini, MD, UOC Neuroradiologia, IRCCS-ISNB, Ospedale Bellaria, Via Altura 3, 40139, Bologna, Italy, phone: +39 051 622 5520. Fax: +39 051 622 5785.

Martino Cellerini will handle correspondence at all stages of refereeing, publication, and post-publication

## **ABSTRACT**

At difference with the adults, acute ischaemic stroke (AIS) in children presents significant differences mainly regarding aetiology and physiological response to an ischaemic insult (collateral vessels). Herein we report a small series of children (<16 yo) with AIS who underwent mechanical thrombectomy (MT). We speculate on the peculiar findings on the preliminary subtraction angiography (DSA), suggesting a possible aetiology of AIS, and on indications and limits of the currently available treatments.

## **PAPER**

**Background:** MT is the standard care of patients with large vessel occlusions (LVO) causing acute ischaemic stroke (AIS). On the preliminary DSA it is usually not possible to demonstrate the underlying cause of the vessel's occlusion. In the majority of patients, the vessel's occlusion is caused by an embolus in otherwise normal vessels and diagnosis is usually made on hindsight. However, in a minority of patients the occlusion is caused by a local vessel wall lesion, such as an atheromatic plaque in adults, or a focal arteriopathy in children. MT devices, such as stentrievors and large-bore catheters, are designed to efficiently remove emboli, but they are not necessarily as efficient in different lesions. One of the Authors (MC), observed a peculiar angiographic pattern in two children with AIS submitted to MT. Subsequently, a revision was started to pull out similar cases in different centres. Herein we report a small series of AIS cases in children whose diagnostic appearances, endovascular treatment strategies and outcome pose more questions than answers. The paper focuses on the peculiar findings of the preliminary DSA.

**Methods:** we retrospectively reviewed the pre-procedural DSA of patients <16 yo, submitted to MT because of AIS of the anterior circulation, from January 2018 to December 2019, in three large volume centres. Patients were classified as having either a vessel's occlusion or a stenosis. Only patients with a stenosis were included. Procedural imaging and clinical notes were then extracted and reviewed.

## **Results:**

Out of 777 patients with AIS submitted to MT 4 patients (<16 yo , range 13-16 years) .with no history of cardiopathy nor cervical dissection nor coagulopaties had similar appearances on the preliminary DSA. Appearances were characterized by a tight narrowing of the vessel lumen at the carotid terminus caused by a “minus” lump of the vessel’s lumen. (fig 1A,2A,3A,4A).

## **Case description**

### **Case #1 torino**

Thirteen yo boy, previously fit and well. He presented with a sudden onset right hemiparesis, while skying. He was admitted to a local hospital one hour later with a NIHSS=14 and a CT ASPECT score of 10. On MRI appearances were in keeping with an acute ischemic stroke in the left MCA territory. No i.v. lysis was performed. He was transferred to a comprehensive hospital for further treatment. At arrival (9 hours since symptoms onset), DSA demonstrated a diffuse filling defect of the left carotid terminus extending to the A1 and the M1 tracts of the anterior and middle cerebral arteries (fig.1A). Delayed albeit complete filling of the distal MCA branches was noted. MT with an ADAPT technique (3 passes) resulted in a complete occlusion of the distal M1 and A1 segments (fig.1B). The child had an unfavourable outcome with right MCA infarct ending with a dense right hemiplegia and mRS of 4 at discharge (1 mo later)

### **Case #2 bologna**

Fifteen yo girl previously fit and well. She presented with sudden onset of a right hemiparesis and transitory loss of consciousness.. She was tubed at the scene. On A&E arrival 1hrs and a half later she was submitted to a CT that resulted in normal appearances. A subsequent MRI-MRA study showed an area of restricted diffusion in the left lenticulostriate nuclei with no flow signal in the distal left carotid siphon and proximal M1 arteries. On DSA appearances were consistent with a severe stenosis of the supraclinoid left carotid siphon and proximal M1 with a delayed, albeit complete and orthograde filling of the distal left middle cerebral artery (MCA) branches (fig 2A) and good collateral circulation from pial branches of the anterior cerebral arteries (ACA) . Two consecutive stent-retriever passes under aspiration (Solumbra technique) resulted in an overall improvement of orthograde flow to the

left hemisphere with an area of vascular void in the left temporoparietal region (TICI=2B) and a residual stenosis at the origin of the left M1 segment (fig.2B). Follow-up MRI-MRA (7 days and 3 mo later) showed an established left lenticulostriate arteries infarct with persistent flow signal abnormalities in the left distal carotid siphon and M1. The child recovered gradually to a 3 month mRS of 2

### **Case #3 torino**

Sixteen yo female previously fit and well. She presented at the local hospital with high temperature (39° C) and a sudden onset left hemiparesis (NIHSS=14). She was transferred to the comprehensive hospital. At arrival 4 hrs 1/2 later a CT/CTA scan showed early ischemic signs in the right basal ganglia (ASPECTS=7) and a severe stenosis of the distal right ICA. She was transferred to the angi suite where the preliminary DSA confirmed the diagnosis of severe carotid terminus stenosis (fig.3A). A self-expandable stent was deployed in the right supraclinoid ICA, achieving an immediate and complete reopening of the vessel lumen (fig.3B). The patient was administered Tirofiban (i.v.bolus + 12 hrs infusion) followed by Clopidogrel loading and maintenance doses. She was discharged 2 weeks later with a mild left hemiparesis. An MRI scan obtained one month later ( mRS =2) was consistent with a partial infarction in the right ACA and anterior MCA.

### **Case#4 parma**

12yo boy admitted to hospital with a left dense hemiplegia (NIHSS=12) 5hrs and 40 min since symptoms onset. An immediate plain CT scan did not demonstrate early ischemic signs (ASPECTS=10) and a subsequent MRI-MRA study revealed an area of restricted diffusion in the right insula and frontoparietal region with a distal right ICA and MCA occlusion. No i.v. lysis was performed. The boy was transferred in the angi suite and a preliminary DSA showed an eccentric, severe narrowing of the right distal ICA –M1 junction with good pial collaterals (fig. 4A). One pass with a stent retriever (fig.4B,C) resulted in a complete reopening of the vessel lumen (TICI=3) and a good 3 month clinical outcome (mRS=0)

**Table 1 : Summary of the demographic , clinical (NIHSS), diagnostic (ASPECTs) features of the case series together with the endovascular treatment time-windows, techniques, follow-up imaging and outcomes**

	Age Sex	Clinical onset	CT/MR on hospital admission	Preliminary DSA	Procedures	Final DSA	Imaging follow-up and outcomes
<b>Case#1</b>	13yo M	R hemi. NIHSS= 12 No i.v. rT-PA	CT ASPECTS=10 MRI L.MCA territory diffusion hyperintensity MRA distal L ica - M1CA occlusion	Distal ICA, proximal M1-A1 stenosis Good collaterals O-to-G: 9 hrs	3 passes ADAPT	Worsened progression to occlusion L.MCA TICI=0	MRI L.MCA infarction l.MCA occlusion mRS (1 mo)= 4
<b>Case#2</b>	15yo F	R. hemi, LOC No NIHSS (tubed at the scene) No i.v. rT-PA	CT ASPECTs=10 MRI L. basal ganglia lesion MRA Distal ICA – M1 occlusion	Distal ICA proximal M1-A1 stenosis Good collaterals O-to-G::3hrs	2 passes ADAPT 1 pass Solumbra stent-triever	Improved perfusion but persistent severe stenosis at M1 CA origin TICI=2b	MRI L.basal ganglia infarct MRA abnormal flow signal in L. carotid siphon and M1 mRS (3mo)= 2
<b>Case#3</b>	16yo F	L. hemi NIHSS= 10 No i.v. rT-PA	CT ASPECTS=7 CTA preocclusive stenosis of R. distal carotid siphon R sigmoid sinus occlusion	Distal ICA proximal M1-A1 stenosis Good collaterals O-to-G : 2 dd	Primary stenting of the distal segment of R carotid siphon	Improved complete vessel lumen reopening TICI=3	MRI R.partial ischaemic infarct in ACA and anterior MCA territories mRS (1 mo)= 2
<b>Case#4</b>	12yo M	L hemi, NIHSS 12 No i.v. rT-PA	MR R insula and frontoparietal cortex lesion MRA distal R ICA, M1, A1 occlusion	Distal R ICA, proximal M1 A1 stenosis poor collaterals , O-to-G 5 hrs	1 pass with stent triever	vessel reopening TICI=3	MR basal ganglia and insula and frontoparietal cortex infarct ; mRS (3 mo)

**Legend:** M: Male, F: Female, L:Left, R:Right, NIHSS: National Institute Health Stroke Scale, i.v.: intra-venous, rT-PA: recombinant Tissue Plasminogen Activator, ASPECTS: Alberta Stroke Program Early CT Score, MR: Magnetic Resonance, MRA: MR angiography, CT: Computed Tomography, CTA: CT angiography, ICA: Internal Carotid Artery, M1: M1 segment of middle cerebral artery, A1: A1 segment of anterior cerebral artery, MCA: Middle Cerebral Artery, mRS: modified Rankin Score, O-to-G: Onset –to-Groin

## DISCUSSION

Age apart, the patients in our series are not in any way different from all other stroke patients, as far as the clinical presentation and cross sectional imaging are concerned. However, they are indeed different. On DSA, we found a peculiar and constant pattern characterized by a focal “minus” defect of the vessel’s lumen at the carotid terminus causing a severe stenosis. To our knowledge this pattern has not been described yet, and it deserves some thoughts.

First, regarding the patients. Our review was focused on patients less than 16 y.o. because our first cases were children. However we do not have any recollection of adults with AIS with a similar pattern.. This may be due both to a pathogenetic mechanism selectively affecting young people. Alternatively, appearances may be caused by a focal arteriopathy (inflammatory or non-inflammatory) more common in children than adults since the relative rarity of AIS and the absence of atherosclerosis in the paediatric age.

Second, regarding the nature of the lesion. A relevant element is that the ICA was not completely occluded.. Indeed in all patients the affected MCA territories were supplied by a satisfactory amount of orthograde and collateral flow. It is unlikely that such a limited flow reduction especially in children and young adults, may cause symptoms as relevant as those that affected our patients. A possible explanation is that a partial resolution of the ICA-MCA occlusion may have occurred within the time window from symptom onset to DSA. Such behaviour, (occlusion and partial spontaneous reopening) although not exclusive, is in keeping with a sub-intimal dissection with a moving flap. Although a partially recanalized embolus may not be completely excluded, the angiographic appearances are not consistent at all with this hypothesis if the location (ICA instead of MCA) the eccentricity of the lesion (a recanalized embolus most likely appears as a concentric recanalization) and its profile (smooth versus irregular) are taken into account. A different aetiology to be considered is an inflammatory

focal arteriopathy. This is a leading cause of stroke in children in the absence of other risk factors. The angiographic pattern has been described (lasjaunias) and clinical features have been recently revised (). Although this disease may not be completely excluded, focal arteriopathies have different angiographic appearances, and they usually involves the first portion of MCA, while in our patients the disease was located in terminal ICA.

Third, regarding treatment. The stentriever and direct stenting techniques were efficient in 3 cases, while aspiration resulted harmful in a single patient. Due to the limited size of the sample, we obviously cannot generalize these results. Anyway, while aspiration and stentriever are both efficient in embolic occlusions, (responsible for the vast majority of LVO in AIS), this may not necessarily be the case in patients with a dissective arteriopathy. In the hypothesis of a focal subintimal dissection, the retrieval of a stentriever moving retrogradely to flow direction (from distal-to- proximal) may have a very different effect on a flap than a large bore aspiration catheter moving the other way round (from proximal- to-distal). The presence of a subintimal dissection with a flap may also explain the optimal and immediate vessel reopening in case #3 following the deployment of a self-expandable stent in the right terminal ICA.

As a final consideration, it is possible that in these patients there is a yet-unrecognized benefit in relying on collateral circulation rather than attempting to aggressively reopen the vessel. Aggressive management of acute stroke in children involves general anaesthesia, possibly lowering blood pressure and disrupting normal compensatory mechanism for an efficient collateral circulation.

**Conclusions:** we identified a peculiar angiographic pattern of lesions in four children with anterior circulation AIS. Although a definitive diagnosis could not be made, a focal subintimal dissective pathology was suspected based on the preliminary DSA appearances and the procedural behaviour during MT. This pattern should suggest a cautious attitude for MT and/ or different strategies for revascularization.



## REFERENCES

1. Berkhemer OA, Fransen PS, Beumer D, et al. A randomized trial of intraarterial treatment for acute ischemic stroke. *N Engl J Med.* 2015;372:11e20.
2. Campbell BC, Mitchell PJ, Kleinig TJ, et al. Endovascular therapy for ischemic stroke with perfusion-imaging selection. *N Engl J Med.* 2015;372:1009e1018.
3. Goyal M, Demchuk AM, Menon BK, et al. Randomized assessment of rapid endovascular treatment of ischemic stroke. *N Engl J Med.* 2015;372:1019e1030.
4. Jovin TG, Chamorro A, Cobo E, et al. Thrombectomy within 8 hours after symptom onset in ischemic stroke. *N Engl J Med.* 2015;372:2296e2306.
5. Saver JL, Goyal M, Bonafe A, et al. Stent-retriever thrombectomy after intravenous t-PA vs. t-PA alone in stroke. *N Engl J Med.* 2015;372:2285e2295
6. Nencini P, Inzitari D, Baruffi MC, et al. Incidence of stroke in young adults in Florence, Italy. *Stroke* 1988;19:977–81.
7. Rozenhul-Sorokin N, Ronen R, Tamir A, et al. Stroke in the young in Israel. Incidence and outcomes. *Stroke* 1996;27:838–41.
8. Kristensen B, Malm J, Carlberg B, et al. Epidemiology and etiology of ischemic stroke in young adults aged 18 to 44 years in northern Sweden. *Stroke* 1997;28:1702–9.
9. Marini C, Totaro R, De Santis F, et al. Stroke in young adults in the community based. L'Aquila registry: incidence and prognosis. *Stroke* 2001;32:52–6.
10. K Nedeltchev, T A der Maur, D Georgiadis, M Arnold, V Caso, H P Mattle, G Schroth, L Remonda,
11. M Sturzenegger, U Fischer, R W Baumgartner Ischaemic stroke in young adults: predictors of outcome and
12. Recurrence *J Neurol Neurosurg Psychiatry* 2005;76:191–195. doi: 10.1136/jnnp.2004.040543
13. Powers WJ, Derdeyn CP, Biller J, et al. 2015 American Heart Association/American Stroke Association focused update of the 2013 Guidelines for the early management of patients with acute ischemic stroke

- regarding endovascular treatment: A Guideline for healthcare professionals from the American Heart Association/American Stroke Association. *Stroke*. 2015;46:3020e3035.
14. Albers GW, Marks MP, Kemp S, et al. Thrombectomy for stroke at 6 to 16 hours with selection by perfusion imaging. *N Engl J Med*. 2018;378:708e718.
  15. Nogueira RG, Jadhav AP, Haussen DC, et al. Thrombectomy 6 to 24 hours after stroke with a mismatch between deficit and infarct. *N Engl J Med*. 2018;378: 11e21.
  16. Powers WJ, Rabinstein AA, Ackerson T, et al. Guidelines for the early management of patients with acute ischemic stroke: a guideline for healthcare professionals from the American Heart Association/American Stroke Association. *Stroke*. 2018;49:e46e110.
  17. Satti S, Chen J, Sivapatham T, Jayaraman M, Orbach D. Mechanical thrombectomy for pediatric acute ischemic stroke: review of the literature. *J Neurointerv Surg*. 2017;9:732e737.
  18. Jacobs BS, Boden-Albala B, Lin IF, et al. Stroke in the young in the northern Manhattan stroke study. *Stroke* 2002;33:2789–93.
  19. Naess H, Nyland HI, Thomassen L, et al. Incidence and short-term outcome of cerebral infarction in young adults in western Norway. *Stroke* 2002;33:2105–8.
  20. Mallick AA, Ganesan V, Kirkham FJ, et al. Diagnostic delays in paediatric stroke. *J Neurol Neurosurg Psychiatry*. 2015;86:917e921.
  21. Rivkin MJ, deVeber G, Ichord RN, et al. Thrombolysis in pediatric stroke study. *Stroke*. 2015;46:880e885.
  22. Smajlović D. Strokes in young adults: epidemiology and prevention. *Vasc Health Risk Manag*. 2015 Feb 24;11:157-64. doi: 10.2147/VHRM.S53203. PMID: 25750539; PMCID: PMC4348138.
  23. Mineyko A, Kirton A. Mechanisms of pediatric cerebral arteriopathy: an inflammatory debate. *Pediatr Neurol*. 2013 Jan;48(1):14-23. doi: 10.1016/j.pediatrneurol.2012.06.021. Review. PMID: 23290015
  24. Harwood-Nash DC, McDonald P, Argent W (1971) Cerebral arterial disease in children. *AJR Am J Roentgenol* 111:672–686 11.

25. Chabrier S, Rodesch G, Lasjaunias P, et al (1998) Transient cerebral arteriopathy: a disorder recognized by serial angiograms in children with stroke. *J Child Neurol* 13:27–32 12.
26. Lanthier S, Lortie A, Michaud J, et al (2001) Isolated angiitis of the CNS in children. *Neurology* 56:837–842 13.
27. Fullerton HJ, Johnston SC, Smith WS (2001) Arterial dissection and stroke in children. *Neurology* 57:1155–1160
28. Lasjaunias, P., & Husson, B. (2004). Radiological approach to disorders of arterial brain vessels associated with childhood arterial stroke? A comparison between MRA and contrast angiography. *Pediatric Radiology*, 34(1), 10–15. doi:10.1007/s00247-003-1109-0
29. Balami JS, White PM, McMeekin PJ, Ford GA, Buchan AM. Complications of endovascular treatment for acute ischemic stroke: prevention and management. *Int J Stroke*. 2018;13:348e361.

## FIGURES AND CAPTIONS

### FIGURE 1 (A-B)

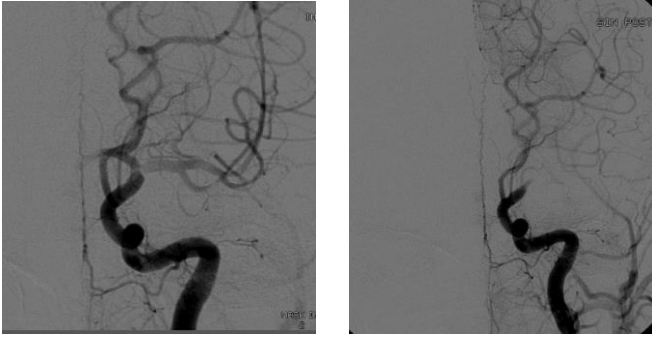


Fig. 1 (A-B) DSA selective left ICA injection pre and post MT, frontal view (case #1) On the preliminary angiogram there is a scant filling of the carotid terminus and the M1 segment with persistent orthograde flow. The ACAs are not opacified because of a wash out phenomenon from the right ICA. After MT (B) there is a dramatic worsening of the angiogram with complete occlusion of the carotid terminus.

### FIGURE 2(A-B)

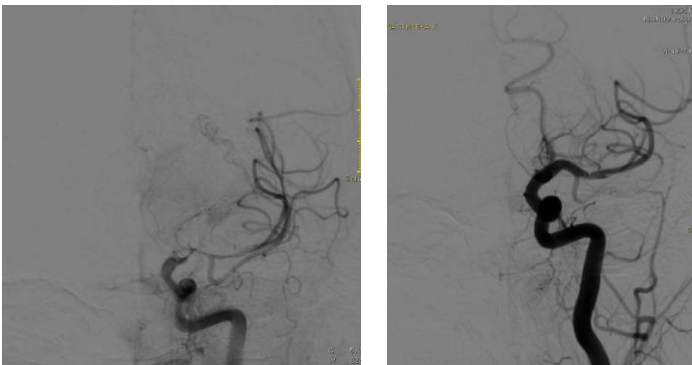


Fig. 1 (A-B) DSA selective left ICA injection pre and post MT, frontal view (case #2) On the preliminary angiogram (A) there is a severe narrowing of the carotid terminus-M1 junction with an eccentric “minus” image (“lump”) protruding into the vessel’s lumen with a smooth profile. After MT (B) there is a satisfactory reopening of the vessel with a focal vasospasm in the proximal M1 segment

### FIGURE 3 (A-B)

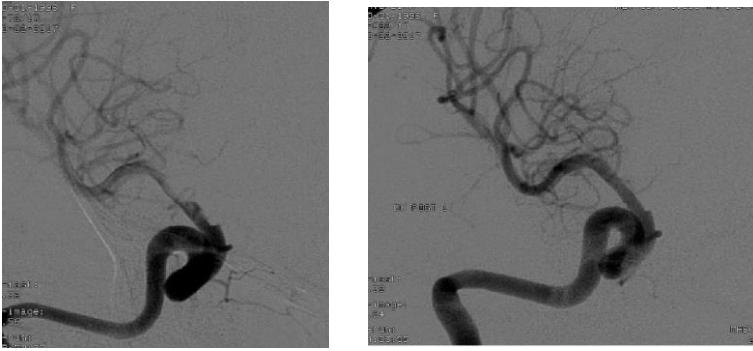


Fig. 3 (A-B) DSA selective right ICA injection pre and post MT, frontal view (case #3) On the preliminary angiogram (A) there is a smooth narrowing of the carotid terminus-M1 junction with persistent orthograde flow. The ACAs are not opacified because of a left dominant A1 segment. After MT (B) there is a successful reopening of the vessel lumen

### FIGURE 4 (A-C)

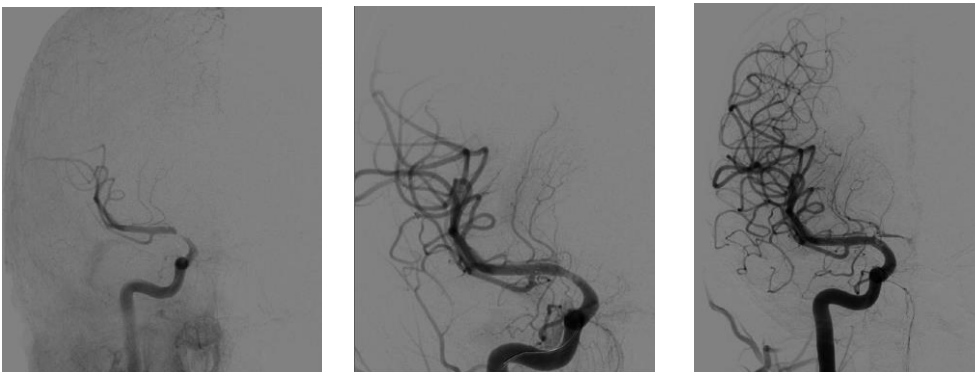


Fig. 4 (A-C) DSA selective right ICA injection pre , during and post MT, frontal view (case #4) On the preliminary angiogram (A) there is a smooth eccentric narrowing of the carotid terminus-M1 junction with delayed orthograde filling of the distal MCA branches. After placement and unsheathing of the stentriever (B) there is a satisfactory reopening of the vessel with restoration of a full orthograde flow. After retrieval of the stentriever (C) there is a complete vessel's patency restoration with filling of a hypoplastic A1 segment as well.