

AperTO - Archivio Istituzionale Open Access dell'Università di Torino

## Expanding the molecular and clinical phenotypes of FUT8-CDG

### This is the author's manuscript

*Original Citation:*

*Availability:*

This version is available <http://hdl.handle.net/2318/1800478> since 2021-09-09T13:18:51Z

*Published version:*

DOI:10.1002/jimd.12221


*Terms of use:*

Open Access

Anyone can freely access the full text of works made available as "Open Access". Works made available under a Creative Commons license can be used according to the terms and conditions of said license. Use of all other works requires consent of the right holder (author or publisher) if not exempted from copyright protection by the applicable law.

(Article begins on next page)

# Expanding the molecular and clinical phenotypes of FUT8-CDG

Bobby G. Ng<sup>1</sup>  | Hassan Dastsooz<sup>2,3</sup> | Mohammad Silawi<sup>3</sup> | Parham Habibzadeh<sup>3</sup> | Shima B. Jahan<sup>3</sup> | Mohammad A. F. Fard<sup>3</sup> | Benjamin J. Halliday<sup>4</sup> | Kimiyo Raymond<sup>5</sup> | Maura R. Z. Ruzhnikov<sup>6,7</sup> | Zahra Tabatabaei<sup>3</sup> | Afsaneh Taghipour-Sheshdeh<sup>3</sup> | Elise Brimble<sup>6</sup> | Stephen P. Robertson<sup>4</sup> | Mohammad A. Faghihi<sup>3,8</sup> | Hudson H. Freeze<sup>1</sup>

<sup>1</sup>Human Genetics Program, Sanford Burnham Prebys Medical Discovery Institute, La Jolla, California

<sup>2</sup>Department of Life Sciences and Systems Biology, Italian Institute for Genomic Medicine (IIGM), University of Turin, Turin, Italy

<sup>3</sup>Persian BayanGene Research and Training Center, Shiraz University of Medical Sciences, Shiraz, Iran

<sup>4</sup>Department of Women's and Children's Health, Dunedin School of Medicine, University of Otago, Dunedin, New Zealand

<sup>5</sup>Biochemical Genetics Laboratory, Mayo Clinic College of Medicine, Rochester, Minnesota

<sup>6</sup>Department of Neurology and Neurological Sciences, Stanford Medicine, Stanford, California

<sup>7</sup>Division of Medical Genetics, Department of Pediatrics, Stanford Medicine, Stanford, California

<sup>8</sup>Center for Therapeutic Innovation, Department of Psychiatry and Behavioral Sciences, University of Miami Miller School of Medicine, Miami, Florida

## Correspondence

Hudson H. Freeze, Human Genetics Program, Sanford Children's Health Research Center, Sanford-Burnham-Prebys Medical Discovery Institute, 10901 N. Torrey Pines Rd. La Jolla, CA 92037.  
Email: hudson@sbnpdiscovery.org

**Communicating Editor:** Eva Morava

## Funding information

Genomics Aotearoa; Curekids; National Institutes of Health, Grant/Award Number: R01DK099551; Bella Conneran Foundation; Rocket Fund

## Abstract

Pathogenic variants in the Golgi localised alpha 1,6 fucosyltransferase, *FUT8*, cause a rare inherited metabolic disorder known as FUT8-CDG. To date, only three affected individuals have been reported presenting with a constellation of symptoms including intrauterine growth restriction, severe delays in growth and development, other neurological impairments, significantly shortened limbs, respiratory complications, and shortened lifespan. Here, we report an additional four unrelated affected individuals homozygous for novel pathogenic variants in *FUT8*. Analysis of serum *N*-glycans revealed a complete lack of core fucosylation, an important diagnostic biomarker of FUT8-CDG. Our data expands both the molecular and clinical phenotypes of FUT8-CDG and highlights the importance of identifying a reliable biomarker for confirming potentially pathogenic variants.

## KEYWORDS

congenital disorders of glycosylation, core fucosylation, mass spectrometry, *N*-glycans, whole exome sequencing

## 1 | INTRODUCTION

Congenital disorders of glycosylation (CDG) are a clinically diverse group of primarily autosomal recessive disorders that result in altered protein and lipid glycosylation. To date, more than 135 genes have been found to cause CDG.<sup>1,2</sup> Several of these disorders are specifically due to abnormalities in fucosylation, which is an enzymatic process of incorporating the monosaccharide L-fucose into the N- and O-glycans of proteins or glycolipids.<sup>3</sup>

Proper fucosylation requires the formation of the activated donor substrate, guanosine diphosphate L-fucose (GDP-fucose), which can occur by both de novo and salvage mechanisms.<sup>3</sup> It is widely believed that the de novo pathway accounts for the vast majority (90%) of GDP-fucose generated within a cell.<sup>4</sup> In the de novo pathway, glucose and mannose are essential for synthesising GDP-mannose, of which a portion is subsequently converted to GDP-fucose via a two-enzyme mechanism involving GDP mannose 4,6-dehydratase (GMDS), and GDP-keto-6-deoxymannose 3,5 epimerase (TSTA3) (aka FX protein).<sup>3</sup> The salvage pathway also utilises a two-enzyme mechanism to convert exogenously provided (diet) or recycled L-fucose (lysosomal-dependent glycan degradation) to GDP-fucose. Here, L-fucose is first phosphorylated by fucose kinase (FCSK) to generate fucose-1-phosphate which then undergoes a pyrophosphorylase (FPGT) reaction to yield GDP-fucose.<sup>3,5</sup> Postnatal lethality in a *Tsta3* (aka FX) knockout (KO) mouse model has shown that complete loss of the de novo pathway can be rescued by providing exogenous L-fucose, suggesting a compensatory role of the salvage pathway.<sup>6</sup> Ultimately, GDP-fucose is transported into the Golgi via SLC35C1 or into the endoplasmic reticulum by SLC35C2 where specific fucosyltransferases add fucose to various acceptor substrates.<sup>7,8</sup>

The most ubiquitous form of fucosylation is “Core fucosylation” of N-linked glycans and requires the Golgi localised fucosyltransferase FUT8 to attach an L-fucose to the N-acetylglucosamine (GlcNAc) directly linked to an asparagine (Asn)<sup>3</sup> (Figure 1A). FUT8 contains three distinct domains, an N-terminal coiled-coil domain, a glycosyltransferase 23 family domain and a C-terminal SH3 domain. It is unclear what role the coiled-coil or SH3 domains of FUT8 play in its function. Although, if compared to other proteins containing these domains, they likely are involved in protein-protein interactions.<sup>10</sup> Core fucosylation has been shown to be critical for many cellular processes including immune system regulation, inflammatory responses, cancer metastasis, and embryonic development.<sup>11-15</sup>

Thus far, biochemically confirmed pathogenic variants have been identified in fucose kinase (*FCSK*) [OMIM

#618324], fucosyltransferase 8 (*FUT8*) [OMIM# 618005], GDP-fucose transporter (*SLC35C1*) [OMIM# 605881], protein O-fucosyltransferases (*POFUT1*) [OMIM# 615327], fucose-specific beta-1,3-N-acetylglucosaminyltransferase (*LFNG*) [OMIM# 609813], and the lysosomal fucosidase 1 (*FUCA1*) [OMIM# 612280]. All are extremely rare disorders, and only a few SLC35C1-CDG individuals have been shown to benefit from oral fucose therapy.<sup>16</sup>

Here, we identify four unreported FUT8-CDG subjects expanding this disorder's molecular and clinical presentation.

## 2 | METHODS AND MATERIALS

### 2.1 | Clinical data

Written consent was provided for all four families in accordance with a Sanford Burnham Prebys Medical Discovery Institute approved IRB-2014-038-17.

### 2.2 | Serum N-glycan analysis

Matrix-assisted laser desorption/ionisation tandem time of flight/time of flight (MALDI-TOF/TOF) mass spectrometry analysis of total serum N-glycans was performed as previously described at the Mayo Clinic.<sup>17</sup>

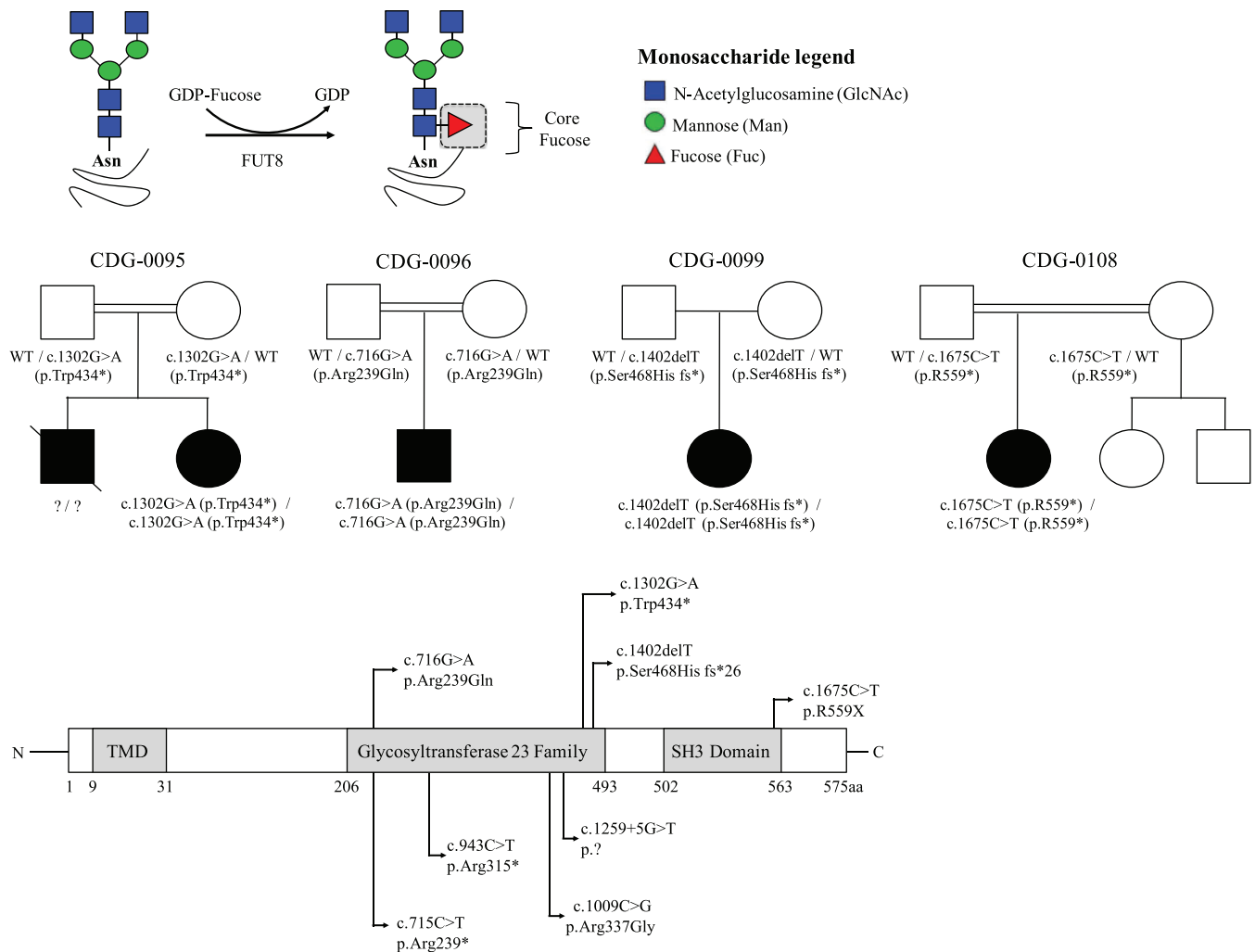
### 2.3 | Exome sequencing and analysis

All four affected individuals had next generation sequencing performed by different institutions. CDG-0099 had whole genome trio sequencing performed in a research setting, while CDG-0108 had whole exome sequencing (WES) performed by a CLIA approved clinical lab service. Specifically, for CDG-0095 and 0096, genomic DNA was extracted from blood and used for WES on an Illumina NextSeq500 instrument with 150-nucleotide paired-end sequencing. WES raw data were processed and analysed with BWA aligner (19451168), GATK (20644199), and ANNOVAR (20601685). All variants were confirmed by Sanger sequencing.

## 3 | RESULTS

### 3.1 | Clinical phenotype

CDG-0095 is a female infant of Iranian ancestry born to consanguineous second-degree cousins (Figure 1B). The



**FIGURE 1** Identification of novel *FUT8* pathogenic variants in four unrelated families. A, Schematic showing the FUT8-dependent synthesis of core fucose. B, Pedigrees for the four families. C, Schematic showing both new (upper) and previously reported (lower) mutations in *FUT8* (GenBank: NM\_178155.2, Uniprot: Q9BYC5). Figure adapted and updated from Reference 9

family history was notable for an affected sibling with similar presentation who passed away at 14 months of age without a diagnosis. The pregnancy was complicated by polyhydramnios. However, there was no evidence of intrauterine growth restriction (IUGR) on prenatal ultrasonography. She was unable to tolerate breastfeeding and had hypotonia and dysmorphic features on physical examination (Table 1). She had global developmental delays with cognitive impairment and epilepsy. She had a history of recurrent pneumonia. She is still alive at 3 years of age.

The second individual, CDG-0096, is a male also of Iranian descent and a product of a second-degree consanguineous marriage (Figure 1B). The pregnancy was not complicated by polyhydramnios or IUGR, but he was delivered at 37 weeks gestation by caesarean section due to meconium aspiration. During the postnatal period, he was hypotonic and could not tolerate breast feeding. He was also found to have dysplastic ears and dysmorphic

facial features. He has a history of developmental delays with severe intellectual disability and epilepsy that is only partially controlled with medication (Table 1). Brain magnetic resonance imaging revealed slight ventriculomegaly with mildly delayed myelination. Abdominopelvic ultrasonography showed renal stones in both kidneys without any evidence of hepatosplenomegaly. The individual has had recurrent pneumonia for which he was admitted to hospital on two occasions. Thyroid-stimulating hormone level (8.1  $\mu$ U/mL, reference range: 0.3-5.5  $\mu$ U/mL) was mildly increased. He remains alive at 6 years of age.

The third individual, CDG-0099, is an affected female from healthy non-consanguineous parents of European ancestry who did not have a family history of a similar disorder (Figure 1B). No pregnancy complications were reported; however, IUGR was noted. She presented early with significant hypotonia, facial dysmorphism, failure to thrive, and feeding problems requiring placement of a

**TABLE 1** Clinical and molecular summaries for the three previously reported and four new FUT8-CDG individuals

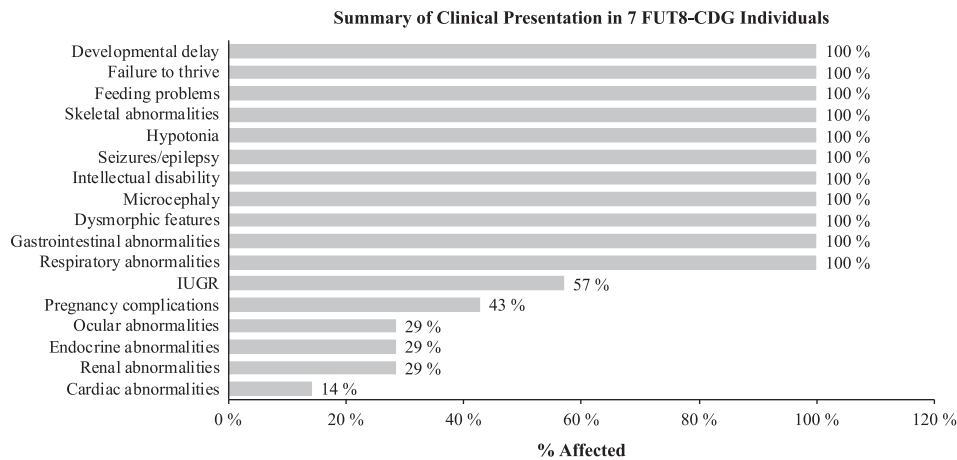
	Ng et al <sup>9</sup>	Ng et al <sup>9</sup>	Ng et al <sup>9</sup>	CDG—0095	CDG—0096	CDG—0099	CDG—0108	Total
Gender	Female	Female	Male	Female	Male	Female	Female	5F/2M
Year of birth	2014	2014	2010	2016	2013	2015	2003	
Death (date)	Feb 2018	Feb 2018	Sept 2017	NA-Alive	NA-Alive	NA-Alive	NA-Alive	
Family history	No	No	Yes, deceased older brother	Older brother with similar presentation, deceased at 14 months	Intellectual disability in distant relatives	No	No	
Consanguinity	Yes, second cousin	No	Yes, first cousin	Yes, second cousin	Yes, second cousin	No	Yes, first cousins	
Ancestry	Irish, Italian, Native American	Irish-Norwegian / Irish-Ukrainian-Belgian	Arab	Iranian	Iranian	New Zealand / European	Southeast Asia (Philippines)	
Detection method	WES	WES	WES	WES	WES	WGS	WES	
FUT8 pathogenic variants	c.715C > T (p. Arg239*)	c.1009C > G (p. Arg337Gly) c.1259 + 5 G > T (N/A)	c.943C > T (p. Arg315*)	c.1302G > A (p. Trp434*)	c.716G > A (p. Arg239Gln)	c.1402delT (p. Ser468His fs*26)	c.1675C > T (p.R559*)	
Developmental delay	Severe	Severe	Severe	Severe	Severe	Severe	Severe	7/7
Failure to thrive	Severe	Severe	Severe	Severe	Severe	Severe	Severe	7/7
Feeding problems	Yes	Yes	Yes	Yes	Yes	Yes	Yes	7/7
Skeletal abnormalities	Short stature	Short stature	Short stature, multiple contractures, severe osteopenia, hip dislocations, kyphoscoliosis	Short stature, upper extremity hemihypertrophy	Short stature	Short stature, scoliosis	Contractures fingers, ankles, feet; progressive scoliosis; left hip dislocation; short stature	7/7
Hypotonia	Yes	Yes	Central with peripheral spasticity	Yes	Yes	Yes	Yes	7/7
Seizures/epilepsy	Yes	Yes	Yes	Yes	Yes	Yes	Yes	7/7
Intellectual disability	Yes	Yes	Yes	Yes	Yes	Yes	Yes	7/7

(Continues)

TABLE 1 (Continued)

	Ng et al <sup>a</sup>	Ng et al <sup>b</sup>	Ng et al <sup>c</sup>	CDG—0095	CDG—0096	CDG—0099	CDG—0108	Total
Microcephaly	Yes, 33 months <first percentile	Yes, 31 months <10th percentile	Yes, 36 months <third percentile	Yes, 21 months ≤first percentile	Yes, 5 Years ≤third percentile	Yes	Yes, 16 years <first percentile	7/7
Dysmorphic features	High palate, oedematous eyelids and nasal bridge, wide nasal bridge, retrognathia	Buphthalmos, high broad forehead, mild lymphedema of hands and feet	Bitemporal narrowing, hirsutism, exotropia, exophthalmos, short nose, enlarged left eye with macrocornea	Oedematous eyelids, wide nasal bridge, retrognathia, epicanthal fold	Oedematous eyelids, dysplastic ears	Course facial features, downslanting palpebral fissures, high palate	Flattened midface, flattened nasal bridge with short rounded tip that is upturned with anteverted nares, broad lips, lower lip is everted, many teeth are mispositioned and eroded	7/7
Gastrointestinal abnormalities	G-tube placement	G-tube placement	Feeding difficulties with reflux	Feeding difficulties and constipation	Feeding difficulties	NG-tube placement	G-tube placement	7/7
Respiratory abnormalities	Tracheostomy	Reactive airway disease	Recurrent bronchopneumonia	Recurrent pneumonia	Recurrent pneumonia	Recurrent pulmonary infections	Chronic lung disease	7/7
IUGR	Yes (<second percentile)	Yes (third percentile)	Yes (third percentile)	No	No	Yes	No	4/7
Pregnancy complications	Polyhydramnios	Polyhydramnios	Normal	Polyhydramnios	Normal	Normal	Normal	3/7
Ocular abnormalities	No	Congenital glaucoma	No	No	No	Congenital glaucoma	Cortical visual impairment, high myopia, intermittent esotropia	2/7
Endocrine abnormalities	Hypothyroidism	Not reported	No	No	Hypothyroidism	No	No	2/7
Renal abnormalities	Nephrocalcinosis	No	No	No	Renal stones	No	No	2/7
Cardiac abnormalities	Atrial septal defect, repaired; patent ductus arteriosus ligation	No	No	No	No	No	No	1/7

Abbreviations: WES, whole exome sequencing; WGS, whole genome sequencing.



**FIGURE 2** Clinical Summary for the three previously reported and four new FUT8-CDG individuals

nasogastric tube (NG-tube). She has a history of severe developmental delays with intellectual disability, along with intractable seizures. Skeletal abnormalities include short stature and scoliosis. She is noted to have congenital glaucoma (Table 1). CDG-0099 is still alive at 4 years of age.

Finally, CDG-0108 is an affected female born to healthy consanguineous parents of Southeast Asian ancestry (Figure 1B). No complications or IUGR were noted during pregnancy. She has significant hypotonia and facial dysmorphism that includes a flattened nasal bridge with short rounded tip and broad lips with a lower lip that is everted. Like the previously mentioned subjects, she has feeding problems with severe failure to thrive, a history of global developmental delay with severe intellectual disabilities, epilepsy, and microcephaly. A multitude of skeletal abnormalities were noted including contractures of the fingers, ankles and feet, progressive scoliosis and a history of left hip dislocations (Table 1). Like those described above, CDG-0108 is still alive at 16 years of age, making her the oldest known FUT8-CDG case.

Comparing the three previously reported FUT8-CDG cases, these four reveal striking similarities. All seven individuals presented with severe global developmental delays with cognitive impairment or intellectual disability, feeding problems, dysmorphic facial features, microcephaly, seizures, hypotonia, and various skeletal abnormalities (Figure 2, Table 1). This suggests that FUT8-CDG could have a recognisable phenotypic presentation. Respiratory difficulties were also seen in 7/7 individuals with five of those seven having recurrent infections (Figure 2, Table 1). This is noteworthy because FUT8-KO mice also have respiratory difficulties.<sup>15</sup> Cardiac and renal abnormalities were less frequent and could be due to other genetic factors. While all three original cases presented with IUGR and ultimately died

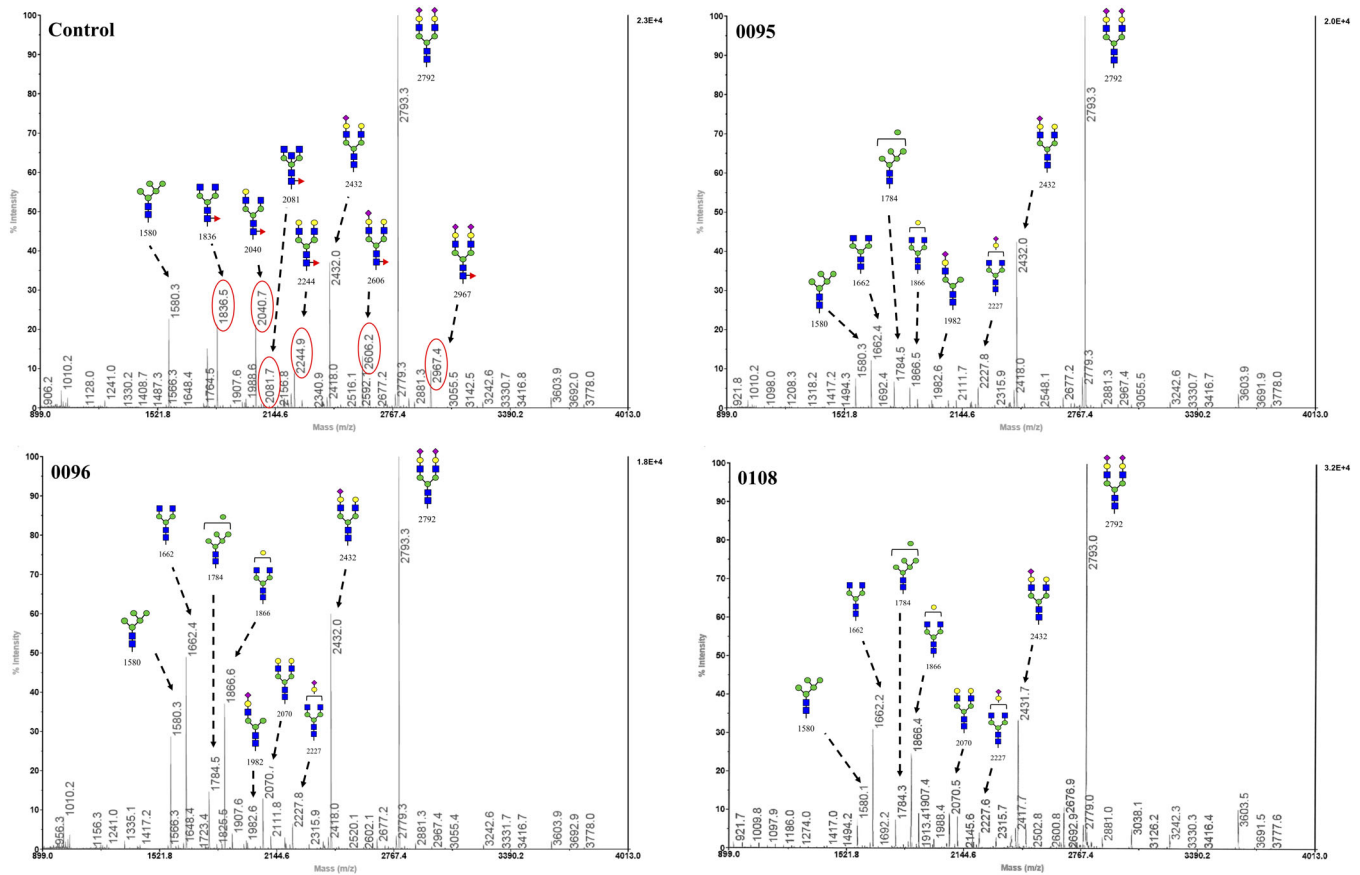
prematurely, only one of the current four had IUGR and all are still alive (Figure 2, Table 1).

In all four cases, clinical phenotyping and laboratory testing failed to reach a definitive diagnosis. Therefore, next-generation sequencing was used to reach a diagnosis.

### 3.2 | Molecular analysis

All four affected individuals had next generation sequencing performed at different institutions or clinical lab services. Three of the four individuals (0095, 0096, 0108) were from consanguineous families who had whole exome performed on the proband (Table 1). For these individuals, due to the consanguinity, filtering was initially focused on rare homozygous variants of less than 1% allele frequency. CDG-0099 had whole genome sequencing performed on the family trio, which was used to determine potential compound heterozygous, homozygous, and de novo variants that segregated appropriately.

Importantly, variant filtering revealed that three of the four individuals (0095, 0099, 0108) were homozygous for truncating loss of function INDEL or nonsense variants in the alpha 1,6 fucosyltransferase *FUT8* (NCBI Refseq—NM\_178155.2, Uniprot—Q9BYC5). CDG-0095 was identified to have a novel c.1302G > A [p.Trp434\*], CDG-0099 a novel c.1402delT [p.Ser468Hisfs\*26] and CDG-0108 c.1675C > T [p.Arg559\*] (Table 1, Figure 1B,C). Interestingly, CDG-0096 was determined to be homozygous for a variant of uncertain significance (VUS) c.716G > A [p.R239Q], which overlaps with a previously reported nonsense variant c.715C > T (p.Arg239\*)<sup>9</sup> (Table 1, Figure 1B, C). Three in silico prediction programs suggest the c.716G > A [p.R239Q] to be damaging with a Polyphen2 (<http://genetics.bwh.harvard.edu/pph2/>) score of 1 (probably damaging), SIFT (<http://provean.jcvi.org/index.php>)



**FIGURE 3** MALDI-TOF/TOF-MS *N*-glycan profiles from a healthy control serum sample as well as CDG-0095, 0096, 0108. Highlighted within the red circles of the control sample, are those core fucosylated *N*-glycans that are completely lost in each of the three (0095, 0096, 0108) affected FUT8-CDG individuals

score of 0 (deleterious), and a CADD (<https://cadd.gs.washington.edu/>) score of 26.1 which would place it in the top 0.5% of deleterious variants in the human genome.

Only the c.1675C > T [p.Arg559\*] variant was seen in a single heterozygous carrier from the gnomAD database (1/250 464 alleles) (<http://gnomad.broadinstitute.org/>) (gnomAD v2.1.1 accessed November 25, 2019) of 125 748 exomes and 15 708 whole-genomes of unrelated individuals. Neither of the four variants were seen in gnomAD v3, which is composed of 71 702 genomes (doi: <https://doi.org/10.1101/531210>).

### 3.3 | Serum *N*-glycan analysis

We had previously used MALDI-TOF/TOF on serum samples to confirm the lack of core fucosylation in individuals with FUT8-CDG.<sup>9</sup> We applied this same technique to three of the four affected individuals presented here. The lone individual (CDG-0099) we were unable to obtain sample for and thus did not have MALDI-TOF/TOF-MS of serum glycoproteins was homozygous for the

c.1402delT [p.Ser468Hisfs\*26] (Table 1). We have previously shown that truncating variants in FUT8, like that seen in CDG-0108, are not tolerated and results in the complete loss of core fucosylation, ultimately causing FUT8-CDG.<sup>9</sup> When compared to a representative control serum sample from a “healthy” individual, CDG-0095 and CDG-0108 who are both homozygous for nonsense mutations, showed a complete loss of core fucosylated *N*-glycans from serum proteins (Figure 3). MALDI-TOF/TOF-MS values highlighted within red circles represent those glycans that are completely missing in both CDG-0095 and CDG-0108 (1836; 2040; 2081, 2244, 2606; 2967 m/z) (Figure 3). Importantly, CDG-0096, who carries the VUS c.716G > A [p.R239Q] was also shown to have a complete loss of core fucosylation (Figure 3). Thus, confirming that the c.716G > A [p.R239Q] is in fact, a pathogenic variant. Finally, analysis of serum transferrin glycosylation in at least one individual was normal and did not reveal any clear abnormalities in fucosylation (Figure S1). However, it should be noted that only a small percentage of the total transferrin undergoes fucosylation.



## 4 | DISCUSSION

There are an estimated 13 fucosyltransferases encoded in the human genome, but only one (*FUT8*) encodes an enzyme capable of carrying out core fucosylation.<sup>3</sup> The importance of creating the *FUT8*-dependent core fucosylation epitope can be seen in both mouse KO models and individuals who have *FUT8*-CDG. *Fut8* KO mice show severe growth restriction, respiratory defects, and a high mortality rate of ~70%.<sup>15</sup> KO mice that do survive are more vulnerable to progressive chronic obstructive pulmonary disease and have been shown to exhibit a significant reduction in liver regeneration capabilities following partial hepatectomy.<sup>18,19</sup> Additionally, they display increased neuroinflammation and display multiple behavioural abnormalities consistent with a schizophrenia-like phenotype.<sup>13,20</sup> Consistent with the KO mouse model, affected individuals with *FUT8*-CDG show severe developmental and growth delays, shortened limbs, various neurological impairments, and respiratory complications.<sup>9</sup> Subsequent follow up of the original reported cases revealed that all three have passed away, while all four subjects described here are still alive at 3 to 16 years of age.

Interestingly, when heterozygous *Fut8*<sup>+/-</sup> mice were given L-fucose prior to partial hepatectomies, those that received L-Fucose saw dramatically accelerated liver regeneration.<sup>19</sup> This likely occurred through increased salvage-dependent synthesis of GDP-fucose. We had previously tested the effects of supplementing tissue culture medium with L-fucose on *FUT8*-CDG fibroblasts, but we saw no increase in total fucosylation.<sup>9</sup> We considered L-fucose supplementation with CDG-0096 since he had a missense variant that could potentially have some residual activity. However, total N-glycan analysis of serum showed that this individual was not capable of synthesising any detectable core fucosylation (Figure 3). Providing fucose could potentially create a neo-antigen specific for that individual and could precipitate a severe immunological response. The family and physicians decided the risks outweighed the potential benefits of fucose supplementation.

In summary, *FUT8*-CDG is an extremely rare metabolic disorder with only three documented cases who present with a multitude of symptoms including IUGR, severe delays in growth and development, severe neurological impairments, significantly shortened limbs, respiratory complications, and decreased lifespan. Here, we present on an additional four unrelated affected individuals to expand both the molecular and clinical knowledge for this disorder and highlight the usefulness of a reliable serum biomarker for confirming *FUT8*-CDG cases.

## ACKNOWLEDGEMENTS

We would like to thank all the families for their continued support and for providing valuable biological specimens. This work is supported by The Rocket Fund and The Bella Conneran Foundation, National Institutes of Health (NIH) grants R01DK099551 (to H.H.F). SPR is supported by Curekids (NZ) and Genomics Aotearoa. This paper is dedicated to the memory of Bella Conneran.

## CONFLICT OF INTEREST

Bobby G. Ng, Hassan Dastsooz, Mohammad Silawi, Parham Habibzadeh, Shima Bahram Jahan, Mohammad Ali Farazi Fard, Benjamin Halliday, Kimiyo Raymond, Maura R. Z. Ruzhnikov, Zahra Tabatabaei, Afsaneh Taghipour-Sheshdeh, Elise Brimble, Stephen P. Robertson, Mohammad Ali Faghihi and Hudson H. Freeze declare that they have no conflict of interest.

## ROLE FOR EACH CONTRIBUTING AUTHOR

B.N. performed experiments and drafted manuscript. H.D., M.S., and M.A.F. performed NGS data analysis of CDG-0095 and drafted manuscript. H.D., M.S., P.H., S.B.J., M.A.F.F., M.R., E.B., Z.T., S.R., A.T.S., M.A.F. provided clinical evaluations and drafted manuscript. B.H. provides bioinformatic analysis of whole-genomes sequence data for CDG-0099. K.R. performed MALDI-TOF/TOF-MS analysis and interpretation. H.F. supervised and drafted manuscript.

## ETHICAL APPROVAL AND INFORMED CONSENT

All procedures followed were in accordance with the ethical standards of the responsible committee on human experimentation (institutional and national) and with the Helsinki Declaration of 1975, as revised in 2000 (5). Informed consent was obtained from all patients for being included in the study. Sanford Burnham Prebys Medical Discovery Institute (IRB-2014-038-17).

## ANIMAL RIGHTS

This article does not contain any studies with animal subjects.

## ORCID

Bobby G. Ng  <https://orcid.org/0000-0003-0649-848X>

## REFERENCES

1. Chang IJ, He M, Lam CT. Congenital disorders of glycosylation. *Ann Transl Med.* 2018;6:477. <https://doi.org/10.21037/atm.2018.10.45>.
2. Pascoal C, Francisco R, Ferro T, Dos Reis FV, Jaeken J, Videira PA. CDG and immune response: from bedside to bench and back. *J Inherit Metab Dis.* 2019;43:90-124. <https://doi.org/10.1002/jimd.12126>.

3. Schneider M, Al-Shareffi E, Haltiwanger RS. Biological functions of fucose in mammals. *Glycobiology*. 2017;27:601-618. <https://doi.org/10.1093/glycob/cwx034>.
4. Yurchenco PD, Atkinson PH. Fucosyl-glycoprotein and precursor pools in HeLa cells. *Biochemistry*. 1975;14:3107-3114. <https://doi.org/10.1021/bi00685a011>.
5. Richards WL, Serif GS. Canine thyroid fucokinase. *Biochim Biophys Acta*. 1977;484:353-367. [https://doi.org/10.1016/0005-2744\(77\)90091-2](https://doi.org/10.1016/0005-2744(77)90091-2).
6. Smith PL, Myers JT, Rogers CE, et al. Conditional control of selectin ligand expression and global fucosylation events in mice with a targeted mutation at the FX locus. *J Cell Biol*. 2002;158:801-815. <https://doi.org/10.1083/jcb.200203125>.
7. Lu L, Hou X, Shi S, Korner C, Stanley P. Slc35c2 promotes Notch1 fucosylation and is required for optimal notch signaling in mammalian cells. *J Biol Chem*. 2010;285:36245-36254. <https://doi.org/10.1074/jbc.M110.126003>.
8. Puglielli L, Hirschberg CB. Reconstitution, identification, and purification of the rat liver golgi membrane GDP-fucose transporter. *J Biol Chem*. 1999;274:35596-35600. <https://doi.org/10.1074/jbc.274.50.35596>.
9. Ng BG, Xu G, Chandy N, et al. Biallelic mutations in FUT8 cause a congenital disorder of glycosylation with defective Fucosylation. *Am J Hum Genet*. 2018;102:188-195. <https://doi.org/10.1016/j.ajhg.2017.12.009>.
10. Ihara H, Ikeda Y, Toma S, et al. Crystal structure of mammalian alpha1,6- fucosyltransferase, FUT8. *Glycobiology*. 2007;17:455-466. <https://doi.org/10.1093/glycob/cwl079>.
11. Agrawal P, Fontanals-Cirera B, Sokolova E, et al. A systems biology approach identifies FUT8 as a driver of melanoma metastasis. *Cancer Cell*. 2017;31:804-819. <https://doi.org/10.1016/j.ccell.2017.05.007>.
12. Fujii H, Shinzaki S, Iijima H, et al. Core fucosylation on T cells, required for activation of T-cell receptor signaling and induction of colitis in mice, is increased in patients with inflammatory bowel disease. *Gastroenterology*. 2016;150:1620-1632. <https://doi.org/10.1053/j.gastro.2016.03.002>.
13. Lu X, Zhang D, Shoji H, et al. Deficiency of alpha1,6-fucosyltransferase promotes neuroinflammation by increasing the sensitivity of glial cells to inflammatory mediators. *Biochim Biophys Acta Gen Subj*. 2019;1863:598-608. <https://doi.org/10.1016/j.bbagen.2018.12.008>.
14. Tu CF, Wu MY, Lin YC, Kannagi R, Yang RB. FUT8 promotes breast cancer cell invasiveness by remodeling TGF-beta receptor core fucosylation. *Breast Cancer Res*. 2017;19:111. <https://doi.org/10.1186/s13058-017-0904-8>.
15. Wang X, Inoue S, Gu J, et al. Dysregulation of TGF-beta1 receptor activation leads to abnormal lung development and emphysema-like phenotype in core fucose-deficient mice. *Proc Natl Acad Sci USA*. 2005;102:15791-15796. <https://doi.org/10.1073/pnas.0507375102>.
16. Marquardt T, Luhn K, Srikrishna G, Freeze HH, Harms E, Vestweber D. Correction of leukocyte adhesion deficiency type II with oral fucose. *Blood*. 1999;94:3976-3985.
17. Xia B, Asif G, Arthur L, et al. Oligosaccharide analysis in urine by maldi-tof mass spectrometry for the diagnosis of lysosomal storage diseases. *Clin Chem*. 2013;59:1357-1368. <https://doi.org/10.1373/clinchem.2012.201053>.
18. Kamio K, Yoshida T, Gao C, et al. alpha1,6-Fucosyltransferase (Fut8) is implicated in vulnerability to elastase-induced emphysema in mice and a possible non-invasive predictive marker for disease progression and exacerbations in chronic obstructive pulmonary disease (COPD). *Biochem Biophys Res Commun*. 2012;424:112-117. <https://doi.org/10.1016/j.bbrc.2012.06.081>.
19. Wang Y, Fukuda T, Isaji T, et al. Loss of alpha1,6-fucosyltransferase suppressed liver regeneration: implication of core fucose in the regulation of growth factor receptor-mediated cellular signaling. *Sci Rep*. 2015;5:8264. <https://doi.org/10.1038/srep08264>.
20. Fukuda T, Hashimoto H, Okayasu N, et al. Alpha1,6-fucosyltransferase-deficient mice exhibit multiple behavioral abnormalities associated with a schizophrenia-like phenotype: importance of the balance between the dopamine and serotonin systems. *J Biol Chem*. 2011;286:18434-18443. <https://doi.org/10.1074/jbc.M110.172536>.

## SUPPORTING INFORMATION

Additional supporting information may be found online in the Supporting Information section at the end of this article.

**How to cite this article:** Ng BG, Dastsooz H, Silawi M, et al. Expanding the molecular and clinical phenotypes of FUT8-CDG. *J Inherit Metab Dis*. 2020;43:871–879. <https://doi.org/10.1002/jimd.12221>