

AperTO - Archivio Istituzionale Open Access dell'Università di Torino

**A preliminary analysis of late structural failures of the Navion stent graft in the treatment of descending thoracic aortic aneurysms**

**This is the author's manuscript**

*Original Citation:*

*Availability:*

This version is available <http://hdl.handle.net/2318/1797262> since 2021-08-17T21:52:46Z

*Published version:*

DOI:10.1016/j.jvs.2021.04.018

*Terms of use:*

Open Access

Anyone can freely access the full text of works made available as "Open Access". Works made available under a Creative Commons license can be used according to the terms and conditions of said license. Use of all other works requires consent of the right holder (author or publisher) if not exempted from copyright protection by the applicable law.

(Article begins on next page)

# A preliminary analysis of late structural failures of the Navion stent graft in the treatment of descending thoracic aortic aneurysms

Fabio Verzini, MD, PhD, FEBVS,<sup>a</sup> Enrico Cieri, MD, PhD,<sup>b</sup> Andrea Kahlberg, MD,<sup>c</sup> Yaron Sternbach, MD,<sup>d</sup> Robin Heijmen, MD, PhD,<sup>e</sup> Kenneth Ouriel, MD,<sup>f</sup> Sam Robaina, MS,<sup>g</sup> and Ali Azizzadeh, MD, FACS,<sup>h</sup> Turin, Perugia, and Milan, Italy; Albany and New York, NY; Nieuwegein, The Netherlands; and Santa Rosa and Los Angeles, Calif

## ABSTRACT

**Objective:** Patients in the Valiant Evo U.S. and international clinical trials had positive short-term outcomes; however, late structural failures, including type IIIb endoleaks have been recently discovered. Type IIIb endoleaks are serious adverse events because the repressurization of the aneurysm sac increases the risk of rupture. The purpose of the present study was to detail the imaging patterns associated with the structural failures with the aim of increasing awareness of failing graft presentation, early recognition, and prompt treatment.

**Methods:** The Valiant Evo clinical trial was a prospective, single-arm investigation of a thoracic stent graft system. With the recent late structural failures, sites were requested to submit all available imaging studies to date to allow the core laboratory to assess for structural failures such as type IIIb endoleaks, stent ring fractures, and stent ring enlargement. Of the 100 patients originally enrolled in the trial from 2016 to 2018, the core laboratory assessed the imaging studies performed at  $\geq 1$  year for 83 patients.

**Results:** No structural failures of the graft were reported through 1 year of follow-up. At 1 to 4 years, graft structural failures were detected in 11 patients with descending thoracic aortic aneurysms. Of the 11 patients, 5 had a type IIIb endoleak. Four of the five had imaging findings showing stent fractures consistent with the location of the graft seam and one had a type IIIb endoleak attributed to calcium erosion with no stent fracture or ring enlargement. Of the four patients with stent fracture in line with the graft seam, three underwent a relining procedure that successfully excluded the type IIIb endoleak. One of these three patients died 4 days later of suspected thoracic aortic rupture because the distal thoracic endovascular aortic repair extension had been landed in a previously dissected and fragile section of the aorta. The remaining six patients had had stent ring enlargement. One of the six patients had had persistent aneurysm expansion from the time of implantation onward and had died of unknown causes. The remaining five patients have continued to be monitored.

**Conclusions:** In the present preliminary analysis, the imaging patterns associated with type IIIb endoleaks, stent fractures, and stent ring enlargement appear to be related to the loss of seam integrity or detachment of the stent rings from the surface of the graft material. The imaging patterns we have detailed should be closely monitored using computed tomography angiography surveillance to allow structural failures to be promptly identified and treated. (J Vasc Surg 2021;■:1-10.)

**Keywords:** Endoleak; Stent graft fracture; TEVAR; Thoracic aneurysm; Thoracic endovascular aortic repair; Thoracic stent graft; Type IIIb endoleak

The Valiant Navion thoracic stent graft system (Medtronic Inc, Santa Rosa, Calif) was designed with improved conformability and a lower profile, and the patient outcomes through the 30-day and 1-year points have

generally been positive.<sup>1,2</sup> Recently, however, unexpected late structural failures of the stent graft have been observed in the Valiant Evo U.S. and international clinical trials (ClinicalTrials.gov identifiers, NCT02625324 and

From the Unit of Vascular Surgery, Department of Surgical Sciences, University of Turin, Turin<sup>a</sup>; the Department of Vascular and Endovascular Surgery, University of Perugia, Perugia<sup>b</sup>; the Department of Vascular Surgery, Vita-Salute University, San Raffaele Scientific Institute, Milan<sup>c</sup>; the Department of Vascular Surgery, St. Peter's Health Partners, Albany Medical College, Albany<sup>d</sup>; Department of Cardiothoracic Surgery, St. Antonius Hospital, Nieuwegein<sup>e</sup>; the Syntactx, New York<sup>f</sup>; the Medtronic Inc, Santa Rosa<sup>g</sup>; and the Division of Vascular Surgery, Cedars-Sinai Medical Center, Los Angeles.<sup>h</sup>

The Valiant EVO US and international clinical trials (ClinicalTrials.gov identifiers, NCT02625324 and NCT02652949) were funded by Medtronic, Inc, Santa Rosa, Calif.

Clinical Trial Registration: NCT02625324 and NCT02652949.

Author conflict of interest: F.V.'s institution receives consultancy fees from Medtronic Inc. R.H. is a consultant for Medtronic Inc. K.O. is an employee of Syntactx, which receives funding from Medtronic Inc. S.R. is an employee of Medtronic Inc. E.C., A.K., Y.S., and A.A. have no conflicts of interest.

Presented in part at the 2021 Charing Cross International Symposium, London, United Kingdom, April 19-22, 2021.

Additional material for this article may be found online at [www.jvascsurg.org](http://www.jvascsurg.org). Correspondence: Fabio Verzini, MD, PhD, FEBVS, Unit of Vascular Surgery, Department of Surgical Sciences, University of Turin, A.O.U. Città della Salute e della Scienza, Corso Dogliotti 14, Turin 10126, Italy (e-mail: [fabio.verzini@unito.it](mailto:fabio.verzini@unito.it)).

The editors and reviewers of this article have no relevant financial relationships to disclose per the JVS policy that requires reviewers to decline review of any manuscript for which they may have a conflict of interest.

0741-5214

Copyright © 2021 The Authors. Published by Elsevier Inc. on behalf of the Society for Vascular Surgery. This is an open access article under the CC BY license (<http://creativecommons.org/licenses/by/4.0/>).

<https://doi.org/10.1016/j.jvs.2021.04.018>

NCT02652949).<sup>3</sup> In response to these adverse events, the manufacturer decided to issue a voluntary global recall of the device in February 2021.

Stent graft failure modes can generally be grouped into fractures of the metallic stent rings, suture breakage, and other causes of fabric wear.<sup>4</sup> Cyclical movement of the metal stents due to the pulsatile environment can lead to fatigue stress and fracture<sup>4,5</sup>; however, the occurrence of stent fractures has been rare with modern grafts.<sup>6,7</sup> The sutures in the graft can also fail by creating micro-leakage where the suture penetrates the fabric,<sup>8</sup> or a broken suture can lead to detachment of a stent ring<sup>9,10</sup> or fabric disruption if the suture had joined two edges of the fabric. Finally, fabric wear can occur from excessive manipulation during implantation or balloon dilation or the presence of calcification.<sup>11-13</sup>

Identifying structural failures of a graft is imperative because failure can be associated with type IIIb endoleaks. Type IIIb endoleaks after thoracic endovascular aortic repair (TEVAR) are rare but have been documented in a few case reports.<sup>14,15</sup> Even with abdominal endovascular aneurysm repair, both randomized control trials and large multicenter registries of current generation stent grafts have reported rates <2%.<sup>11,16</sup> Although uncommon, type IIIb endoleaks are serious adverse events because they result in blood flow back into the aneurysm sac, resulting in a significant risk of rupture.<sup>16,17</sup> When diagnosed, a type IIIb endoleak can generally be successfully treated by relining the device.<sup>18,19</sup> In the present report, we have summarized the recurring patterns in the imaging studies of patients with Navion stent graft failure with the aim of increasing physician awareness in the identification of possible failure modes, early recognition, and prompt treatment.

## METHODS

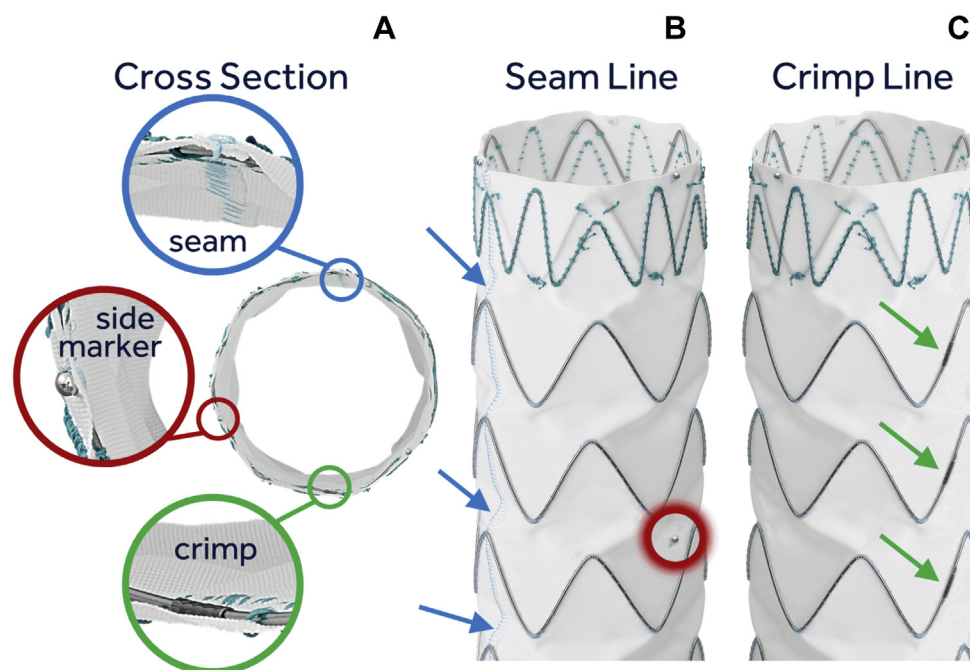
**Trial design and clinical and imaging follow-up extension.** The patients identified with type IIIb endoleaks and other imaging findings were a part of the Valiant Evo U.S. and international clinical trials (ClinicalTrials.gov identifiers, NCT02625324 and NCT02652949). In brief, the trials were prospective, single-arm investigations of the Valiant Navion stent graft system for the treatment of pathologies, including descending thoracic aortic aneurysms (DTAAs) and penetrating atherosclerotic ulcers. More details on the trial design and the 30-day and 1-year outcomes have been previously reported.<sup>1,2</sup> All the sites conducted the study in accordance with the clinical investigation protocol and received institutional review board or ethics committee approval, as applicable. All the patients in the trials provided written informed consent, and the trials were compliant with the Declaration of Helsinki (October 2013) and the laws and regulations of the countries in which the clinical trials were conducted.

## ARTICLE HIGHLIGHTS

- **Type of Research:** A multicenter, prospective, non-randomized trial
- **Key Findings:** Eleven patients with a descending thoracic aortic aneurysm from the Valiant EVO clinical trial were identified with structural failure in their thoracic stent grafts. Five patients had experienced type IIIb endoleaks, with four having stent fractures and loss of seam integrity, and six patients had stent ring enlargements.
- **Take Home Message:** Late structural failures were identified with the thoracic stent graft in the Valiant Evo clinical trial. These can present as type IIIb endoleaks, stent fractures, and stent ring enlargement. Lifelong surveillance using computed tomography angiography is important to allow structural failures to be promptly identified and appropriately treated.

The trials were originally designed with clinical and imaging follow-up, including independent core laboratory analysis (Syntactx, New York, NY) through 1 year. A total of 100 patients were enrolled between April 2016 and March 2018. With the recent observations of type IIIb endoleaks, the sponsor initiated an investigation in which all sites were asked to submit their follow-up imaging studies beyond 1 year to the core laboratory for review, including from patients who had withdrawn from the study. The request for the retrospective imaging review was made possible in the United States under a Health Insurance Portability and Accountability Act exception, given the urgency to assess patient safety, and was communicated to the related institutional review boards through the unanticipated adverse device effects letter. For the sites outside the United States, the unanticipated serious adverse device effects letter sent to the ethics committees included language regarding the core laboratory review of imaging studies from all the study patients in the interest of patient safety and specified how data privacy would be ensured for the patients who had withdrawn from the trial.

**Valiant Navion thoracic stent graft design and relevance to imaging findings.** The Valiant Navion stent graft is constructed from a sheet of multifilament polyester sewn into a cylindrical shape, resulting in a seam line running along the length of the graft (Fig 1). The graft also has a series of stent rings that are formed by joining two ends of a stent ring with a cylindrical crimp sleeve. The stent rings are formed at a larger diameter (~20%) than that of the graft fabric diameter and sewn to the outer surface of the graft fabric such that the crimp sleeve on each stent ring is oriented ~180° from the seam line (Fig 1).



**Fig 1.** **A**, Construction of the Valiant Navion stent graft with the cross-section view showing the stent rings sewn with the crimps located  $\sim 180^\circ$  from the graft seam. Also, a radiopaque side marker is nearly equidistant between the seam and crimps (red circle). **B**, View of a graft with the seam running down the length of the graft (blue arrows). **C**, View showing a line of crimps on the other side of the graft (green arrows).

The stent graft has three radiopaque proximal markers placed  $120^\circ$  from each other at the proximal end of the fabric. One radiopaque side marker is sewn between the third and fourth stent rings, with two radiopaque markers at the distal end of the fabric. Both the side marker and the crimps can be identified using high contrast-enhanced computed tomography (CT) or radiography. Together, they can be used to determine the location of the seam because the side marker is approximately equidistant between the crimps and the seam.

**Core laboratory image analysis.** All core laboratory reviews were performed on fully de-identified images. The core laboratory assessed the images for evidence of type IIIb endoleaks, stent ring fractures, and stent ring enlargement, which were required to meet the following criteria:

- Type IIIb endoleak: defined as blood flow through a fabric disruption with confirmation with CT angiography (CTA)
- Stent fracture: stents were considered fractured if a visible gap was present in the ring, with confirmation by CT or radiography
- Stent ring enlargement: defined as an increase of the diameter of a nitinol stent ring  $>1$  mm of the nominal graft diameter as measured by CT; the most conservative threshold was chosen to detect all possible events, with the understanding that false-positive results could also be identified

## RESULTS

Through 1 year, no structural failures or type IIIb endoleaks were detected.<sup>2</sup> Of the 100 patients originally enrolled, the core laboratory assessed the imaging studies at  $\geq 1$  year for 83 patients, including some patients who had withdrawn from the clinical trials. Through the retrospective core laboratory review, four patients who had been treated for a DTAA were identified with late type IIIb endoleaks concomitant with stent fracture and stent ring enlargement detected 36 to 49 months after the initial TEVAR implantation (Table I). Two of the four patients were asymptomatic and had undergone a complete relining procedure that successfully excluded their endoleak. One of the four patients was asymptomatic and the reintervention had been scheduled. Patient 1 underwent a relining procedure that successfully excluded the type IIIb endoleak; however, the patient died 4 days later. According to the investigator review, the death was likely secondary to aortic rupture at the level of the distal TEVAR extension, which had been landed in a previously dissected aortic segment. However, the cause of death could not be confirmed because the family refused an autopsy.

Patient 5 did not have any stent fractures but experienced a type IIIb endoleak that the core laboratory suspected had resulted from fabric wear near a region of calcification. The patient underwent a successful secondary procedure to treat the type IIIb endoleak but died 3 months later of non-aortic-related causes.

**Table I.** Core laboratory–reported baseline characteristics and outcomes of subjects with imaging findings

Pt. No.	Age, Sex	Age, years	Aneurysm type	MAD at 1 month, mm	Imaging finding <sup>a</sup>	Timing of imaging finding, months	MAD at imaging, mm	Sac increase at imaging	Secondary procedures to treat imaging findings
1	M	66	Fusiform	63	Type IIIb endoleak Fracture (multiple) Ring enlargement	44 41 41	69 61 61	Yes No No	Relining with three Navion stent grafts
2	M	60	Fusiform	63	Type IIIb endoleak Fracture Ring enlargement	43 27 27	69 64 64	Yes No No	Carotid to carotid bypass 1 week before complete relining <sup>b</sup>
3	F	65	Fusiform	70	Type IIIb endoleak Fracture (multiple) Ring enlargement	36 36 26	73 73 68	No No No	Relining <sup>b</sup>
4 <sup>c</sup>	F	74	Fusiform	58	Type IIIb endoleak Fracture (multiple) Ring enlargement	49 49 49	59 59 59	No No No	Scheduled for additional imaging and endovascular reintervention <sup>b</sup>
5 <sup>c</sup>	F	74	Saccular	53	Type IIIb endoleak	34	85	Yes	Relining <sup>b</sup>
6 <sup>c</sup>	M	68	Fusiform	73	Ring enlargement	9	89	Yes	NA
7	F	68	Saccular	63	Ring enlargement	24	47	No	None
8	F	72	Fusiform	61	Ring enlargement	12	56	No	None
9	M	76	Fusiform	64 <sup>d</sup>	Ring enlargement	39	58	No	None
10 <sup>c</sup>	F	77	Fusiform	62	Ring enlargement <sup>e</sup>	53	56	No	NA
11 <sup>c</sup>	M	84	Fusiform	66	Ring enlargement	47	72	Yes	NA

F, Female; M, male; MAD, maximum aneurysm diameter; NA, not applicable; Pt. No., patient number.

<sup>a</sup>Type IIIb endoleak, fracture, and/or ring enlargement.

<sup>b</sup>Information on secondary procedures determined from site and/or investigator communication because the information was not entered in the database.

<sup>c</sup>Subject withdrew from the study and did not provide consent for long-term follow-up in the trial; thus, data >1 year were either not available or reported from site and/or investigator communication instead of the clinical study electronic case report form for these subjects.

<sup>d</sup>Subject 9 did not have 1-month imaging studies available; thus, we reported the preprocedure imaging measurement.

<sup>e</sup>Officially reported by the core laboratory as ring deformation owing to an inability to locate the peaks to measure ring enlargement, although both the core laboratory and the investigators reviewed imaging studies and believe the findings indicate ring enlargement.

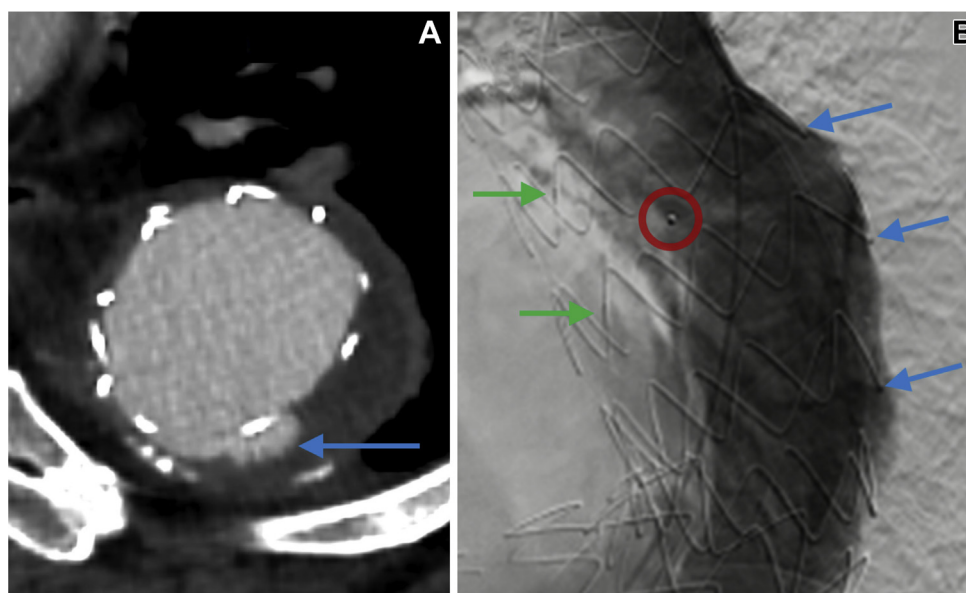
Finally, six patients with a DTAA were identified with stent ring enlargement without any stent fracture or type IIIb endoleak. The stent ring enlargements measured by the core laboratory were all beyond the margin of error that could have resulted from imaging modality limitations or interobserver variability. Patient 6 underwent successful reintervention for type Ia and Ib endoleaks within the first year,<sup>2</sup> and the core laboratory reported no endoleaks after the secondary procedure. However, patient 6 experienced had persistent aneurysm expansion and died of unknown causes. The other five patients have continued to be monitored without reinterventions planned. None of the patients treated for a penetrating atherosclerotic ulcer presented with signs of structural failure of the graft at the last follow-up examination.

**Patient 1 (type IIIb endoleak, stent fractures along seam line, stent ring enlargement).** Patient 1 was a 66-year-old man and had a saccular DTAA with a diameter of 59 mm. The patient was treated with a Valiant Navion stent graft (40 mm, 40 mm, 225 mm) successfully

advanced and deployed in zone 4. The completion angiography showed a type Ib and type II endoleak that was resolved by balloon dilation. One day later, the patient presented with acute back pain. The CTA scan revealed a focal aortic dissection at the distal end of the graft that extended distally for 4.6 cm. The stent graft still appeared to be positioned normally, without a sign of an endoleak. Because the patient's pain resolved without further treatment, he was discharged 10 days after procedure.

The patient was admitted 44 months after the index procedure for acute left chest pain. CTA showed a type IIIb endoleak (Fig 2, A) and an aneurysm sac increase of >1 cm. Angiography confirmed blood flow outside of what should have been the cylindrical stent graft boundary (Fig 2, B). A secondary procedure was performed to reline the graft, and the type IIIb endoleak was successfully excluded with no evidence of any endoleaks. Four days after the secondary procedure, the patient was found unresponsive after an episode of left flank pain and pronounced dead, with the family refusing an autopsy. A retrospective review of the imaging studies





**Fig 2.** Patient 1. **A**, Computed tomography angiography (CTA) at 44 months after treatment showing contrast outside the stent graft profile (*blue arrow*) indicative of a type IIIb endoleak. **B**, Angiogram showing the side marker (*red circle*) identified and crimps evident along the inner curvature (*green arrows*). These findings indicate the graft seam is on the outer curvature and coincident with the location of the fractured stents (*blue arrows*).

determined that the aortic rupture was likely related to placement of the distal TEVAR extension device in a previously dissected and fragile portion of the aorta (Supplementary Fig 1, online only).

From the combination of CTA scans and angiography, it was evident that the stent graft fractures coincided with the location of the seam line of the graft. On the angiogram (Fig 2, B), the side marker was identified in the middle of the aorta, with the crimps visible along the inner curvature. This confirmed that the seam line was on the outer curvature where the stents had fractured. The three-dimensional CTA reconstructions (Fig 3), performed between 24 and 41 months after the index procedure, showed that four stent rings had fractured, with an additional stent ring fracture that occurred between 41 and 44 months. Stent ring enlargement had occurred as early as 24 months after initial treatment.

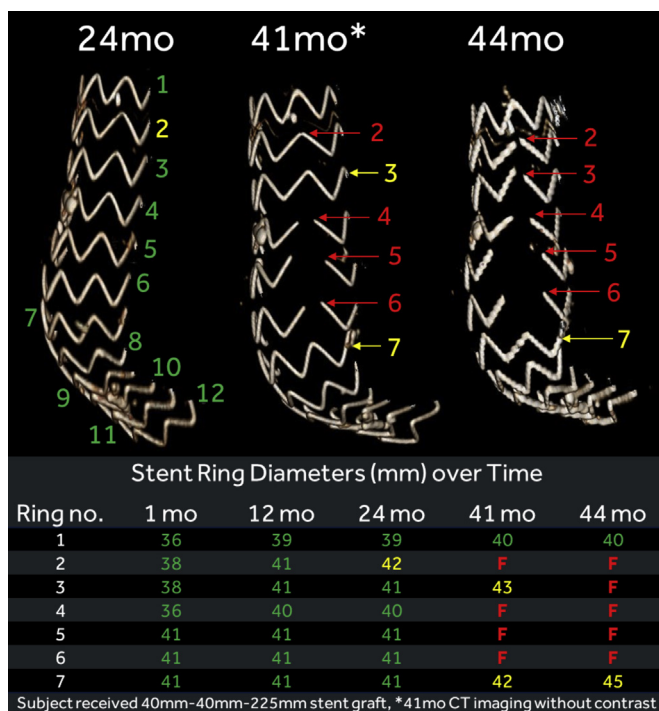
**Patient 3 (type IIIb endoleak, stent fractures along seam line, stent ring enlargement).** The details and images from patient 3 are shown in Supplementary Fig 2 (online only).

**Patient 4 (type IIIb endoleak, distal stent fractures along seam line, stent ring enlargement).** Patient 4 was a 74-year-old woman with a fusiform DTAA with a diameter of 56 mm. The patient was implanted with two Valiant Navion stent grafts (proximal device, 34 mm, 34 mm, 225 mm; distal device, 43 mm, 43 mm, 175 mm) with a zone 3 proximal landing. The patient tolerated the procedure well and was discharged in 2 days. The CTA

imaging studies at 1 and 12 months showed that the distance between the distal end of the graft and the distal edge of the celiac artery had increased by 17 mm (from 19 mm to 36 mm; Fig 4, A and B). The core laboratory did not consider this a distal migration owing to the corresponding increase in the centerline length of the thoracic aorta.

At 49 months, the patient had new findings of pulmonary malignancy and was referred for further evaluation. In the 49-month imaging study (Fig 4, C), stent rings 9, 10, and 11 of the distal graft were found to have fractured, coincident with the location of the graft seam line. The findings were further confirmed by the 51-month chest radiograph (Fig 4, D). Because the patient elected to undergo partial pneumonectomy and adjuvant therapy, reintervention for the stent fractures and type IIIb endoleak was deferred. At the last follow-up visit, the patient was scheduled for additional imaging studies and a planned endovascular reintervention.

**Patient 11 (single stent ring enlargement).** Patient 11 was an 84-year-old man with a fusiform DTAA with a diameter of 60 mm. The patient had two Valiant Navion stent grafts placed with the proximal device (43 mm, 43 mm, 225 mm) landed in zone 3 and the distal device (46 mm, 46 mm, 175 mm) in zone 4. The patient tolerated the procedure well and was discharged in 2 days. Between 12 and 48 months, stent ring enlargement was suspected because, although the flow was contained within the boundary of the stent fabric, a focal stent ring detachment from the fabric on the upper edge was



**Fig 3.** Patient 1. Three-dimensional computed tomography angiography (CTA) reconstructions over time with the stent rings numbered starting from the proximal end of the graft and showing no stent fractures at 24 months. At 41 months, four stent fractures (red numbers) were found, coincident with the seam line, with an additional stent fracturing by 44 months. The individual stent ring diameters over time showed ring enlargement (yellow numbers) as early as 24 months.

observed (Fig 5). The patient was asymptomatic with no detected endoleaks, and further monitoring was planned.

## DISCUSSION

Type IIIb endoleaks are serious adverse events owing to repressurization of the aneurysm sac, which puts patients at an increased risk of rupture.<sup>16</sup> In the literature, the incidence of type IIIb endoleaks has been reported to be <2%.<sup>11,16</sup> At the time of the present analysis of the Valiant Evo clinical trial, five patients had been identified with late type IIIb endoleaks. Four of these patients had stent fractures coincident with the seam and the fifth endoleak was attributed to calcium erosion. The observations of stent fractures and type IIIb endoleaks led the manufacturer to initiate a voluntary global recall of the Navion devices in the interest of patient safety.

Although type IIIb endoleaks require immediate attention, the existing data have shown that type IIIb endoleaks can often be successfully treated endovascularly.<sup>20-22</sup> At the time of our report, four patients had undergone a relining procedure, and all reinterventions had successfully sealed the type IIIb

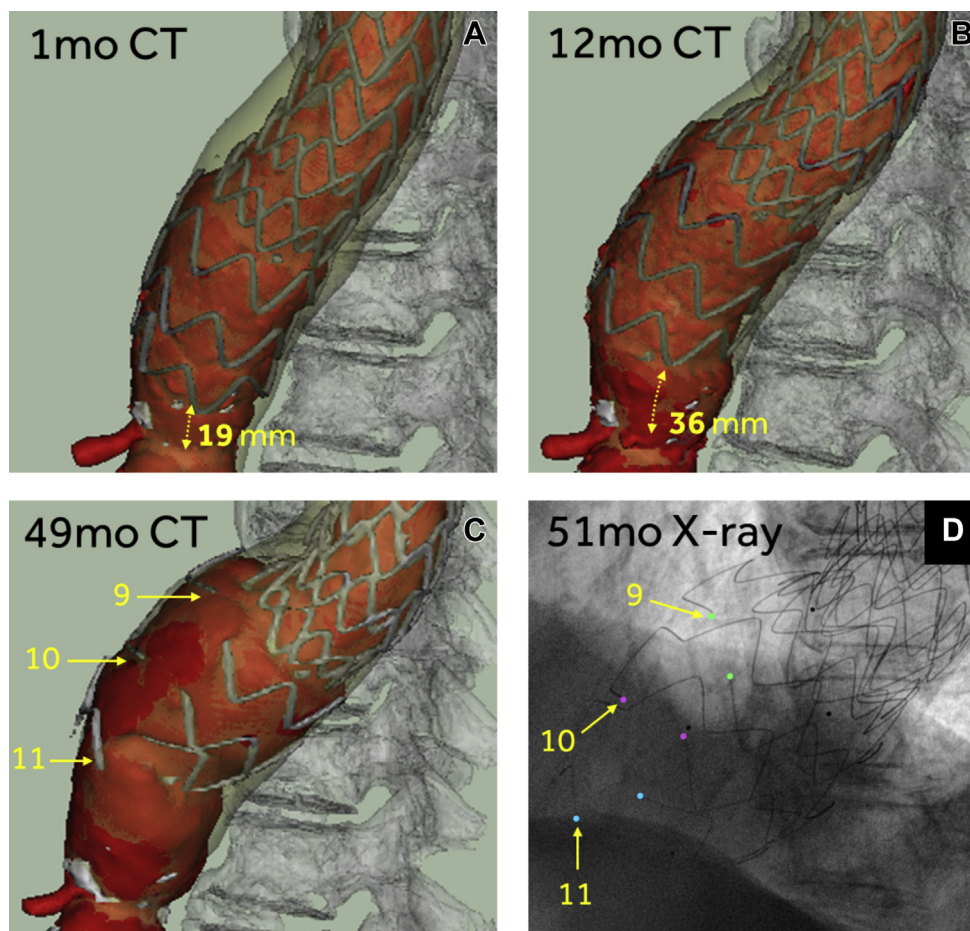
endoleak. However, for patient 1, the distal end of the relining graft might have induced aortic rupture, because the distal landing was in a previously dissected and fragile aortic segment (Supplementary Fig 1, online only).

The multiple stent fractures in line with the seam was a different pattern from the typical description of stent ring fractures from case reports of other grafts.<sup>4,10,23</sup> From this image analysis, one could hypothesize that the finding of stent fractures along the same longitudinal line as the seam, opposite the stent crimps, is highly suspicious for the loss of integrity of the seam. A significant loss of seam integrity might allow for unanticipated loading and/or displacement of the stent rings, which might, in turn, result in an increased risk of stent ring fracture. Although previous reports have also concluded that excessive mechanical stress can make stent rings more prone to failure,<sup>23,24</sup> this does not explain the cause of the loss of seam integrity, which is still under investigation.

Stent ring enlargement was also identified as a failure mode in our retrospective analysis and believed to result from detachment of the stent from the surface of the graft material. Although it is not common practice to measure stent ring enlargement, we would emphasize the importance of assessing the stent ring sizes along the length of the graft from the cross-sectional CT images (Fig 5). The detachment of stent rings from grafts after suture breakage has been previously reported with other grafts,<sup>9,10,20</sup> and the additional movement of a detached ring could result in stent fracture.<sup>23,24</sup> Although no cause has been identified for stent ring enlargement, one possibility is the loss of suture fixation integrity. Because suture failure could lead to the development of endoleaks,<sup>10</sup> compliance with follow-up imaging recommended.

We would emphasize that the root cause analysis of the structural failures is still ongoing, and the results will be reported when available. A number of engineering design factors can contribute to structural failure, including the design, material, construction, and use of the component. Several different design elements, materials, and manufacturing methods are unique to the Valiant Navion device compared with those used in previous generations of devices such as the Valiant Captivia (Medtronic Inc). No cases of stent fracture or type IIIb endoleak were reported through 5 years in the VALOR II (the Valiant thoracic stent graft system clinical study),<sup>21</sup> Dissection,<sup>22</sup> and RESCUE (study to determine if the Valiant stent graft is safe and effective in treating patients who have a blunt thoracic aortic injury)<sup>25</sup> clinical trials with the Valiant Captivia device.

Strict adherence to lifelong surveillance with a minimum of annual CTA is important for the timely identification of any structural failure of stent grafts.<sup>26</sup> If a patient presents with a line of stent fractures, further



**Fig 4.** Patient 4. **A,B**, Three-dimensional computed tomography angiography (CTA) reconstruction showing the distance between the distal edge of the graft and distal edge of the celiac artery had increased by 17 mm by the 12-month imaging follow-up. The bottom three stent rings had fractured by the 49-month CTA study (**C**), and the fractured stents were also clear on the 51-month chest radiography (**D**).

interrogation is required to assess for type IIIb endoleaks. Strict imaging follow-up with CTA should be suggested for patients found with a single stent fracture without endoleaks and for patients identified with single stent ring enlargement. In accordance with the Society for Vascular Surgery guidelines,<sup>27,28</sup> lifelong surveillance is warranted because a single stent fracture and suture breakage can lead to fabric degradation over time.<sup>8,9</sup> Finally, a retrospective review of previous imaging studies might be beneficial because the patterns of graft failure we have described are difficult to assess and could be overlooked initially.

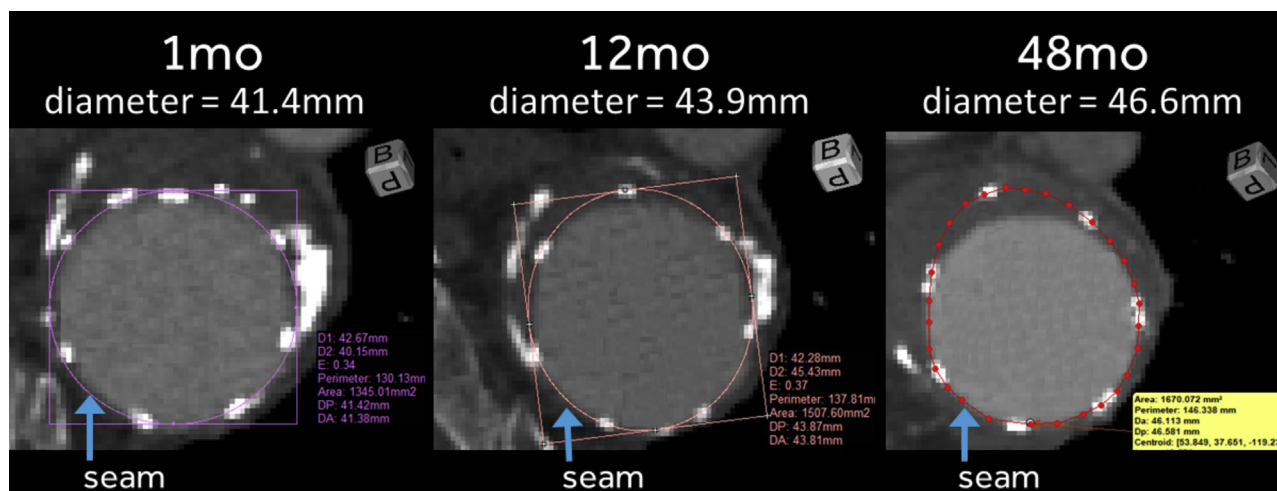
To detect these late graft structural failures (Table II), we would recommend high quality CTA imaging studies, and, ideally, the stent diameter should be sized in planes orthogonal to the graft's main longitudinal axis to assess for stent ring enlargement. Using these same images, the outside of the stent graft boundaries should be carefully examined for any presence of contrast. Moreover, three-dimensional reconstructions with the centerline should be obtained from CTA scans to identify stent breakage.<sup>5,23</sup> These can also be found by careful

evaluation of plain radiographs of the graft,<sup>31,32</sup> although overlapping stents can sometimes render the fractures difficult to ascertain. Although digital subtraction angiography is the most accurate method to differentiate the types of endoleaks, it is generally not used because it is invasive.<sup>33-35</sup>

The guidelines at present recommend treatment for type I and III endoleaks or type II endoleaks with aneurysm expansion.<sup>26,29,30</sup> If an endovascular aortic re-intervention is planned for any disease progression in a patient previously implanted with a Valiant Navion stent graft, we would suggest relining the previously treated areas, even without the diagnosis of other failures. In contrast to the reported data in which type IIIb endoleaks are often treated with spot relining using cuffs or limb extensions to exclude the endoleak,<sup>11,36</sup> we would suggest complete relining of the graft similar to the method used by Lemmon et al<sup>37</sup> to avoid future potential complications.

Finally, the distal seal has generally been discussed in the context of type Ib endoleaks.<sup>2,38,39</sup> However, reported studies have also suggested the loss of fixation and





**Fig 5.** Patient 11. Computed tomography angiography (CTA) showing stent ring enlargement that occurred between 12 and 48 months. The stent appears to have detached from the fabric, although this did not lead to a type IIIb endoleak. The nominal stent graft diameter was 43 mm; the seam location is marked by blue arrows.

**Table II.** Imaging recommendations for evaluation of stent graft structural failures

Complication to look for	Findings indicative of complication
Type IIIb endoleak	Retrospective review of previous imaging studies Lifelong surveillance with a minimum of annual high quality CTA imaging studies Further interrogation of any presence of contrast outside stent graft boundaries or irregular, noncircular lumen margins, which might indicate fabric defects in accordance with society guidelines <sup>26,29,30</sup>
Failure of stent rings or fabric seam	Retrospective review of previous imaging studies Lifelong surveillance with a minimum of annual high quality CTA imaging studies Sizing of stent diameters in planes orthogonal to the graft main longitudinal axis to assess for ring enlargement Careful evaluation of three-dimensional reconstructions or plain radiographs to identify stent fractures Identification of seam line using CT scans of visible crimps and radiopaque markers

CT, Computed tomography; CTA, computed tomography angiography.

migration will result in increased movement of the graft and fatigue stress on the stent rings.<sup>5,23</sup> Aortic elongation will be more pronounced at the distal end of the thoracic aorta,<sup>40,41</sup> and the morphologic changes in the anatomy will affect the structural integrity of grafts.<sup>2,4</sup> Furthermore, angulation is a well-discussed risk factor for graft migration and a compromised seal.<sup>42,43</sup> All these factors could have played a role in the structural failures seen in our patient 4. Consistent with the present guidelines, which recommend endovascular treatment of all type III endoleaks,<sup>26,29,30</sup> we believe it is imperative to have a good seal zones to minimize the risk of further complications.

**Study limitations.** One limitation of the present retrospective analysis was that the original trial protocol was concluded at 1 year. Thus, clinical information on secondary procedures and mortality was not available for patients who had withdrawn from the study despite the core laboratory assessing the images from 83 patients. Also, if the CT images are not orthogonal to the main axis of the graft, a margin of error will be

introduced into the calculation of the stent ring diameter. The 1-mm threshold beyond the nominal graft diameter as the definition for stent ring enlargement was conservatively chosen to identify all possible events, with the understanding that potential false-positive results would be found. Although a 1-mm threshold might be too strict a criterion to apply in the clinical setting because of imaging modality limitations or interobserver variability, stent ring enlargement resulting from detachment from the graft material can be expected to be >1 mm owing to the oversizing of the stent rings relative to the stent fabric. Likewise, without explanted devices to examine, the structural graft failures identified using the various imaging techniques could not be fully confirmed.

## CONCLUSIONS

In the present preliminary analysis, several late structural graft failures occurred in the Valiant Evo U.S. and international clinical trials. We have described the imaging patterns associated with the type IIIb endoleaks, stent fractures, and stent ring enlargements seen in the

present study and appear to be related to the loss of seam integrity or detachment of the stent rings from the surface of the graft fabric. In accordance with society guidelines,<sup>26-28</sup> lifelong surveillance for these imaging trends should be performed with CTA to allow structural failures to be promptly identified and treated. The complete understanding of the mechanisms of failure requires further investigation, which is underway.

The authors acknowledge the following persons from Medtronic Inc: Alessandro Marucchini, Brian Glynn, and Polina Rapoport for clinical and engineering expertise and Victoria Rendon and Ming-Jay Chow for their help in the preparation of our report.

### AUTHOR CONTRIBUTIONS

Conception and design: FV, EC, AK, YS, RH, KO, SR, AA

Analysis and interpretation: FV, KO, SR, AA

Data collection: FV, EC, AK, YS, RH, KO, SR, AA

Writing the article: FV, KO, AA

Critical revision of the article: FV, EC, AK, YS, RH, KO, SR, AA

Final approval of the article: FV, EC, AK, YS, RH, KO, SR, AA

Statistical analysis: Not applicable

Obtained funding: Not applicable

Overall responsibility: FV

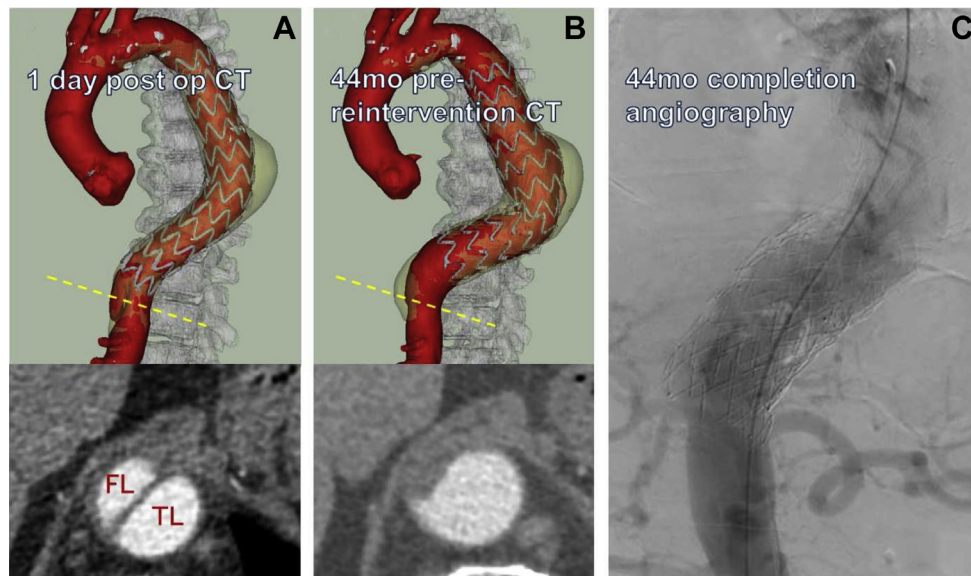
### REFERENCES

- Azizzadeh A, Desai N, Arko FR III, Panneton JM, Thaveau F, Hayes P, et al. Pivotal results for the Valiant Navion stent graft system in the Valiant Evo global clinical trial. *J Vasc Surg* 2019;70:1399-408.e1.
- Verzini F, Desai N, Arko FR III, Panneton JM, Thaveau F, Dagenais F, et al. Clinical trial outcomes and thoracic aorta morphometry after one year with the Valiant Navion stent graft system [e-pub ahead of print]. *J Vasc Surg*. <https://doi.org/10.1016/j.jvs.2021.01.047>. Accessed February 13, 2021.
- Chaikof EL, Blankensteijn JD, Harris PL, White GH, Zarins CK, Bernhard VM, et al. Reporting standards for endovascular aortic aneurysm repair. *J Vasc Surg* 2002;35:1048-60.
- Jacobs TS, Won J, Gravereaux EC, Faries PL, Morrissey N, Teodorescu VJ, et al. Mechanical failure of prosthetic human implants: a 10-year experience with aortic stent graft devices. *J Vasc Surg* 2003;37:16-26.
- Ueda T, Takaoka H, Petrovitch I, Rubin GD. Detection of broken sutures and metal-ring fractures in AneuRx stent-grafts by using three-dimensional CT angiography after endovascular abdominal aortic aneurysm repair: association with late endoleak development and device migration. *Radiology* 2014;272:275-83.
- Riambau V, Giudice R, Trabattoni P, Llagostera S, Fadda G, Lenti M, et al. Prospective multicenter study of the low-profile relay stent-graft in patients with thoracic aortic disease: the Regeneration study. *Ann Vasc Surg* 2019;58:180-9.
- Torsello GF, Inchingolo M, Austermann M, Torsello GB, Panuccio G, Bisdas T. Durability of a low-profile stent graft for thoracic endovascular aneurysm repair. *J Vasc Surg* 2017;66:1638-43.
- Bussmann A, Heim F, Delay C, Girsowicz E, Del Tatto B, Dion D, et al. Textile aging characterization on new generations of explanted commercial endoprosthesis: a preliminary study. *Eur J Vasc Endovasc Surg* 2017;54:378-86.
- Jones SM, Vallabhaneni SR, McWilliams RC, Naik J, Nicholas T, Fisher RK. Type IIIb endoleak is an important cause of failure following endovascular aneurysm repair. *J Endovasc Ther* 2014;21:723-7.
- Wanhainen A, Nyman R, Eriksson MO, Björck M. First report of a late type III endoleak from fabric tears of a Zenith stent graft. *J Vasc Surg* 2008;48:723-6.
- Maleux C, Poorteman L, Laenen A, Saint-Lèbes B, Houthoofd S, Fourneau I, et al. Incidence, etiology, and management of type III endoleak after endovascular aortic repair. *J Vasc Surg* 2017;66:1056-64.
- Dayama A, Tsilimparis N, Kasirajan K, Reeves JC. Late Gore Excluder endoprosthesis fabric tear leading to abdominal aortic aneurysm rupture 5 years after initial implant. *J Vasc Surg* 2013;57:221-4.
- Kwon J, Dimuzio P, Salvatore D, Abai B. Incidence of stent graft failure from type IIIb endoleak in contemporary endovascular abdominal aortic aneurysm repair. *J Vasc Surg* 2020;71:645-53.
- Uehara K, Inoue T, Matsuo J, Sasaki H, Matsuda H. Type IIIb endoleak from stent suture lines of a thoracic endograft. *J Vasc Surg Cases Innov Tech* 2019;5:214-7.
- Müller-Eschner M, Peters AS, Meisenbacher K, Böckler D, Bischoff MS. Type IIIb endoleak after thoracic endovascular aortic repair caused by endoanchor dislocation. *Ann Vasc Surg* 2015;29:1019.e7-1019.e10.
- Fujimura N, Ichihashi S, Matsubara K, Shibutani S, Harada H, Obara H, et al. Type IIIb endoleak is not extremely rare and may be underdiagnosed after endovascular aneurysm repair. *J Vasc Interv Radiol* 2019;30:1393-9.e1.
- Harris PL, Vallabhaneni SR, Desgranges P, Becquemin JP, van Marrewijk C, Laheij RJ. Incidence and risk factors of late rupture, conversion, and death after endovascular repair of infrarenal aortic aneurysms: the EUROSTAR experience. European Collaborators on Stent/graft techniques for aortic aneurysm repair. *J Vasc Surg* 2000;32:739-49.
- Bucci F, Fiengo L, Valerio N, Ferdani M. Late type IIIb endoleak after endovascular aneurysm repair: case report and review of the literature. *G Chir* 2011;32:329-33.
- Shao J, Zhang X, Chen Y, Zheng Y, Liu B. Endovascular repair of late type IIIb endoleak after endovascular aneurysm repair: a case report. *BMC Cardiovasc Disord* 2019;19:183.
- Leopardi M, Salerno A, Scarpelli P, Ventura M. Type III B endoleak leading to aortic rupture after endovascular repair: analysis of errors in follow up and treatment. *CVIR Endovasc* 2018;1:9.
- Conrad MF, Tucheck J, Freezor R, Bavaria J, White R, Fairman R. Results of the VALOR II trial of the Medtronic Valiant thoracic stent graft. *J Vasc Surg* 2017;66:335-42.
- Bavaria JE, Brinkman WT, Hughes GC, Shah AS, Charlton-Ouw KM, Azizzadeh A, et al. Five-year outcomes of endovascular repair of complicated acute type B aortic dissections [e-pub ahead of print]. *J Thorac Cardiovasc Surg*. <https://doi.org/10.1016/j.jtcvs.2020.03.162>. Accessed May 13, 2020.
- Roos JE, Hellinger JC, Hallet R, Fleischmann D, Zarins CK, Rubin GD. Detection of endograft fractures with multidetector row computed tomography. *J Vasc Surg* 2005;42:1002-6.
- Bashir MR, Ferral H, Jacobs C, McCarthy W, Goldin M. Endoleaks after endovascular abdominal aortic aneurysm repair: management strategies according to CT findings. *AJR Am J Roentgenol* 2009;192:W178-86.
- Patel HJ, Azizzadeh A, Matsumoto AH, Velazquez OC, Rovin JD, Lombardi JV, et al. Five-year outcomes from the United States pivotal trial of Valiant Captivia stent graft for blunt aortic injury. *Ann Thorac Surg* 2020;110:815-20.
- Chaikof EL, Dalman RL, Eskandari MK, Jackson BM, Lee WA, Mansour MA, et al. The Society for Vascular Surgery practice guidelines on the care of patients with an abdominal aortic aneurysm. *J Vasc Surg* 2018;67:2-77.e2.
- Upchurch GR Jr, Escobar GA, Azizzadeh A, Beck AW, Conrad MF, Matsumura JS, et al. Society for Vascular Surgery clinical practice guidelines of thoracic endovascular aortic repair for descending thoracic aortic aneurysms. *J Vasc Surg* 2021;73:55s-83s.
- Czerny M, Schmidli J, Adler S, van den Berg JC, Bertoglio L, Carrel T, et al. Current options and recommendations for the treatment of thoracic aortic pathologies involving the aortic arch: an expert consensus document of the European Association for Cardio-Thoracic surgery (EACTS) and the European Society for Vascular Surgery (ESVS). *Eur J Cardiothorac Surg* 2018;55:133-62.
- Erbel R, Aboyans V, Boileau C, Bossone E, Bartolomeo RD, Eggebrecht H, et al. 2014 ESC guidelines on the diagnosis and treatment of aortic diseases: document covering acute and chronic aortic diseases of the thoracic and abdominal aorta of the adult. The Task Force for the Diagnosis and Treatment of

- Aortic Diseases of the European Society of Cardiology (ESC). *Eur Heart J* 2014;35:2873-926.
30. Wanhainen A, Verzini F, Van Herzelee I, Allaire E, Bown M, Cohnert T, et al. Editor's choice – European Society for Vascular Surgery (ESVS) 2019 clinical practice guidelines on the management of abdominal aorto-iliac artery aneurysms. *Eur J Vasc Endovasc Surg* 2019;57:8-93.
  31. Falkenberg M, Cronqvist J, Malina M. Early stent fracture and collapse of a Zenith TX2 thoracic stent graft used for traumatic aortic rupture. *Vascular* 2011;19:287-90.
  32. Stefaniak K, Stanisic M, Gabriel M, Oszkinis G. Diagnostic imaging methods applied in long-term surveillance after EVAR: will computed tomography angiography be replaced by other methods? *Postepy Kardiol Interwencyjnej* 2016;12:6-12.
  33. Pini R, Faggioli G, Mascoli C, Freyrie A, Gargiulo M, Stella A. The diagnostic and treatment challenge of type IIIb endoleaks. *J Vasc Surg Cases* 2015;1:249-53.
  34. Tsoumakidou G, Brontzos E. Detection of complications after aortic stent grafting. *Eur Cardiol* 2010;6:83-7.
  35. Stavropoulos SW, Charagundla SR. Imaging techniques for detection and management of endoleaks after endovascular aortic aneurysm repair. *Radiology* 2007;243:641.
  36. Lee WA, Huber TS, Seeger JM. Late type III endoleak from graft erosion of an Excluder stent graft: a case report. *J Vasc Surg* 2006;44:183-5.
  37. Lemmon G, Barleben A, Nelson P, Garrett HE Jr. Diagnosis and relining techniques for delayed type IIIb endoleaks with the second-generation AFX endograft. *J Vasc Surg Cases Innov Tech* 2019;5:51-3.
  38. Berezowski M, Morlock J, Beyersdorf F, Jasinski M, Plonek T, Siepe M, et al. Inaccurate aortic stent graft deployment in the distal landing zone: incidence, reasons and consequences. *Eur J Cardiothorac Surg* 2018;53:1158-64.
  39. Geisbüsch P, Skrypnik D, Ante M, Trojan M, Bruckner T, Rengier F, et al. Endograft migration after thoracic endovascular aortic repair. *J Vasc Surg* 2019;69:1387-94.
  40. Alberta HB, Takayama T, Panthofer A, Cambria RP, Farber MA, Jordan WD, et al. Thoracic endovascular aortic repair migration and aortic elongation differentiated using dual reference point analysis. *J Vasc Surg* 2018;67:382-8.
  41. Chen C-K, Chou H-P, Chang Y-Y, Shih C-C. Elongation of the aorta after thoracic endovascular aortic repair: a longitudinal study. *Int J Environ Res Public Health* 2020;17:1205.
  42. Mathlouthi A, Locham S, Dakour-Aridi H, Black JH, Malas MB. Impact of suprarenal neck angulation on endovascular aneurysm repair outcomes. *J Vasc Surg* 2020;71:1900-6.
  43. Jasinski PT, Adrahtas D, Monastiriotis S, Tassiopoulos AK. Early and late endograft limb proximal migration with resulting type 1b endoleak following an EVAR for ruptured AAA. *Case Rep Vasc Med* 2017;2017:4931282.

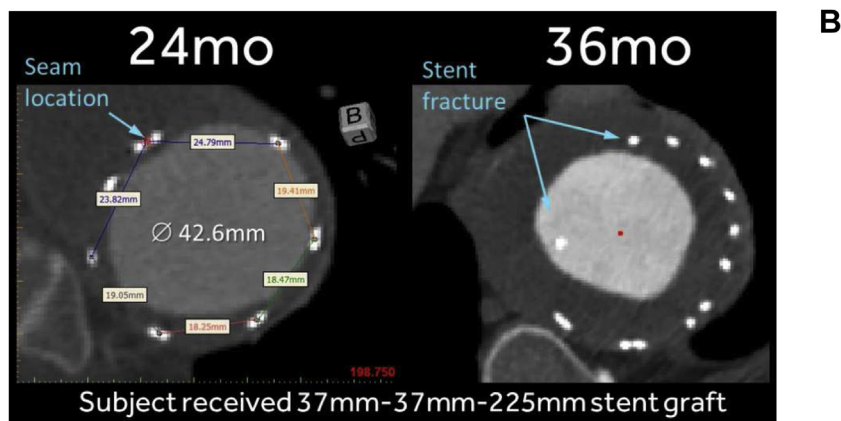
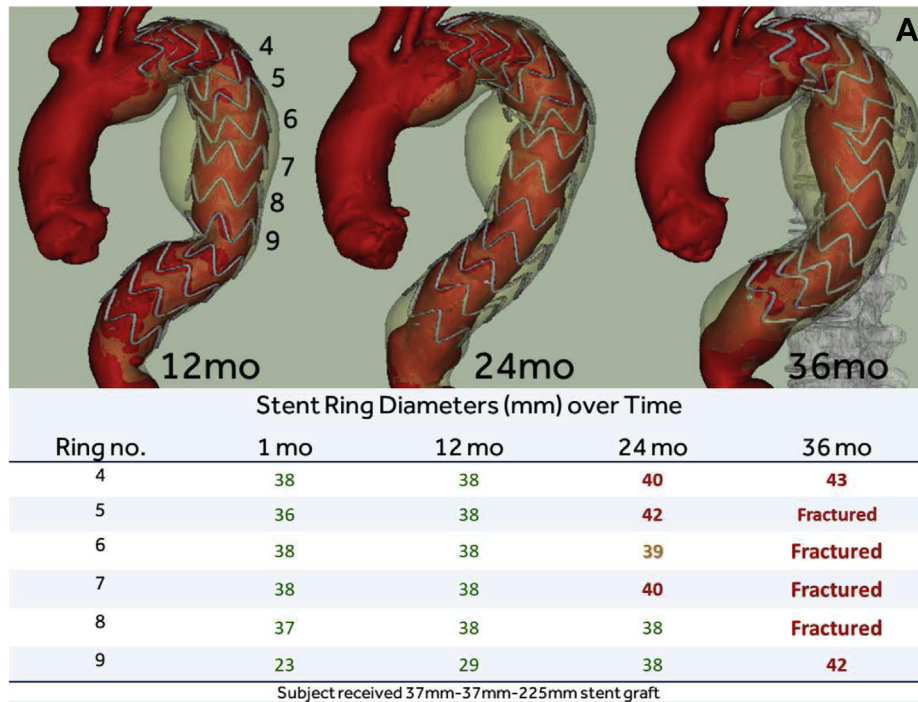
Submitted Mar 23, 2021; accepted Apr 13, 2021.

*Additional material for this article may be found online at [www.jvascsurg.org](http://www.jvascsurg.org).*



**Supplementary Fig 1 (online only).** Patient 1. Additional details surrounding the rupture at the level of the distal thoracic endovascular aortic repair (TEVAR) extension. **A**, One day after the initial TEVAR procedure, the patient complained of acute back pain. The three-dimensional reconstruction and cross-sectional computed tomography (CT) images confirmed a focal aortic dissection at the distal end of the graft, which extended distally for 4.6 cm. The stent graft still appeared to be positioned normally without signs of an endoleak. Because the patient's pain had resolved without further treatment, the patient was discharged home 10 days after procedure. **B**, Imaging study performed at 44 months after index procedure and before the relining procedure showing false lumen (FL) of the previously dissected section of the aorta appeared to have thrombosed and the true lumen (TL) volume had increased. **C**, A secondary procedure was performed to reline the graft, and the type IIIb was successfully excluded with no evidence of endoleaks. Completion angiogram showing the distal end of the relining graft landed at the level of the previously dissected and fragile aorta. Four days after the secondary procedure, the patient was found unresponsive after an episode of left flank pain and pronounced dead of suspected aortic rupture at the level of the distal TEVAR extension.





**Supplementary Fig 2 (online only).** Patient 3 (type IIIb endoleak, stent fractures along seam line, and stent ring enlargement). The patient was a 65-year-old woman with a fusiform descending thoracic aortic aneurysm (DTAA) with diameter of 62 mm. The patient underwent implantation with a single Valiant Navion stent graft (37 mm, 37 mm, 225 mm) and a zone 3 proximal landing. On the 24-month imaging study, no endoleaks, stent fractures, or aneurysm enlargement was observed. However, the diameters of stent rings 4, 5, 6, and 7 had enlarged. **A**, Between the 24- and 36-month imaging studies, stent rings 5, 6, 7, and 8 had fractured, and stent rings 4 and 9 showed stent ring enlargement. **B**, The seam of the graft was identified at the inner curvature, and the fractures were in line with the graft seam shown on the cross-section computed tomography (CT) scan. At last follow-up, the patient was scheduled for an endovascular reintervention.