

AperTO - Archivio Istituzionale Open Access dell'Università di Torino

The prevalence of TTR cardiac amyloidosis among patients undergoing bone scintigraphy

This is a pre print version of the following article:

Original Citation:

Availability:

This version is available <http://hdl.handle.net/2318/1795237> since 2021-07-28T15:37:42Z

Published version:

DOI:10.1007/s12350-021-02575-0

Terms of use:

Open Access

Anyone can freely access the full text of works made available as "Open Access". Works made available under a Creative Commons license can be used according to the terms and conditions of said license. Use of all other works requires consent of the right holder (author or publisher) if not exempted from copyright protection by the applicable law.

(Article begins on next page)

Non-invasive diagnosis of transthyretin amyloidosis heart involvement using bone scan: a retrospective evaluation of 4228 scintigraphies.

Bianco M^{1*} MD, Righetti C^{1*} MD, Biolè C¹ MD, Spirito A¹ MD, Luciano A¹ MD, Destefanis P¹ MD, Nangeroni G¹ MD, Parente A² MD, Angusti T² MD, Anselmino M³ MD, Prof, Montagna L¹ MD.

¹ Department of Cardiology, San Luigi Gonzaga Hospital, Orbassano, Turin;

² Department of nuclear medicine, San Luigi Gonzaga Hospital, Orbassano, Turin;

³ Division of Cardiology, Department of Medical Sciences, “Città della Salute e della Scienza di Torino” Hospital, University of Turin, Turin;

*The first two authors equally contributed to the paper.

Corresponding author: Matteo Bianco, MD, Cardiology Division, San Luigi Gonzaga University Hospital, Orbassano (Turin), Italy. Email: matteo.bianco87@gmail.com, website: www.cardiogroup.org

Keywords: amyloidosis, transthyretin, TTR, bone scan, scintigraphy, Perugini score, prevalence, comorbidities, complications, prognosis.

ABSTRACT

Amyloidosis is an important cause of infiltrative cardiomyopathy and is often diagnosed lately in the course of the disease; radiolabeled bisphosphonates bone scan is highly sensitive in detecting transthyretin (TTR) cardiac amyloidosis; data on the true prevalence of cardiac involvement in TTR amyloidosis are lacking. The aim of the present retrospective observational, monocentric study was to estimate the prevalence of positive bone scan suspect for TTR cardiac amyloidosis in the population of Piedmont - a region in the north-west of Italy - retrospectively assessing unexpected cardiac emissions in bone scan scintigraphy among an all-comers population who underwent a bone scan at San Luigi Gonzaga University Hospital between January 2015 and May 2020. ECG, echocardiography and clinical status of patients with positive cardiac emission have been collected in order to better characterize their clinical features.

Background. Amyloidosis is a group of diseases characterized by deposition in human tissues of protein aggregates [1]. A subtype of amyloidosis is characterized by accumulation of transthyretin (TTR), either in its natural (wild type ATTR amyloidosis, ATTRwt) or mutated (hereditary ATTR amyloidosis, hATTR) form. In this disease TTR tetramer, mutated or natural with age, becomes instable and dissociates into single monomers [2]. Clinically, the disease causes heart failure, orthostatic hypotension, neurological and autonomic dysfunctions, renal insufficiency, carpal tunnel syndrome and lumbar spinal stenosis [3].

Currently, the diagnosis is based on non-invasive tools [3]: ECG typically shows low voltages and atrial fibrillation, first-degree atrioventricular block, left bundle-branch blocks and infarct-like patterns [4] while echocardiography a hypertrophic phenotype with thickness of interventricular septum and posterior wall, atrial enlargement, pericardial effusion, diastolic abnormalities and apical sparing [5]. Cardiac Magnetic Resonance is a sensitive and specific tool in diagnosing the condition but does not differentiate between TTR and other forms of amyloidosis [6]. Conversely, bone scan with radiolabeled bisphosphonates, such as [99mTc]-HDP or [99mTc]-DPD, able to link calcium of TTR fibrils, has approximately 100% sensitivity for detection of myocardial involvement in TTR amyloidosis [7]. Endomyocardial biopsy (EMB), considered the gold standard for histological diagnosis, is used only when noninvasive examinations for TTR amyloidosis are inconclusive [8].

Despite an early diagnosis is of paramount importance for the prognosis of these patients, nowadays, the average time from symptoms onset to TTR amyloidosis diagnosis is about three years [9].

Study goals. Data on the true prevalence of cardiac involvement in TTR amyloidosis are lacking. The aim of our study was to estimate the prevalence of positive bone scan suspect for TTR cardiac amyloidosis in the population of Piedmont - a region in the north-west of Italy - retrospectively assessing unexpected cardiac emissions in bone scan scintigraphy among an all-comers population who underwent a bone scan in our centre. Moreover, we aimed to analyze the clinical history, electrocardiographic and echocardiographic features of patients with positive scans (Perugini score of 2 or 3) in order to describe the phenotypic expression of TTR amyloidosis cardiac involvement.

Methods. We conducted a retrospective, observational, monocentric study which included patients by analyzing the digital archive of bone scintigraphies performed between January 2015 and May 2020 in the Nuclear Medicine Department of AOU San Luigi Gonzaga, Orbassano, Turin, Italy. We included all patients who underwent a total-body scintigraphy for any reason. The protocol used in our centre is a whole-body bone scan using [99mTc]-HDP or [99mTc]-DPD at the discretion of nuclear doctor. The tracer is administrated intravenously at the median dose of 740 MBq. The patients usually only undergo the delayed phase examination, 3 hours after the agent's injection. The results obtained are analyzed for both cardiac and non-cardiac emissions. In case of cardiac emission, the Perugini score is used. We collected general demographic data, indication to bone scintigraphy, tracer and protocol used and results of the bone scintigraphy including any positivity for cardiac uptake from the digital archive of the Nuclear Medicine Department. Hence, patients with a positive cardiac uptake (Perugini 2 or 3) were selected. Personal data in the Cardiology department digital database were searched for to obtain all relevant clinical data available, focusing on previous cardiovascular history, ECGs and echocardiographic examinations. In the absence of cardiological data, patients, or their general practitioners, were contacted. When multiple examinations were present the temporally closest to the bone scan was considered. Finally, only for those patients without previous cardiovascular evaluation, an in-person visit with ECG and echocardiography scan was arranged. The data

collected were analyzed using SPSS 25.0 software (IBM, ARMONK, USA) and GraphPad Prism 4 (La Jolla California USA). The study was performed according to the Institution Review Board guidance of our centre and conducted in accordance to the latest amendments of the Declaration of Helsinki.

Results and discussion. The prevalence of Perugini score 2 or 3 for cardiac involvement of TTR amyloidosis was 0.54% (23/4228) in the five year time span included in our analysis. The bone scan was mainly performed using [^{99m}Tc]-HDP (82.9%) and the dominant indication for the exam was oncological in the 61% of cases.

The 23 patients (18 men (78%), mean age of 83 ± 5 years, BSA of $1.82 \text{ m}^2 \pm 0.15 \text{ m}^2$) having a cardiac gamma emission, 14 (61%) had a Perugini score of 3. Scan indication was dominantly oncological (11, 47.9%), followed by orthopedical (7, 30.1%). Sex and age stratification of patients with positive cardiac uptake is reported in **Figure 1**. The clinical and scintigraphic features are reported, instead, in **Table 1**.

Fourteen subjects (60.9%) had arterial hypertension, with mean 126 ± 11.86 mmHg systolic, and 80.2 ± 13.7 mmHg diastolic BP. One subject had a history of coronary artery disease (4.4%), 3 had a permanent pacemaker (13%), 11 suffered a previous episode of heart failure (48%). Eight subjects presented known neuropathy (34.8%) and 5 carpal tunnel syndrome (21.7%). Five patients (21.7%) were asymptomatic, with a silent cardiovascular history, without arrhythmias or heart failure signs. Hs Troponin I levels, when available (missing data for 9 patients), resulted slightly abnormal (69.1 ± 15.2 ng/mL; normal value ≤ 34 ng/ml). Several features were revealed at ECG: 6 subjects presented low voltages (26%), 13 atrial fibrillation (55%) and conduction disturbances were common (7 first-degree AV blocks (30%), 5 left bundle branch block (22%) and 4 right bundle branch blocks (17%)). Echocardiogram showed biatrial dilatation (left atrial volume 66.6 ± 18.5 ml/m², right atrial volume 52.5 ± 9.3 ml/m²). The left ventricle was not dilated (telediastolic diameter: 50.4 ± 5.5 mm; telesistolic diameter: 35.2 ± 6.9 mm) but indexed mass was overall increased (182 ± 25.5 g/m²) due to the thickening of interventricular septum (13.1 ± 2 mm) and posterior wall (12.9 ± 1.7 mm). Moreover, the left ventricular systolic function was slightly reduced with an ejection fraction (EF) of $49.1 \pm 9.3\%$. None of the subjects with positive cardiac uptake presented alterations of the segmental kinesis nor moderate or severe valvular heart disease. The mitral E/A ratio was 1.3 ± 0.8 and the average E/E' of the left ventricle 15.1 ± 6.4 . The systolic pulmonary artery pressure (PAPs) was 43.9 ± 12.6 mmHg and a mild right ventricle basal telediastolic diameter dilatation was, instead, prevalent (45.2 ± 1.5 mm) with a normal right ventricle systolic function (tricuspid S' 12.2 ± 3.9 cm). Full details of the echocardiographical features of our population are also reported in **Table 1**.

The present study, providing a 0.5% prevalence of TTR amyloidosis heart involvement in the population of Piedmont, north-west Italy, confirms previous data from Longhi et al showing a 0.36% myocardial tracer uptake in an all-comers population undergoing ^{99m}Tc-DPD scintigraphies at the Bologna University Hospital [10]. TTR amyloidosis is a condition characterized by a long latency period between the symptoms onset and the definite diagnosis. Consequently, a positive bone scan with cardiac gamma emissions should be considered as a crucial opportunity in order to diagnose the pathology early in the disease course. In

our case series, bone scan allowed a diagnosis in 5 (21.7%) asymptomatic patients before the onset of arrhythmias or heart failure; however, it should be noted that all patients with a positive bone scan defined as a Perugini score 2 or 3, showed already a degree of involvement on echocardiography, with at least a mildly abnormal left ventricular wall thickness (minimum 12 mm) and a moderately abnormal indexed left ventricular mass (minimum 147 g/m²). The diagnosis in a preclinical stage could allow early treatment of the disease, potentially improving prognosis of the patients [11]. In fact, during the study period, 6 patients (26%) died. Bone scan should, therefore, be considered a useful opportunity in which an early diagnosis can be achieved. As a consequence, an in-hospital medical network in which Nuclear Medicine doctors refer patients with a positive bone scan for myocardial uptake with a Perugini score of 2 or 3 to cardiologists expert on cardiomyopathies surely could contribute to significantly reduce the time to reach diagnosis of heart involvement in cardiac amyloidosis starting prognosis modifying therapies.

Study limitation. Our study encompasses several limitations, first of all the retrospective and monocentric design of the study; moreover, the patients did not undergo a comprehensive diagnostic workup in case of bone scan positivity for cardiac uptake. Important exams such as serum and urinary immunofixation and genetic testing were waived not giving the chance to confirm the diagnosis of amyloidosis TTR. Anyway, the main purpose of the study was to evaluate the prevalence of cardiac uptake in an all-comers population undergoing bone scan for different reasons to estimate cardiac involvement; echocardiography showed characteristics compatible with initial amyloidotic involvement in most cases. Finally, some TTR gene mutations appear to have a low correlation with bone scan cardiac uptake [12]; as a consequence, an underestimation of the true prevalence of TTR amyloidosis heart involvement can not be excluded.

Conclusions. Prevalence of cardiac TTR amyloidosis involvement in an all-comers population undergoing bone scan was 0.54%. A positive bone scan (Perugini score 2 or 3) allowed an early, preclinical diagnosis in 21.7% of amyloidosis patients, supporting the need of a strong collaboration between nuclear doctors and cardiologists to improve management of this disease.

Bibliography

- [1] Blancas-Mejía L, Ramirez-Alvarado M, Systemic Amyloidoses, *Annual Review of Biochemistry*, 2013; 82:745-774.
- [2] Vieira M, Saraiva M, Transthyretin: a multifaceted protein, *Biomolecular Concepts*, 2014;5: 45-54.
- [3] Rapezzi C, Lorenzini M, Longhi S, Milandri A, Gagliardi C, Bartolomei I, Salvi F, Maurer MS, Cardiac amyloidosis: the great pretender, *Heart Failure Review*, 2015; 20: 117-24.
- [4] Ruberg F, Grogan M, Mazen H, Kelly J, Transthyretin Amyloid Cardiomyopathy, *Journal of the American College of Cardiology*, 2019; 73: 2872-2891.
- [5] Rapezzi C, Quarta C, Obici L, Perfetto F, Longhi S, Salvi F, Disease profile and differential diagnosis of hereditary transthyretin-related amyloidosis with exclusively cardiac phenotype: an Italian perspective, *European Heart Journal*, 2013; 34: 520-8.
- [6] Syed I, Glockner J, Feng D, Araoz P, Martinez M, Edwards W, Gertz M, Dispenzieri A, Oh J, Bellavia D, Tajik A, Grogan M, Role of cardiac magnetic resonance imaging in the detection of cardiac amyloidosis, *JACC Cardiovascular Imaging*, 2010; 3: 155-64.
- [7] Chen W, Ton VK, Dilsizian V, Clinical Phenotyping of Transthyretin Cardiac Amyloidosis with Bone-Seeking Radiotracers in Heart Failure with Preserved Ejection Fraction, *Current Cardiology Reports*, 2018; 20: 23.
- [8] Jamet M, Gnemmi V, Hachulla E, Distinctive patterns of transthyretin amyloid in salivary tissue: a clinicopathologic study of 92 patients with amyloid-containing minor salivary gland biopsies, *The American Journal of Surgical Pathology*, 2015; 39:1035-44.
- [9] Lane T, Fontana M, Martinez-Naharro A, Quarta CC, Whelan CJ, Petrie A, Rowczenio DM, Gilbertson JA, Hutt DF, Rezk T, Strehina SG, Caringal-Galima J, Manwani R, Sharpley FA, Wechalekar AD, Lachmann HJ, Mahmood S, Sachchithanantham S, Drage EPS, Jenner HD, McDonald R, Bertolli O, Calleja A, Hawkins PN, Gillmore JD, Natural History, Quality of Life, and Outcome in Cardiac Transthyretin Amyloidosis, *Circulation*, 2019; 140: 16–26.
- [10] Longhi S, Guidalotti P, Quarta C, Gagliardi C, Milandri A, Lorenzini M, Potena L, Leone O, Bartolomei I, Pastorelli F, Salvi F, Rapezzi C, Identification of TTR-related Subclinical Amyloidosis With ^{99m}Tc-DPD Scintigraphy, *JACC: Cardiovascular Imaging*, 2014;7: 531-532.
- [11] Maurer M, Schwartz J, Gundapanemi B, Elliott P, Merlini G, Rapezzi C, Tafamidis Treatment for Patients with Transthyretin Amyloid Cardiomyopathy, *The New England Journal of Medicine*, 2018; 379: 1007-1016.
- [12] Musumeci MB, Cappelli F, Russo D, Tini G, Canepa M, Milandri A, Bonfiglioli R, Di Bella G, My F, Luigetti M, Grandis M, Autore C, Perlini S, Perfetto F, Rapezzi C, Low Sensitivity of Bone Scintigraphy in Detecting Phe64Leu Mutation-Related Transthyretin Cardiac Amyloidosis, *JACC Cardiovascular Imaging*, 2019;13: 1314-1321.

BASELINE, SCINTIGRAPHY
AND ECHOCARDIOGRAPHY
FEATURES

Perugini 2
N = 9

Perugini 3
N = 14

p-value

Age	83.6 ± 5.3	82.6 ± 5.7	0.69
Men	6 (66.7)	12 (85.7)	0.28
BSA (Body Surface Area)	1.8 ± 0.07	1.8 ± 0.12	0.38
Reason for scintigraphy			
Orthopaedical	2 (22.2)	5 (35.7)	0.79
Oncological	4 (44.4)	7 (50.0)	0.49
Other	3 (33.3)	2 (14.3)	0.28
Medication			
[99mTc]-DPD	2 (22.2)	2 (14.3)	0.62
[99mTc]-HDP	7 (77.8)	12 (85.7)	0.62
Aortic root	36.0 ± 5.6	35.9 ± 5.3	0.95
Ascendant aorta	37.1 ± 2.8	37.6 ± 2.9	0.71
Ascendant aorta (mm/m ³)	19.9 ± 2.5	19.4 ± 2.5	0.67
Left-atrial diameter (mm)	50.3 ± 9.6	51.3 ± 8.3	0.81
Left-ventricular telediastolic diameter (mm)	51.7 ± 6.3	49.6 ± 4.9	0.89
Left-ventricular telesistolic diameter (mm)	36.1 ± 7.2	34.6 ± 6.9	0.61
Right-ventricular basis telediastolic diameter (mm)	46.0 ± 1.5	44.6 ± 1.3	0.03
Interventricular septum diameter (mm)	13.9 ± 0.9	14.3 ± 1.5	0.49
Posterior wall diameter (mm)	12.8 ± 1.8	13.1 ± 1.7	0.69
Left ventricular mass (g)	302.3 ± 50.3	272.8 ± 64.2	0.26
Left ventricular mass (g/m ²)	175.8 ± 27.8	186.7 ± 23.9	0.33
Right atrial volume (ml/m ²)	52.3 ± 9.6	52.6 ± 9.4	0.95
Left atrial volume (ml/m ²)	63.1 ± 10.0	68.9 ± 22.5	0.48
E/A ratio	1.6 ± 1.1	1.1 ± 0.4	0.11
Isovolumetric relaxation time (msec)	61.7 ± 9.8	59.7 ± 12.9	0.7
Mitral E/E'	17.0 ± 7.8	13.9 ± 5.3	0.83
Tricuspid S'	12.4 ± 4.7	12.1 ± 3.5	0.26

PAPs (mmHg)	45.5 ± 15.9	42.9 ± 10.5	0.64
Ejection fraction (%)	51.1 ± 10.1	42.9 ± 10.5	0.43
Aortic stenosis	0	0	-
Ventricular kinesis alterations	5 (55.6)	7 (50.0)	0.79

Table 1: TTR patients' population characteristics

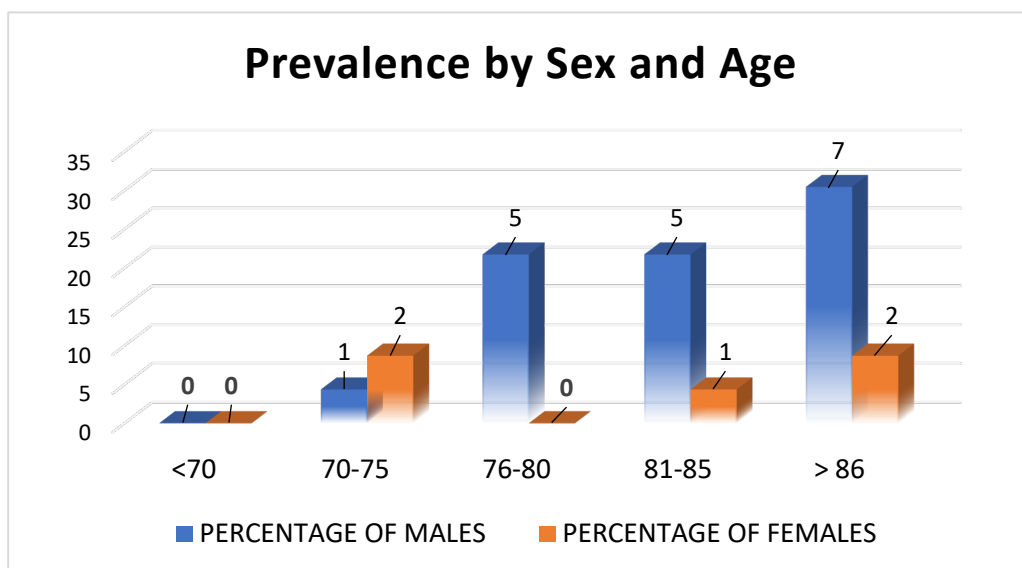


Figure 1: TTR amyloidosis stratification by sex and age