

AperTO - Archivio Istituzionale Open Access dell'Università di Torino

Successful Treatment of Pyometra Caused by *Pseudomonas aeruginosa* Infection in a Rabbit

This is the author's manuscript

Original Citation:

Availability:

This version is available <http://hdl.handle.net/2318/1758115> since 2020-11-07T09:55:08Z

Published version:

DOI:10.1016/j.tcam.2020.100473

Terms of use:

Open Access

Anyone can freely access the full text of works made available as "Open Access". Works made available under a Creative Commons license can be used according to the terms and conditions of said license. Use of all other works requires consent of the right holder (author or publisher) if not exempted from copyright protection by the applicable law.

(Article begins on next page)

Journal Pre-proof

Successful treatment of pyometra caused by *Pseudomonas aeruginosa* infection in a rabbit

Mitzy Mauthe von Degerfeld , Penelope Banchi ,
Giuseppe Quaranta

PII: S1938-9736(20)30071-4
DOI: <https://doi.org/10.1016/j.tcam.2020.100473>
Reference: TCAM 100473



To appear in: *Topics in Companion Animal Medicine*

Please cite this article as: Mitzy Mauthe von Degerfeld , Penelope Banchi , Giuseppe Quaranta , Successful treatment of pyometra caused by *Pseudomonas aeruginosa* infection in a rabbit, *Topics in Companion Animal Medicine* (2020), doi: <https://doi.org/10.1016/j.tcam.2020.100473>

This is a PDF file of an article that has undergone enhancements after acceptance, such as the addition of a cover page and metadata, and formatting for readability, but it is not yet the definitive version of record. This version will undergo additional copyediting, typesetting and review before it is published in its final form, but we are providing this version to give early visibility of the article. Please note that, during the production process, errors may be discovered which could affect the content, and all legal disclaimers that apply to the journal pertain.

© 2020 Published by Elsevier Inc.

Successful treatment of pyometra caused by *Pseudomonas aeruginosa* infection in a rabbit

Mitzy Mauthe von Degerfeld¹, Penelope Banchi^{1*}, Giuseppe Quaranta¹

¹Dip. di Scienze Veterinarie, Università degli Studi di Torino, 10095, Grugliasco (TO), Italy

Email addresses: mitzy.mauthe@unito.it, penelope.banchi@unito.it, giuseppe.quaranta@unito.it

Correspondence

Penelope Banchi DVM; penelope.banchi@unito.it;

Largo Paolo Braccini 2, 10095, Grugliasco (TO), Italy;

00390116709291

Abstract

This article reports an unusual presentation of pyometra in a pet rabbit. A 2-year-old mixed-breed female rabbit with pelvic limb paralysis was referred for abdominal distension associated with prolonged depression and decreased appetite. Clinical examination and diagnostic imaging (radiographs and ultrasound) led to the provisional diagnosis of pyometra, that was caused by the presence of an enlarged organ containing fluid material and occupying most of the caudal abdomen. Exploratory laparotomy was performed under general anesthesia. After abdominal wall incision along the *linea alba*, the uterus was immediately evident and the uterine wall was over-distended and damaged, with purulent material free in the abdominal cavity. Ovariohysterectomy was performed and uterine wall samples were sent for microbiological examination and antimicrobial susceptibility testing. The agent causing the pyometra was found to be *Pseudomonas aeruginosa*, which was resistant to enrofloxacin and ceftazidime. This is the first report of pyometra caused by *P. aeruginosa* in a pet rabbit, based on a literature search. Furthermore, a peculiarity of the present case is the occurrence of pyometra in a rabbit with no history of mating or parturition.

Key words

Pet rabbits, lagomorph, pyometra, *Pseudomonas aeruginosa*, female reproduction, small mammals

Introduction

Pyometra is a purulent inflammation of the uterus with an accumulation of pus within the uterine lumen. It is a common disorder in dogs and cats, but it is reported only sporadically in rabbits [1]. The incidence is higher in rabbit does on industrial farms than in pet rabbits (6.5% vs. 2%) [2]. In lagomorphs, pyometra is mostly caused by *Pasteurella multocida* and *Staphylococcus aureus* infections [3], and it typically occurs after parturition.

Various clinical signs can be associated with the disease, including depression, anorexia, hematuria, vaginal discharge, and abdominal enlargement [2]. However, some cases can be insidious because of mild clinical signs and the lack of vaginal discharge. Pyometra can be a life-threatening condition and immediate surgical intervention is a first-choice treatment.

Case description

A 2-year-old mixed-breed pet female rabbit weighing 1.5 kg was referred to the C.A.N.C. (the exotics and wild animals section of the Veterinary Teaching Hospital of the University of Torino) because of abdominal distension. Additional clinical history included a traumatic vertebral with spinal cord injury causing grade 5 paralysis of both pelvic limbs with urinary incontinence associated with a large bladder. The traumatic event that caused the fracture occurred 18 months earlier. During the consultation, the owner reported that he had noticed unusual behavior with decreased appetite and depression lasting for the previous 10 days. No parturition or mating had ever occurred, and the patient lived free in the apartment with no other animal. On physical examination, the rabbit was alert and responsive, but appeared restless. Rectal temperature was 39.5°C (reference interval, 38.5–40°C) [4]. The conjunctiva were severely pale. Oral examination

performed with an otoscope demonstrated minor overgrowth of premolars and molars of all four arcades, but no mucosal lesion was present. The abdominal wall was extremely distended, and ballottement suggested the presence either of abdominal effusion, dilated organ, or mass containing liquid material. Abdominal palpation appeared painful, with a two-point increase in the Rabbit Grimace Scale score (orbital tightening, 1 to 2; cheek flattening, 1; whisker position, 0; nostril shape, 2; ear position, 1 to 2) [5]. Heart rate was within the reference interval (120–325 bpm), whereas tachypnea was present (respiratory rate, 104 breaths per minute; reference interval, 30–60 breaths per minute) [4]. Abnormal hematology and biochemistry results included decreased hematocrit (25.8%; reference interval, 30–44%) and hemoglobin (8.4 g/dL; reference interval, 9.8–13.2 g/dL), mild leukocytosis ($11.7 \times 10^9/L$; reference interval, $4.54\text{--}10.22 \times 10^9/L$) with neutrophilia (61.7%; reference interval, 35–55%), thrombocytosis ($777 \times 10^9/L$; reference interval, $219\text{--}521 \times 10^9/L$), and an elevation in blood urea nitrogen (72 mg/dL, reference interval, 15–50 mg/dL). No other blood abnormalities were observed.

Radiographs (*Figure 1*) revealed a markedly distended abdomen with poor detail caused by mild peritoneal effusion and organomegaly occupying the caudal and mid-abdomen and displacing the cecum and small bowel cranially and ventrally. The stomach was filled with gas and opaque material, the margins of the liver were well defined, and the colon was also filled with gas. The urinary bladder and kidneys were not visible. Kyphosis was observed at vertebral segments T9–T12, and a deviation of the vertebral column was observed that corresponded to the lumbosacral junction.

Transabdominal ultrasonography showed a minimally filled urinary bladder and normal kidneys. All intestinal loops were displaced cranially, with normal content and peristalsis and no alteration of the intestinal wall. The liver was poorly evaluable because of its cranial displacement. Finally, the uterus occupied most of the abdomen, showing walls with an increased size and thickness. The

organ presented a massive fluid accumulation within the lumen with numerous hyperechoic spots, which is consistent with the presence of purulent material.

The provisional diagnosis of pyometra was made based on the medical history, physical examination, and diagnostic imaging findings. Explorative laparotomy was recommended and scheduled for the following morning. Fluid therapy was immediately started (0.9% NaCl; 100 mL/kg/day subcutaneously [s.c.]) every 8 hours, and the analgesic that was administered was carprofen (Rimadyl, Pfizer, Italy; 4 mg/kg s.c.). Early in the morning, anesthesia was induced using an intramuscular mixture of ketamine (Ketavet 100, Intervet, Italy; 12.5 mg/kg), medetomidine (Sedator, ATI, Italy; 250 µg/kg), and butorphanol (Nargesic, ACME, Italy; 125 µg/kg), and it was maintained with isoflurane via a facial mask. The heart rate, ECG, respiratory rate, and oxygen saturation (SpO₂) were monitored throughout the procedure.

The rabbit's abdomen was shaved, and the patient was moved to the operating room, placed in dorsal recumbency and the abdomen was surgically scrubbed. Surgical drapes were positioned, and a 4-cm ventral midline incision was made along the *linea alba*. The uterus occupied most of the abdomen, and the uterine wall was distended and damaged, with a modest amount of purulent material that was free in the abdomen. Ovariohysterectomy was performed following standard procedures, carefully exteriorizing the uterus to avoid further damage to the uterine wall and *ex vacuo* hemodynamic complications. The ovarian blood vessels were properly secured, and the uterine body was double ligated with two circumferential sutures (Vicryl 3-0, Ethicon, Belgium). The ovaries and uterus were then completely removed (*Figure 2*). After abdominal lavage with warmed 0.9% NaCl, the abdominal wall was sutured in two layers using a simple interrupted suture (Vicryl 2-0, Ethicon). The weight of the removed uterus was 0.395 kg and the content appeared to be a homogeneous white dense material, with no traces of blood (*Figure 3*).

In addition to preemptive butorphanol administration, the rabbit received carprofen (Rimadyl, Pfizer; 4 mg/kg s.c.) at the end of the surgery and every 24 hours for 3 days.

Antimicrobial therapy was initiated using a broad-spectrum agent (Baytril, Bayer, Germany: enrofloxacin, 5 mg/kg every 12 hours). Assisted oral feeding with commercially available powdered formula (Oxbow Critical Care, Oxbow Animal Health, Omaha, NE, USA) was performed 1 hour after recovering from anesthesia, and afterwards, the patient started to eat hay and fresh vegetables. In accordance with the owner, the rabbit was hospitalized for 5 days after surgery. The uterine wall was submitted for microbiological analysis and antimicrobial susceptibility testing. The identified etiologic agent was found to be *Pseudomonas aeruginosa* that was resistant to enrofloxacin and ceftazidime, but susceptible to marbofloxacin. Therefore, antimicrobial therapy with marbofloxacin (Marbocyl, Vetoquinol, France, 5 mg/kg orally administered every 24 h) was prescribed for 10 days.

At discharge, the patient was quiet, alert, and responsive, and no sign of pain was present, according to the facial expression that was assessed using the Rabbit Grimace Scale score. The surgical wound appeared clean, dry, and no signs of inflammation were present. Three days after discharge the owner was contacted for an update, and he stated that the rabbit seemed to feel fine and that the rabbit had returned to normal behavior and appetite and regular fecal production. Ten days after discharge the patient returned for clinical examination, appearing active, alert, and responsive. The surgical wound was healed, and the scar was clean and did not appear inflamed. No further treatment was prescribed.

Discussion and Conclusions

Pyometra caused by *P. aeruginosa* has not been reported previously in a pet rabbit.

P. aeruginosa can be involved in many diseases in companion animals, such as skin infections, otitis externa, cystitis, and infections of the lower urinary tract [6]. Pyometra caused by *P. aeruginosa* infections is sporadically reported in the bitch [7]. However, other agents are more common. It is a Gram-negative non-glucose-fermenting aerobic bacterium, and treatment of *P. aeruginosa*-associated infections can represent a challenge because of the ability of this bacterium to develop resistance towards many antibiotics [6]. Enrofloxacin is the most widely used antimicrobial agent on the market that is authorized for use in rabbits [8], and it is known to be active against some Gram-positive and several Gram-negative bacteria, including *P. aeruginosa*. As a fluoroquinolone, enrofloxacin is recognized by the World Health Organization as a “Highest Priority Critically Important Antimicrobial” for human medicine [8]. Therefore, it should be used responsibly based on microbiological analysis and antimicrobial susceptibility testing. However, it is widely used to treat infections caused by *P. multocida* in pet rabbits [9]. As mentioned before, pyometra in lagomorphs is mostly associated with *P. multocida* infections [3]. All these considerations make enrofloxacin a first choice when dealing with pyometra in rabbits and waiting for antimicrobial susceptibility testing results. Clinicians should observe general principles of antimicrobial therapy, always submitting samples for microbiological analysis, and antimicrobial susceptibility testing, to set up an effective treatment plan [10].

A peculiarity to consider is the limb paralysis that affected the patient. There is no known association between limb paralysis and uterine infection in rabbits. However, a common origin for urinary tract and genital infections in the bitch was reported when it was caused by ascending infections from the vagina [11]. Cystitis is a common condition in paralytic companion animals [12], and therefore, it is not possible to exclude that pyometra was accompanied by a urinary tract infection in the present case. This could further explain the presence of *P. aeruginosa*. However, no urinalysis was performed because there were no clinical signs of cystitis.

In rabbits, pyometra usually occurs after parturition [2]. The present case report describes how pyometra is a possibility even when no mating has previously occurred. Therefore, it should always be initially included in the differential diagnosis when a female rabbit that is not spayed is presented.

The patient presented with depression, decreased appetite and abdominal distension. These signs can be associated with a wide number of conditions, especially those causing gastrointestinal stasis [9]. Diagnostic imaging was of primary importance in the diagnosis.

In conclusion, this report describes the successful treatment of pyometra caused by *P. aeruginosa* infection in a female rabbit with no history of parturition. Uterine infections are to be listed in the differential diagnosis, even when no vaginal discharge is present. A meticulous diagnostic pathway, including diagnostic imaging, microbiological analysis, and antimicrobial susceptibility assay, is always advisable in clinical practice to diagnose even rare disorders.

Authors' contributions

PB was the veterinarian in charge of the clinical case, performed all the examinations, and wrote the manuscript; MMvD and GQ participated in the surgical procedure; MMvD critically revised the manuscript. All authors read and approved the manuscript.

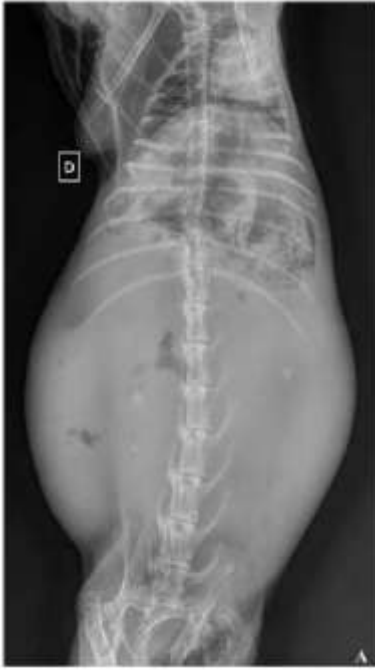Competing Interest

The authors report no conflict of interest related to this case report.

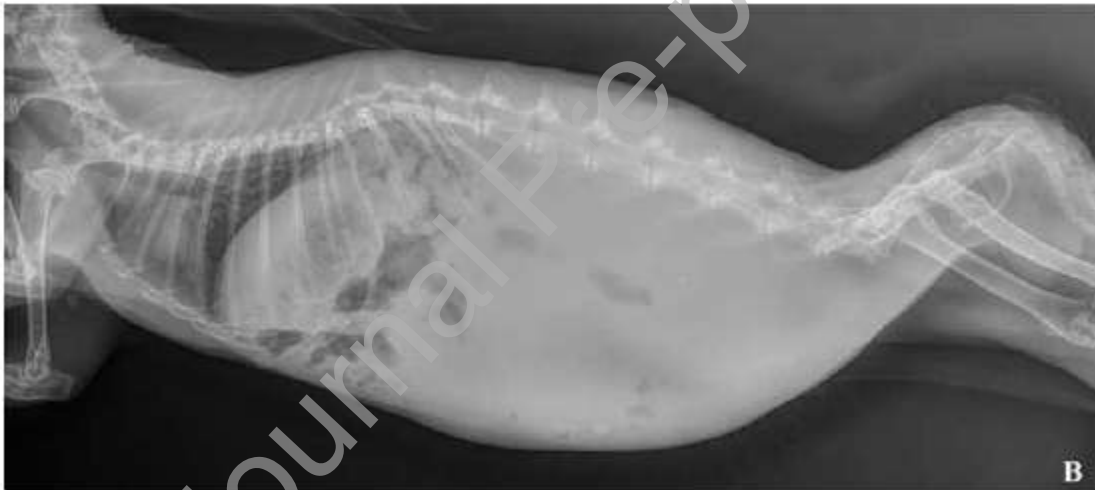
References

1. Künzel F, Grinninger P, Shibly S, Hassan J, Tichy A, Berghold P, et al. Uterine disorders in 50 pet rabbits. *J Am Anim Hosp Assoc* 2015;51(1):8-14.
2. Harcourt-Brown FM. Disorders of the reproductive tract of rabbits. *Vet Clin North Am Exot Anim Pract* 2017;20(2):555-87.
3. Segura P, Martinez J, Pris B, Selva L, Viana D, Penades JR, et al. Staphylococcal infections in rabbit does on two industrial farms. *Vet Rec* 2007;160(25):869-72.
4. Carpenter JW, Marion CJ. *Exotic animal formulary*. 5th ed. St. Louis: Elsevier Pub; 2018.
5. Keating SCJ, Thomas AA, Flecknell PA, Leach MC. Evaluation of EMLA cream for preventing pain during tattooing of rabbits: changes in physiological, behavioural and racial expression responses. *PLoS One* 2012;7:1-11.

6. Harada K, Arima S, Niina A, Kataoka Y, Takahashi T. Characterization of *Pseudomonas aeruginosa* isolates from dogs and cats in Japan: current status of antimicrobial resistance and prevailing resistance mechanisms. *Microbiol Immunol* 2012;56(2):123-7.
7. Coggan JA, Melville PA, de Oliveira CM, Faustino M, Moreno AM, Benites NR. Microbiological and histopathological aspects of canine pyometra. *Braz J Microbiol* 2008;39(3):477-83.
8. Hedley J. Antibiotic usage in rabbits and rodents. *In Pract* 2018;40:230-7.
9. Varga M. Textbook of rabbit medicine. 2nd ed. St. Louis: Elsevier Pub; 2014.
10. Leekha S, Terrell CL, Edson RS. General principles of antimicrobial therapy. *Mayo Clinic Proc* 2011;86(2):156-67.
11. Hagman R, Kühn I. *Escherichia coli* strains isolated from the uterus and urinary bladder of bitches suffering from pyometra: comparison by restriction enzyme digestion and pulsed-field gel electrophoresis. *Vet Microbiol* 2002;84(1-2):143-53.
12. Herrera JJ, Haywood-Watson RJ, Grill RJ. Acute and chronic deficits in the urinary bladder after spinal contusion injury in the adult rat. *J Neurotrauma* 2010;27(2):423-31.



(a)



(b)

Fig. 1. Radiographs, ventrodorsal (A) and lateral (B) views. A large abdominal mass of soft tissue opacity occupies the caudal and mid-abdomen and displaces the cecum and small bowel cranially and ventrally. The letter *D* (*dexter*) on the ventrodorsal view indicates the right side of the patient.

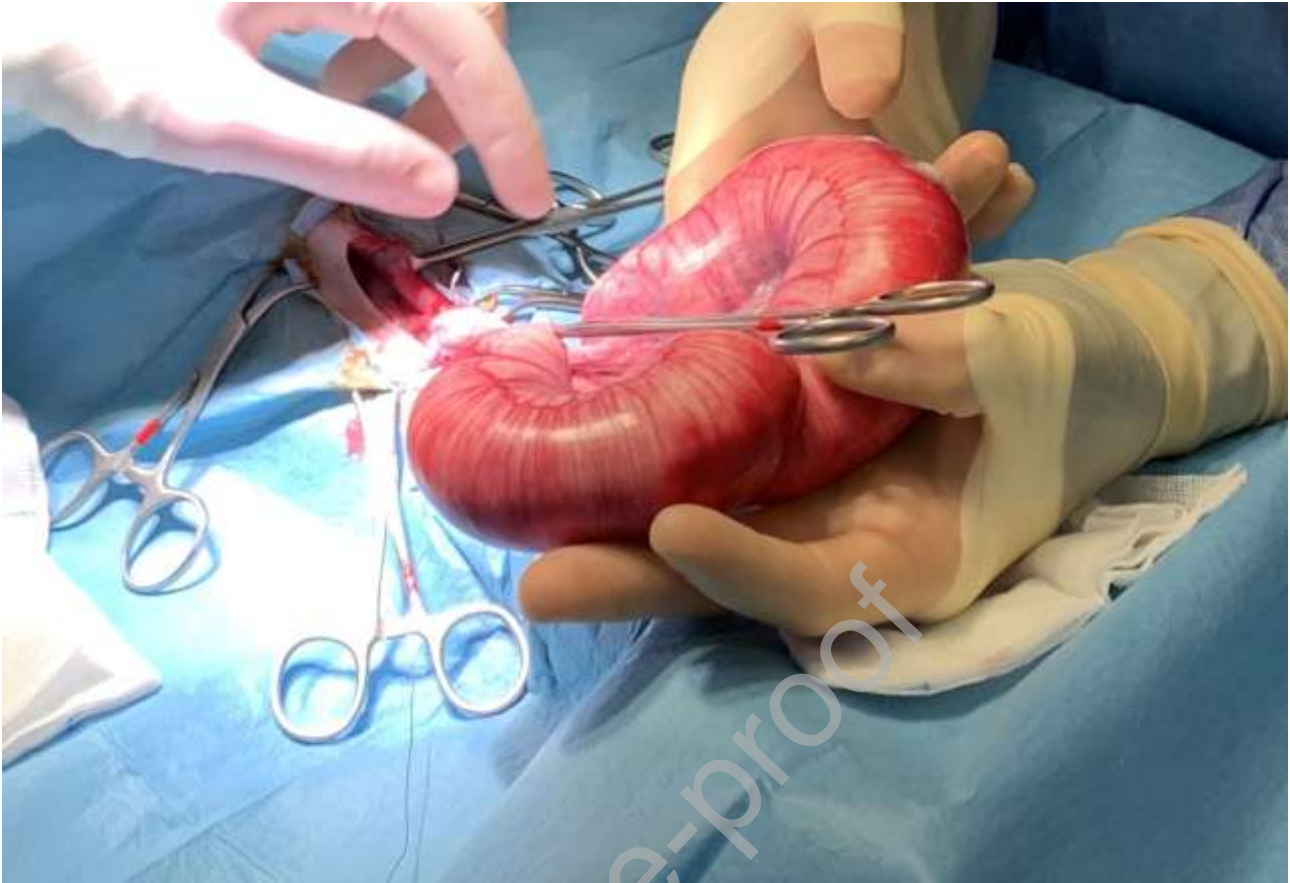


Fig. 2. Intraoperative photograph from the patient in Figure 1. The patient is positioned in dorsal recumbency, the abdomen is surgically opened, and the uterus is exteriorized. The uterus is enlarged with white material on the wall of the right uterine horn, indicating damage.

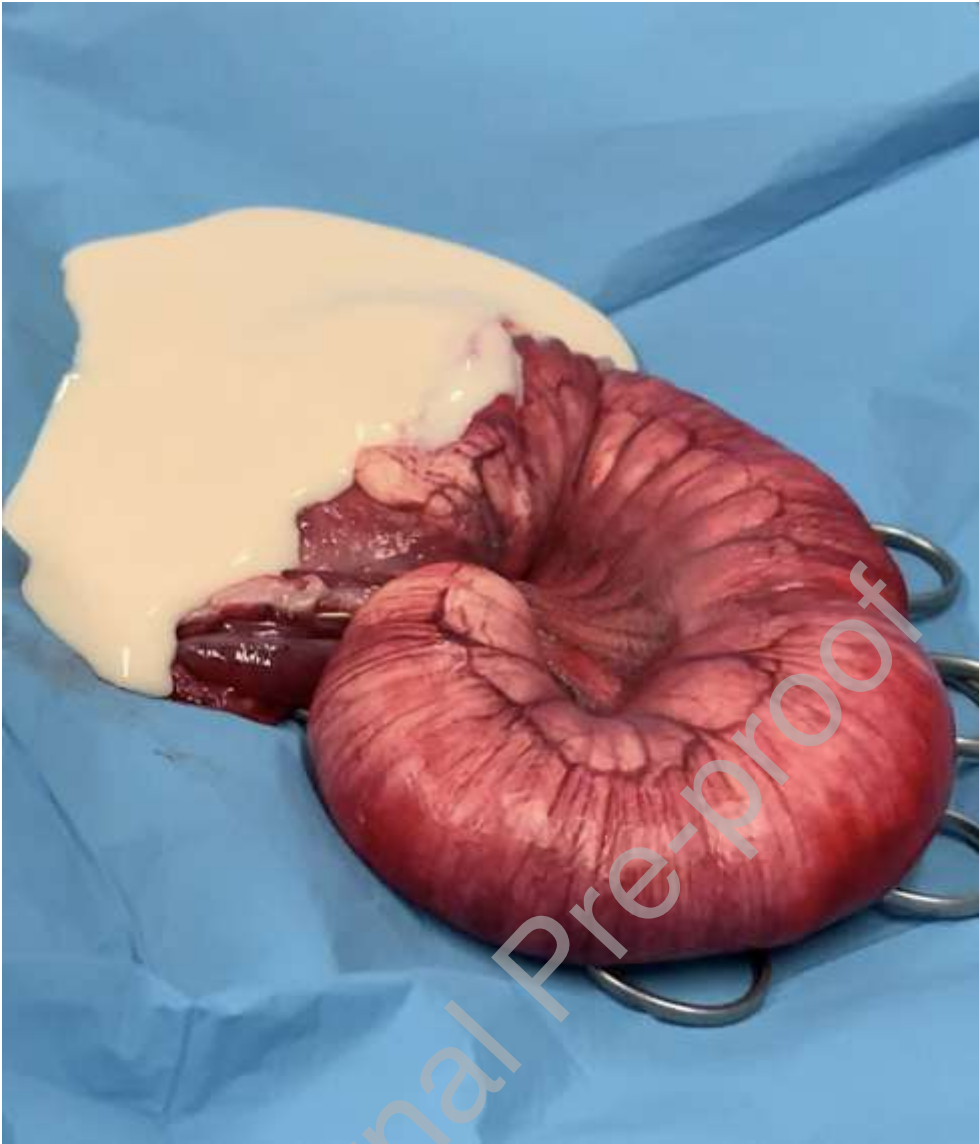

Fig. 3. Appearance of the uterus that was removed from the patient in Figure 1. A longitudinal section was performed, and the white exudate filling the organ leaked onto the surgical drape.