

# Ultra-high-molecular-weight Polyethylene (UHMWPE) Wing Method for Strong Cranioplasty

Kazuki KOBAYASHI,<sup>1</sup> Tadato YUKIUE,<sup>1</sup> Hideyuki YOSHIDA,<sup>1</sup> Nobushige TSUBOI,<sup>1,2</sup> Yuu TAKAHASHI,<sup>1,2</sup> Keigo MAKINO,<sup>1</sup> Ryu KIMURA,<sup>1</sup> Ryo MIZUTA,<sup>1</sup> Susumu SASADA,<sup>1</sup> Tomoyuki OGAWA,<sup>1</sup> Noriyuki NAGAYAMA,<sup>3</sup> Takao YASUHARA,<sup>2</sup> and Isao DATE<sup>2</sup>

<sup>1</sup>Department of Neurosurgery, Tsuyama Chuo Hospital, Tsuyama, Okayama, Japan

<sup>2</sup>Department of Neurological Surgery, Okayama University Graduate School of Medicine, Dentistry and Pharmaceutical Sciences, Okayama, Okayama, Japan

<sup>3</sup>Industrial Technology Center of Okayama Prefecture, Okayama, Okayama, Japan

## Abstract

We developed a new cranioplasty method that utilizes artificial bone made of ultra-high-molecular-weight polyethylene, with a wedge-shaped edge (UHMWPE Wing). This study shows the methods and data of case series and finite element analyses with the UHMWPE Wing. A circumferential wing was preoperatively designed for a custom-made artificial bone made of UHMWPE to achieve high fixed power and to minimize the usage of cranial implants. Here, we present 4 years of follow-up data and finite element analyses for patients treated with the UHMWPE Wing between February 2015 and February 2019. Eighteen consecutive patients underwent cranioplasty using our UHMWPE Wing design. There were no postoperative adverse events in 17 of the patients for at least 18 months. One case of hydrocephalus experienced screw loosening and graft uplift due to shunt malfunction. Placement of a ventriculo-peritoneal shunt immediately returned the artificial bone to normal position. Finite element analyses revealed that a model using the UHMWPE Wing had the highest withstand load and lowest deformation. This is the first report on the UHMWPE Wing method. This method may enable clinicians to minimize dead space and achieve high strength in cranioplasty.

Keywords: artificial bone, cranioplasty, finite element analyses, ultra-high-molecular-weight polyethylene

## Introduction

Cranioplasty using artificial bone is an established procedure for patients with open skull fracture, complicated fracture, bone absorption, and infection of the skull. Artificial bone must be unsusceptible to infection and immune reactions, must be stronger than autologous bone, and must offer patient aesthetic satisfaction. The titanium plate and screw system

was invented and first used in neurosurgery in 1991.<sup>1</sup> Other fixation systems, artificial bones, and artifacts have subsequently been developed and used around the world. Titanium mesh and artificial bones made of alumina ceramics, apatite ceramics, and recently, ultra-high-molecular-weight polyethylene (UHMWPE) are the main materials used in cranioplasty. UHMWPE is useful because it is lightweight and strong. UHMWPE was first reported in the medical literature in ankle joint prostheses in 1975.<sup>2</sup> Since then it has been used in joint replacement prostheses, in combination with a metal surface against which it articulates.<sup>3,4</sup> UHMWPE is a subset of thermoplastic polyethylene, which is characterized by its lightness, non-toxicity, high strength, high

Received February 1, 2021; Accepted April 28, 2021

Copyright© 2021 The Japan Neurosurgical Society  
This work is licensed under a Creative Commons Attribution-NonCommercial-NoDerivatives International License.

bioaffinity, and non-porous structure.<sup>3)</sup> Very recently, successfully scheduled cranioplasty using UHMWPE cranial plates in two patients with meningioma was reported.<sup>5)</sup>

This article examines the usefulness of the UHMWPE Wing design, which is artificial bone made of UHMWPE that has a wedge-shaped edge. We demonstrate that the development of the UHMWPE Wing method has enabled safer and easier cranioplasty. The method is presented herein together with our case series and finite element analyses data.

## Methods

### Development of the UHMWPE Wing method

Three weeks or more before cranioplasty, patients with bone defects undergo CT scan, and the resultant digital imaging and communications in medicine (DICOM) data is sent to the manufacturing company (Kyocera Corporation, Kyoto, Japan). The UHMWPE Wing is created by adding a wedge-shaped edge that has a wing-like appearance circumferentially to artificial bone made of UHMWPE (SKULPIO; Figs. 1A–F).

### Case series

The UHMWPE Wing was utilized in patients undergoing cranioplasty with artificial bone at our institute between February 2015 and February 2019. The inclusion criteria of this case series were cases of external decompression after infection, open or complicated fractures, and skin defects with exposure of the artificial bone placed in a previous surgery. Cases of scheduled tumor removal with bony invasion were also included. Patient cranioplasty data were obtained and evaluated. All patients provided informed consent and received printed information on the fixation methods. This study was approved by the Institutional Review Board and the Ethics Committee of Tsuyama Chuo Hospital, Japan (IRB#448).

### Finite element analyses

Three-dimensional finite element analyses were performed to analyze the relationship between load and deformation in fixed artificial bone. Models were designed to analyze the fixation of the round artificial bone to the bone edge using screws with or without a titanium plate, in accordance with the artificial bone shape (Fig. 1G–I). The relationship between the load on the artificial bone and deformation was evaluated (Fig. 1J). The results of finite element analyses for various settings were compared. Six conditions were compared, including alumina

ceramics with a plate and screws (with polyethylene cap), apatite ceramics with a plate and screws, UHMWPE Wing (UHMWPE plate with a wedge-shaped edge and screws), UHMWPE plate with a plate and screws, titanium artificial bone with screws, and titanium mesh with screws. Finite element analyses were performed collaboratively at the Industrial Technology Center of Okayama Prefecture using MSC Software Marc/Mentat 2018 (MSC Software Co, LA, CA, USA).

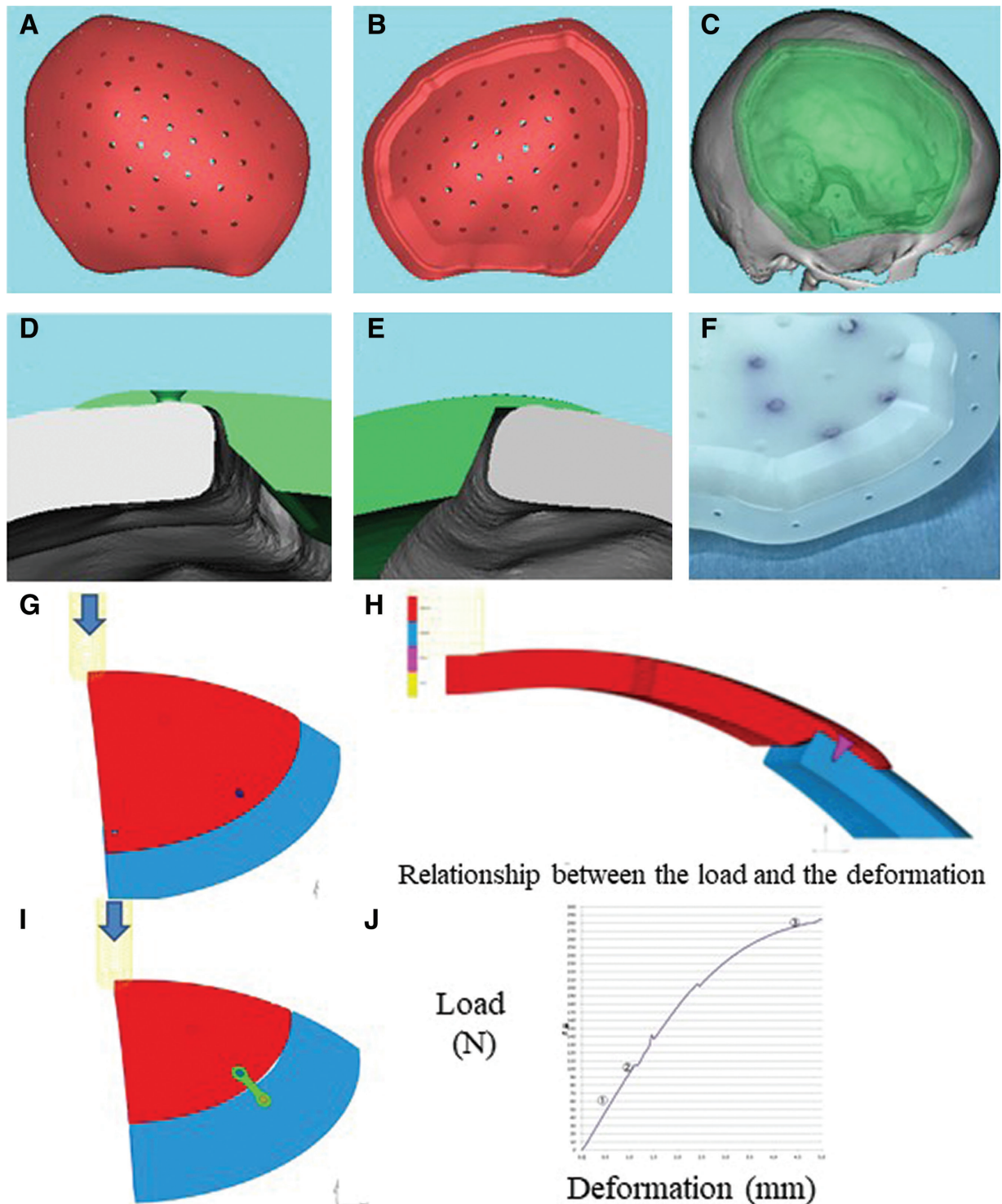
## Results

### UHMWPE Wing development

First, the UHMWPE plate was utilized as a common artificial bone that could be fixed to the bone edge by a plate and screw systems. Next, the edge was added with a subsequent minor change in the width ranging from 2 to 10 mm in accordance with the shape and position of the bone edge. The added edge was made thinner in the front for cosmetic reasons. The hole at the added edge was designed to be a counterbored hole that corresponds to the shape of inserted screws (Fig. 2).

### Case series data

The causes of bone defects in the 18 patients who underwent cranioplasty with the UHMWPE Wing (male: 12, female: 6; median age: 61 years old [range, 14–87]) were as follows: infection: 12, open or complicated fracture: 3, tumor invasion to bone: 2, and skin defect and exposure of titanium mesh: 1. The median area of the skull defect was 87 cm<sup>2</sup> (range 32–178 cm<sup>2</sup>). As described below, only one case required additional surgery for floating cranioplasty (1/18: 5.6%). There were no cases with postoperative infection, ruptured sutures, bone absorption, implant exposure, or graft sinking in the remaining 17 cases for at least 18 months. The complication rate of traditional cranioplasty using artificial bone between 2012 and 2015 was 31% (4/13) in our institute, and all of the complications were infections. Thus, the short-term results of the UHMWPE Wing method are reasonable. The median duration between external decompression and cranioplasty with the UHMWPE Wing was 155 days (22–741 days). Screw loosening, migration, and graft uplift were observed in one case of hydrocephalus with high intracranial pressure induced by lumbo-peritoneal shunt malfunction (Fig. 3). Placement of a ventriculo-peritoneal shunt immediately returned the artificial bone to the normal position without additional cranial surgeries. The patient lived without further adverse events for 3 years after shunt placement.



**Fig. 1** UHMWPE Wing and finite element analyses. (A and B) Three-dimensional (3D) images of the UHMWPE Wing are shown (A: outer surface, B: inner surface). (C) Preoperative 3D CT shows a bone defect utilized to make an UHMWPE artificial bone for cranioplasty. (D and E) Cross-section surface of the UHMWPE Wing (D: screw-insertion site, E: wedge-shaped edge at the frontal region). (F) Inner surface of the UHMWPE Wing. (G and H) 3D images of the load and UHMWPE Wing (G: outer surface, H: cross-section surface). A gray arrow shows the load direction. (I) A 3D image of the load and UHMWPE plate fixed with a plate and screws. A gray arrow shows the load direction. (J) Load–deformation relationship.



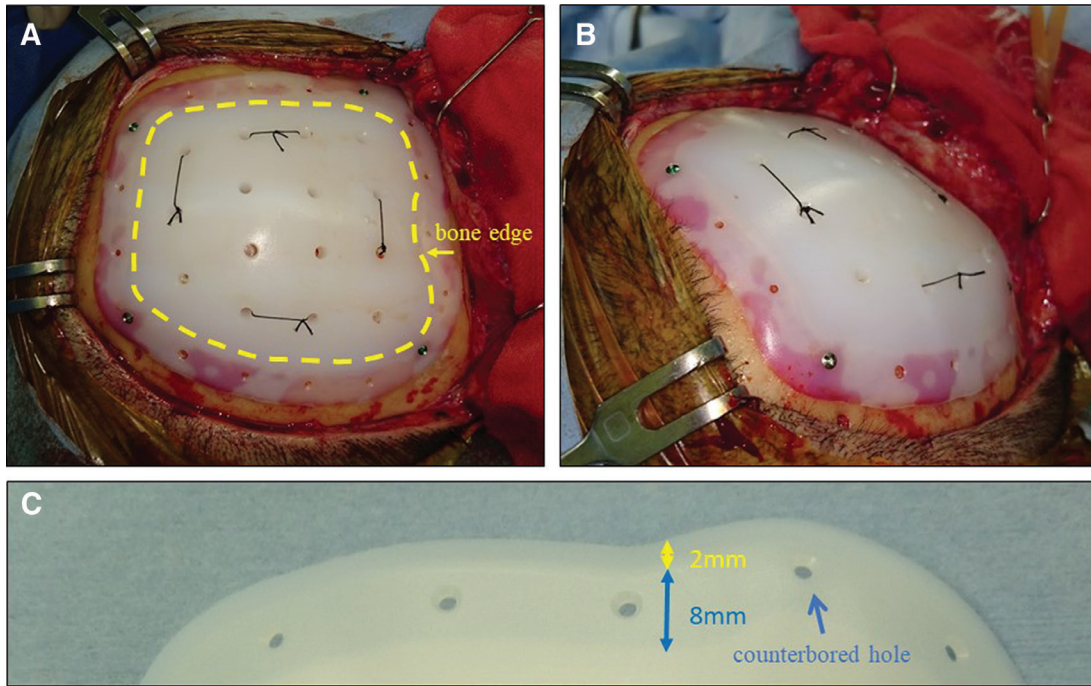


Fig. 2 Clinical usage of the UHMWPE Wing in cranioplasty. (A and B) A UHMWPE plate with the UHMWPE Wing placed in a bone defect. Black string is used to tent the dura mater. The yellow dotted line indicates the bone edge. (C) The UHMWPE Wing design. A tapered 2 mm edge is added to the 8 mm edge of the UHMWPE plate. The counterbored holes are made with stable intervals for easy clinical use.

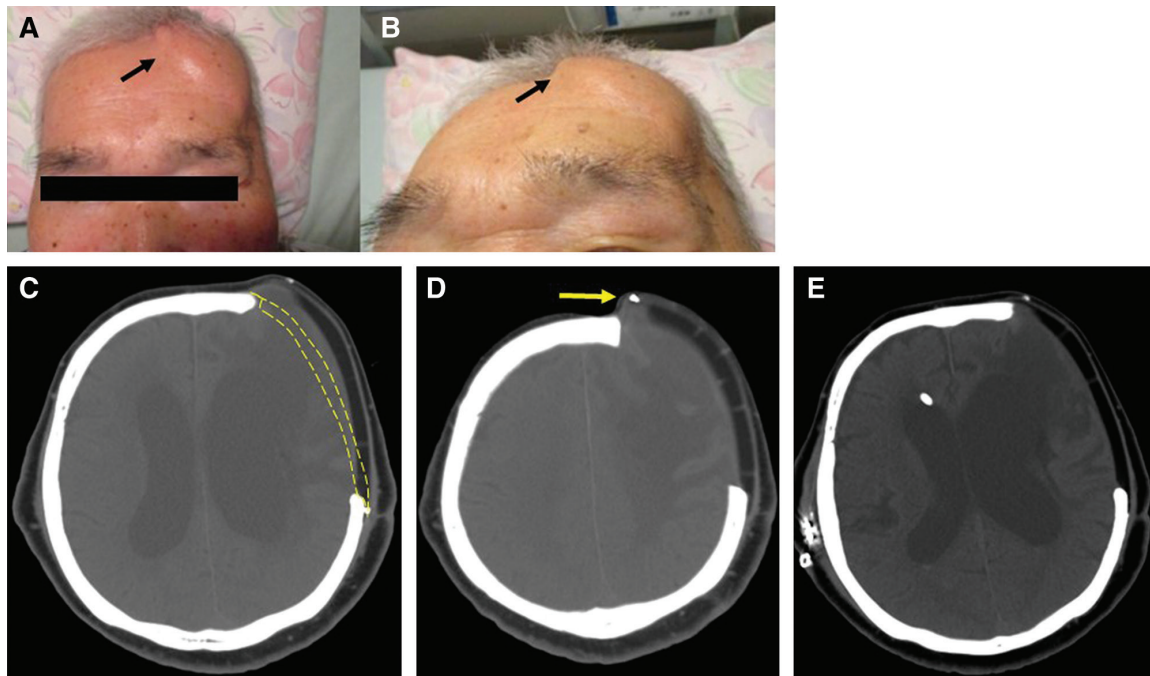


Fig. 3 A case with graft uplift and screw migration due to increased intracranial pressure caused by shunt malfunction. (A and B) Photos of a case with graft uplift showing a bulging scalp (black arrow). (C and D) CT images of a case with an uplifted UHMWPE plate. The yellow dotted line shows the original site of the UHMWPE plate. The yellow arrow shows a migrated screw. (E) The UHMWPE plate almost returned to place after ventriculo-peritoneal shunt.

## Finite element analyses

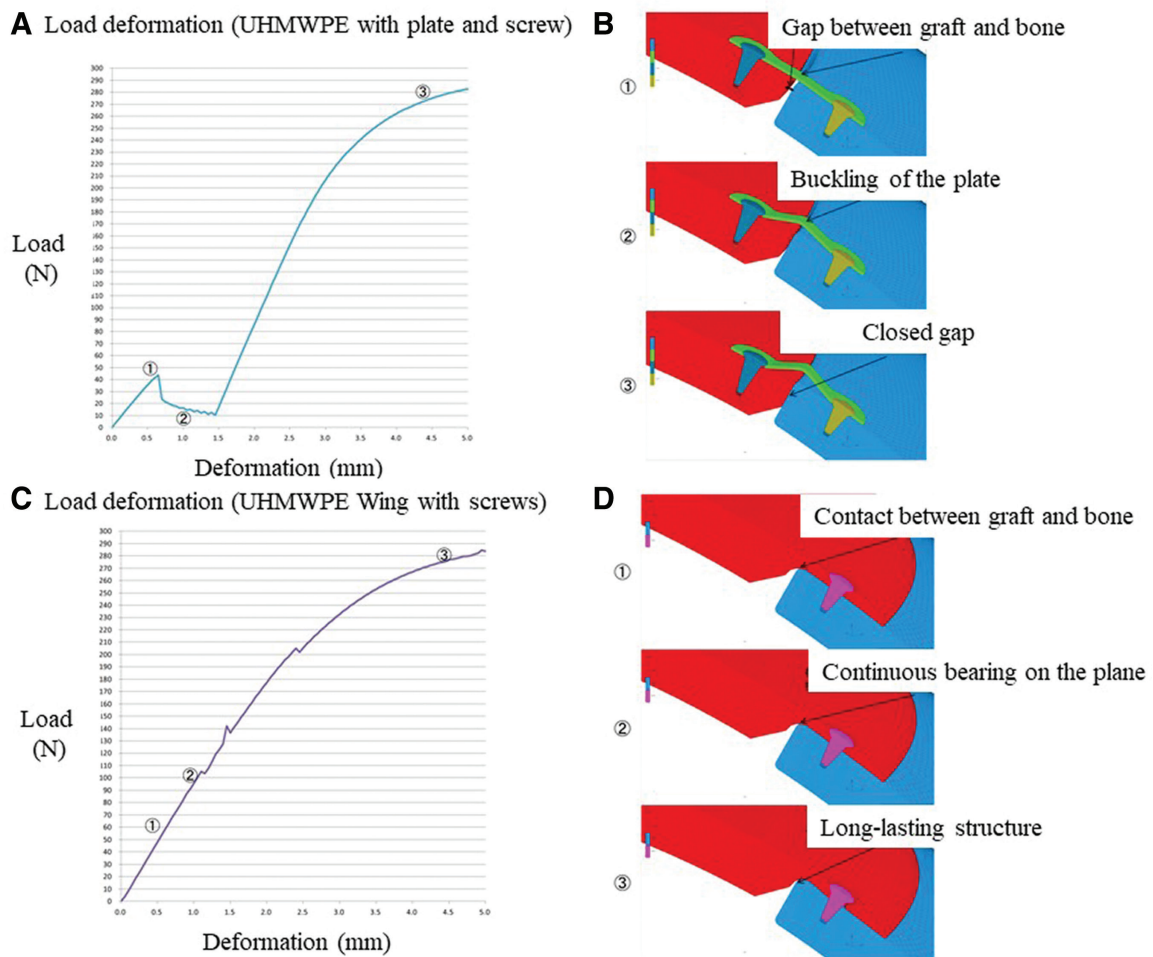
In the analyses, the round hole was made as a craniotomy site and various materials of a round graft was fixed at 4 points every 90°. A rod (diameter: 10 mm) was put at the center of the graft and the vertical load was applied. The relationships between load and deformation in UHMWPE with a plate and screws (Fig. 4A and 4B) and in the UHMWPE Wing (UHMWPE with a wedge-shaped edge and screws, Fig. 4C and 4D) are shown, respectively. This study compared six conditions (Fig. 5). Cranioplasty using a plate and screws led to buckling of the plate with subsequent misalignment and contact between the graft and the bone. Cranioplasty without a plate resulted in a relatively gentle load–deformation curve. Titanium mesh and a plate exhibited more deformation than the UHMWPE Wing.

## Discussion

In this article, we presented the UHMWPE Wing method for strong cranioplasty together with our case series and finite element analyses data. Seventeen cases had uneventful postoperative courses for at least 18 months. Displacement of the graft occurred in one case of hydrocephalus due to shunt malfunction. The graft uplift might be due to the fixation by only four screws and the early timing of complication after surgery with no tissue adhesion between the subcutaneous tissue and bone. Finite element analyses revealed the strong load–deformity characteristics of the UHMWPE Wing.

### Complications after cranioplasty

Cranioplasty is a relatively common neurosurgical procedure. Artificial bone is used in cases where



**Fig. 4** Finite element analyses in the model using a UHMWPE plate fixed with a plate and screws and a UHMWPE Wing fixed with screws. (A and B) A UHMWPE plate fixed with a plate and screws. (A) Load–deformation relationship. (B) Analyses of the load–deformation curve in each phase. (C and D) UHMWPE Wing fixed with screws. (C) Load–deformation relationship. (D) Analyses of the load–deformation curve in each phase.

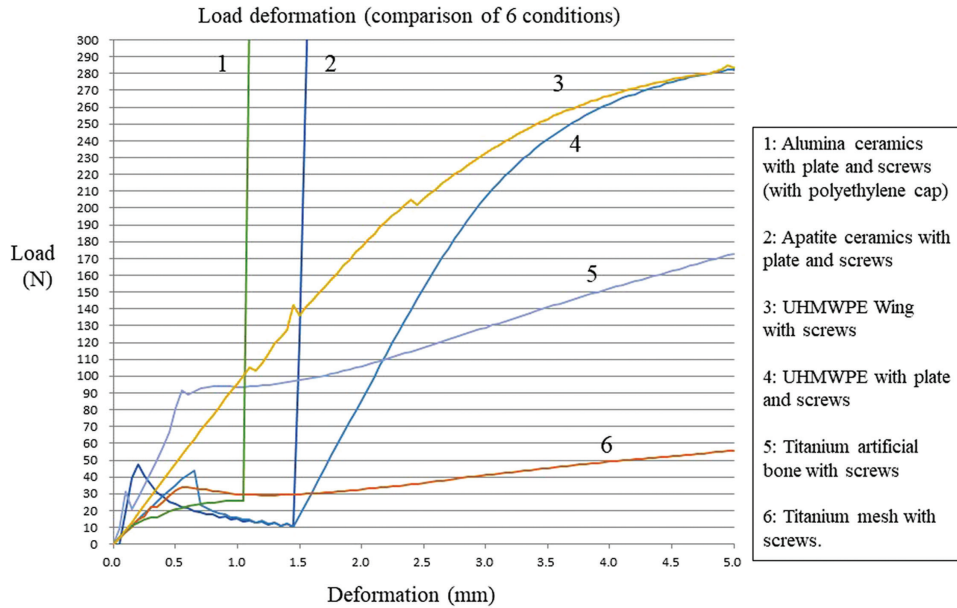


Fig. 5 Comparison of the load–deformation relationship in six conditions.

an autologous bone flap cannot be utilized. Cranioplasty can involve postoperative complications. In Western Australia, for example, the incidence of complications after cranioplasty using titanium mesh was reported to be 29% in 127 cranioplasties.<sup>6)</sup> The most frequent complication was infection, with an incidence of 18%, and large titanium mesh was a significant risk factor for infection. In England, a similar study reported rates of complication and titanium plate removal of 26% and 10%, respectively.<sup>7)</sup> The cause of system removal was infection in approximately 70% of cases. The risk factors for complications were trauma as the initial disease and large skull defect. A Japanese study reported a complication rate of 12% in 155 non-titanium cranioplasties over 11 years (starting in 2005).<sup>8)</sup> Infection was the most frequent complication, occurring in two-thirds of complication cases. Very recently, a national questionnaire survey on complications related to cranial implants was performed. The results revealed only a few cases of infection following cranioplasties using UHMWPE plates, although they have only recently begun to be used as artificial bone in Japan.<sup>9)</sup>

#### Advantages of the UHMWPE Wing

Although titanium mesh is easy to place without other plates, the dead space is relatively large. In contrast, artificial bone made of alumina ceramics, apatite ceramics, or other material has minimal dead space, but usually requires plates and screws. Embedded cranioplasty with polyetheretherketone

was reported to be superior to cover cranioplasty using titanium mesh in overall complications, postoperative new seizures, postoperative implant exposure, and reoperation rate.<sup>10)</sup> The gap between the artificial bone and the bone edge might widen over time. The UHMWPE Wing has negligible aesthetic problems and surgical fixation is very easy. The study to reveal the change of knee joint implants over time showed that oxidative degradation of UHMWPE implants after EOG sterilization was minimal at 23 years after surgery.<sup>11)</sup> Its superior strength was demonstrated in finite element analyses. UHMWPE Wing is stronger for impactive force than alumina ceramics or apatite ceramics with less deformation than titanium bone or mesh. The circumferential, wedge-shaped edge enabled stable contact to the skull bone during load on the artificial bone. The UHMWPE Wing may thus be an ideal form of artificial bone for cranioplasty. Additionally, the UHMWPE Wing method eliminates three plates per cranioplasty with an accompanying cost reduction of approximately US\$330 in Japan compared to other cranioplasty methods using embedded types of artificial bones. In Japan, the cost of artificial bones is US\$7000–8000 and depends only on the size, not on the materials or the processing of the edge.

#### Detailed information on finite element analyses

In cranioplasties with plates and screws, plates initially bear the load on artificial bones (Fig. 4A1). When the load exceeds the bearing power of plates,



plastic deformation occurs in the plates (Fig. 4A2). After the gap between the bone and grafts (artificial bones) closes, the grafts themselves bear the load in contact with the bone edge (Fig. 4A3). In models using ceramics, the subsequent rise is precipitous compared to that in models using UHMWPE plates, mainly due to the different Young's modulus of the material. In cranioplasties with a covered type of artificial bones, the degree of plastic deformation depends on the stiffness properties of the artificial bones. In models using titanium mesh and titanium artificial bone, plastic deformation starts from the beginning of the load addition. The gradient difference between titanium mesh and plates is due to the stiffness properties. The difference in the maximum load is caused by the difference in pure titanium (titanium mesh) and titanium alloy (titanium artificial bone) in stress at yield. In UHMWPE Wing models, the contact between the artificial bone and the bone edge continues from the beginning after the load increases (Fig. 4C1). The smooth load–deformation curve was due to the lower Young's modulus of UHMWPE than that of ceramics.

### Study limitations

Our case series is a retrospective study with a small number of patients from a single institute that shows our initial 4-year experience of the UHMWPE Wing method. The UHMWPE Wing method is helpful to surgeons because of its ease of administration, lightweight properties, and strong fixation power against load. This method is expected to be used worldwide because surgeons only require DICOM data (with the cooperation of the company). A further accumulation of cases using the UHMWPE Wing for a longer follow-up period and a prospective multicenter study should be performed to demonstrate the real advantages of UHMWPE and the UHMWPE Wing method. Finite element analyses show the superiority of the UHMWPE Wing. In clinical settings, however, there are many factors that affect the results of cranioplasty. The shape and location of the defect, bone quality, skin thickness, and other patient-derived factors significantly affect the results. Finite element analyses have several limitations and cannot be perfectly applied to the clinical setting, although they can demonstrate the comparison in physically equal conditions.

### Conclusions

The UHMWPE Wing method for strong cranioplasty was presented herein. Our initial 4-year case series

showed good outcomes with this method. Finite element analyses demonstrated superior strength against load in the model using the UHMWPE Wing. Although further examination is needed to fully clarify its merits, the UHMWPE Wing method may change the clinical practice of cranioplasty.

### Acknowledgments

We thank Kenji Takekawa and Kyocera Corporation, Japan for technical support.

### Conflicts of Interest Disclosure

The authors have no COI to be declared related to this study.

### References

- 1) Smith SC, Pelofsky S: Adaptation of rigid fixation to cranial flap replacement. *Neurosurgery* 29: 417–418, 1991
- 2) Kempson GE, Freeman MA, Tuke MA: Engineering considerations in the design of an ankle joint. *Biomed Eng* 10: 166–171, 180, 1975
- 3) Pietrzak WS: Ultra-high molecular weight polyethylene for total hip acetabular liners: a brief review of current status. *J Invest Surg* 34: 321–323, 2019
- 4) Rose RM, Radin EL: A prognosis for ultra high molecular weight polyethylene. *Biomaterials* 11: 63–67, 1990
- 5) Oishi T, Sameshima T, Totsuka T, Yamasaki T, Koizumi S, Namba H: Cosmetic and neuroprotective placement of custom-made ultra-high-molecular-weight polyethylene cranial plate (SKULPIO) in single-step surgery: technical note and case report. *World Neurosurg* 130: 187–191, 2019
- 6) Wiggins A, Austerberry R, Morrison D, Ho KM, Honeybul S: Cranioplasty with custom-made titanium plates--14 years experience. *Neurosurgery* 72: 248–256; discussion 256, 2013
- 7) Mukherjee S, Thakur B, Haq I, Hettige S, Martin AJ: Complications of titanium cranioplasty--a retrospective analysis of 174 patients. *Acta Neurochir (Wien)* 156: 989–998; discussion 998, 2014
- 8) Shibahashi K, Hoda H, Takasu Y, Hanakawa K, Ide T, Hamabe Y: Cranioplasty outcomes and analysis of the factors influencing surgical site infection: a retrospective review of more than 10 years of institutional experience. *World Neurosurg* 101: 20–25, 2017
- 9) Yasuhara T, Murai S, Mikuni N, Miyamoto S, Date I: Japanese National Questionnaire Survey in 2018 on complications related to cranial implants in neurosurgery. *Neurol Med Chir (Tokyo)* 60: 337–350, 2020
- 10) Zhang Q, Yuan Y, Li X, et al.: A large multicenter retrospective research on embedded cranioplasty

- and covered cranioplasty. *World Neurosurg* 112: e645–e651, 2018
- 11) Oonishi H, Ueno M, Kim SC, et al.: Ceramic versus cobalt-chrome femoral components; wear of polyethylene insert in total knee prosthesis. *J Arthroplasty* 24: 374–382, 2009

---

Corresponding author: Takao Yasuhara, MD

Department of Neurological Surgery, Okayama University Graduate School of Medicine, Dentistry and Pharmaceutical Sciences, 2-5-1, Shikatacho, Kita-ku, Okayama, Okayama 700-8558, Japan.  
*e-mail:* tyasu37@cc.okayama-u.ac.jp