

Case Report

Vasculitis and Breast Cancer: Mind the Hint

Miguel Esperança-Martins^{a, b, c} Vasco Evangelista^d Salomão Fernandes^e
Raquel Almeida^d

^aMedical Oncology Department, Hospital de Santa Maria, Centro Hospitalar Universitário Lisboa Norte, Lisbon, Portugal; ^bSérgio Dias/Vascular Biology and Cancer Microenvironment Lab, Instituto de Medicina Molecular João Lobo Antunes, Faculdade de Medicina da Universidade de Lisboa, Lisbon, Portugal; ^cLuís Costa/Translational Oncobiology Lab, Instituto de Medicina Molecular João Lobo Antunes, Faculdade de Medicina da Universidade de Lisboa, Lisbon, Portugal; ^dInternal Medicine Department, Hospital Beatriz Ângelo, Loures, Portugal; ^eInfectious Diseases Department, Hospital Beatriz Ângelo, Loures, Portugal

Keywords

Diffuse alveolar haemorrhage · Paraneoplastic vasculitis · Plasmapheresis; Breast cancer

Abstract

Diffuse alveolar haemorrhage related to an anti-neutrophil cytoplasmic antibody (ANCA)-associated small vessel vasculitis is an extremely rare form of presentation of breast cancer. Here we report the case of a 77-year-old woman with a histological diagnosis of a papillary ductal carcinoma of the breast presenting with a diffuse alveolar haemorrhage secondary to a perinuclear ANCA-associated vasculitis. To our knowledge, this is the first case ever reported of a diffuse alveolar haemorrhage related to an ANCA-associated small vessel vasculitis as a form of presentation of breast cancer. The therapeutic approach of this paraneoplastic vasculitis included the use of corticosteroids and plasmapheresis, a very useful technique to remove endothelial aggressors (circulating antibodies) as a strategy to earn time for a proper therapeutic decision specifically directed for disease modification, but that can also be associated with several severe adverse effects, which are illustrated in our case.

© 2021 The Author(s).

Published by S. Karger AG, Basel

Miguel Esperança-Martins
Medical Oncology Department, Hospital de Santa Maria
Centro Hospitalar Universitário Lisboa Norte
Avenida Professor Egas Moniz, PT-1649-035 Lisbon (Portugal)
miguelmemartins@campus.ul.pt

Introduction

Breast cancer (BC) is the most common cause of cancer-related death in women around the world [1]. The clinical presentation of a breast malignancy is frequently composed by a constellation of signs and symptoms that include change in breast shape, skin alterations, nipple inversion, single duct discharge, and an axillary dump [2]. A paraneoplastic vasculitis, especially an anti-neutrophil cytoplasmic antibody (ANCA)-associated vasculitis, is a rare form of presentation of BC. In fact, leukocytoclastic vasculitis is the most frequent type of cancer-associated vasculitis, most commonly related to haematological malignancies [3]. Regardless of the type of vasculitis and the type of malignancy that it is associated with, paraneoplastic vasculitides are very uncommon forms of cancer presentation.

Here we report the case of a 77-year-old woman with a histological diagnosis of a papillary ductal carcinoma of the breast presenting with a diffuse alveolar haemorrhage (DAH) secondary to a perinuclear ANCA (p-ANCA)-associated vasculitis.

Case Presentation

A 77-year-old woman was admitted to the emergency department with a 2-week history of persistent dry cough and progressive severe fatigue associated with three episodes of frank haemoptysis in the previous 24 h. She had also recently noticed a small hard lump in the right breast that was painful to touch. She recalled having skin lesions with characteristics compatible with purpura in the lower limbs 6 months before, which she assumed were related to an antivertigo drug as they disappeared as soon as she stopped taking it. She denied any other symptoms.

The patient had a medical history of hypertension, dyslipidaemia, hyperuricemia, and peripheral vestibular disorder, and was accordingly treated with bisoprolol, lercanidipine, losartan/hydrochlorothiazide, allopurinol, and betahistine.

Initial assessment revealed normal vital signs (with an oxygen saturation of 97% on room air). She had skin and mucosae pallor, discrete rales in the bases of both hemithoraxes, two nodular, hard, and adherent lesions in the upper inner quadrant and peri-areolar region of the right breast, no identifiable adenopathies, and no skin lesions. A complete blood count showed a normocytic and normochromic anaemia, with a haemoglobin value of 7 g/dL, and a slightly elevated NT-proB-type natriuretic peptide value (657 pg/mL).

Urinary Sediment Examination Showed Haematuria and Proteinuria

The arterial blood gas analysis only revealed mild hypoxemia and the chest radiograph showed a bilateral peri-hilar parenchymal infiltrate, located in the inferior two-thirds of the pulmonary fields (Fig. 1).

A computed tomography (CT) angiogram of the thorax was then performed, revealing diffuse, bilateral, ground-glass opacities predominantly located in the inferior and posterior segments of the lungs, which are features compatible with DAH (Fig. 2).

The patient was admitted to the intermediate care unit for adequate clinical surveillance and later on transferred to an internal medicine ward. A flexible bronchoscopy confirmed the presence of blood in the tracheobronchial tree without a visible focal haemorrhagic point. Bacteriological and mycological exams were negative, and no neoplastic cells were found on cytological analysis of the bronchoalveolar lavage.

The immunoserological studies showed high titres of ANCA, both myeloperoxidase (MPO; >134 U/mL) and proteinase-3 (PR3; 4.5 U/mL), positive anti-nuclear antibodies (ANA) with a nucleolar pattern, positive mitosis and a titre of 1:320, normal C3, C4, and CH50 levels,

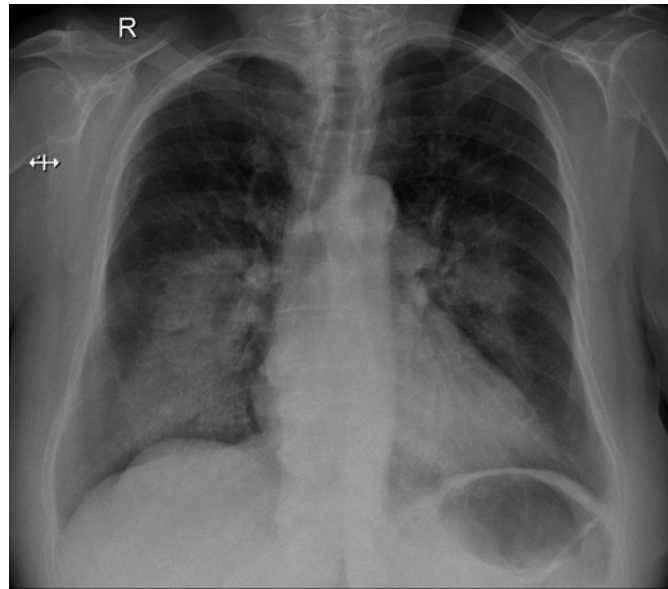


Fig. 1. The patient's chest radiograph when admitted to the emergency department.

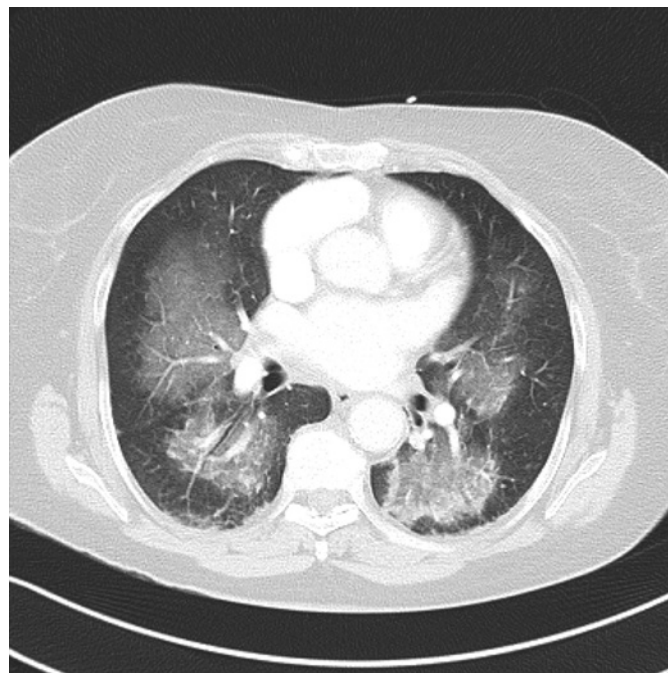


Fig. 2. CT angiogram of the thorax after admission.

negative anti-GBM, anti-dsDNA, anti-CCP antibodies, normal rheumatoid factor levels, and negative serological testing for HIV and hepatotropic viruses (Table 1).

Dermatology observation excluded any skin lesions that could potentially be biopsied. Regarding the documented haematuria and proteinuria, a renal ultrasound was performed showing no alterations. The nephrology team was consulted to evaluate the eligibility of the patient for a renal biopsy. The result of the urinary sediment examination was discredited, as it was performed shortly after algation, with subsequent urinary sediment examination being normal. Renal function evaluations were always normal. Renal involvement was considered to be unlikely and it was considered that there was no indication for renal biopsy. A bilateral mammary ultrasound and digital mammography revealed benign alterations of

Table 1. Laboratory immunoserological investigation

ANCA-MPO	Positive (>134 U/mL)
ANCA-PR3	Positive (4.5 U/mL)
ANA	Positive (1/320)
C3	Normal
C4	Normal
CH50	Normal
Anti-GBM	Negative
Anti-dsDNA	Negative
Anti-CCP	Negative
RF	Normal
Anti-HIV 1/2	Non-reactive
AgHBs	Non-reactive
Anti-HCV	Non-reactive

ANCA-MPO, myeloperoxidase anti-neutrophil cytoplasmic antibodies; ANCA-PR3, proteinase 3-anti-neutrophil cytoplasmic antibodies; ANA, anti-nuclear antibodies; C3, complement component 3; C4, complement component 4; CH50, 50% haemolytic complement activity of serum; anti-GBM, anti-glomerular basal membrane antibodies; anti-dsDNA, anti-double stranded DNA antibodies; anti-CCP, anti-cyclic citrullinated peptide antibodies; RF, rheumatoid factor; anti-HIV 1/2, anti-HIV 1 and 2 antibodies; AgHBs, hepatitis B surface antigen; anti-HCV, anti-hepatitis C antibodies.

the left breast (BI-RADS 2) and suspected malignant alterations of the right breast (BI-RADS 4C; Fig. 3).

Senology experts performed microbiopsies of both lesions of the right breast that were compatible with a papillary ductal carcinoma. Thoracoabdominal-pelvic CT scan and bone scintigraphy were clear. For further complementation of the vasculitis study, a sinus CT scan and an electromyogram were required and were normal.

At this point it was considered that the most likely diagnosis was of a paraneoplastic p-ANCA-associated small vessel vasculitis secondary to a papillary ductal carcinoma of the right breast. During the rest of the patient's hospital stay there was a clinical deterioration with a new episode of haemoptysis, subsequent worsening of her anaemia, and a clear imagological proof (a new thoracic CT angiogram was performed; Fig. 4) of DAH aggravation.

The patient was initially treated with pulse therapy with methylprednisolone (1 g/day) for 3 days and, after that, with prednisolone (1 mg/kg/day). The potential benefit of plasmapheresis was discussed as a way of removing the circulating p-ANCA and, consequently, earning time for a more specifically directed therapeutic approach to the BC. Accordingly, a cycle of nine sessions of plasmapheresis (five on consecutive days, and four on alternate days) was proposed, in association with the ongoing therapy with oral corticosteroids.

Only six sessions were completed due to several adverse effects, particularly significant hypofibrinogenemia, severe thrombocytopaenia (minimum of 15,000 platelets) and anaemia (haemoglobin minimum value of 6.2 g/dL), managed with fibrinogen (2 g), red blood cell (1 unit) and human immunoglobulin (30 g) administration. A new CT angiogram of the thorax showed an impressive decrease of the DAH extension (Fig. 5).

Following a mammary magnetic resonance imaging (MRI) of the right breast (Fig. 6) and the discussion of the case in the multidisciplinary oncology meeting, a radical mastectomy with sentinel lymph node biopsy was suggested.

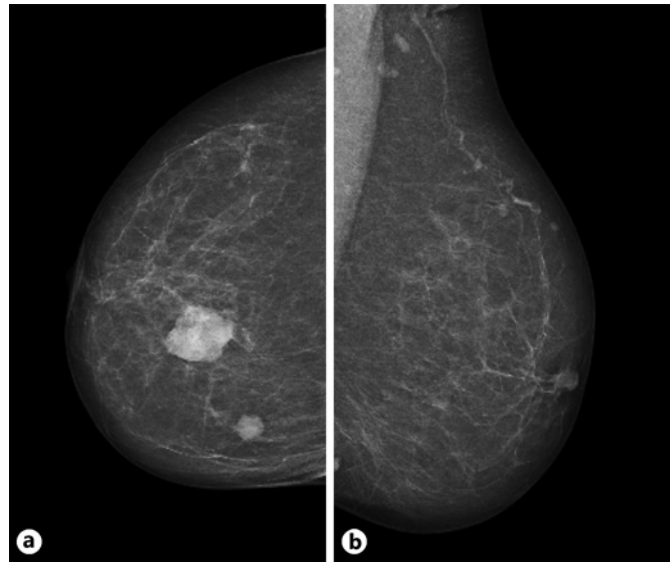


Fig. 3. Digital mammography showing suspected malignant alterations of the right breast (BI-RADS 4C; **a**) and benign alterations of the left breast (BI-RADS 2; **b**).

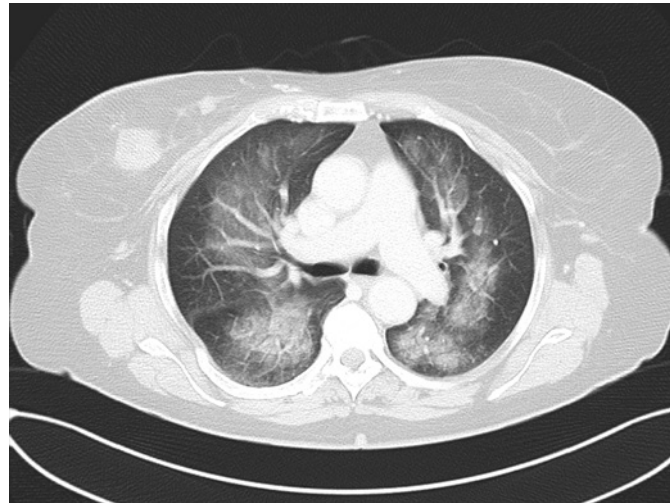


Fig. 4. CT angiogram of the thorax performed during hospitalization, revealing aggravation of the extent of DAH.

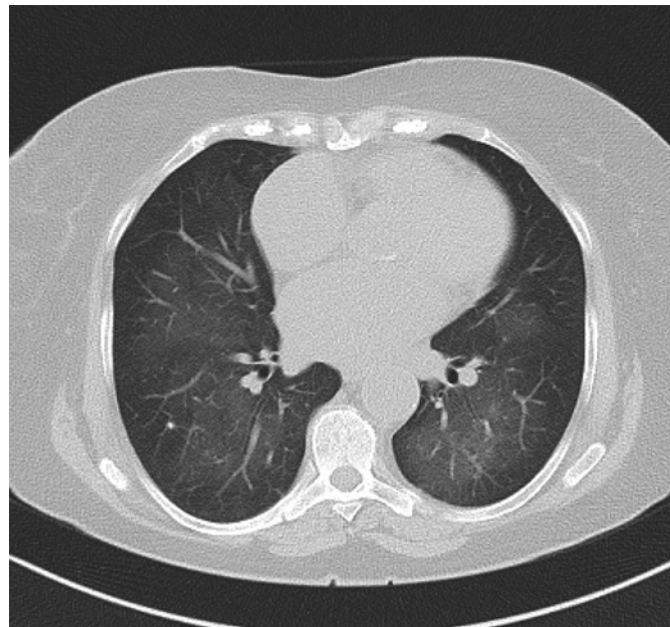


Fig. 5. CT angiogram of the thorax performed after six sessions of plasma-pheresis, revealing an impressive decrease of the extent of DAH.

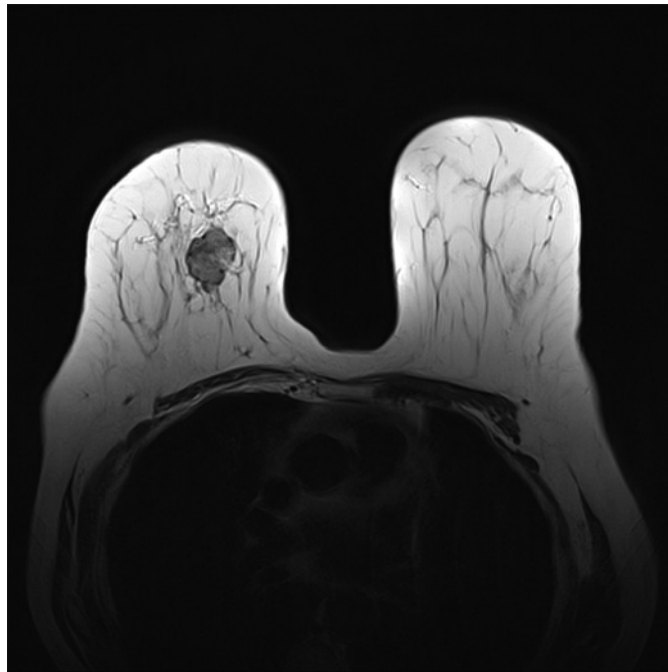


Fig. 6. MRI of the right and left breasts.

Further clinical improvement was observed, and the patient was discharged. Internal medicine, autoimmune diseases, and general surgery appointments were arranged after discharge. The patient was submitted to a radical mastectomy with sentinel lymph node biopsy 2 months after, which was uneventful.

The anatomical-pathological examination of the surgical sample revealed an invasive, micropapillary carcinoma, G2, with extensive haemorrhagic areas, and a diameter of 2.7 cm. The adjacent parenchyma had lesions of focal adenosis, and aspects compatible with invasive ductal carcinoma. Lymphangiosis was observed, with no angioneuro invasion, ER >95%, PR >95%, HER2 –, Ki67 <10%. The surgical margins were tumour free, and the TNM stage was pT2, pN0.

A CT angiogram of the thorax was performed 2 weeks after the surgery, showing complete resolution of DAH (Fig. 7). No distant disease (metastasis) was present. The case was again discussed in the multidisciplinary meeting of BC and the patient was treated with letrozole and zoledronic acid, without any side effects. Unexpectedly, the patient died at home presumably due to complications related to concurrent atrial fibrillation (which had been diagnosed after hospital discharge).

Discussion

To our knowledge, this is the first case ever reported of a DAH related to an ANCA-associated small vessel vasculitis as a form of presentation of BC. There are some other cases that report an episode of DAH as a manifestation of a concomitant disease in a patient with a previous diagnosis of BC and that associate DAH as a short- or long-term complication of the treatment (chemotherapy and radiotherapy) for BC.

The connection between BC and scleroderma renal crisis (SRC) complicated with DAH and pleuro-pericardial effusions was previously reported in a patient who had already been diagnosed (5 months before) with stage IIB BC. When the SRC manifestations arose, the patient had already had a bilateral mastectomy with lymph node resection and had not received systemic anti-neoplastic therapy [4].

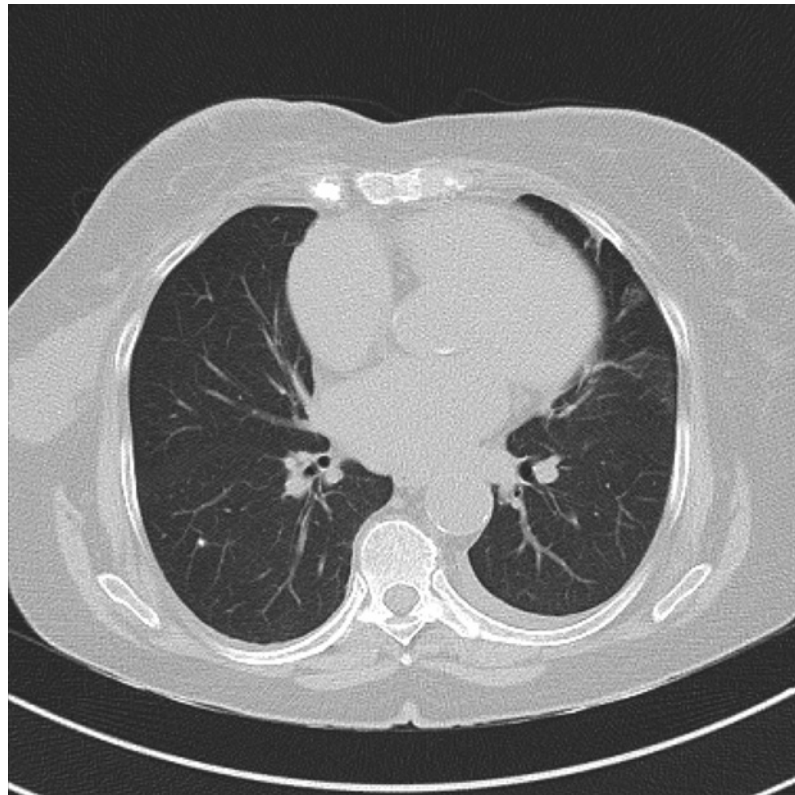


Fig. 7. CT angiogram of the thorax performed 2 weeks after radical right mastectomy.

The development of DAH caused by sequential adjuvant chemoradiotherapy for BC was also described in a female patient with BC (an adenocarcinoma of the left breast, pT1cN0M0) originally treated with conserving surgery and subsequently with adjuvant radiotherapy and chemotherapy. The symptoms related with the evolving DAH appeared 9 days after the third administration of docetaxel and cyclophosphamide (3 months after the final irradiation) [5].

The occurrence of DAH secondary to pulmonary angiosarcoma in post-irradiation and post-radical mastectomy patients is mentioned in the literature. Angiosarcoma arising, several years later, at post-irradiation sites is a well-described phenomenon [6].

DAH consists of diffuse bleeding in the alveolar space. It is defined by the triad of diffuse alveolar infiltrates, haemoptysis, and dropped haematocrit, followed by increased diffusion capacity by 30% [7]. In the present case episodes of frank haemoptysis were reported, and radiographic and tomographic evidence of diffuse alveolar infiltrates and a dropped haematocrit were verified.

Causes of DAH can be inflammatory or non-inflammatory. Inflammatory DAH may be due to ANCA-associated vasculitis with pulmonary capillaritis. There are different genetic, infectious, and immunological factors that interact and play a role in the aetiology of pulmonary vasculitis [7–10].

The immunoserological studies of the patient showed high titres of ANCA, both MPO and PR3, and positive ANA. There was not a previous diagnosis of lupus erythematosus or any manifestations that could suggest it. The anti-dsDNA antibodies were negative, the complement levels were normal, the exam of the urinary sediment was normal, the renal function remained stable, and the anti-MBG antibodies were negative. The most plausible cause for the DAH was an ANCA-associated vasculitis.

ANCA are IgG-type antibodies against cytoplasmic antigens of neutrophils and monocytes (MPO and PR-3) [7]. The ANCA-associated vasculitis comprise granulomatosis with polyangiitis, microscopic polyangiitis, and eosinophilic granulomatosis with polyangiitis. Typical features of granulomatosis with polyangiitis include nasal crusting, stuffiness and epistaxis, upper respiratory tract involvement, and often, when in the context of an active urinary sediment, renal involvement. Patients with microscopic polyangiitis are typically older and present with more severe renal involvement, rash, and neuropathy. Eosinophilic granulomatosis with polyangiitis typically presents as a multisystem disease on a background of asthma, nasal polyposis, and peripheral blood eosinophilia [11].

In this case, the titres of ANCA were not useful for distinguishing between the different types of ANCA-associated vasculitis, since both MPO and PR3 antibodies titres were high. Given the absence of nasal and upper respiratory tract involvement, asthmatic symptoms, and peripheral blood eosinophilia, a microscopic polyangiitis was considered the most likely diagnosis.

The association between cancer and vasculitis is uncommon and, conceptually, hard to establish as it is particularly difficult to define the temporal relationship necessary to draw valid conclusions [3]. Certain cancers may cause a plethora of signs and symptoms that are not linked with tumour invasion and compression [12, 13], syndromes that were labelled “paraneoplastic” in the 1940s [12, 14]. These syndromes are attributed to tumour secretion of functional peptides and hormones or immune cross-reactivity between tumour and normal host tissues [12].

In 1986, Longley et al. [15, 16] suggested that malignant neoplasms might produce antigens and consequently cause paraneoplastic vasculitis. In the same year, McLean [15, 17] defined two criteria to establish the presence of paraneoplastic vasculitis: first, the simultaneous appearance of both vasculitis and neoplasm, and second, their parallel course. Some of the suggested mechanisms for the development of paraneoplastic vasculitis are the production of immunoglobulins directed to the abnormal tumour cells and also the normal endothelium; abnormal production of immunoglobulins that can react to vascular antigens causing formation of in situ immune complexes; release of various cytokines that can cause endothelial injury; induction of a delayed hypersensitivity reaction by deposition of cancer proteins on vessel walls, and overrun of vessel walls. Concomitant precipitating events (infections, drugs) may also cause an immune complex-mediated disorder that can be observed even at the beginning of the neoplastic disease [15–21].

Paraneoplastic vasculitides are estimated to represent 2–5% of all vasculitis [3, 22, 23]. In an 18-year study, 12 patients were diagnosed with both cancer and vasculitis in the same 12-month period [3, 24]. In a 10-year study, 60 patients had a diagnosis of vasculitis associated with malignancies [3, 22]. Hematologic malignancies were one of the most common type of malignancies in both studies, accounting for 50 and 63% of cancers respectively. Carcinomas of the urinary tract accounted for 40% of solid tumours associated with paraneoplastic vasculitis [3, 23]. Leukocytoclastic vasculitis is the most commonly reported paraneoplastic vasculitis [3, 22–24]. There is only a cancer-specific association with a vasculitis – hairy cell leukaemia and polyarteritis nodosa [3, 25]. ANCA-associated vasculitides have rarely been described as paraneoplastic manifestations [3].

Regarding this case, the appearance of skin lesions reported by the patient 6 months before the admission may be related to the antivertigo drug (given the temporal relationship), even though one cannot exclude the possibility of them already being cancer manifestations. The diagnosis of DAH due to an ANCA-associated vasculitis was concomitant with the diagnosis of BC, which supports the paraneoplastic nature of this vasculitis. The singularity of this case is also underlined by the type of paraneoplastic vasculitis (opposed to leukocytoclastic vasculitis, ANCA-associated vasculitis has rarely been described as a para-

neoplastic manifestation) and the type of cancer involved. In fact, in contrast to hematologic and some solid organ malignancies, such as the carcinomas of the urinary tract, BC is rarely associated with paraneoplastic syndromes [26]. Nevertheless, when present, these can occur at any point in the disease's course, even preceding formal diagnosis in some cases [26, 27]. It is also interesting to note that the majority of studies that correlate ANCA-associated vasculitis with an increased cancer risk attribute this to the use of cytotoxic medications for the treatment of the vasculitis, especially cyclophosphamide (a known carcinogen associated with an increased risk for bladder cancer, acute leukaemia, and skin cancer [28]), which was not the case.

The recommended treatment for ANCA-associated vasculitis comprises both remission induction and maintenance phases. The induction of remission may be achieved by the use of daily glucocorticoids plus cyclophosphamide or rituximab. Other regimens using methotrexate or mycophenolate mofetil should only be an option for patients without evidence of organ dysfunction or life-threatening disease. In patients presenting with creatinine >500 $\mu\text{mol/L}$, the addition of plasma exchange to high-dose glucocorticoids and cyclophosphamide or rituximab should be considered [11]. After successful remission induction, guidelines recommend withdrawing the initial immunosuppressive agent and commencing a maintenance regimen with either azathioprine or methotrexate [9, 29, 30].

In the present case, we opted to initially treat the patient with pulse therapy with methylprednisolone and, after that, with prednisolone. We did not include cyclophosphamide in the remission induction therapeutic scheme as there was, by that time and as previously mentioned, a deterioration of the patient's clinical status.

We decided to commence plasma exchange, even though the patient did not meet the recommended criteria, as a way of removing the circulating p-ANCA and earning time for a more specifically directed therapeutic approach to the, by that time, probable BC. A cycle of nine sessions of plasmapheresis was programmed and combined with the ongoing therapy with oral corticosteroids. Our case highlights that plasma exchange can be a very useful technique to remove endothelial aggressors, but several significant adverse effects may be associated with the procedure and must be taken into consideration. In fact, our patient only completed six sessions because of hypofibrinogenemia, severe thrombocytopaenia, and severe anaemia, which were treated accordingly.

Statement of Ethics

Written informed consent was obtained from the patient's next of kin (son) for publication of this case report and all the accompanying images and tables.

Conflict of Interest Statement

The authors have no conflicts of interest to declare.

Funding Sources

No funding sources were used for the development and publication of this case report.

Author Contributions

M.E.-M. wrote the present case report. V.E. critically reviewed it in detail. S.F. and R.A. also provided specific suggestions for the final version. All of the authors actively participated in the clinical management of the patient, not only during her hospital stay, but also after discharge (the patient continued to be followed-up by the team). All of the authors approved this final version of the case report and agree to be accountable for all aspects of the work.

References

- 1 Cardoso F, Kyriakides S, Ohno S, et al. Early breast cancer: ESMO Clinical Practice Guidelines for diagnosis, treatment and follow-up. *Ann Oncol*. 2019;30(8):1194–220.
- 2 Chalasani P. Breast Cancer: Practice Essentials, Background, Anatomy. Medscape; 2021. <https://emedicine.medscape.com/article/1947145-overview> [Accessed 11 May 2020].
- 3 Azar L, Khasnis A. Paraneoplastic rheumatologic syndromes. *Curr Opin Rheumatol*. 2013;25(1):44–9.
- 4 Bukamur H, Aqtash O, Shahoub I, Karem E, Ogu I, Zeid F. Atypical rapid onset scleroderma renal crisis (SRC) complicated with diffuse alveolar hemorrhage and pleuro-pericardial effusions in a patient with recently diagnosed breast cancer and a positive anti-RNA polymerase III Ab.: a case report. *Respir Med Case Rep*. 2018;25:137–41.
- 5 Kitajima T, Marumo S, Maeshima Y, Fukui M. Sequential adjuvant chemoradiotherapy-induced diffuse alveolar haemorrhage in a patient with breast cancer successfully treated with corticosteroid plus recombinant human soluble thrombomodulin. *BMJ Case Rep*. 2016;2016:2016. bcr2016217183.
- 6 Segal SL, Lenchner GS, Cichelli AV, Promisloff RA, Hofman WI, Baiocchi GA. Angiosarcoma presenting as diffuse alveolar hemorrhage. *Chest*. 1988;94(1):214–6.
- 7 Casal A, Díaz-Garel J, Pereiro T, Toubes ME, Ricoy J, Valdés L. Pulmonary vasculitis. *J Thorac Dis*. 2018;10(9):5560–75.
- 8 Hoffman GS, Calabrese LH. Vasculitis: determinants of disease patterns. *Nat Rev Rheumatol*. 2014;10(8):454–62.
- 9 Gao F, Fang J, Chen F, et al. EHNO mutations causing low adropin: a possible pathomechanism of MPO-ANCA associated lung injury. *EbioMedicine*. 2016;9:324–35.
- 10 Kamo T, Tasaka S, Tokuda Y, Suzuki S, Asakura T, Yagi K, et al. Levels of soluble receptor for advanced glycation end products in bronchoalveolar lavage fluid in patients with various inflammatory lung diseases. *Clin Med Insights Circ Respir Pulm Med*. 2015;9(Suppl 1):147–54.
- 11 Yates M, Watts R. ANCA-associated vasculitis. *Clin Med*. 2017;17(1):60–4.
- 12 Pelosof LC, Gerber DE. Paraneoplastic syndromes: an approach to diagnosis and treatment. *Mayo Clin Proc*. 2010;85(9):838–54.
- 13 Oppenheim H. Über Hirnsymptome bei Carcinomatose ohne nachweisbare Veränderungen im Gehirn. *Charité-Annalen*. 1888;13:335–44.
- 14 Guichard A, Vignon G. La Polyradiculonéurite cancéreuse métastatique. *J Med Lyon*. 1949;30:197–207.
- 15 Loricera J, Calvo-Río V, Ortiz-Sanjuán F, González-López MA, Fernández-Llaca H, Rueda-Gotor J, et al. The spectrum of paraneoplastic cutaneous vasculitis in a defined population: incidence and clinical features. *Medicine*. 2013;92(6):331–43.
- 16 Longley S, Caldwell JR, Panush RS. Paraneoplastic vasculitis. Unique syndrome of cutaneous angiitis and arthritis associated with myeloproliferative disorders. *Am J Med*. 1986;80(6):1027–30.
- 17 McLean DI. Cutaneous paraneoplastic syndromes. *Arch Dermatol*. 1986;122(7):765–7.
- 18 Buggiani G, Krysenka A, Grazzini M, Vašků V, Hercogová J, Lotti T. Paraneoplastic vasculitis and paraneoplastic vascular syndromes. *Dermatol Ther*. 2010;23(6):597–605.
- 19 Fortin PR. Vasculitides associated with malignancy. *Curr Opin Rheumatol*. 1996;8(1):30–3.
- 20 Calabrese LH, Michel BA, Bloch DA, et al. The American College of Rheumatology 1990 criteria for the classification of hypersensitivity vasculitis. *Arthritis Reum*. 1990;33(8):1108–13.
- 21 Gibson LE, Su WP. Cutaneous vasculitis. *Rheum Dis Clin North Am*. 1998;21(4):1097–113.
- 22 Fain O, Hamidou M, Cacoub P, Godeau B, Wechsler B, Pariès J, et al. Vasculitides associated with malignancies: analysis of sixty patients. *Arthritis Rheum*. 2007;57(8):1473–80.
- 23 Solans-Laque R, Bosch-Gil JA, Perez-Bocanegra C, et al. Paraneoplastic vasculitis in patients with solid tumors: report of 15 cases. *J Rheumatol*. 2008;35:294–304.
- 24 Hutson TE, Hoffman GS. Temporal concurrence of vasculitis and cancer: a report of 12 cases. *Arthritis Care Res*. 2000;13(6):417–23.
- 25 Hasler P, Kistler H, Gerber H. Vasculitides in hairy cell leukemia. *Semin Arthritis Rheum*. 1995;25(2):134–42.
- 26 Fanous I, Dillon P. Paraneoplastic neurological complications of breast cancer. *Exp Hematol Oncol*. 2016;5:29.

- 27 Savci-Heijink CD, Halfwerk H, Hooijer GK, Horlings HM, Wesseling J, van de Vijver MJ. Retrospective analysis of metastatic behaviour of breast cancer subtypes. [Breast Cancer Res Treat](#). 2015;150(3):547–57.
- 28 Emadi A, Jones RJ, Brodsky RA. Cyclophosphamide and cancer: golden anniversary. [Nat Rev Clin Oncol](#). 2009;6(11):638–47.
- 29 Ntatsaki E, Carruthers D, Chakravarty K, D'Cruz D, Harper L, Jayne D, et al. BSR and BHPR guideline for the management of adults with ANCA-associated vasculitis. [Rheumatology](#). 2014;53(12):2306–9.
- 30 Yates M, Watts RA, Bajema IM, Cid MC, Crestani B, Hauser T, et al. EULAR/ERA-EDTA recommendations for the management of ANCA-associated vasculitis. [Ann Rheum Dis](#). 2016;75(9):1583–94.