

JACC STATE-OF-THE-ART REVIEW

Global Chronic Total Occlusion Crossing Algorithm

JACC State-of-the-Art Review



Eugene B. Wu, MD,^a Emmanouil S. Brilakis, MD, PhD,^b Kambis Mashayekhi, MD,^c Etsuo Tsuchikane, MD, PhD,^d Khaldoon Alaswad, MD,^e Mario Araya, MD,^f Alexandre Avran, MD,^g Lorenzo Azzalini, MD, MSc, PhD,^h Avtandil M. Babunashvili, MD,ⁱ Baktash Bayani, MD,^j Michael Behnes, MD,^k Ravinay Bhindi, MD,^l Nicolas Boudou, MD,^m Marouane Boukhris, MD,ⁿ Nenad Z. Bozinovic, MD,^o Leszek Bryniarski, MD,^p Alexander Bufo, MD,^q Christopher E. Buller, MD,^{r,s} M. Nicholas Burke, MD,^b Achim Buttner, MD,^s Pedro Cardoso, MD,^t Mauro Carlino, MD,^u Ji-Yan Chen, MD,^v Evald Hoej Christiansen, MD,^w Antonio Colombo, MD,^x Kevin Croce, MD, PhD,^y Felix Damas de los Santos, MD, MET,^z Tony de Martini, MD,^{aa} Joseph Dens, MD, PhD,^{bb} Carlo di Mario, MD,^{cc} Kefei Dou, MD,^{dd} Mohaned Egred, MD,^{ee} Basem Elbarouni, MD,^{ff} Ahmed M. ElGuindy, MD,^{gg} Javier Escaned, MD,^{hh} Sergey Furkalo, MD,ⁱⁱ Andrea Gagnor, MD,^{jj} Alfredo R. Galassi, MD,^{kk} Roberto Garbo, MD,^{ll} Gabriele Gasparini, MD,^{mm} Junbo Ge, MD,ⁿⁿ Lei Ge, MD,ⁿⁿ Pravin Kumar Goel, MD,^{oo} Omer Goktekin, MD,^{pp} Nieves Gonzalo, MD,^{qq} Luca Grancini, MD,^{rr} Allison Hall, MD,^{ss} Franklin Leonardo Hanna Quesada, MD,^{tt} Colm Hanratty, MD,^{uu} Stefan Harb, MD,^{vv} Scott A. Harding, MD,^{ww} Raja Hatem, MD,^{xx} Jose P.S. Henriques, MD,^{yy} David Hildick-Smith, MD,^{zz} Jonathan M. Hill, MD,^{aaa} Angela Hoye, MD,^{bbb} Wissam Jaber, MD,^{ccc} Farouc A. Jaffer, MD, PhD,^{ddd} Yangsoo Jang, MD,^{eee} Risto Jussila, MD,^{fff} Artis Kalnins, MD,^{ggg} Arun Kalyanasundaram, MD, MPH,^{hhh} David E. Kandzari, MD,ⁱⁱⁱ Hsien-Li Kao, MD,^{jjj} Dimitri Karpaliotis, MD, PhD,^{kkk} Hussien Heshmat Kassem, MD, PhD,^{lll} Jaikirshan Khatri, MD,^{mmm} Paul Knaapen, MD,ⁿⁿⁿ Ran Kornowski, MD,^{ooo} Oleg Kretyaninov, MD,^{ppp} A.V. Ganesh Kumar, MD,^{qqq} Pablo Manuel Lamelas, MD, MSc,^{rrr} Seung-Whan Lee, MD,^{sss} Thierry Lefevre, MD,^{ttt} Raymond Leung, MD,^{uuu} Yu Li, MD,^{vvv} Yue Li, MD,^{www} Soo-Teik Lim, MD,^{xxx} Sidney Lo, MD,^{yyy} William Lombardi, MD,^{zzz} Anbukarasi Maran, MD,^{aaaa} Margaret McEntegart, MD, PhD,^{bbbb} Jeffrey Moses, MD,^{ccc} Muhammad Munawar, MD,^{ddd} Andres Navarro, MD,^{eee} Hung M. Ngo, MD, PhD,^{fff} William Nicholson, MD,^{ggg} Anja Oksnes, MD,^{hhh} Goran K. Olivecrona, MD, PhD,ⁱⁱⁱ Lucio Padilla, MD,^{jjj} Mitul Patel, MD,^{kkk} Ashish Pershad, MD,^{lll} Marin Postu, MD,^{mmm} Jie Qian, MD,ⁿⁿⁿ Alexandre Quadros, MD,^{ooo} Nidal Abi Rafeh, MD,^{ppp} Truls Råmunddal, MD, PhD,^{qqq} Vithala Surya Prakasa Rao, MD,^{rrr} Nicolaus Reifart, MD, PhD,^{sss} Robert F. Riley, MD,^{ttt} Stephane Rinfret, MD,^{uuu} Meruzhan Saghatelian, MD,^{vvv} George Sianos, MD, PhD,^{www} Elliot Smith, MD,^{xxx} Anthony Spaedy, MD,^{yyy} James Spratt, MD,^{zzz} Gregg Stone, MD,^{aaaa} Julian W. Strange, MD,^{bbbb} Khalid O. Tammam, MD, PhD,^{cccc} Craig A. Thompson, MD,^{dddd} Aurel Toma, MD,^{eeee} Jennifer A. Tremmel, MD, MS,^{fff} Ricardo Santiago Trinidad, MD,^{ggg} Imre Ungi, MD, PhD,^{hhhh} Minh Vo, MD,ⁱⁱⁱⁱ Vu Hoang Vu, MD,^{jjjj} Simon Walsh, MD,^{uu} Gerald Werner, MD,^{kkkk} Jaroslaw Wojcik, MD,^{llll} Jason Wollmuth, MD,^{mmmm} Bo Xu, MD,ⁿⁿⁿⁿ Masahisa Yamane, MD,^{oooo} Luiz F. Ybarra, MD,^{pppp} Robert W. Yeh, MD,^{qqqq} Qi Zhang, MD^{rrrr}



Listen to this manuscript's audio summary by Editor-in-Chief Dr. Valentin Fuster on JACC.org.

From the ^aPrince of Wales Hospital, Chinese University Hong Kong, Hong Kong; ^bMinneapolis Heart Institute and Minneapolis Heart Institute Foundation, Minneapolis, Minnesota, USA; ^cDepartment of Cardiology and Angiology, II University Heart Center Freiburg, Bad Krozingen, Germany; ^dToyohashi Heart Center, Aichi, Japan; ^eEdith and Benson Ford Heart and Vascular Institute, Henry Ford Hospital, Henry Ford Health System, Wayne State University, Detroit, Michigan, USA; ^fClinica Alemana, Hospital Militar de Santiago, Santiago, Chile; ^gPasteur Clinic Essey-lès-Nancy, Essey-lès-Nancy, France; ^hDivision of Cardiology, VCU Health Pauley Heart Center, Virginia Commonwealth University, Richmond, Virginia, USA; ⁱCenter of Endosurgery, Moscow, Russia; ^jCardiology Department, Mehr Hospital, Mashhad, Iran; ^kFirst Department of Medicine, University Medical Centre Mannheim, Faculty of Medicine Mannheim, University of Heidelberg, Heidelberg, Germany; ^lRoyal North Shore Hospital, University of Sydney, Sydney, Australia; ^mInterventional Cardiology, Clinique Saint Augustin, Bordeaux, France; ⁿCardiology Department, Abderrahment Mami Hospital, Faculty of Medicine of Tunis, University of Tunis El Manar, Tunis, Tunisia; ^oUniversity Clinical Niš, Niš, Serbia; ^pII Department of Cardiology and Cardiovascular Interventions, Institute of Cardiology, Jagiellonian University Medical College, Kraków, Poland; ^qHeart Center Krefeld, University Witten/Herdecke, Witten, Germany; ^rTeleflex, Markham, Ontario, Canada; ^sSt. Michael's Hospital, Toronto, Ontario, Canada; ^tSanta Maria University Hospital, Lisbon Academic Medical

ABSTRACT

The authors developed a global chronic total occlusion crossing algorithm following 10 steps: 1) dual angiography; 2) careful angiographic review focusing on proximal cap morphology, occlusion segment, distal vessel quality, and collateral circulation; 3) approaching proximal cap ambiguity using intravascular ultrasound, retrograde, and move-the-cap techniques; 4) approaching poor distal vessel quality using the retrograde approach and bifurcation at the distal cap by use of a dual-lumen catheter and intravascular ultrasound; 5) feasibility of retrograde crossing through grafts and septal and epicardial collateral vessels; 6) antegrade wiring strategies; 7) retrograde approach; 8) changing strategy when failing to achieve progress; 9) considering performing an investment procedure if crossing attempts fail; and 10) stopping when reaching high radiation or contrast dose or in case of long procedural time, occurrence of a serious complication, operator and patient fatigue, or lack of expertise or equipment. This algorithm can improve outcomes and expand discussion, research, and collaboration. (J Am Coll Cardiol 2021;78:840-853) © 2021 The Authors. Published by Elsevier on behalf of the American College of Cardiology Foundation. This is an open access article under the CC BY-NC-ND license (<http://creativecommons.org/licenses/by-nc-nd/4.0/>).

Centre and Centro Cardiovascular da Universidade de Lisboa, Lisbon, Portugal; ¹Interventional Cardiology Unit, Cardio-Thoracic-Vascular Department, IRCCS, San Raffaele Scientific Institute, Milan, Italy; ²Guangdong General Hospital, Guangdong, China; ³Department of Cardiology, Aarhus University Hospital, Aarhus, Denmark; ⁴Cardiology, Humanitas University, Humanitas IRCCS, Rozzano, Milan, Italy; ⁵Cardiovascular Division, Brigham and Women's Hospital, Boston, Massachusetts, USA; ⁶Instituto Nacional de Cardiología, Ignacio Chávez and Centro Medico ABC, Mexico City, Mexico; ^{7a}Advocate Heart Institute, Downers Grove, Illinois, USA; ^{7b}Hospital Oost-Limburg, Genk, Belgium; ⁸Department of Clinical & Experimental Medicine, University Hospital Careggi, Florence, Italy; ⁹Research Center for Coronary Heart Disease, State Key Laboratory of Cardiovascular Disease, Fuwai Hospital National Center for Cardiovascular Diseases, Chinese Academy of Medical Sciences, Beijing, China; ¹⁰Freeman Hospital & Newcastle University, Newcastle upon Tyne, UK; ¹¹St. Boniface Hospital & University of Manitoba, Winnipeg, Manitoba, Canada; ¹²Department of Cardiology, Aswan Heart Centre, Magdi Yacoub Foundation, Aswan, Egypt; ¹³Hospital Clinico San Carlos, IDISSC, Complutense University of Madrid, Madrid, Spain; ¹⁴National Institute of Surgery and Transplantology NAMS, Kiev, Ukraine; ¹⁵Department of Invasive Cardiology, Maria Vittoria Hospital, Turin, Italy; ¹⁶Cardiovascular Medicine Department of PROMISE University of Palermo, Palermo, Italy; ¹⁷Maria Pia Hospital, GVM Care & Research, Turin, Italy; ¹⁸Department of Invasive Cardiology, Humanitas Clinical and Research Center, IRCCS, Rozzano, Italy; ¹⁹Zhongshan Hospital, Fudan University, Shanghai, China; ²⁰Sanjay Gandhi Post Graduate Institute of Medical Sciences, Lucknow, India; ²¹Memorial Hospital, Istanbul, Turkey; ²²Interventional Cardiology, Hospital Clinico San Carlos, IDISSC, Universidad Complutense, Madrid, Spain; ²³Centro Cardiologico Monzino, IRCCS, Milan, Italy; ²⁴Eastern Health/Memorial University of Newfoundland, St. John's, Newfoundland, Canada; ²⁵Clinica Comfamiliar, Pereira, Colombia; ²⁶Belfast Health and Social Care Trust, Belfast, UK; ²⁷Medical University of Graz, University Heart Center, Graz, Austria; ²⁸Wellington Hospital, Capital and Coast District Health Board, Wellington, New Zealand; ²⁹Hôpital du Sacré-Coeur de Montréal Université de Montréal, Montréal, Québec, Canada; ³⁰University of Amsterdam, Amsterdam, the Netherlands; ³¹Sussex Cardiac Centre, Brighton, UK; ³²King's College Hospital, London, UK; ³³Centre for Atherothrombosis and Metabolic Disease, Hull York Medical School, University of Hull, Hull, UK; ³⁴Emory University, Atlanta, Georgia, USA; ³⁵Cardiology Division, Massachusetts General Hospital, Harvard Medical School, Boston, Massachusetts, USA; ³⁶Severance Cardiovascular Hospital, Yonsei University College of Medicine, Seoul, South Korea; ³⁷Interventional Cardiology, Helsinki Heart Hospital, Helsinki, Finland; ³⁸Clinic of Cardiovascular Diseases, Riga East Clinical University Hospital, Riga, Latvia; ³⁹Promed Hospital, Chennai, India; ⁴⁰Piedmont Heart Institute and Cardiovascular Services, Atlanta, Georgia, USA; ⁴¹Department of Internal Medicine, Cardiology Division, Cardiovascular Center, National Taiwan University Hospital, Taipei, Taiwan; ⁴²Columbia University, New York, New York, USA; ⁴³Kasr Alainy Medical School, Cairo University, Cairo, Egypt, and Fujairah Hospital, Ministry of Health, Fujairah, United Arab Emirates; ⁴⁴Cleveland Clinic, Cleveland, Ohio, USA; ⁴⁵Heart Center of the Amsterdam University Medical Centers, Amsterdam, the Netherlands; ⁴⁶Department of Cardiology, Rabin Medical Center, Faculty of Medicine, Tel Aviv University, Tel Aviv, Israel; ⁴⁷Meshalkin Novosibirsk Research Institute, Novosibirsk, Russia; ⁴⁸Department of Cardiology, Dr. L.H. Hiranandani Hospital, Mumbai, India; ⁴⁹Instituto Cardiovascular de Buenos Aires, Buenos Aires, Argentina, and Health Research Methods, Evidence, and Impact, McMaster University, Hamilton, Ontario, Canada; ⁵⁰Department of Cardiology, Asan Medical Center, University of Ulsan College of Medicine, Seoul, South Korea; ⁵¹Institut Cardiovasculaire Paris Sud, Hôpital Prive Jacques Cartier, Massy, France; ⁵²C.K. Hui Heart Centre, Royal Alexandra Hospital, Edmonton, Alberta, Canada; ⁵³Beijing Anzhen Hospital, Capital Medical University, Beijing, China; ⁵⁴Department of Cardiology, First Affiliated Hospital of Harbin Medical University, Harbin, China; ⁵⁵National Heart Centre of Singapore, Singapore; ⁵⁶Department of Cardiology, Liverpool Hospital and The University of New South Wales, Sydney, Australia; ⁵⁷University of Washington, Seattle, Washington, USA; ⁵⁸Medical University of South Carolina, Ralph H. Johnson VA Medical Center, Charleston, South Carolina, USA; ⁵⁹Golden Jubilee National Hospital, Glasgow, UK; ⁶⁰New York-Presbyterian/Columbia University Irving Medical Center, New York, New York, USA; ⁶¹Binawaluya Cardiac Center and Department of Cardiology, Faculty of Medicine, Universitas Indonesia, Jakarta, Indonesia, and Department of Cardiology, Faculty of Medicine, Universitas Gadjahmada, Yogyakarta, Indonesia; ⁶²Hospital de los Valles, Hospital de Especialidades Eugenio Espejo, Universidad San Francisco de Quito, Quito, Ecuador; ⁶³Choray University

**ABBREVIATIONS
AND ACRONYMS**

ADR = antegrade dissection
and re-entry

APCTO = Asia Pacific CTO Club

CTO = chronic total occlusion

IVUS = intravascular
ultrasound

PCI = percutaneous coronary
intervention

The success of chronic total occlusion (CTO) percutaneous coronary intervention (PCI) significantly improved during the past decade from 50%-70% (1) to 85%-94% (2-7) at experienced centers. In addition to technological advances, this improvement was catalyzed by the widespread implementation of an algorithmic approach to CTO crossing. The first CTO crossing algorithm was the hybrid algorithm (8) (Figure 1A, Table 1), which emphasized

the importance of dual angiography and careful angiographic review to guide the selection of initial and subsequent crossing strategies. The hybrid algorithm also recommended a prompt change of strategy in case of failure to achieve progress and awareness of radiation and contrast use and procedure time. These guiding principles were adopted and expanded in subsequent algorithms (Table 1). The Asia Pacific CTO Club (APCTO) algorithm (9) (Figure 1B) recommended intravascular ultrasound (IVUS) to resolve ambiguity in the location of the proximal cap of the CTO, use of the CrossBoss catheter (Boston Scientific) for in-stent CTOs, use of parallel wiring, and consideration of tortuosity, calcification, and ambiguity for

using a knuckle-wire technique. Similar algorithms were also published by the CTO Club China (10) (Figure 1C), the EuroCTO Club (11) (Figure 1D), and the Japan CTO Club (2). Existing algorithms have similarities but also significant differences (Table 1).

Recently, a global consensus document highlighted 7 key principles of CTO PCI (12), 1 of which is that all CTO crossing techniques are valuable in the right setting. Development of a unified global CTO crossing algorithm could significantly facilitate decision making and CTO PCI teaching across various geographies and improve the safety, reproducibility, and efficiency of the procedure (13). An initial document draft of a global CTO crossing algorithm (Central Illustration, Table 1) was created by a group of 4 CTO PCI experts from North America, Europe, and Asia. A total of 122 other CTO PCI experts from 50 countries were invited to participate, of whom 121 from 50 countries provided comments and approved this final document.

The global CTO crossing algorithm includes the following 10 steps.

STEP 1: DUAL ANGIOGRAPHY. Dual coronary angiography remains the cornerstone of CTO PCI and should be performed in nearly all cases unless the

Hospital, Hochiminh City, Vietnam; ⁸⁸⁸⁸Emory Healthcare, Atlanta, Georgia, USA; ^{hhhh}Heart Department, Haukeland University Hospital, Bergen, Norway; ⁱⁱⁱⁱDepartment of Cardiology SUS-Lund, Lund University, Lund, Sweden; ^{jjjj}Department of Interventional Cardiology and Endovascular Therapeutics, ICBA, Instituto Cardiovascular, Buenos Aires, Argentina; ^{kkkk}Division of Cardiovascular Medicine, University of California, San Diego, School of Medicine, San Diego, California, USA; ^{llll}Chandler Regional Medical Center, Chandler, Arizona, USA; ^{mmmm}Cardiology Department, University of Medicine and Pharmacy "Carol Davila," Institute of Cardiovascular Diseases "Prof Dr C.C. Iliescu," Bucharest, Romania; ⁿⁿⁿⁿBeijing Fuwai Hospital, Beijing, China; ^{oooo}Interventional Cardiology Division and Post Graduate Course of Cardiology, Instituto de Cardiologia do Rio Grande do Sul, Porto Alegre, Brazil; ^{pppp}St. George Hospital University Medical Center, Beirut, Lebanon, and North Oaks Healthcare System, Hammond, Louisiana, USA; ^{qqqq}Department of Cardiology, Sahlgrenska University Hospital, Gothenburg, Sweden; ^{rrrr}Care Hospitals, Hyderabad, India; ^{ssss}Department of Cardiology, Main Taunus Heart Institute, Bad Soden, Germany; ^{tttt}The Christ Hospital Health Network, Cincinnati, Ohio, USA; ^{uuuu}McGill University Health Centre, Montréal, Québec, Canada; ^{vvvv}Nork Marash MC, Erebouni MC, Yerevan, Armenia; ^{wwww}AHEPA University Hospital, Thessaloniki, Greece; ^{xxxx}Department of Cardiology, Barts Heart Centre, St. Bartholomew's Hospital, London, UK; ^{yyyy}Boone Hospital Center, Columbia, Missouri, USA; ^{zzzz}St. George's University Hospital NHS Foundation Trust, London, UK; ^{aaaa}The Zena and Michael A. Wiener Cardiovascular Institute, Icahn School of Medicine at Mount Sinai, New York, New York, USA; ^{bbbbb}Bristol Royal Infirmary, University Hospital Bristol NHS Trust, Bristol, UK; ^{cccc}Department at the International Medical Center, Jeddah, Saudi Arabia; ^{dddd}NYU Langone Medical Center, New York, New York, USA; ^{eeee}Department of Internal Medicine II, Division of Cardiology, Medical University of Vienna, Vienna, Austria; ^{ffff}Stanford University Medical Centre, Stanford, California, USA; ^{gggg}PCI Cardiology Group, Bayamon, Puerto Rico, USA; ^{hhhhh}University of Szeged, Department of Invasive Cardiology, Szeged, Hungary; ⁱⁱⁱⁱⁱRoyal Columbian Hospital, Vancouver, British Columbia, Canada; ^{jjjjj}Heart Center University Medical Center, Ho Chi Minh City, Vietnam; ^{kkkkk}Medizinische Klinik I Klinikum Darmstadt, Darmstadt, Germany; ^{lllll}Hospital of Invasive Cardiology IKARDIA, Nałęczów/Lublin, Poland; ^{mmmmm}Providence Heart and Vascular Institute, Portland, Oregon, USA; ⁿⁿⁿⁿⁿFu Wai Hospital, National Center for Cardiovascular Diseases, Chinese Academy of Medical Sciences, Beijing, China; ^{ooooo}Saitima St. Luke's International Hospital, Tokyo, Japan; ^{ppppp}London Health Sciences Centre, Schulich School of Medicine & Dentistry, Western University, London, Ontario, Canada; ^{qqqqq}Richard A. and Susan F. Smith Center for Outcomes Research in Cardiology, Division of Cardiovascular Medicine, Beth Israel Deaconess Medical Center, Harvard Medical School, Boston, Massachusetts, USA; and the ^{rrrrr}Shanghai East Hospital, Tongji University, Shanghai, China.

Javed Butler, MD, MPH, MBA, served as the Guest Editor-in-Chief for this paper.

The authors attest they are in compliance with human studies committees and animal welfare regulations of the authors' institutions and Food and Drug Administration guidelines, including patient consent where appropriate. For more information, visit the [Author Center](#).

collateral circulation originates exclusively from ipsilateral vessels. Dual angiography, with nitroglycerin if needed, facilitates planning of CTO crossing and guides crossing attempts by helping determine the guidewire position and detecting potential complications. Coronary computed tomographic angiography can also provide important information on CTO anatomy and procedural planning (14).

Currently, most CTO techniques, including antegrade dissection and re-entry (ADR) techniques with the Stingray LP system (Boston Scientific) and simultaneous IVUS-controlled cap puncture or IVUS-guided wiring, can be performed with 7-F guide catheters using 7-F compatible equipment combinations, such as 5-F IVUS and low-profile microcatheters. Eight-French guide catheters are

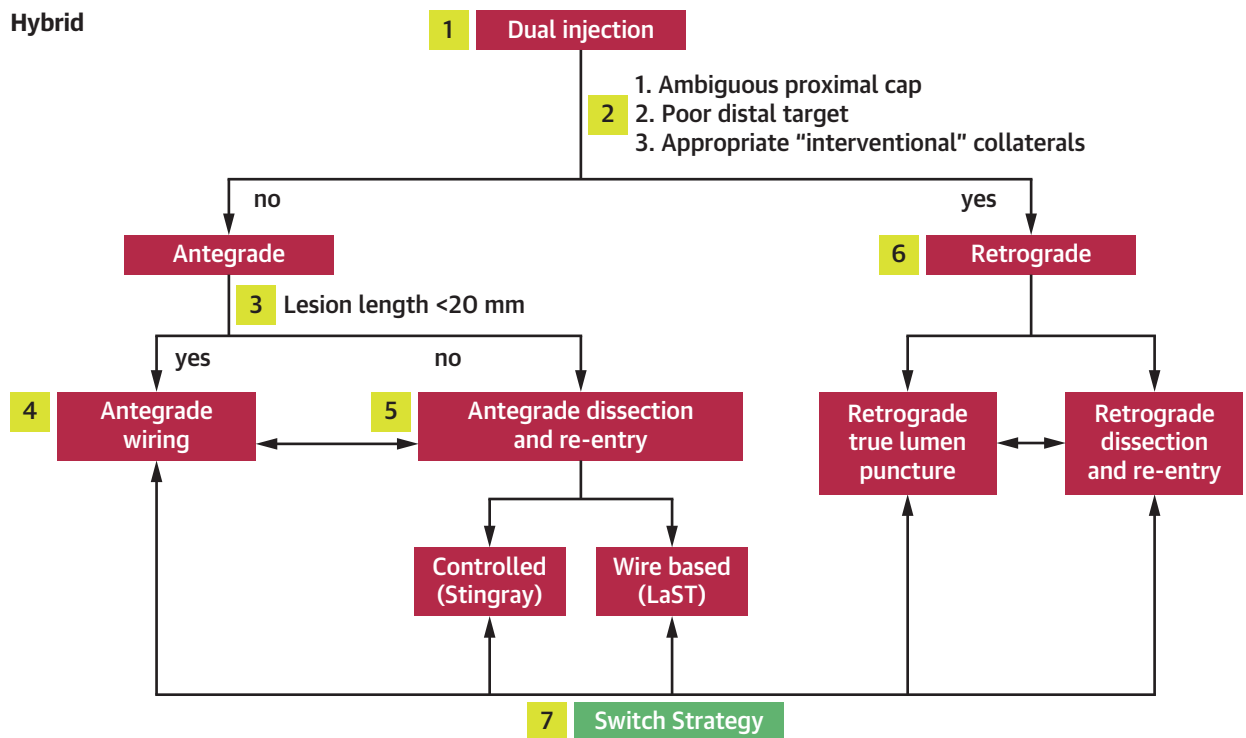
HIGHLIGHTS

- Several regional crossing algorithms for chronic total coronary artery occlusive lesions (CTO) have been published.
- The authors of these regional algorithms from 50 countries have collaborated in developing a global CTO crossing algorithm.
- This algorithm can encourage discussion, promote research collaboration, facilitate training and improve outcomes of percutaneous revascularization for patients with CTO.

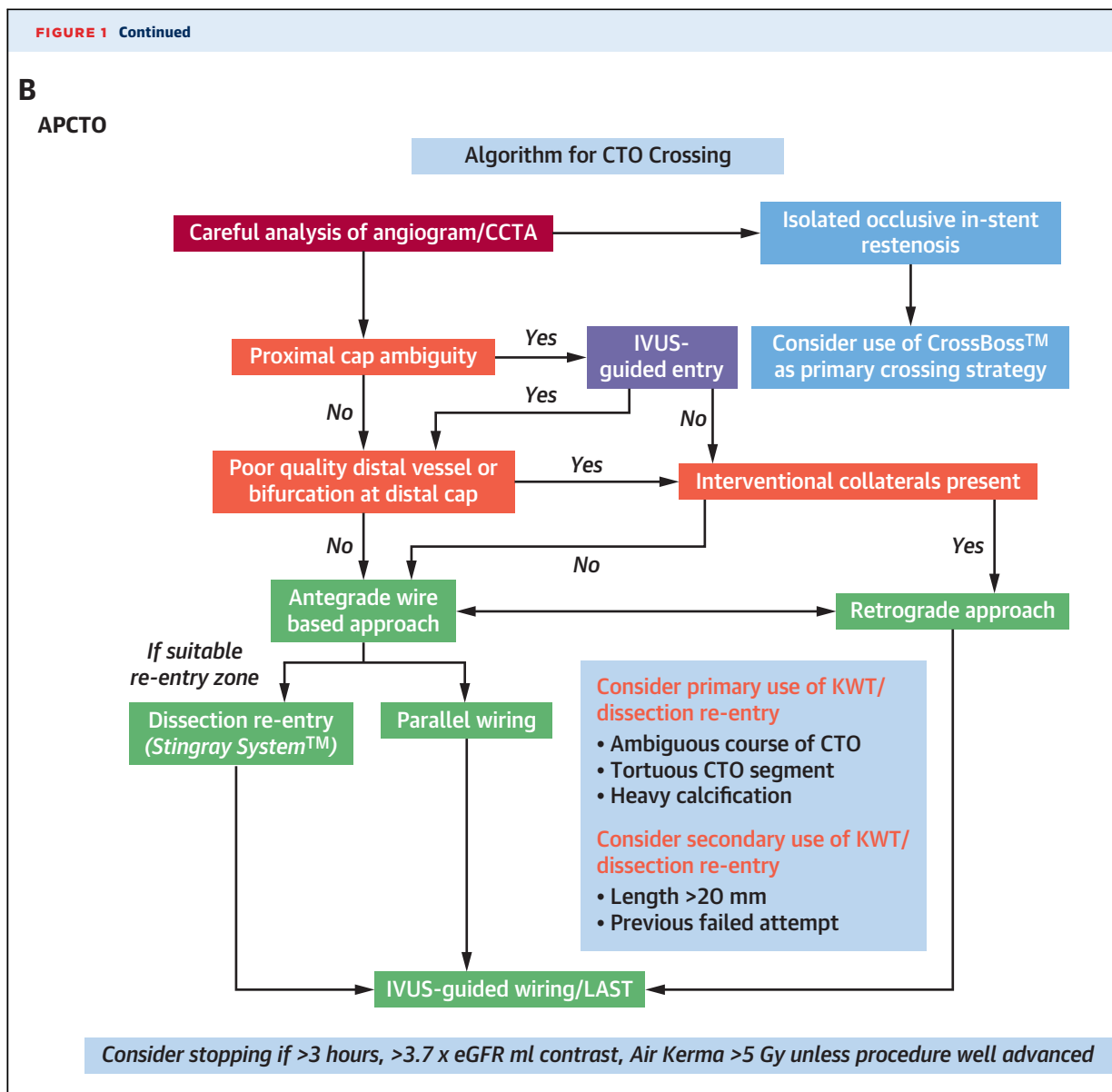
FIGURE 1 Different CTO Crossing Algorithms

A

Hybrid



(A) The hybrid algorithm. Reprinted with permission from Brilakis et al (8). (B) The Asia Pacific CTO Club (APCTO) algorithm. Reprinted with permission from Harding et al (9). (C) CTO Club China algorithm. Reprinted with permission from Junbo (10). (D) EuroCTO Club algorithm. Reprinted with permission from Galassi et al (11). ADR = antegrade dissection and re-entry; AWE antegrade wire escalation; BASE = balloon-assisted subintimal entry; CAG = coronary angiography; CART = controlled antegrade and retrograde tracking; CCTA = coronary computed tomographic angiography; CTO = chronic total occlusion; eGFR = estimated glomerular filtration rate; IVUS = intravascular ultrasound; KWT = kissing wire technique; LaST = limited antegrade subintimal tracking; POBA = plain old balloon angioplasty; RWE = retrograde wire escalation; SB = side branch; STAR = subintimal tracking and re-entry.



still needed for more complex antegrade IVUS controlled re-entry cases and for ipsilateral single-guide retrograde cases with simultaneous IVUS guidance. Access choice depends on the balance of risk for vascular complication against potential benefits, especially in more complex CTO procedures.

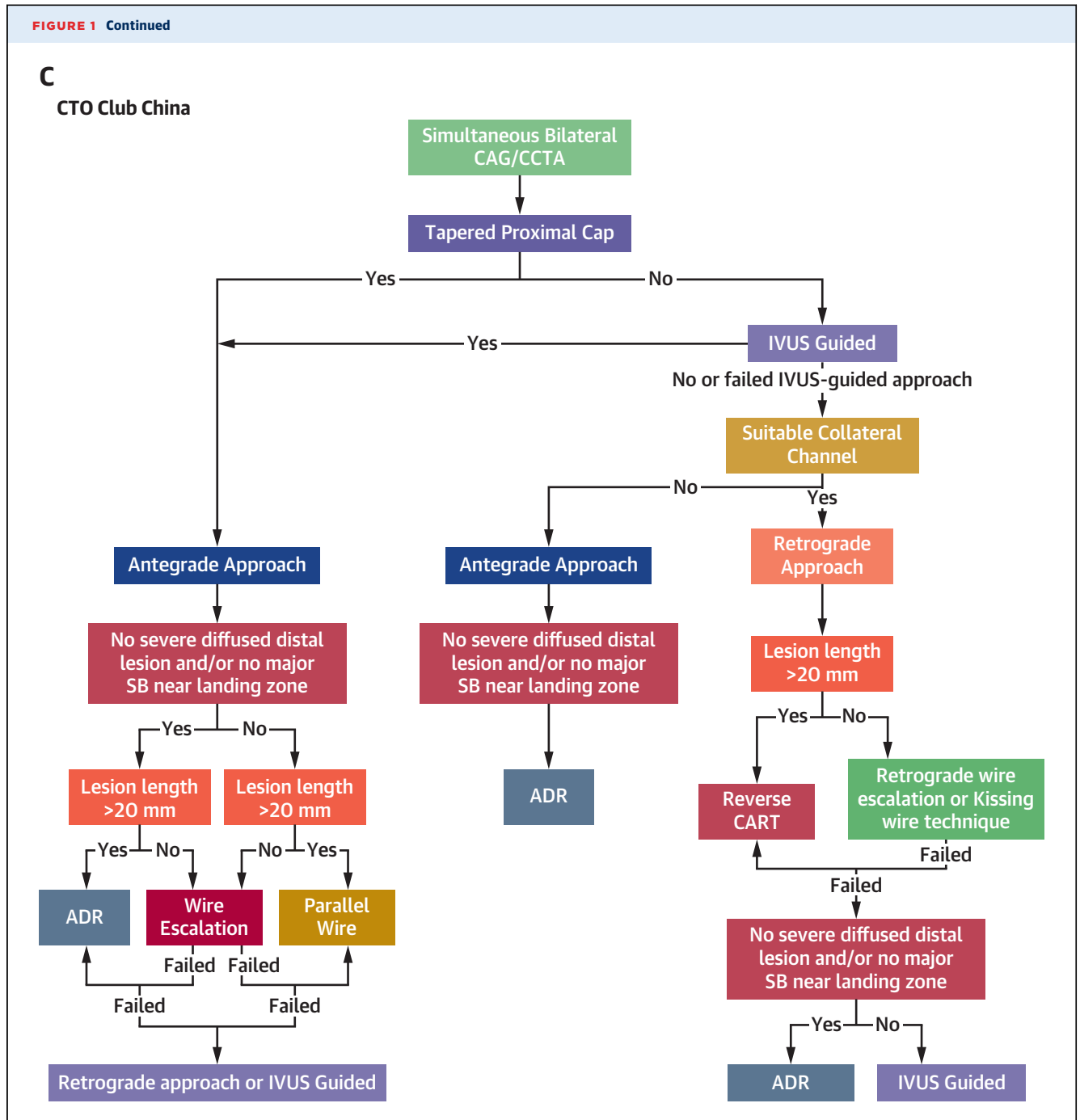
STEP 2: CAREFUL ANGIOGRAPHIC REVIEW. The coronary angiogram (most recent as well as prior angiograms) should be reviewed in detail, focusing on the following 4 characteristics.

Proximal cap morphology. Clear understanding of proximal cap location is critical for safely attempting antegrade CTO crossing recanalization. Proximal cap ambiguity is a key parameter in the global CTO

crossing algorithm. CTOs with ambiguous proximal caps may be approached using the retrograde approach or IVUS or the “move-the-cap” subintimal crossing techniques, such as balloon-assisted subintimal entry or scratch and go (15).

CTO lesion length and composition. Dual injection is necessary for estimating the occlusion length, as it allows visualization of the distal vessel and the distal cap. Calcification and tortuosity of the occluded segment increase the difficulty of CTO crossing and favor use of subintimal crossing techniques.

Distal vessel quality. A distal vessel of large caliber (≥ 2.0 mm) that fills well, does not have significant



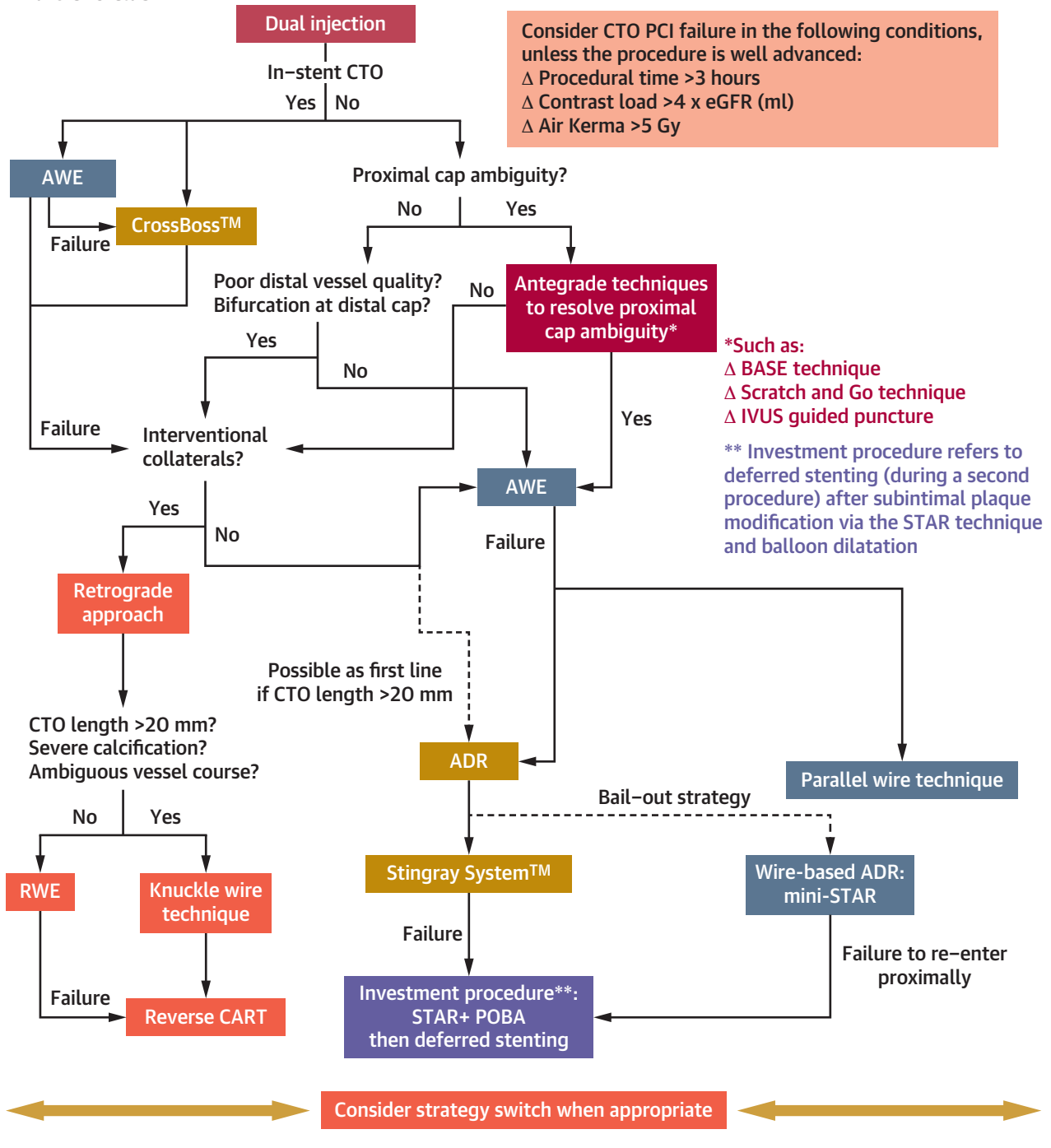
disease, and is free from major branches facilitates CTO recanalization. Conversely, small, diffusely diseased distal vessels with significant bifurcations are more challenging to recanalize, especially after subintimal guidewire entry.

Collateral circulation. Evaluation of the collateral circulation helps determine the feasibility of the retrograde approach. Retrograde access to the distal vessel can be obtained via septal collateral

vessels, epicardial collateral vessels, or (patent or occluded) coronary bypass grafts. When assessing collateral vessels, it is important to consider size, tortuosity, bifurcations, angle of entry to and exit from the channel, and distance between the collateral exit and the distal cap. Larger collateral size and lack of tortuosity are associated with easier crossing by a guidewire and microcatheter (16,17).

FIGURE 1 Continued

D
Euro CTO Club



STEP 3: APPROACHING PROXIMAL CAP AMBIGUITY. Proximal cap ambiguity is inability to confidently determine the location of the proximal cap and is common in CTOs with a side branch at the proximal

cap. A stiff-tip guidewire should not be used to puncture caps with proximal cap ambiguity. In some patients, proximal cap ambiguity can be resolved by performing angiography in different projections and

TABLE 1 Comparison of Various CTO Crossing Algorithms

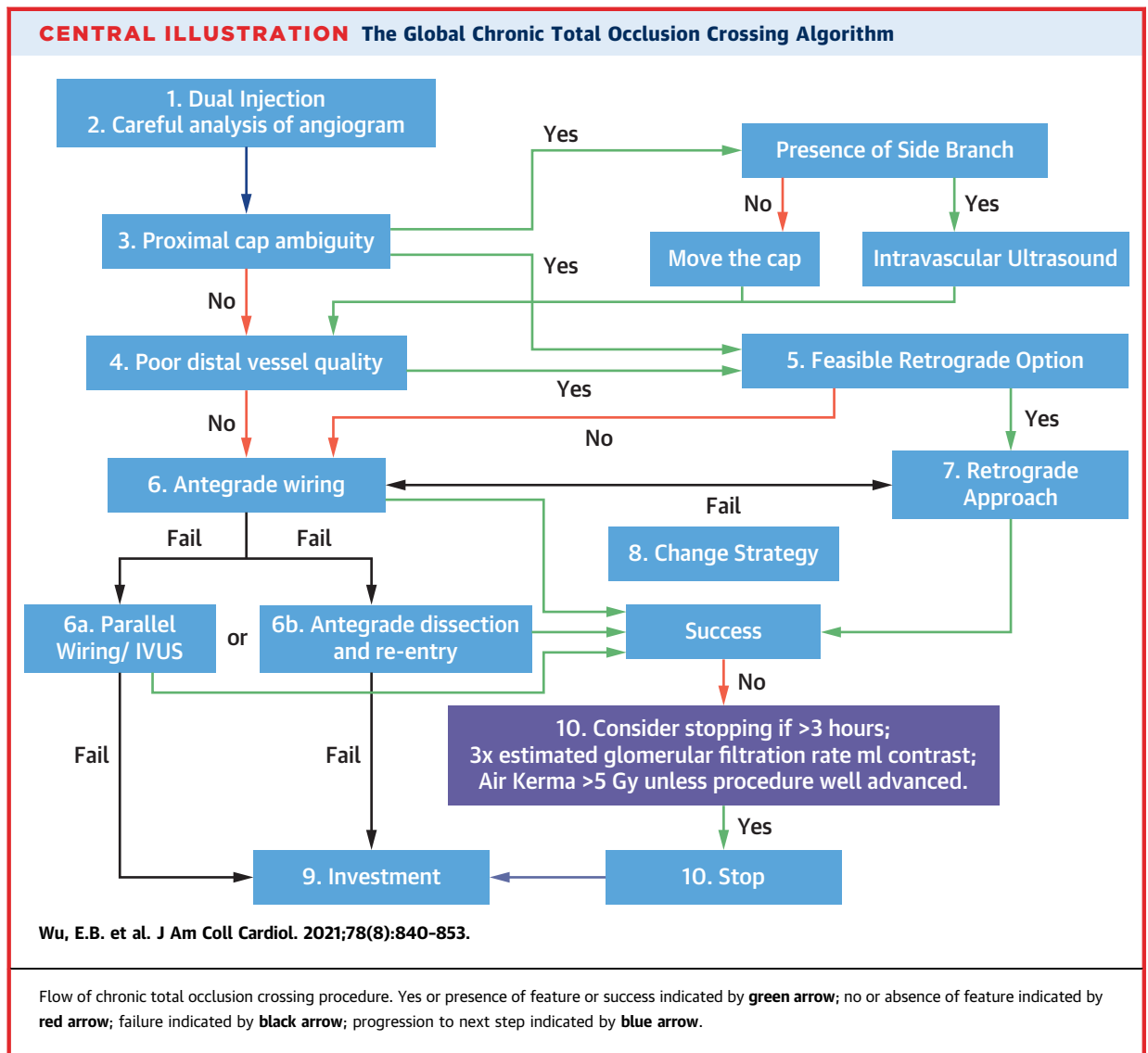
	Hybrid	Asia Pacific CTO Club	EuroCTO Club	CTO Club China	Japan CTO Club	Global
1. Dual angiography	+	+	+	+	+	+
1b. CTA		+		+		+
2. Careful angiographic review	+	+	+	+	+	+
ISR	No specific recommendation	+ (CrossBoss)	+ (CrossBoss)	+ (CrossBoss)	Antegrade	No specific recommendation; assess lesion characteristics and treat accordingly
3. Proximal cap ambiguity	+	+	+	+	+	+
3b. Solutions to proximal ambiguity	Retrograde	Retrograde, IVUS	Retrograde, IVUS, move the cap	Retrograde, IVUS, move the cap	Retrograde	IVUS, retrograde, move the cap
4. Poor distal vessel bifurcation distal cap	+ (retrograde)	+ (retrograde)	+ (retrograde)	+ (retrograde)		+ (retrograde)
5. Retrograde option	+	+	+	+	+	+
6. Antegrade wiring strategies	ADR for length ≥ 20 mm	AWE, parallel wiring Primary ADR for ambiguous CTO course, tortuous CTO segment, heavy calcification Secondary ADR: length ≥ 20 mm, prior failed attempt	AWE preferred; ADR possible as first line if length ≥ 20 mm	ADR preferred if severe diffuse distal disease and major side branch near landing zone	ADR or parallel wiring after AWE failure	AWE preferred
7. Retrograde	Ambiguous proximal cap, poor distal vessel + interventional collateral vessels	Ambiguous proximal cap (if IVUS fails), poor distal vessel + interventional collateral vessels	Ambiguous proximal cap, poor distal vessel + interventional collateral vessels	Ambiguous proximal cap + no or failed IVUS-guided approach + interventional collateral vessels	Reattempt, CTO length of ≥ 20 mm, and no stump + interventional collateral vessels	Ambiguous proximal cap, poor distal vessel + feasible retrograde option
7b. RDR preferred over RWE	Length ≥ 20 mm	Length ≥ 15 mm	Length ≥ 20 mm Severe calcification Ambiguous vessel course	Length ≥ 20 mm		Length ≥ 20 mm Severe calcification Ambiguous vessel course
7c. RDR preferred technique	Reverse CART	Contemporary reverse CART	Reverse CART	Reverse CART		Reverse CART
8. Change	+	+	+	+	After 20-min wire manipulation time	+
9. Investment			+			+
10. When to stop	Air kerma >10 Gy	Procedure duration >3 h Air kerma >5 Gy Contrast $>3.7 \times$ eGFR	Procedure duration >3 h Air kerma >5 Gy Contrast $>4 \times$ eGFR		Procedure duration >3 h	Procedure duration >3 h Air kerma >5 Gy Contrast $>3 \times$ eGFR Complication

ADR = antegrade dissection and re-entry; AWE = antegrade wire escalation; CART = controlled antegrade and retrograde tracking; CTA = computed tomographic angiography; CTO = chronic total occlusion; eGFR = estimated glomerular filtration rate; ISR = in-stent restenosis; IVUS = intravascular ultrasound; RDR = retrograde dissection and re-entry; RWE = retrograde wire escalation.

in others by contrast injection through a microcatheter near the suspected proximal cap. Coronary computed tomographic angiography can also help resolve proximal cap ambiguity.

All current CTO crossing algorithms recommend a stepwise approach to proximal cap ambiguity: the hybrid algorithm recommends retrograde crossing, the APCTO algorithm recommends IVUS first followed by retrograde crossing if IVUS cannot clarify the anatomy, and the EuroCTO Club algorithm recommends IVUS or the “move-the-cap” subintimal techniques first, followed by retrograde crossing attempts.

The global CTO crossing algorithm supports all 3 strategies (IVUS-guided puncture, “move-the-cap” techniques, and retrograde crossing) for approaching proximal cap ambiguity without prioritizing one strategy over another (Figures 2 and 3). Instead, the strategy that optimizes safety and increases the likelihood of success should be selected on the basis of CTO anatomy. For example, in cases of proximal cap ambiguity without an appropriate side branch for IVUS but with excellent septal collateral vessels, retrograde could often be the initial crossing strategy. In contrast, in proximal caps with a favorable side branch, IVUS-guided proximal cap puncture may be



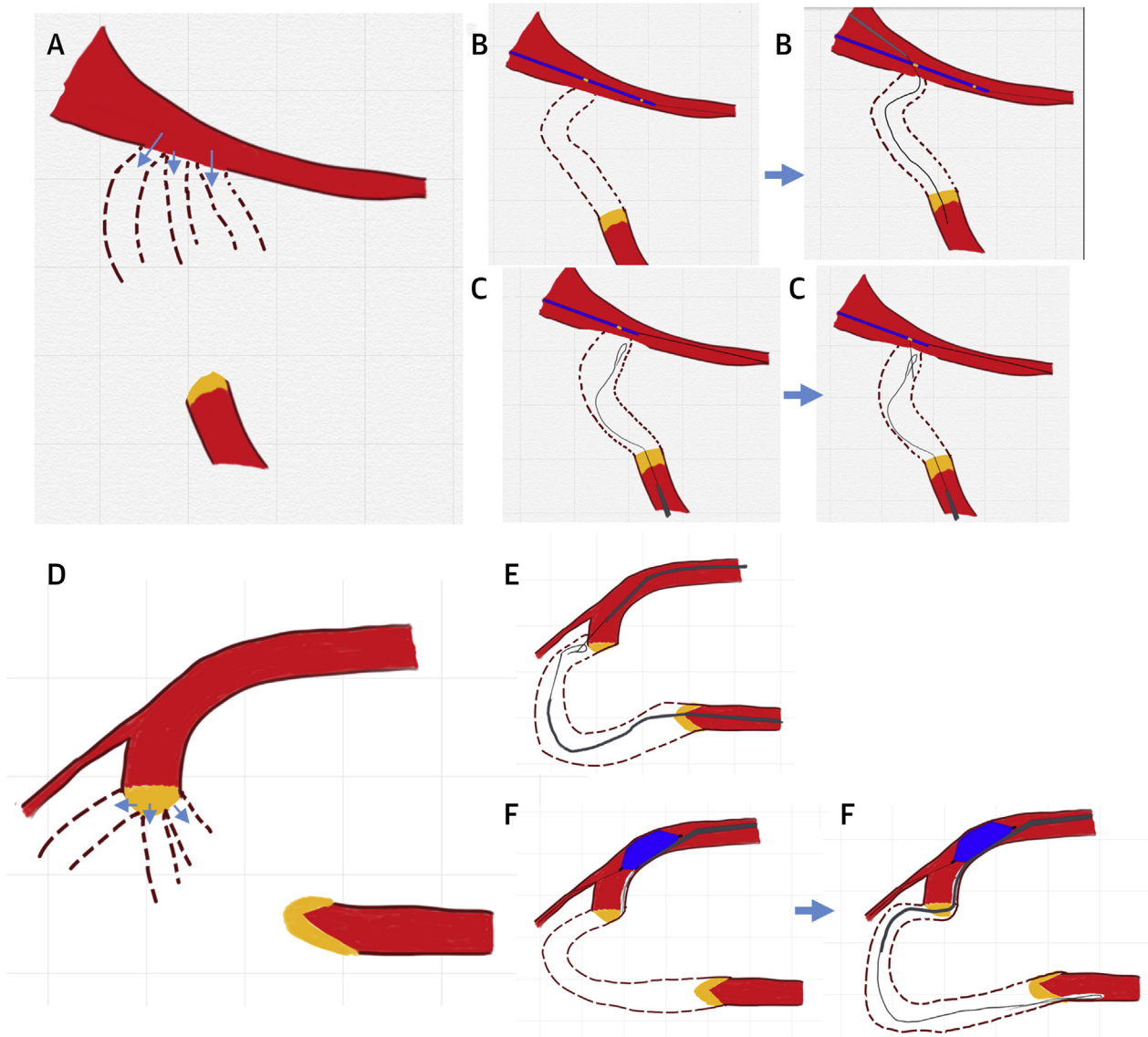
preferred. The “move-the-cap” techniques could be used if there are no significant side branches at the proximal or distal cap, as the intentional dissection can lead to occlusion of those branches, but should be avoided in patients with small and diffusely diseased distal vessels in whom re-entry into the distal true lumen may be challenging.

STEP 4: APPROACHING POOR DISTAL VESSEL QUALITY OR BIFURCATION AT THE DISTAL CAP. In patients with poor distal vessel quality or bifurcation at the distal cap, the retrograde approach may be safer and more efficient for operators experienced in this technique (10). In patients with bifurcation at the distal cap, use of a dual-lumen microcatheter is recommended for advancing a guidewire into the side branch to prevent side branch occlusion after balloon

angioplasty and stenting. If the CTO crossing guidewire position is unclear, IVUS should be performed before stent placement to avoid side branch occlusion due to subintimal position of the main branch wire at the bifurcation.

STEP 5: FEASIBLE RETROGRADE OPTION. The term “interventional” collateral has been used for retrograde collateral vessels considered appropriate for crossing by the operator (8). Coronary bypass grafts, whether patent or occluded, are often used for the retrograde approach, even though bypass grafts are not truly “collateral” vessels. We introduce the term “feasible retrograde option” to describe the presence of any retrograde route considered appropriate for retrograde CTO PCI. Bypass grafts and septal collateral vessels are preferred over epicardial collateral

FIGURE 2 Approaches to Proximal Cap Ambiguity

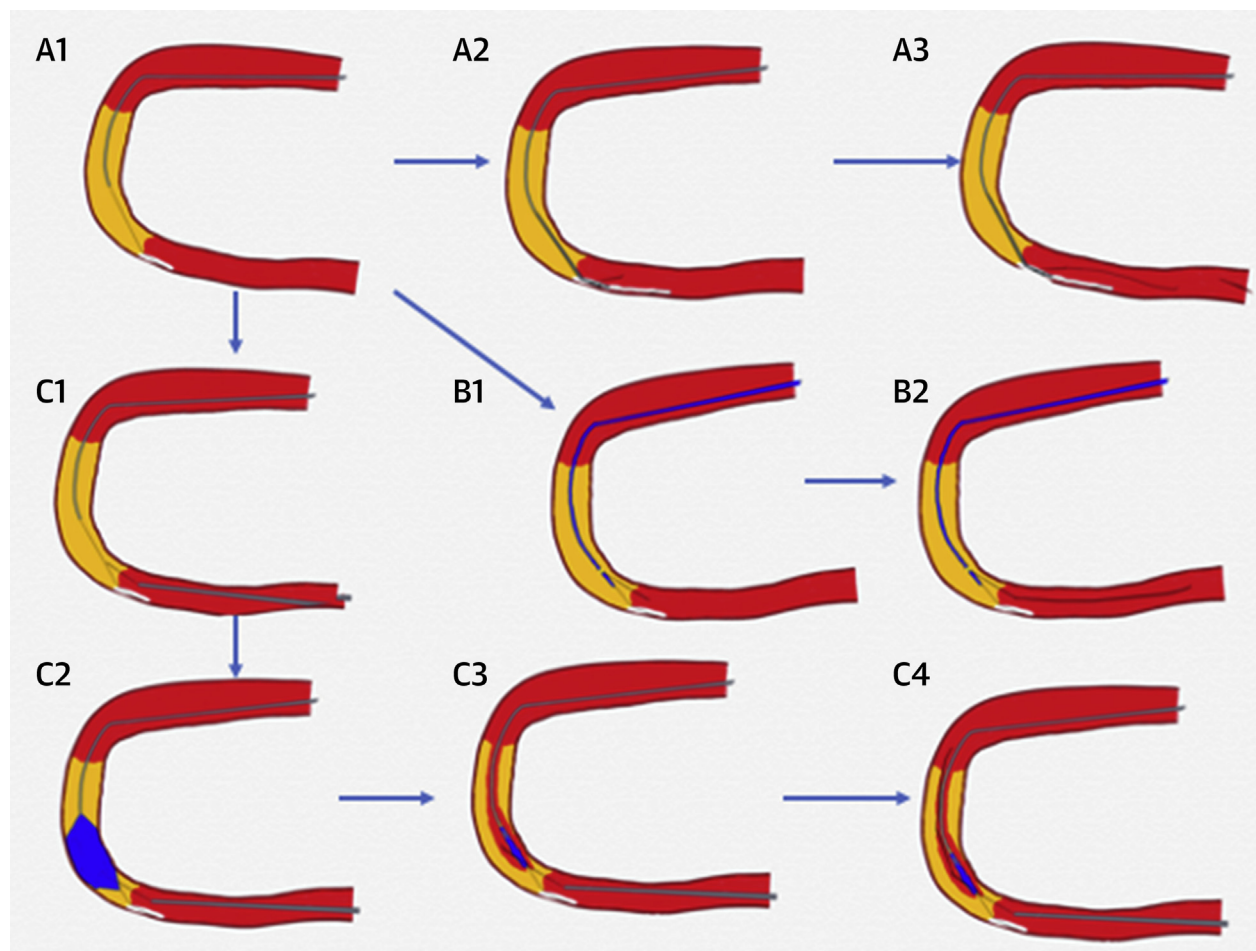


(A) Three possible position of proximal cap and vessel course of CTO (**arrows**). **(B)** True location of proximal cap revealed by IVUS and successful wiring of CTO. **(C)** Retrograde knuckle wire reveals proximal cap location, enabling successful antegrade puncture of the proximal cap. **(D)** Three possible positions (**arrows**) of the CTO proximal cap. **(E)** True location of proximal cap revealed by a retrograde knuckled wire and successful antegrade puncture into the cap. **(F)** Balloon-assisted subintimal entry, followed by subintimal crossing of the occlusion and distal re-entry. Abbreviations as in [Figure 1](#).

vessels, as perforation of the latter is more likely to cause tamponade or potentially life-threatening loculated hematomas in patients with prior coronary artery bypass graft surgery.

STEP 6: ANTEGRADE WIRING STRATEGIES. Antegrade wiring is the most commonly used CTO crossing strategy and should be performed in most cases, unless there is proximal cap ambiguity or poor quality

distal vessel. Antegrade wiring usually starts with a low-tip-load, tapered, polymer-jacketed guidewire, followed by escalation to a stiffer polymer jacketed or a higher tip load, tapered guidewire if there is resistance to crossing (18,19). Escalation is usually followed by de-escalation to a softer tip, torquable guidewire after advancing through the area of resistance, especially when the vessel course is ambiguous

FIGURE 3 Approaches to Subintimal Guidewire Entry

When antegrade wire escalation strategy fails and the first wire enters the subintimal space next to the distal cap, subsequent wiring options include **(A1)** antegrade wire in subintimal space, **(A2)** antegrade dissection and device-based re-entry using the Stingray balloon, **(A3)** successful wiring of distal true lumen with use of Stingray, **(B1)** parallel wiring, **(B2)** successful wiring of distal true lumen with parallel wiring, **(C1)** retrograde approach, **(C2)** reverse controlled antegrade and retrograde tracking, **(C3)** successful crossing of retrograde wire into antegrade balloon space, and **(C4)** successful wiring of proximal true lumen via retrograde.

(20). If antegrade wiring fails to enter the distal true lumen, either antegrade (parallel wiring, device-based re-entry [such as use of the Stingray system], IVUS-guided antegrade wiring), or the retrograde approach can be used (Figure 3).

In ADR, the subintimal space is entered, followed by subintimal crossing of the CTO with re-entry into the distal true lumen. ADR may be intentional or unintentional during antegrade wiring attempts. The hybrid algorithm uses occlusion length alone (≥ 20 mm) to determine whether to use wire escalation or ADR, whereas the APCTO and EuroCTO Club algorithms use a combination of length and other

factors, such as tortuosity, calcification, and proximal cap ambiguity.

In the global CTO crossing algorithm, the following 4 parameters favor the use of ADR: ≥ 20 mm occlusion length, calcification, tortuosity, and presence of an appropriate re-entry zone of large caliber and without major side branches. ADR may be less desirable in long left anterior descending coronary artery CTOs with multiple branches (septal and diagonal) at risk for occlusion. Re-entry should be performed as close to the distal cap as possible, which may be best achieved by using a dedicated re-entry device, such as the Stingray balloon. Stenting should be avoided if

the subintimal tracking and re-entry technique is used, as it is associated with high rates of restenosis and reocclusion (21).

STEP 7: RETROGRADE APPROACH. The primary retrograde approach should be considered when retrograde is the best option to resolve proximal cap ambiguity, when there is a bifurcation in the distal cap, or when antegrade approach is completely impossible. Similar to antegrade wiring, retrograde crossing can be achieved via retrograde wiring versus retrograde dissection and re-entry, with the latter favored in cases with long occlusion length (≥ 20 mm), severe tortuosity, and calcification and lack of large side branches that could be compromised with use of dissection techniques. Reverse controlled antegrade and retrograde tracking is the most commonly used retrograde crossing technique (22) and can be facilitated by use of guide catheter extensions and IVUS (23).

STEP 8: CHANGE. Similar to all CTO crossing algorithms, the global CTO crossing algorithm recommends a change of strategy if the initially or subsequently selected strategies fail to achieve progress. The Japanese CTO algorithm recommends changing from antegrade to retrograde crossing after 20 minutes of guidewire manipulation, but the threshold for change varies depending on CTO anatomy and local expertise in various crossing techniques (2).

STEP 9: INVESTMENT PROCEDURE. If CTO crossing attempts fail, a variety of investment procedures should be considered if the anticipated benefit exceeds the potential harm (24-26). For example, if an antegrade guidewire has been advanced intraplaque through an ambiguous proximal cap, balloon angioplasty of the proximal cap is recommended. Repeat CTO crossing attempts are usually performed after ≥ 2 months to allow healing of any created dissections.

STEP 10: WHEN TO STOP. Deciding when to stop the CTO crossing attempts depends on the dynamic balance between the likelihood of success and patient safety. The global CTO algorithm recommends stopping the CTO PCI procedure if the procedure time is >3 hours, if contrast volume is >3 times the estimated glomerular filtration rate, or if the air kerma radiation dose is >5 Gy, unless the procedure is well advanced. Even lower contrast volume thresholds may be used in patients with chronic kidney disease and comorbidities, such as diabetes (27). The procedure should also be stopped if it becomes evident that advanced crossing strategies, such as retrograde crossing or

ADR, are needed for successful crossing but the operator does not have expertise in those techniques or there is significant operator or patient fatigue. In such cases, referral to a CTO expert center or repeat attempt with a proctor could be considered. In most cases, occurrence of a serious complication should lead to discontinuation of CTO crossing attempts.

Optimal implementation of the global CTO algorithm is dependent on operator expertise in all CTO crossing strategies and techniques. Expertise can be developed in several ways, such as studying, attending meetings, and proctorship. Proctoring may not only improve an operator's CTO PCI skills but can also improve the safety of the CTO procedure, especially for highly complex lesions and patients.

CONCLUSIONS

CTO crossing algorithms are useful tools for optimizing the success and safety of CTO PCI. The global CTO crossing algorithm reflects the consensus of several experienced operators from multiple countries around the world and could help further improve the outcomes of these challenging procedures. This algorithm could help expand discussion, research, collaboration, and training in CTO PCI.

ACKNOWLEDGMENT The authors acknowledge the assistance Dr Karl Chi-Yuen Chan provided in the production of this document.

FUNDING SUPPORT AND AUTHOR DISCLOSURES

Dr Wu has received research funding from Abiomed, OrbusNeich, Asahi Intecc; has received consulting honoraria from Boston Scientific and Abbott Vascular; is a member of the board of directors for APCTO Club; and holds stock in Abbott Vascular. Dr Brilakis has received consulting and speaker honoraria from Abbott Vascular, the American Heart Association (associate editor, *Circulation*), Amgen, Biotronik, Boston Scientific, Cardiovascular Innovations Foundation (board of directors), ControlRad, CSI, Ebix, Elsevier, GE Healthcare, InfraRedx, Medtronic, Siemens, and Teleflex; has received research support from Regeneron and Siemens; is an owner of Hippocrates; and is a shareholder in MHI Ventures. Dr Mashayekhi has received consulting, speaker, and proctoring honoraria from Abbott Vascular, Asahi Intecc, AstraZeneca, Biotronik, Boston Scientific, Cardinal Health, Daiichi-Sankyo, Medtronic, Teleflex, and Terumo. Dr Tsuchikane is a consultant for Boston Scientific, Asahi Intecc, Nipro, and Kaneka. Dr Avran has received consulting, speaker, and proctoring honoraria from Asahi Intecc, Biotronik, Boston Scientific, Terumo, Alvimedica, and OrbusNeich. Dr Azzalini has received consulting fees from Abiomed and Teleflex. Dr Buller is global medical director of Teleflex. Dr Burke is a shareholder in Egg Medical and MHI Ventures. Dr Croce has received grants from Abbott, Takeda, Teleflex, and CSI; has received consulting honoraria from Abbott, BSCI, Biotronik, Philips, Abiomed, CSI, Takeda, and Cordis; and holds stock in Dyad Medical. Dr Damas de los Santos is a proctor, speaker, and consultant for Boston Scientific, Terumo, Abbott Vascular, and Biotronik. Dr Dens has consultancy contracts with Abbott, Boston Scientific, IMDS, Terumo, Topmedical (a distributor for Asahi); and is a chronic total occlusion proctor for Boston Scientific and Topmedical (Asahi). Dr di

Mario has received research grants from Abbott, Amgen, Behring, Daiichi-Sankyo, Edwards, Medtronic, and Shockwave Medical. Dr Egred has received chronic total occlusion proctorship fees, speaker fees, honoraria, and grants from Abbott Vascular, Boston Scientific, Philips, Spectranetics, Vascular Perspectives, Merrill, Biotronik, and AstraZeneca. Dr Elbarouni has received speaker fees from Teleflex and Bayer. Dr ElGuindy has received consulting, speaker, and proctoring honoraria from Medtronic, Boston Scientific, Asahi Intecc, and Terumo. Dr Escaned has received personal fees from Abbott, Boston Scientific, Terumo, and Phillips. Dr Furkalo has a proctoring agreement with Medtronic; and has received speaker honoraria from Sanofi. Dr Garbo is a proctor and consultant for Philips Volcano, Boston Europe, Terumo Italy, and Europe Teleflex. Dr Hall has received speaker honoraria from Medtronic, OpSens Medical, and the Cardiovascular Innovations Foundation. Dr Hanna Quesada has received honoraria from Boston Scientific. Dr Harb is a consultant for Medtronic and Cardinal Health; and has received speaker honoraria from Cardinal Health and Terumo. Dr Harding has received speaker and consultancy fees from Boston Scientific, Medtronic, Bio-Excel, and Asahi Intecc. Dr Hatem is a member of the Speakers Bureau for Abbott, Boston Scientific, and Teleflex. Dr Hoye has received speaker fees from AstraZeneca and Sanofi. Dr Jaber has received proctoring fees from Abbott; and has received consulting, advisory board, and institutional funds from Medtronic. Dr Jaffer conducts sponsored research for Canon, Siemens, Teleflex, and Shockwave; is a consultant for Boston Scientific, Siemens, Biotronik, and Magenta Medical; and holds equity interest in Intravascular Imaging. Dr Jussila has a proctoring contract with Boston Scientific and EPS Vascular. Dr Kalyanasundaram has received fees from Abbott Vascular, Boston Scientific, Asahi Intecc, and Terumo. Dr Kandzari has received institutional research grant support from Abbott, Biotronik, Boston Scientific, Cardiovascular Systems, Medtronic, Teleflex, and OrbusNeich; Dr Karpaliotis has received honoraria from Abbott Vascular and Boston Scientific; and holds equity in Saranas, Soundbite, and Traverse Vascular. Dr Kassem has received speaker honoraria from Boston Scientific, Abbott Vascular, GE, and Abiomed. Dr Khatri has received institutional research grant from Asahi Intecc and honoraria or consulting fees from Abbott Vascular, Boston Scientific, and Terumo. Dr Kornowski is a founder of NitiLoop. Dr Lamelas has received proctoring fees from Boston Scientific, Edwards Lifesciences, and Medtronic. Dr Lim has received educational support and honoraria from Asahi Intecc, Boston Scientific, Abbott Vascular, Kaneka, Biotronik, Alvimedica, Terumo, and Medtronic. Dr Lo has received speaker and proctoring honoraria from Bio-Excel, Boston Scientific, Abbott, and Terumo; and is a member of Medtronic's advisory board. Dr Lombardi has received royalties and is a consultant for Asahi Intecc; is a consultant for Abiomed, Boston Scientific,

Medtronic, Siemens, and Teleflex; and his spouse is an employee of Philips. Dr Maran is a consultant for Boston Scientific, Medtronic, and Philips. Dr Moses has received funding from Orchestra Biomedical and Ostial Corporation. Dr Munawar has received speaker and proctorship honoraria from Asahi Intecc, Terumo, Boston Scientific, Abbott Vascular, Toray, and Phillips. Dr Oksnes has proctoring contracts with Boston Scientific and EPS Vascular. Dr Olivecrona has received lecture honoraria from Abbott and Biotronik; and has received proctoring honoraria from EPS Vascular and Terumo. Dr Patel is a consultant for Abbott Vascular, Terumo, and Chiesi; and is a proctor for Medtronic. Dr Quadros has received honoraria from Boston Scientific; and has received research funding from Boston and Terumo. Dr Abi Rafah is a proctor and consultant for Boston Scientific, Abbott, and Shockwave Medical. Dr Råmunddal has received consulting honoraria from EPS Vascular, Boston Scientific, and Abbott Vascular. Dr Riley is an advisory board and Speakers Bureau member for and has received consulting honoraria from Boston Scientific, Asahi Intecc, and Medtronic. Dr Saghatlyan has received proctoring and speaker honoraria from Asahi Intecc and Terumo. Dr Spaedy is a consultant for Boston Scientific and Abbott Vascular. Dr Stone has received speaker or other honoraria from Cook and Terumo; is a consultant to Valfix, TherOx, Vascular Dynamics, Robocath, HeartFlow, Gore, Ablative Solutions, Miracor, Neovasc, V-Wave, Abiomed, Ancora, MAIA Pharmaceuticals, Vectorious, Reva, Matrizyme, Cardiomech, Elucid Bio, and Occlutech; and holds equity or options with Ancora, Cagent, Applied Therapeutics, the Biostar family of funds, SpectraWave, Orchestra Biomed, Aria, Cardiac Success, the MedFocus family of funds, and Valfix. Dr Tammam has a proctorship agreement with Terumo. Dr Tremmel has received honoraria from Abbott Vascular and Boston Scientific. Dr Wollmuth has received consulting, speaker, and proctoring honoraria from Abbott Vascular, Abiomed, Asahi Intecc, Biotronik, Boston Scientific, Cardiovascular Systems, Medtronic, and Philips. Dr Ybarra has received consulting and speaker fees from Abbott Vascular Canada and SoundBite Medical Solutions. Dr Yeh has received research grants from Abbott Vascular, AstraZeneca, Cook, BD Bard, Boston Scientific, Medtronic, and Philips; and is a consultant for Abbott Vascular, AstraZeneca, Boston Scientific, Edwards Lifesciences, Medtronic, Shockwave Medical, and Zoll. All other authors have reported that they have no relationships relevant to the contents of this paper to disclose.

ADDRESS FOR CORRESPONDENCE: Dr Eugene B. Wu, 9/F, Division of Cardiology, Department of Medicine & Therapeutics, Clinical Sciences Building, Prince of Wales Hospital, Shatin, N.T., Hong Kong. E-mail: cto.demon@gmail.com. Twitter: [@CtoDemon](https://twitter.com/CtoDemon).

REFERENCES

- Patel VG, Brayton KM, Tamayo A, et al. Angiographic success and procedural complications in patients undergoing percutaneous coronary chronic total occlusion interventions. *J Am Coll Cardiol Interv*. 2013;6(2):128-136.
- Tanaka H, Tsuchikane E, Muramatsu T, et al. A novel algorithm for treating chronic total coronary artery occlusion. *J Am Coll Cardiol*. 2019;74(19):2392-2404.
- Lamelas P, Padilla L, Abud M, et al. In-stent chronic total occlusion angioplasty in the LATAM-CTO registry. *Catheter Cardiovasc Interv*. 2021;97(1):E34-E39.
- Konstantinidis NV, Werner GS, Deftereos S, et al. Temporal trends in chronic total occlusion interventions in Europe. *Circ Cardiovasc Interv*. 2018;11(10):e006229.
- Wu EB, Tsuchikane E, Ge L, et al. Retrograde versus antegrade approach for coronary chronic total occlusion in an algorithm-driven contemporary Asia-Pacific Multicentre Registry: comparison of outcomes. *Heart Lung Circ*. 2020;29:894-903.
- Tajti P, Karpaliotis D, Alaswad K, et al. The hybrid approach to chronic total occlusion percutaneous coronary intervention: update from the PROGRESS CTO registry. *J Am Coll Cardiol Interv*. 2018;11:1325-1335.
- Maeremans J, Walsh S, Knaapen P, et al. The hybrid algorithm for treating chronic total occlusions in Europe: the RECHARGE registry. *J Am Coll Cardiol*. 2016;68:1958-1970.
- Brilakis ES, Grantham JA, Rinfret S, et al. A percutaneous treatment algorithm for crossing coronary chronic total occlusions. *J Am Coll Cardiol Interv*. 2012;5:367-379.
- Harding SA, Wu EB, Lo S, et al. A new algorithm for crossing chronic total occlusions from the Asia Pacific Chronic Total Occlusion Club. *J Am Coll Cardiol Interv*. 2017;10:2135-2143.
- Ge J, on behalf of CTOCC. Strategic roadmap of percutaneous coronary intervention for chronic total occlusions. *Cardiol Plus*. 2018;3:30-37.
- Galassi AR, Werner GS, Boukhris M, et al. Percutaneous recanalisation of chronic total occlusions: 2019 consensus document from the EuroCTO Club. *EuroIntervention*. 2019;15:198-208.
- Brilakis ES, Mashayekhi K, Tsuchikane E, et al. Guiding principles for chronic total occlusion

percutaneous coronary intervention. *Circulation*. 2019;140:420-433.

13. Rinfret S, Harding SA. A new Japanese CTO algorithm: a step forward or backward? *J Am Coll Cardiol*. 2019;74:2405-2409.

14. Werner GS. Use of coronary computed tomographic angiography to facilitate percutaneous coronary intervention of chronic total occlusions. *Circ Cardiovasc Interv*. 2019;12(10):e007387.

15. Vo MN, Karpaliotis D, Brilakis ES. "Move the cap" technique for ambiguous or impenetrable proximal cap of coronary total occlusion: move the cap technique. *Cathet Cardiovasc Interv*. 2016;87:742-748.

16. Nagamatsu W, Tsuchikane E, Oikawa Y, et al. Successful guidewire crossing via collateral channel at retrograde percutaneous coronary intervention for chronic total occlusion: the J-Channel score. *EuroIntervention*. 2020;15(18):e1624-e1632.

17. Huang C-C, Lee C-K, Meng S-W, et al. Collateral channel size and tortuosity predict retrograde percutaneous coronary intervention success for chronic total occlusion. *Circ Cardiovasc Interv*. 2018;11(1):e005124.

18. Rossi JE, Nair R, Ellis SG, Kapadia SR, Khatri JJ. Use of polymer-jacketed, tapered-tip, low-force

guidewires with composite-core, dual-coil design as part of the antegrade approach to coronary chronic total occlusions. *J Invasive Cardiol*. 2020;32:161-168.

19. Wu EB, Tsuchikane E, Lo S, et al. Chronic total occlusion wiring: a state-of-the-art guide from the Asia Pacific Chronic Total Occlusion Club. *Heart Lung Circ*. 2019;28:1490-1500.

20. Karacsonyi J. Randomized comparison of a CrossBoss first versus standard wire escalation strategy for crossing coronary chronic total occlusions. *J Am Coll Cardiol Interv*. 2018;11:225-233.

21. Karatasakis A, Danek BA, Karacsonyi J, et al. Mid-term outcomes of chronic total occlusion percutaneous coronary intervention with sub-adventitial vs. intraplaque crossing: a systematic review and meta-analysis. *Int J Cardiol*. 2018;253:29-34.

22. Matsuno S, Tsuchikane E, Harding SA, et al. Overview and proposed terminology for the reverse controlled antegrade and retrograde tracking (reverse CART) techniques. *EuroIntervention*. 2018;14(1):94-101.

23. Wu EB, Tsuchikane E, Lo S, et al. The retrograde algorithm for chronic total occlusion from

the Asia Pacific Chronic Total Occlusion Club. *Asian Interv*. 2018;4:98-107.

24. Hirai T, Grantham JA, Sapontis J, et al. Impact of subintimal plaque modification procedures on health status after unsuccessful chronic total occlusion angioplasty. *Catheter Cardiovasc Interv*. 2018;91:1035-1042.

25. Xenogiannis I, Choi JW, Alaswad K, et al. Outcomes of subintimal plaque modification in chronic total occlusion percutaneous coronary intervention. *Catheter Cardiovasc Interv*. 2020;96:1029-1035.

26. Hirai T, Grantham JA, Gosch KL, et al. Impact of subintimal or plaque modification on repeat chronic total occlusion angioplasty following an unsuccessful attempt. *J Am Coll Cardiol Interv*. 2020;13:1010-1012.

27. Almendarez M, Gurm HS, Mariani J, et al. Procedural strategies to reduce the incidence of contrast-induced acute kidney injury during percutaneous coronary intervention. *J Am Coll Cardiol Interv*. 2019;12(19):1877-1888.

KEY WORDS chronic total occlusion, global, percutaneous coronary intervention, treatment algorithm