

## PUBLISHED VERSION

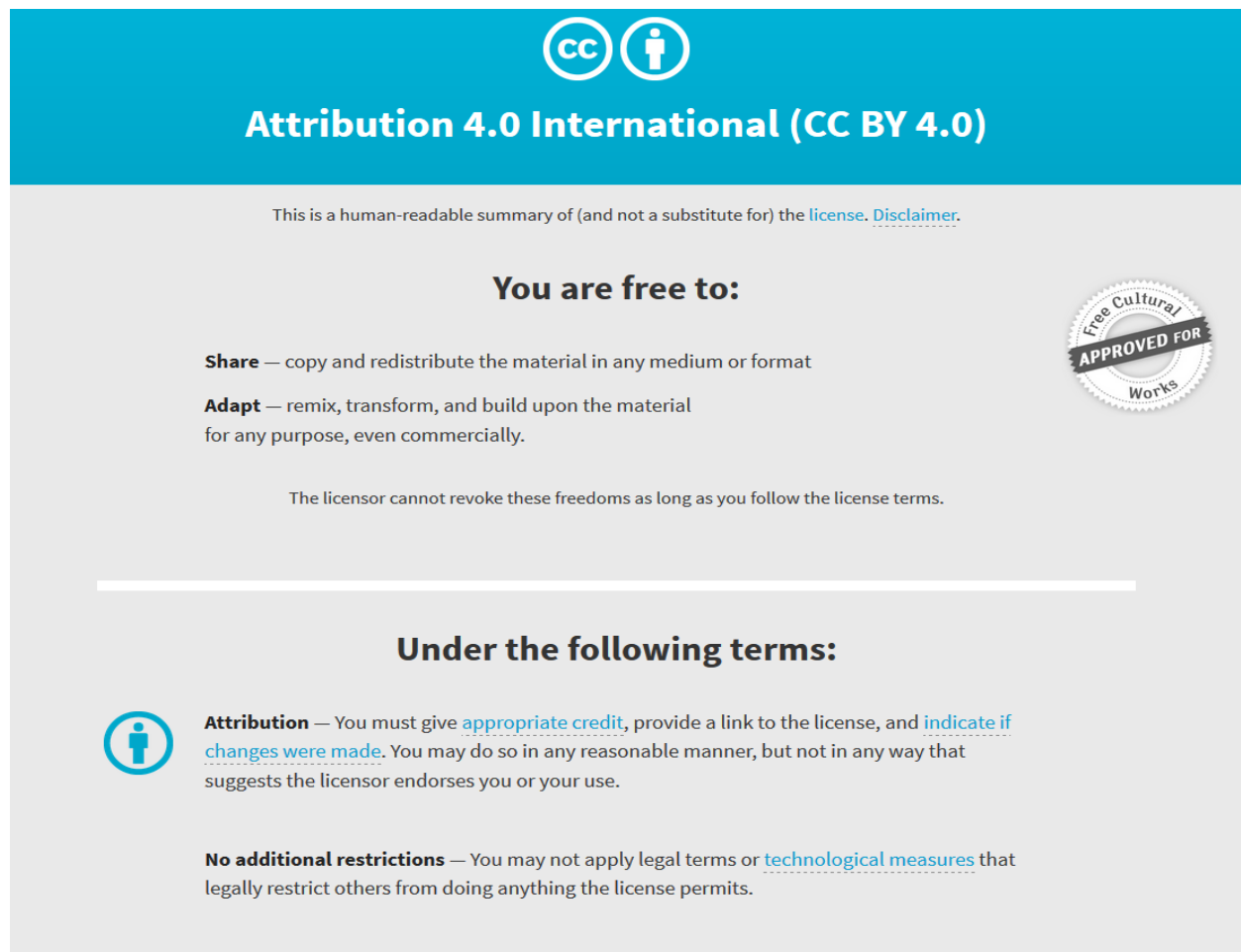
Liza Johannesson, Jennifer Mason, John Miller, Selva-Nayagam S, and Oehler MK  
**Primary non-Hodgkin's lymphomas of the uterus and uterine cervix**  
Oncology & Cancer Case Reports, 2017; 3(1):1000127-1-1000127-5

Copyright: © 2017 Johannesson L, et al. This is an open-access article distributed under the terms of the Creative Commons Attribution License, which permits unrestricted use, distribution, and reproduction in any medium, provided the original author and source are credited.

Published version <http://dx.doi.org/10.4172/2471-8556.1000127>

### PERMISSIONS

<http://creativecommons.org/licenses/by/4.0/>



The image shows the Creative Commons Attribution 4.0 International (CC BY 4.0) license banner. It features the CC logo and a person icon in a circle. The text reads "Attribution 4.0 International (CC BY 4.0)". Below this, it states "This is a human-readable summary of (and not a substitute for) the license. [Disclaimer.](#)". The main heading is "You are free to:", followed by two bullet points: "Share — copy and redistribute the material in any medium or format" and "Adapt — remix, transform, and build upon the material for any purpose, even commercially." A circular seal on the right says "Free Cultural Works APPROVED FOR". Below this, it states "The licensor cannot revoke these freedoms as long as you follow the license terms." A horizontal line separates this from the "Under the following terms:" section. The first term is "Attribution" with a person icon in a circle, stating "You must give [appropriate credit](#), provide a link to the license, and [indicate if changes were made](#). You may do so in any reasonable manner, but not in any way that suggests the licensor endorses you or your use." The second term is "No additional restrictions" stating "You may not apply legal terms or [technological measures](#) that legally restrict others from doing anything the license permits."

6 September 2018

<http://hdl.handle.net/2440/114221>

## Primary Non-Hodgkin's Lymphomas of the Uterus and Uterine Cervix

Liza Johannesson<sup>1</sup>, Jennifer Mason<sup>1</sup>, John Miller<sup>1</sup>, Selva-Nayagam S<sup>2</sup>, and Oehler MK<sup>1,3\*</sup>

<sup>1</sup>Department of Gynaecological Oncology, Royal Adelaide Hospital, Adelaide, South Australia, Australia

<sup>2</sup>Department of Medical Oncology, Royal Adelaide Hospital, Adelaide, South Australia, Australia

<sup>3</sup>Discipline of Obstetrics and Gynaecology, University of Adelaide, Adelaide, South Australia, Australia

### Abstract

**Objective:** Primary malignant non-Hodgkin's lymphomas in the female genital tract are rare, accounting for less than 1% of all extranodal non-Hodgkin's lymphomas.

**Methods/materials:** We report on four cases of primary non-Hodgkin's lymphomas of the uterus and cervix. Three of our patients were confirmed to be diffuse large B-cell lymphomas (DLBCL) and one patient to be T-cell rich DLBCL on histopathological examination and immunohistochemical study. One of our three patients who presented with diffuse DLBCL was diagnosed with intravascular diffuse DLBCL. Other potential origins of disease were excluded.

**Results:** Two patients were successfully treated with chemotherapy, one with the addition of involved field radiotherapy post chemotherapy, while two had surgery followed by chemotherapy. All four patients are in complete remission with follow up period ranging from 6 months to 5 years.

**Conclusions:** Gynaecological lymphomas can be a diagnostic challenge due to unspecific symptoms. However, when diagnosed and treated they have a good prognosis. Clinicians should therefore include lymphoma in their differential diagnosis when investigating gynaecological symptoms.

**Keywords:** Lymphoma; Gynecological cancer; Non-Hodgkin; Uterus; Uterine cervix

### Introduction

Non-Hodgkin's lymphomas (NHL) represent 90% of all lymphomas [1] and most commonly occur in lymph nodes or lymphoid tissue of the thymus, spleen, bone marrow or Waldeyer's ring (tonsils, base of the tongue and nasopharynx). Extra-nodal NHL accounts for approximately one fifth of all cases, and the most frequent locations are the lung, gastrointestinal tract, nervous system and skin [1]. Lymphomas involving the female genital tract are rare, and those originating from this region are extremely uncommon. Primary NHL of the female genital tract account for less than 0.5% of all gynaecological malignancies [2]. As primary sites of NHL, the uterus and cervix are very uncommon and account for 0.5% of extra-nodal lymphomas [3,4]. The majority of NHLs arising from the uterus and cervix are aggressive lymphomas of diffuse large B-cell NHL type (DLBCL) [5]. The presentation of uterine lymphoma is often subclinical; hence diagnosis can be difficult, especially in the differential diagnosis of common neoplasms such as fibroids or sarcomas [6]. Symptoms of patients with cervical lymphomas may include vaginal bleeding, perineal discomfort and/or vaginal discharge. As cervical lymphomas often arise from the cervical stroma the epithelium is initially preserved and therefore PAP smears during routine cervical screening are often normal.

Due to the rarity of uterine and cervical lymphomas treatment is usually highly individualized. Surgery usually plays a limited role as therapeutic modality as gynaecological lymphomas are commonly radio- and chemotherapy-sensitive [7], and is predominantly used for initial diagnosis.

We report on four cases of primary large B-cell lymphomas (DLBCL) of the uterus and cervix. Other potential origins of disease were excluded clinically and radiologically. Two patients were successfully treated with chemotherapy, one with the addition of involved field radiotherapy post chemotherapy, while two had surgery followed by chemotherapy.

### Results

#### Case 1

34-year-old, gravida 0, presented with intermenstrual bleeding during evaluation of infertility. She did not have any B-symptoms (night sweats, weight loss and fever) and had previously been healthy. However, there was a medical history of chronic idiopathic neutropenia, not requiring treatment, and mild asthma. A pelvic ultrasound demonstrated a normal appearing uterus and ovaries and no cause for her symptoms was identified. On gynaecological examination a cervical mass was noted and a PAP smear was taken which showed a low grade squamous intraepithelial lesion and abnormal cells consistent with human papillomavirus (HPV) infection. However, a cervical biopsy showed NHL of large cell type, positive for CD20 and BCL6 with a GCB phenotype. CT imaging revealed a 55 × 71 mm cervical mass with enlarged bilateral pelvic lymph nodes (17 × 13, 20 × 16, 15 × 12 mm) and a prominent left axillary lymph node (7 × 5 mm). Subsequent PET imaging showed an intensely FDG avid large cervical mass, bilateral external iliac and left axillary lymph nodes and low grade FDG activity throughout the bone marrow, with a normal liver and spleen. FISH testing was negative for cMYC. Final diagnosis was DLBCL. The patient received primary chemotherapy consisting of 6 cycles of R-CHOP 14 (C, Cyclophosphamide H, Doxorubicin Hydrochloride O, Vincristine (Oncovin) E, Etoposide P, Prednisolone) and had Goserelin (Zoladex™)

**\*Corresponding author:** Oehler MK, Department of Gynaecological Oncology, Royal Adelaide Hospital, North Terrace, Adelaide, SA 5000, Australia, Tel: +61883326622; E-mail: [martin.oehler@adelaide.edu.au](mailto:martin.oehler@adelaide.edu.au)

**Received:** January 09, 2017; **Accepted:** March 21, 2017; **Published:** March 25, 2017

**Citation:** Johannesson L, Mason J, Miller J, Selva-Nayagam S, Oehler MK (2017) Primary Non-Hodgkin's Lymphomas of the Uterus and Uterine Cervix. *Oncol Cancer Case Rep* 3: 127. doi: 10.4172/2471-8556.1000127

**Copyright:** © 2017 Johannesson L, et al. This is an open-access article distributed under the terms of the Creative Commons Attribution License, which permits unrestricted use, distribution, and reproduction in any medium, provided the original author and source are credited.

injections for ovarian protection. CT imaging at the end of treatment after 4 months showed a normal cervix and no lymphadenopathy. The PET scan was also normal.

A cervical biopsy which was taken due to an inconclusive Pap smear after the treatment did not show any residual lymphoma. After six months, the patient remains in complete remission.

## Case 2

57-year-old patient presented with a 12 months history of intermittent irregular postmenopausal bleeding. She did not have any B-symptoms and had previously been healthy. An MRI scan revealed a 5 cm cervical mass with a left obturator lymph node measuring 16 × 20 mm and two iliac chain nodes measuring 19 × 14 mm and 28 × 15 mm, respectively. Subsequent CT and PET imaging showed no other lymphadenopathy or disease outside of the pelvis. Fine needle aspiration of the cervix revealed lymphoma. CT guided biopsy of the left iliac chain node was suspicious of intermediate grade lymphoma as CD 10, CD 19 and CD 20 were positive. Final diagnosis was DLBCL in a background of follicular lymphoma. Bone marrow biopsy was normal but PET imaging showed findings consistent with FDG avid lymphomatous disease in the distal aspect of the uterus/cervix and lymph node metastasis involving the left iliac lymph nodes. The patient was treated with 6 cycles of R-CHOP 21 and involved field radiotherapy. Restaging imaging after 5 months of treatment showed no pathologically enlarged pelvic or abdominal lymph nodes on CT scan and normalization of the PET. The patient remains in complete remission after 5 years.

## Case 3

58-year-old patient presented with three episodes of postmenopausal spotting over 4 months but without any B symptoms. She did not have any significant surgical or medical history. Curettage of the uterus was performed and showed a malignancy suspicious for a sarcoma in the histopathology. CT imaging showed an unremarkable uterus but para-aortic lymphadenopathy. The patient underwent an abdominal hysterectomy, bilateral salpingo-oophorectomy and para-aortic lymph dissection. Intraoperatively the uterus was found to be mobile and not enlarged but there was a 10 cm to 12 cm mass in the small bowel mesentery extending up to the pancreas. On opening, the uterus had a polypoid lesion within the cavity which in the histopathology was found to be a T cell rich B cell NHL. Postoperative PET imaging showed increased FDG uptake within left supraclavicular, paraoesophageal, porta hepatis and mesenteric lymph nodes. It also showed skeletal uptake in the T9 and T12 vertebral bodies, right iliac bone adjacent to the sacro-iliac joint and the left femoral neck. Final diagnosis was a T-cell rich BCL. The patient was treated with 6 cycles of R-CHOP 21 chemotherapy. Post chemotherapy PET imaging showed no FDG avid residual disease. The patient had 3 years of follow up and was in complete remission. Her blood count occasionally demonstrated mild leukopenia and thrombocytopenia but remained stable otherwise.

## Case 4

61-year-old patient presented with an S1 distribution of right leg discomfort and paraesthesia following a two month history of atypical migraine, as well as a left paracentral visual disturbance with increased colour perception. Initially the patient did not have any B symptoms but later developed both weight loss and night sweats. She had previously been healthy. An MRI of the lumbar spine and sciatic nerve was normal. Nerve conduction studies were most suggestive of L5/S1 radiculopathy. On review two weeks later, the right leg weakness

had progressed and was now global with an absent ankle reflex. The patient developed reduced perineal sensation as well as difficulties passing urine. Ascending sensory deficits were observed, as well as a new onset of pyramidal pattern weakness in the left leg, with brisk knee jerk and an extensor plantar response. By this time, she had also developed constitutional symptoms of lethargy, night sweats and 5 kg weight loss within one month. A PET scan demonstrated abnormal uptake in the lung apices and bilateral hilar regions, diffuse myometrial activity and diffuse uptake in the bone marrow. Repeat MRI of the brain and full spine demonstrated abnormal meningeal infiltrative disease as well as diffuse enhancement of the pachymeninges. There was also a widespread marrow abnormality consistent with an infiltrative process. The patient underwent a bone marrow biopsy which revealed a hyperplastic marrow with evidence of haemophagocytosis and a single lymphoid aggregate. Given the FDG avidity of the myometrium on PET, a hysteroscopy and laparoscopy were performed. Hysteroscopy revealed a slightly thickened endometrium with a small uterine polyp. On laparoscopy, opaque ascites and a bulky uterus were identified. Histology from uterine curettage showed a large cell malignancy consistent with a large cell lymphoma. The patient had a robotic hysterectomy, bilateral salpingo-oophorectomy and pelvic lymph node sampling. Histology of the uterine wall and pelvic lymph nodes revealed an intravascular large B-cell lymphoma. The patient was treated with R-CVP with intrathecal methotrexate as initial debulking therapy followed by six cycles of R-Hyper CVAD chemotherapy. A post chemotherapy PET scan revealed no FDG avidity. The patient has remained in full remission for 4 years.

## Discussion

NHL in general and extra-nodal NHL in particular has increased in incidence over the last decades; the reason for this is unclear [8]. It has been suggested that the aetiology of NHL may include infectious diseases, such as HIV, immunosuppressive drugs and exposure to environmental agents, such as pesticides and pollutants [9]. Primary lymphomas of the uterus and cervix are very rare, with less than 1% of patients with any type of lymphoma presenting with this site of disease. In a study by Kosari, et al. which analysed 117 cases of lymphomas involving the genital tract in female patients, 63% were classified as primary lymphomas of the female genital tract and 37% as secondary involvement [10]. Most commonly affected sites were the adnexa (56%), followed by uterine corpus (15%) and cervix (11%) [10]. The World Health Organization classifies lymphoid neoplasms into subgroups of mature B-cell neoplasms, mature T and NK neoplasms, Hodgkin lymphomas, post-transplant lymphoproliferative disorders and histiocytic and dendritic cell neoplasms [11]. Regardless of the site of involvement, DLBCL is the most common histological subtype in the female genital tract. The mean age in our case series was 52.5 years (range 34-61 years) which is consistent with the mean age of 50.4 years in previous reports [10]. Three of our patients were diagnosed with DLBCL and one patient had T-cell rich LBCL. One of our three patients who presented with DLBCL was diagnosed with intravascular DLBCL. Intravascular large B-cell lymphoma is a very rare subtype of DLBCL with an estimated incidence of less than one in a million in the population. The first case of primary intravascular large B cell lymphoma of the uterus was reported in 2004 [12]. Intravascular lymphomas (IVL) usually present in the central nervous system or skin [13]. IVL of the uterus or cervix are extremely rare and to our knowledge only seven cases has been reported in the literature [12,14-19]. Because of the rarity of IVL and the variability of the clinical presentation, the diagnosis is often made at autopsy [13]. Diagnosis of IVL is almost exclusively made

by biopsy of a involved site [13]. In our case a uterine curettage proved to be insufficient to obtain the correct diagnosis. The final diagnosis of IVL was made on the hysterectomy specimen.

Since gynecological lymphomas are often either subclinical or mimic other genital tumors or disorders, they can be difficult to diagnose and differentiate from more common conditions. Presenting symptoms can be abdominal pain, vaginal bleeding and discharge, dyspareunia and/or symptoms of a pelvic mass [20]. Pap smears of the cervix are usually negative, likely due to the fact that most lymphomas are frequently located in the sub-epithelial layer of the cervix [21]. In our case series three patients presented with bleeding disorders (two with postmenopausal and one with intermenstrual bleeding) and one patient with right leg discomfort and paresthesia after two months of atypical migraine with visual disturbance. Systemic complaints are common in lymphoma patients, and up to 40 percent of patients with NHL present with fever, weight loss, or night sweats (i.e. B symptoms) [22]. The clinical examination is often focused on detection of potentially involved lymphoid sites; palpable adenopathy or hepatosplenomegaly and the findings of these symptoms are important in determining prognosis [23]. In this study, only one of our patients (case 4) developed B symptoms, however, with some delay.

To enable prompt diagnosis and treatment of uterine and cervical lymphomas, clinicians should keep in mind that the presentation may be non-specific, and a high index of suspicion is therefore required. On imaging the appearance of uterine and cervical lymphomas can vary but diffuse enlargement of the uterus without disruption of the endometrial epithelium has been reported to be a characteristic finding [24]. Most commonly the uterine tumour is heterogeneous due to sites of haemorrhage, calcifications and necrosis [24]. Three of our patients had a normal appearing uterus on imaging at presentation. Only one case (case 4) had thickened endometrium with a polyp and an enlarged bulky uterus. The apparent normal appearance of the uterus can be misleading, and potentially delay diagnosis.

Definitive diagnosis of lymphoma always requires a biopsy and histopathological assessment with immunohistochemistry and fresh tissue for flow cytometry. In our cases the histopathological examination revealed LBCL in all cases (Figures 1 and 2). The results of the immunohistochemistry are summarized in Table 1.

The Ann Arbor staging system, developed in 1971, was initially used solely for staging Hodgkin lymphomas, however, has subsequently been adapted to include also NHL. The staging criteria for the four stages are the number and location of affected lymph node regions and/or extra-nodal sites. The presence or absence of B symptoms is also incorporated into the staging system. It has been suggested that staging plays a lesser role in determining prognosis compared to histological features and is more useful in deciding when patients may benefit from more than one treatment modality [25]. The disease stages of our patients are shown in Table 1.

The rarity of patients presenting with primary gynaecological lymphoma contributes to the difficulties of diagnosis and lack of consensus regarding treatment. Lymphomas are usually very chemo- and radiosensitive and consequently surgery has only a limited role [7]. However, it is not uncommon for the final diagnosis to be made after surgery (as in patient 3 and 4). In those cases, histopathology of the curettings was suspicious for sarcoma (case 3) and large cell lymphoma (case 4) whilst subsequent definitive surgery showed a T-cell rich B-cell NHL in one case (case 3) and intravascular LBCL in the other (case 4).

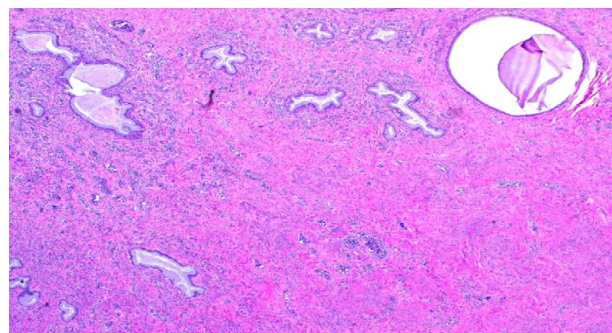


Figure 1: Diffuse large B-cell lymphoma of uterine cervix (Case 3).

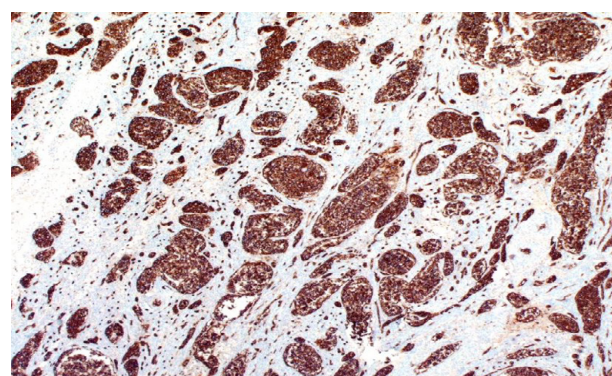


Figure 2: Immunohistochemistry showing CD20 positivity (Case 3).

In some lymphomas of the female genital tract a hysterectomy could be regarded as an important diagnostic procedure to make the correct diagnosis. However, none of the hysterectomies was performed for therapeutic purposes.

Traditionally, the recommended treatment for DLBCL has been chemotherapy  $\pm$  radiotherapy [20]. Lately, other modalities such as allogeneic bone-marrow transplantation, monoclonal antibodies and high-dose chemotherapy have shown improved outcomes [7]. In our case series, all patients were treated with chemotherapy  $\pm$  monoclonal anti CD Ab Rituximab. One patient received additional radiotherapy.

The reported 5-year survival of primary cervical and uterine lymphomas in the literature is approximately 80% [26]. However, the prognosis for IVL is generally poor [27,28]. In a review from Yamamoto et al. on five cases with uterine IVL, two died within 5 months, two after 10 months and one 51 months after diagnosis [17]. In our case series, all patients remain in full remission after follow up ranging from 6 months to 5 years. The prognosis of aggressive NHL can be calculated using the revised international prognostic index (R-IPI) which includes age, Ann Arbor stage, hemoglobin level, serum LDH level, and number of nodal sites [29]. The prognostic index identifies three distinct prognostic groups (very good, good and poor). Patients with no risk factors (very good prognosis) show more than 90% long-term progression free survival, patients with 1 or 2 risk factors (good prognosis) 80% and patients with 3-5 risk factors (poor prognosis) have a long-term chance of cure in 50%.

Our cases showed IPI ranging from 0-3 (Table 1).

	Case 1	Case 2	Case 3	Case 4
Age (years)	34	57	58	61
Presenting symptom	Intermenstrual bleeding	Postmenopausal bleeding	Postmenopausal bleeding	S1 distribution right leg discomfort and paraesthesia
B symptoms	Negative	Negative	Negative	Positive
Hepatosplenomegaly	Negative	Negative	Negative	Positive
Extranodal site	Cervix	Cervix	Uterus	Uterus
Diagnosis	DLBCL	DLBCL	T-cell rich LBCL	IVDLBCL
Stage	III AE	II AE	IV AE	IV BE
IPI	1	0	1	3
LDH	Normal	Normal	Normal	Elevated
CD10	Negative	Positive	Positive	Negative
CD19	Positive	Positive	Positive	Positive
CD20	Positive	Positive	Positive	Positive
BCL2	Negative	Unknown	Positive	Positive
Therapy	Chemotherapy	Chemotherapy, Radiotherapy	Chemotherapy	Chemotherapy
Response	CR	CR	CR	CR
Post treatment follow-up	6 months	5 years	3 years	4 years

DLBCL, Diffuse large B cell lymphoma; IVDLBCL, Intravascular diffuse large B cell lymphoma; CR, Complete remission; IPI, International Prognostic Index

**Table 1:** Characteristics of patients with primary non-Hodgkin's lymphomas of the uterus and uterine cervix.

## Conclusion

Although the incidence of NHL is increasing, primary gynaecological lymphomas are rare and can be a diagnostic challenge due to unspecific symptoms resembling other more common conditions. However, when diagnosed and treated with aggressive chemotherapy, gynaecological lymphomas commonly have a good prognosis. Clinicians should therefore include lymphoma in their differential diagnosis when investigating gynaecological symptoms.

## References

- Shankland KR, Armitage JO, Hancock BW (2012) Non-Hodgkin lymphoma. *Lancet* 380: 848-857.
- Yamada T, Iwao N, Kasamatsu H, Mori H (2003) A case of malignant lymphoma of the ovary manifesting like an advanced ovarian cancer. *Gynecol Oncol* 90: 215-219.
- Chorlton I, Karnei RF, King FM, Norris HJ (1974) Primary malignant reticuloendothelial disease involving the vagina, cervix, and corpus uteri. *Obstet Gynecol* 44: 735-748.
- Frey NV, Svoboda J, Andreadis C, Tsai DE, Schuster SJ, et al. (2006) Primary lymphomas of the cervix and uterus: The University of Pennsylvania's experience and a review of the literature. *Leuk Lymphoma* 47: 1894-901.
- Garavaglia E, Taccagni G, Montoli S, Panacci N, Ponzoni M, et al. (2005) Primary stage I-II E non-Hodgkin's lymphoma of uterine cervix and upper vagina: Evidence for a conservative approach in a study on three patients. *Gynecol Oncol* 97: 214-218.
- Vang R, Medeiros LJ, Ha CS, Deavers M (2000) Non-Hodgkin's lymphomas involving the uterus: A clinicopathologic analysis of 26 cases. *Mod Pathol* 13: 19-28.
- Berthold D, Ghielmini M (2004) Treatment of malignant lymphoma. *Swiss medical weekly*. 134: 472-480.
- Hanprasertpong J, Hanprasertpong T, Thammavichit T, Kongkabpan D, Tungsinmunkong K, et al. (2008) Primary non-Hodgkin's lymphoma of the uterine cervix. *Asian Pac J Cancer Prev* 9: 363-366.
- Trenhaile TR, Killackey MA (2001) Primary pelvic non-Hodgkin's lymphoma. *Obstet Gynecol* 97: 717-720.
- Kosari F, Daneshbod Y, Parwaresch R, Krams M, Wacker HH (2005) Lymphomas of the female genital tract: A study of 186 cases and review of the literature. *Am J Surg Pathol* 29: 1512-1520.
- Swerdlow SH, Campo E, Pileri SA, Harris NL, Stein H, et al. (2016) The 2016 revision of the World Health Organization classification of lymphoid neoplasms. *Blood* 127: 2375-2390.
- Sur M, Ross C, Moens F, Daya D (2005) Intravascular large B-cell lymphoma of the uterus: A diagnostic challenge *Int J Gynecol Pathol* 24: 201-203.
- Zuckerman D, Seliem R, Hochberg E (2006) Intravascular lymphoma: The oncologist's "great imitator". *The oncologist* 11: 496-502.
- Yamada N, Uchida R, Fuchida S, Okano A, Okamoto M, et al. (2005) CD5+ Epstein-Barr virus-positive intravascular large B-cell lymphoma in the uterus co-existing with huge myoma. *Am j hematol* 78: 221-224.
- Lannoo L, Smets S, Steenkiste E, Delforge M, Moerman P, et al. (2007) Intravascular large B-cell lymphoma of the uterus presenting as fever of unknown origin (FUO) and revealed by FDG-PET. *Acta Clin Belg* 62: 187-190.
- Davey DD, Munn R, Smith LW, Cibull ML (1990) Angiotrophic lymphoma. Presentation in uterine vessels with cytogenetic studies. *Arch Pathol Lab Med* 114: 879-882.
- Yamamoto T, Morita K, Iriyama N, Wakui K, Hiroi A, et al. (2011) Intravascular large B-cell lymphoma of the uterus: A case with favorable clinical outcome. *Int J Surg Pathol* 19: 672-676.
- Xia Y, Wang Y, Jiang Y, Yu W, Li Y, et al. (2014) Primary intravascular large B cell lymphoma of the endometrium. *Acta Histochem* 116: 993-996.
- Shigematsu Y, Matsuura M, Nishimura N, Tsuyama N, Takeuchi K, et al. (2016) Intravascular Large B-cell Lymphoma of the Bilateral Ovaries and Uterus in an Asymptomatic Patient with a t(11;22) (q23;q11) Constitutional Translocation. *Internal Med* 55: 3169-3174.
- Signorelli M, Maneo A, Cammarota S, Isimbaldi G, Garcia Parra R, et al. (2007) Conservative management in primary genital lymphomas: The role of chemotherapy. *Gynecol Oncol* 104: 416-421.
- King JA, Elkhalfi MY, Michael C (1997) Malignant lymphoma identified on a cervical cytologic smear, with immunophenotypic analysis. *Acta Cytol* 41: 1228-1230.
- Anderson T, Chabner BA, Young RC, Berard CW, Garvin AJ, et al. (1982) Malignant lymphoma. 1. The histology and staging of 473 patients at the National Cancer Institute. *Cancer* 50: 2699-26707.
- Weingertner AS, Hamid D, Roedlich MN, Baldauf JJ (2004) Non-Hodgkin malignant lymphoma revealed by an ovarian tumor case report and review of the literature. *Gynecol Oncol* 95: 750-754.
- Park SB, Lee YH, Song MJ, Cho HC, Lee MS, et al. (2012) Sonographic findings of uterine cervical lymphoma manifesting as multinodular lesions. *Clin Imaging* 36: 636-638.
- Ansell SM (2015) Hodgkin lymphoma: Diagnosis and treatment. *Mayo Clin Proc* 90: 1574-1583.
- Onyiuke I, Kirby AB, McCarthy S (2013) Primary gynecologic lymphoma: Imaging findings. *AJR* 201: 648-655.

27. Murase T, Yamaguchi M, Suzuki R, Okamoto M, Sato Y, et al. (2007) Intravascular large B-cell lymphoma (IVLBCL): A clinicopathologic study of 96 cases with special reference to the immunophenotypic heterogeneity of CD5 *Blood* 109: 478-485.
28. Ponzoni M, Ferreri AJ, Campo E, Facchetti F, Mazzucchelli L, et al. (2007) Definition, diagnosis, and management of intravascular large B-cell lymphoma: Proposals and perspectives from an international consensus meeting. *J Clin Oncol* 25: 3168-3173.
29. Sehn LH, Berry B, Chhanabhai M, Fitzgerald C, Gill K, et al. (2007) The revised International Prognostic Index (R-IPI) is a better predictor of outcome than the standard IPI for patients with diffuse large B-cell lymphoma treated with R-CHOP. *Blood* 109: 1857-1861.

**Citation:** Johannesson L, Mason J, Miller J, Selva-Nayagam S, Oehler MK (2017) Primary Non-Hodgkin's Lymphomas of the Uterus and Uterine Cervix. *Oncol Cancer Case Rep* 3: 127. doi: [10.4172/2471-8556.1000127](https://doi.org/10.4172/2471-8556.1000127)

### OMICS International: Open Access Publication Benefits & Features

**Unique features:**

- Increased global visibility of articles through worldwide distribution and indexing
- Showcasing recent research output in a timely and updated manner
- Special issues on the current trends of scientific research

**Special features:**

- 700+ Open Access Journals
- 50,000+ editorial team
- Rapid review process
- Quality and quick editorial, review and publication processing
- Indexing at major indexing services
- Sharing Option: Social Networking Enabled
- Authors, Reviewers and Editors rewarded with online Scientific Credits
- Better discount for your subsequent articles

Submit your manuscript at: <http://www.omicsonline.org/submission/>