

CASE REPORT

A case of chest tightness variant asthma : the usefulness of fractional exhaled nitric oxide as a marker for the diagnosis and clinical improvement.

Masaki Hanibuchi¹, Atsushi Mitsuhashi², Tatsuya Kajimoto¹, Atsuro Saijo¹, and Tetsuya Kitagawa³

¹Department of Respiratory Medicine, ³Department of Cardiovascular Surgery, Shikoku Central Hospital of the Mutual aid Association of Public School teachers, Shikoku-Chuo, Japan, ²Department of Respiratory Medicine and Rheumatology, Graduate School of Biomedical Sciences, Tokushima University, Tokushima, Japan

Abstract : A 50-year-old woman was referred to our hospital for further examination of severe constricting pain at the right-side dominant anterior chest. She had medical history of outgrown childhood asthma and allergies to several animals. Chest auscultation revealed no wheezes, rhonchi and other crackles. Laboratory findings showed an eosinophilia and an elevation of total immunoglobulin E. The results of an electrocardiogram, a chest X-ray and a chest CT were unremarkable. A fractional exhaled nitric oxide value remarkably elevated, but the abnormalities in pulmonary function test were modest. Her chest pain was ameliorated after inhaling procaterol. Based on these findings, a diagnosis of chest tightness variant asthma was formulated, and we started treatment with inhaled corticosteroid/long acting β_2 agonist. At two-weeks after treatment, her symptom markedly improved and a fractional exhaled nitric oxide value decreased, which led to a definitive diagnosis of chest tightness variant asthma. A fractional exhaled nitric oxide value further decreased to the normal range in consistent with symptom disappearance at 10-months after treatment, indicating the usefulness of fractional exhaled nitric oxide as a promising marker for the diagnosis and clinical improvement of chest tightness variant asthma. *J. Med. Invest.* 68:389-392, August, 2021

Keywords : chest tightness variant asthma, fractional exhaled nitric oxide, biomarker

INTRODUCTION

Asthma is a chronic inflammatory respiratory disease that is commonly characterized by airway hyperresponsiveness and reversible airway obstruction in the airway, and all asthmatics share common physiologic airway abnormalities in theory. Despite these shared features, asthma has been recognized to have the great heterogeneity and may be manifested in various clinical phenotypes (1, 2). In 2013, Shen *et al.* reported patients with atypical asthma whose sole presenting clinical manifestation was chest tightness and referred to this type of asthma as chest tightness variant asthma (CTVA) (3). CTVA is considered as a rare variant form of asthma, but sufficient data are yet to be collected to clarify its accurate disease concept. In the present report, we demonstrated a case of CTVA who presented chest pain as the sole symptom and highlighted the usefulness of fractional exhaled nitric oxide (FeNO) as a promising marker for the diagnosis and clinical improvement of CTVA.

CASE REPORT

A 50-year-old woman was referred to our hospital from a nearby clinic for further examination of severe constricting pain at the right-side dominant anterior chest from three weeks ago. It was the episode that she had never experienced before, and

the episodes of severe constricting pain lasted for a few minutes, which followed by the weak pain of several-hour duration. While she did not have any other complaints, her symptom did not ameliorate by non-steroidal anti-inflammatory drugs. She required maintenance dialysis due to chronic kidney disease from 12 years ago and had medical history of outgrown childhood asthma and allergies to several animals. She was a never smoker, and no significant social or family history was reported.

The physical examinations at the initial admission revealed body temperature of 36.6°C, blood pressure of 144/91 mmHg, pulse of 80 beats per minute and percutaneous oxygen saturation of 98% on room air. The cardiovascular examination was unremarkable. There were no wheezes, rhonchi and other crackles in chest auscultation. No evident pretibial and foot pad edema were seen. The remainder of the physical examinations was normal. Hematological findings showed normal white blood cell count (7400/ μ L) with eosinophilia (1088/ μ L), and mild anemia. Laboratory findings showed elevated levels of blood urea nitrogen (45.1 mg/dL), creatinine (8.16 mg/dL), potassium (5.5 mEq/L), and N-terminal pro-brain natriuretic peptide (1560 pg/mL) due to chronic renal failure. Serum levels of creatine kinase, creatine kinase-MB, and C-reactive protein were normal. An elevated level of serum total immunoglobulin E (IgE) was observed (779.0 U/mL). Serum antigen-specific IgEs were not measured. The remainder of laboratory test results is shown in Table 1. The results of an electrocardiogram, a chest X-ray and a chest

Abbreviations

CTVA, chest tightness variant asthma ; FeNO, fractional exhaled nitric oxide ; IgE, immunoglobulin E ; ppb, parts per billion ; %PEF, percent predicted peak expiratory flow ; % \dot{V} 50, percent predicted \dot{V} 50 ; % \dot{V} 25, percent predicted \dot{V} 25 ; FEV1, forced expiratory volume in 1 second ; FVC, forced vital capacity ; %VC, percent predicted vital capacity ; ICS, inhaled corticosteroid ; LABA, long acting β_2 agonist ; CVA, cough variant asthma

Received for publication May 6, 2021 ; accepted July 3, 2021.

Address correspondence and reprint requests to Masaki Hanibuchi, Department of Respiratory Medicine, Shikoku Central Hospital of the Mutual Aid Association of Public School teachers, 2233 Kawano-cho, Shikoku-Chuo, 799-0193, Japan and Fax : +81-896-58-3464.

Table 1. Laboratory data at the first admission

Hematology		Biochemistry		Pulmonary function test	
WBC	7,400 / μ L	AST	9 IU/L	VC	2.71 L
Neu	48.8 %	ALT	9 IU/L	%VC	100.7 %
Lymph	28.4 %	ALP	81 U/L	FVC	2.76 L
Mono	7.7 %	LDH	134 IU/L	%FVC	107.8 %
Eos	14.7 %	γ -GTP	15 U/L	FEV1	2.14 L
Baso	0.4 %	CK	261 U/L	FEV1/FVC	77.54 %
RBC	337×10^4 / μ L	CK-MB	9 IU/L	%FEV1	98.6 %
Hb	10.9 g/dL	T-bil	0.4 mg/dL	PEF	5.61 L
Ht	33.2 %	TP	7.5 g/dL	%PEF	75.0 %
Plt	21.1×10^4 / μ L	Alb	3.9 g/dL	$\dot{V}50$	2.34 L
		T-cho	153 mg/dL	% $\dot{V}50$	70.1 %
		Amy	137 IU/L	$\dot{V}25$	0.57 L
		BUN	45.1 mg/dL	% $\dot{V}25$	42.2 %
		Cre	8.16 mg/dL	FeNO	106 ppb
		Na	140 mEq/L		
		K	5.5 mEq/L		
		Cl	102 mEq/L		
		CRP	0.26 mg/dL		
		IgE	779 U/mL		
		NT-proBNP	1560 pg/mL		

IgE, immunoglobulin E; NT-proBNP, N-terminal pro-brain natriuretic peptide; VC, vital capacity; %VC, percent predicted vital capacity; FVC, forced vital capacity; %FVC, percent predicted forced vital capacity; FEV1, forced expiratory volume in 1 second; %FEV1, percent predicted forced expiratory volume in 1 second; PEF, peak expiratory flow; %PEF, percent predicted peak expiratory flow; % $\dot{V}50$, percent predicted $\dot{V}50$; % $\dot{V}25$, percent predicted $\dot{V}25$; FeNO, fractional exhaled nitric oxide; ppb, parts per billion

CT were unremarkable. A value of FeNO remarkably elevated at 106 parts per billion (ppb). In a pulmonary function test, values of percent predicted peak expiratory flow (%PEF), percent predicted $\dot{V}50$ (% $\dot{V}50$), and percent predicted $\dot{V}25$ (% $\dot{V}25$) slightly decreased, while those of forced expiratory volume in 1 second (FEV1), forced vital capacity (FVC), FEV1/FVC, and percent predicted vital capacity (%VC) were normal. Airway reversibility test was not performed following the patient's wishes. Her chest pain was ameliorated after inhaling procaterol.

Based on these findings, a diagnosis of CTVA was formulated, and we started treatment with inhaled corticosteroid (ICS)/long acting β_2 agonist (LABA) at the initial visit. At two-weeks after the treatment initiation, her symptom markedly improved and a FeNO value decreased at 25 ppb. By the confirmation of remarkable clinical improvement in response to ICS/LABA, a definitive diagnosis of CTVA was made. She continues treatment with ICS/LABA even now and chest pain has completely disappeared. At 10-months after the treatment initiation, a FeNO value further decreased at 7 ppb (Fig. 1).

DISCUSSION

Asthma is a chronic inflammatory respiratory disease that is commonly characterized by inflammation, hyperresponsiveness, and reversible obstruction in the airway. By definition, all asthmatics share common physiologic airway abnormalities. Despite these shared features, the great heterogeneity in the severity of airflow limitation and symptoms has been recognized (1). Although the typical symptoms of recurrent episodes of wheezes, dyspnea, chest tightness, and cough, occur simultaneously (4), asthma may be manifested in various clinical phenotypes (2).

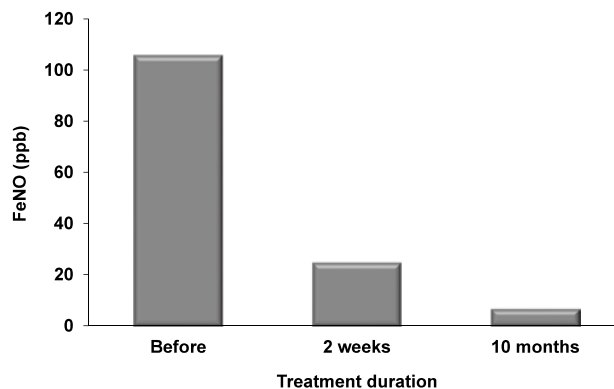


Figure 1. Comparison of FeNO values before and after treatment for CTVA.

FeNO values remarkably decreased at two weeks and 10 months after the treatment initiation compared with that at the initial admission. FeNO values were measured by NIOX VERO[®] electrochemical analyzer (Aerocrine AB, Solna, Sweden) at a flow rate of 50 mL/seconds and were expressed as ppb.

An atypical patient with asthma who presented solely with chest tightness was firstly reported by Farr *et al.* (5), and this phenotype was called as chest pain variant asthma (6, 7). However, this is not generally appreciated, perhaps because these works were published 30-40 years ago. In 2013, Shen *et al.* reported 24 patients with asthma whose sole presenting clinical manifestation was chest tightness and referred to this type of asthma as CTVA (3). As is the case in patients with classic asthma or cough variant asthma (CVA) (8, 9), patients with CTVA also presented

with eosinophilic airway inflammation. Recently, Yan *et al.* advocated the definition of CTVA. According to their criteria, the diagnosis of CTVA is made based on the chest pain or tightness being the sole symptom and at least one of the following conditions was met : 1) an increase of >12% and >200 mL in FEV1 after inhaling short acting β_2 agonist ; 2) airway hyperresponsiveness as evidenced by a positive finding of bronchial provocation test ; 3) a weekly variability in diurnal PEF of greater than 10% ; and 4) a marked clinical improvement in response to β_2 agonists, with or without ICS (10). The present case also revealed chest pain as the sole symptom and had medical history of outgrown childhood asthma and allergies to several animals with peripheral blood eosinophilia. Her chest pain was ameliorated after inhaling procaterol and had completely disappeared in response to the treatment with ICS/LABA. Taken together these findings, we made a definitive diagnosis of CTVA.

The clinical phenotypes of asthma are known to be remarkably different among patients, and it is not unusual in asthmatics for one or more of main symptoms to be absent. Thus, asthma with atypical clinical features such as chest pain and tightness, may be misdiagnosed as conditions such as chronic bronchitis, cardiovascular diseases and mental disorders (11). Edmondstone investigated the frequency and characteristics of chest pain in patients admitted with acute exacerbation of asthma and found that chest pain occurred in 76%. These observations suggested that chest pain is a common symptom in acute severe asthma (12). As the significance of asthmatic chest pain has a tendency to be neglected in adults, it is worthwhile reminding physicians that chest pain and tightness may be related to asthma rather than cardiovascular diseases. CTVA is considered as a rare disease, and there are few case reports in Japan (Table 2) (13-17). But the morbidity of CTVA has possibility to be underestimated for abovementioned reasons. For the adequate treatment and symptom relief of CTVA patients, the accurate diagnosis of the etiology of chest pain and tightness is an important clinical concern.

FeNO could be an airway eosinophilic biomarker for the assessment and management of asthma (18, 19). We also demonstrated that FeNO levels were higher in CVA and classic asthma than those in healthy controls and that FeNO were identified as an independent factor to discriminate CVA and non-CVA (20). Recently, Yan *et al.* evaluated the therapeutic response to standard asthma treatments among 76 patients with CTVA in a 52-week multicenter, prospective study (10). There were no significant improvements in FeNO after 52 weeks compared

with the baseline level, while chest tightness was significantly ameliorated among most patients with CTVA after treatment. However, subgroup analysis revealed that FeNO at the first administration in the responsive group was markedly higher than that in the non-responsive group, indicating that the disease severity of CTVA was associated with FeNO values. In the present case, a FeNO value remarkably elevated at the initial visit (106 ppb), contrary to modest abnormalities in pulmonary function test. At 10-months after treatment with ICS/LABA, a FeNO value drastically decreased to the normal range (7 ppb) in consistent with symptom disappearance. To the best of our knowledge, this is the first report that FeNO might be one of promising candidates as a marker for the diagnosis and clinical improvement of CTVA.

In acute exacerbation of asthma, the mechanisms of chest pain are estimated as follows : The chest hyperinflates during severe asthma and ventilation occurs at lung volumes approaching total lung capacity. This increases the work of breathing as the respiratory muscles are required to operate at a mechanical disadvantage, resulting in muscle fatigue and consequent pain (12). Farr *et al.* attributed the causation of chest tightness in CTVA patients to the remarkable air trapping and enlarged lungs by the severely and marginally obstruction of large and small airways, respectively (5). However, the pathogenesis of chest pain and tightness in CTVA patients remains unclear. Since sufficient data are yet to be collected to clarify whether CTVA can be defined as an independent clinical phenotype regarding the prevalence, risk factors, course of disease, clinical features, management, and prognosis, further studies are warranted to establish the accurate disease concept of CTVA.

In conclusion, we herein reported a case of CTVA who had chest pain as the sole symptom. A remarkable improvement of symptom in response to the treatment with ICS/LABA led to a definitive diagnosis of CTVA. While a FeNO value remarkably elevated at the initial visit, it drastically decreased after treatment in consistent with the symptom relief, suggesting that FeNO might be a promising marker for the diagnosis and clinical improvement of CTVA.

CONFLICT OF INTEREST DISCLOSURE

All authors state that they do not have any financial or other relationships for the present study that might lead to a conflict of interest.

Table 2. Case reports of chest tightness variant asthma in Japan.

Ref. No.	First author	Age	Gender	Diagnosis	Symptom	Wheezes	History of asthma	Inhalation of bronchodilator
13	Kashiwagi H	51	M	Effect of asthma drugs, diagnosis of asthma	Chest pain, cough, dyspnea	-	+	Effective
14	Sano Y	37	M	Effect of asthma drugs, methacholine test positive	Chest pain	-	+	Effective
15	Suko M	24	M	Effect of bronchodilator, acetylcholine test positive	Chest pain, cough, dyspnea, headache	-	-	Effective
16	Taniguchi H	45	F	Effect of LTRA	Chest pain	-	+	-
17	Taniguchi H	37	M	Effect of bronchodilator	Chest pain, headache	-	-	Effective
Present Case	Hanibuchi M	50	F	Effect of ICS/LABA, elevation of FeNO value	Chest pain	-	+	Effective

LTRA, leukotriene receptor antagonist ; ICS/LABA, inhaled corticosteroid/long acting β_2 agonist ; FeNO, fractional exhaled nitric oxide

ACKNOWLEDGEMENTS

We thank our colleagues at Shikoku Central Hospital of the Mutual aid Association of Public School teachers, especially Hitomi Komoda for technical assistance.

REFERENCES

- Bhakta NR, Woodruff PG : Human asthma phenotypes : from the clinic, to cytokines, and back again. *Immunol Rev* 242 : 220-232, 2011
- Irwin RS : Chest tightness variant asthma (CTVA) : reconfirmed and not generally appreciated. *J Thorac Dis* 6 : 405-406, 2014
- Shen H, Hua W, Wang P, Li W : A new phenotype of asthma : chest tightness as the sole presenting manifestation. *Ann Allergy Asthma Immunol* 111 : 226-227, 2013
- The Global Strategy for Asthma Management and Prevention, Global Initiative for Asthma (GINA) 2012. Available online : <https://www.ginasthma.org/>
- Farr RS, Kopetzky MT, Spector SL, Hurewitz DS : Asthma without wheezing. *Chest* 63 (Suppl) : 64S-68S, 1973
- Myers JR, Corrao WM, Braman SS : Clinical applicability of a methacholine inhalational challenge. *JAMA* 246 : 225-229, 1981
- Whitney EJ, Row JM, Boswell RN : Chest pain variant asthma. *Ann Emerg Med* 12 : 572-575, 1983
- Cao C, Li W, Hua W, Yan F, Zhang H, Huang H, Ying Y, Li N, Lan F, Wang S, Chen X, Li J, Liu J, Lai T, Bao Z, Cao Y, Zhao Y, Huang G, Huang L, Huang Y, Wu P, Peng C, Chen Z, Chung KF, Zhong N, Ying S, Shen H : Proteomic analysis of sputum reveals novel biomarkers for various presentations of asthma. *J Transl Med* 15 : 171, 2017
- Sinha A, Sterk PJ : Proteomics in asthma : the clinician-swore right after all, were not they? *Clin Transl Med* 6 : 39, 2017
- Yan F, Li W, Guan W, Chen M, Qiu C, Tang W, Liu X, Xiang X, Li J, Jin M, Dai Y, Chen P, Wu X, Qiu Z, Dong L, Zhao L, Lin X, Wu C, Wu B, Yuan Y, Shi F, Zhang T, Zhou J, Xie M, Fang X, Zhang H, Xiao B, Xian M, Wang J, Qiu Z, Lin J, Ji B, Zhou Y, Li Y, Liu C, Chen Y, Zeng Y, Liu L, Hua W, Huang H, Zhou J, Hu Y, Che L, Ying S, Chen Z, Zhong N, Shen H : Response of patients with chest tightness variant asthma with routine asthma treatment regimen : A 1-year multicenter, prospective, real-world study. *Clin Transl Med* 10 : e178, 2020
- Zhong N : Chest tightness variant asthma : deja vu all over again. *J Thorac Dis* 6 : 407-408, 2014
- Edmondstone WM : Chest pain and non-respiratory symptoms in acute asthma. *Postgrad Med J* 76 : 413-414, 2000
- Kashiwagi H, Ibe T, Takahashi Y, Teramura S, Yamaguchi M, Hamaguchi Y : A case of chest pain variant asthma (pectoralgia heteromorphic asthma) to be differentiated angina pectoris. *Allergy in Practice* 154 : 828-831, 1992
- Sano Y, Koshino K : Chest pain variant asthma. *Nippon Rinsho* 345-348, 1994
- Suko M, Ito K : A case of chest pain variant asthma. *Allergy Immunol* 1 : 72-75, 1994
- Taniguchi H, Inomata M, Ichikawa T, Abo H, Izumi S : A case of chest pain variant asthma. *Nihon Kokyuki Gakkai Zasshi* 45 : 866-868, 2007
- Taniguchi H, Kanbara K, Imanishi S, Abo H, Izumi S : A case of chest pain variant asthma with headache. *Nihon Kokyuki Gakkai Zasshi* 46 : 216-219, 2008
- Matsunaga K, Hirano T, Akamatsu K, Koarai A, Sugiura H, Minakata Y, Ichinose M : Exhaled nitric oxide cutoff values for asthma diagnosis according to rhinitis and smoking status in Japanese subjects. *Allergol Int* 60 : 331-337, 2011
- Rupani H, Chauhan AJ : Measurement of FeNO in asthma : what the hospital doctor needs to know. *Br J Hosp Med* 80 : 99-104, 2019
- Hanibuchi M, Saijo A, Mitsuhashi A, Takeji T, Kitagawa T : The clinical usefulness of a new hand-held device for fractional exhaled nitric oxide measurement, NIOX VERO®, for diagnosing the etiology of cough. *J Med Invest* 67 : 265-270, 2020