

## CASE REPORT

# Primary pyomyositis in an infant following one-day afebrile upper limb monoplegia

Yusuke Takezawa, Soh Niitsuma, Sayaka Kawashima, Shunsuke Miyano, and Takashi Honma

Department of Pediatrics, Ishinomaki Red Cross Hospital, Ishinomaki, Miyagi, Japan

**Abstract :** Background : Pyomyositis is a subacute bacterial infection of the skeletal muscles. Its most common features are fever, muscle swelling, and focal pain. There have been insufficient data regarding pyomyositis in healthy infants. Case report : A one-month-old boy presented with an impairment of his left arm movement. He was well-nourished and not under any apparent distress. His vital signs were within the normal limits but neurological examination revealed left forearm paralysis. Physical examination showed no abnormal findings in the region from the left shoulder joint to the fingertips. Considering these factors, an intracranial pathology was initially suspected. However, he developed a fever, regular tachycardia, and swelling in the left forearm. Magnetic resonance imaging revealed inflammation in the left forearm muscles. He was diagnosed with bacterial myositis and started on intravenous antibiotics. On the 17th day, he was discharged with oral antibiotic treatment, which was completed over 25 days without any sequelae nor relapse. Conclusion : Here we report the case of Japanese primary pyomyositis following one-day afebrile upper limb monoplegia in an infant. Even when infants exhibit afebrile symptoms, a bacterial infection should be suspected. *J. Med. Invest.* 68 : 372-375, August, 2021

**Keywords :** bacteremia, immunocompetence, paralysis, soft tissue infection, *Staphylococcus aureus*

## INTRODUCTION

Pyomyositis is a subacute bacterial infection of the skeletal muscles ; it had been originally reported as tropical pyomyositis in tropical areas (1). It commonly afflicts immunocompromised or elderly people in temperate climate areas, whereas healthy children and young adults have reportedly been afflicted in areas with a tropical climate (2, 3). Pyomyositis is mostly caused by *Staphylococcus aureus*, and typical pyomyositis symptoms include fever, muscle swelling, and focal pain (2). To date, many case reports on pyomyositis have been published ; however, there are insufficient data on cases of pyomyositis in children, especially healthy infants. Here we report the case of a one-month-old baby with left forearm pyomyositis following one-day afebrile upper limb monoplegia of the left upper limb.

## CASE REPORT

A 1-month-old boy presented to the emergency department with his mother complaining of no movement in his left arm. Otherwise, the patient was apparently healthy and even-tempered, and his physical examination findings were normal. He was re-examined in the pediatric department the next day of the first visit. He was the third child born to a healthy, non-consanguineous Japanese couple. He had neither remarkable history of injury, severe infection, nor perinatal event. His general examination findings were as follows : temperature, 36.8°C ; pulse rate, 140/min ; respiratory rate, 30/min ; and saturation of peripheral oxygen, 99% (room air). His body weight was 4.6 kg ; he appeared well-nourished, and was not under any

apparent distress. Neurological examination revealed a movement impairment of his left arm, with only slight movement observed on eliciting Moro or grasp reflex. Physical inspection and palpation of the left arm showed no apparent findings in the region from the shoulder joint to the fingertips and caused no apparent irritability or cry. His left arm radiographs revealed no abnormality. Blood test results showed a total white blood cell count of 19,200/ $\mu$ l and slightly increased C-reactive protein levels (1.2 mg/dl). Venous blood gas analysis, blood electrolyte levels, and renal function test parameters were within the normal limits. He was admitted to the hospital for monitoring and further examination. An intracranial pathology, including cerebral hemorrhage, was suspected at the time of admission despite the absence of hyperreflexia since no other apparent etiology could be identified based on his clinical presentations. However, almost 24 hours after the onset of symptoms, he developed regular tachycardia (up to 190 beats/min) and swelling in the left forearm. Magnetic resonance imaging (MRI) for the left forearm was performed to verify a possible local infection such as osteomyelitis. MRI findings revealed inflammation in the left forearm muscles (Fig. 1-A, B). Intravenous administration of ampicillin/sulbactam (150 mg/kg/day q6h) and clindamycin (40 mg/kg/day q12h) was initiated. After initiating antibiotic treatment, the patient's body temperature increased to 39°C but he became afebrile within 3 days. His blood culture was positive for methicillin-susceptible *S. aureus*, following which cefazolin (100 mg/kg/day) monotherapy was initiated. Ultrasonography of the left arm on the fifth day of admission showed consolidation and swelling in the left forearm muscles ; these image findings eventually disappeared on the 15th day of admission (Fig. 1-C, D). On the fourth day of admission, he began to move his left arm, and the swelling began to subside between the fourth and eighth days ; both the symptoms were eventually resolved. On the 11th day, the flexion attitude of his elbow and shoulder had disappeared. On the 15th day, the patient's blood test results revealed that the inflammation had completely subsided. On the 17th day, he was discharged with oral cefdinir (18 mg/kg/day) treatment. The antibiotic treatment and his follow-up continued

Received for publication December 7, 2020 ; accepted March 14, 2021.

Address correspondence and reprint requests to Yusuke Takezawa, M.D., Ph.D., Department of Pediatrics, Tohoku University School of Medicine, 2-1 Seiryomachi, Aoba-ku, Sendai, Miyagi 980-8574, Japan and Fax : +81-22-717-7290.

for a period of 24 days without relapse. During the one-week follow-up period after the discharge, the patient had been symptom-free without any sequelae, including his left arm movement. The patient's clinical course is summarized in Fig. 2. Ultrasonography of his spleen revealed no dysplastic abnormalities. His blood cell count and hemogram were normal. Furthermore, his immunoglobulin and complement levels were within the normal

range (IgG, 1683 mg/dl; IgA, 84 mg/dl; IgM, 159 mg/dl; IgG4, 27 mg/dl; CH50, 24.2/ml; C3, 116 mg/dl; and C4, 16 mg/dl). Subsequent immunological examination was not performed as the patient responded well to the treatment and there was no abscess formation or requirement of surgery. Informed consent was obtained from the parents.

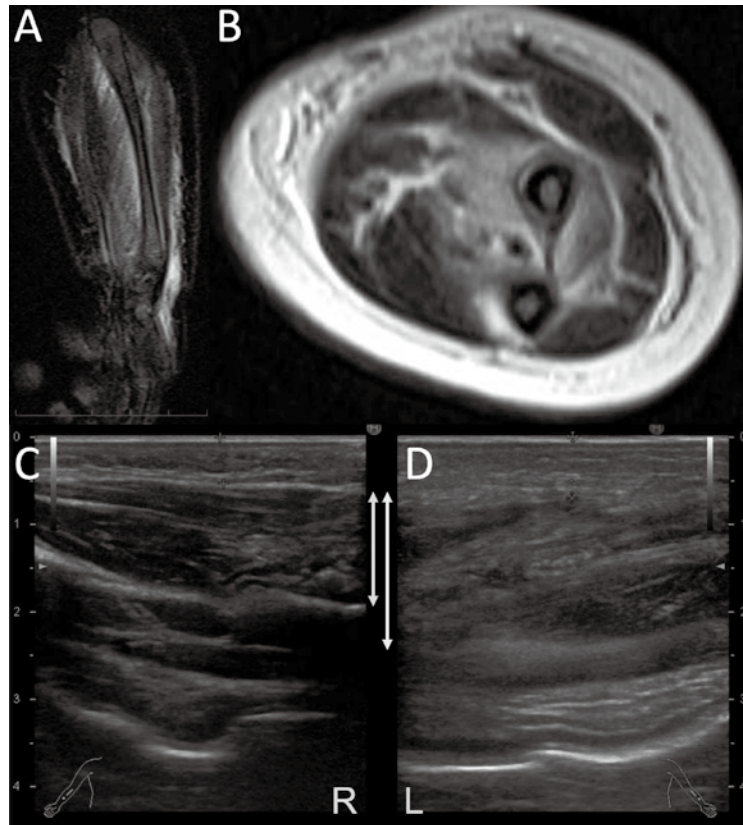


Fig 1. Magnetic resonance imaging (MRI) and ultrasonography (US) images of the patient's left forearm. (A) Contrast-enhanced MRI of the left forearm using T1-weighted sagittal imaging. (B) Contrast-enhanced MRI of the left forearm using T2-weighted coronal imaging. (C, D) US imaging of the right (C) and left (D) forearm

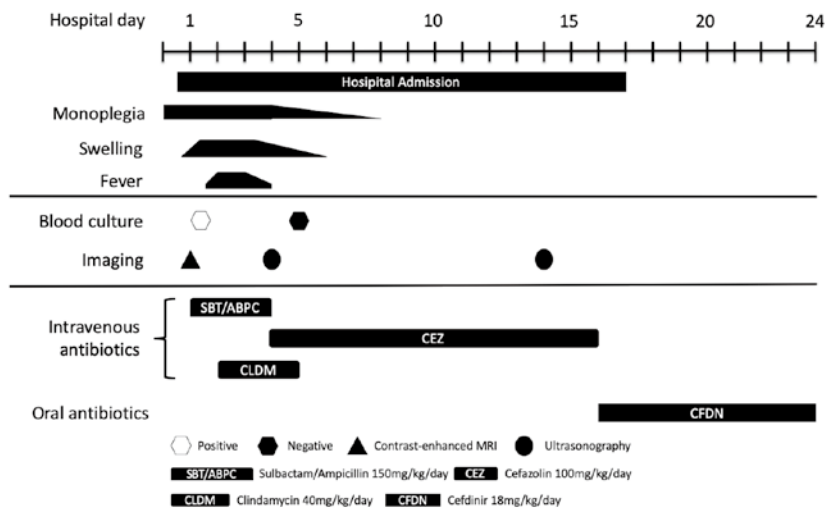


Fig 2. Clinical course of the patient

## DISCUSSION

This study reported the first case of Japanese primary pyomyositis in infancy following one-day afebrile upper limb monoplegia. The patient's left arm function seemed to be completely restored without any surgical intervention; however, symptoms were atypical, and nearly 24 h were required to make a diagnosis.

Although some reports on pyomyositis cases have been published, cases in infants have not yet been reported in Japan. A comparison of the reported pediatric primary pyomyositis cases (including cases in infants) is presented in Table 1 (4-7). Considering these references, this disease tends to affect the truncal or lower limb muscles, and the most common symptoms include fever, muscle pain, swelling, and a feeling of warmth. In addition, infant cases of pyomyositis are rare. Therefore, our case was relatively unusual in terms of the patient's age, site involved,

and symptoms. In fact, a few infant cases have reported to show the impairment of muscle movements, but these cases simultaneously showed other symptoms including fever, pain, or swelling (8, 9). Our patient exhibited the impairment of the left arm movement without any other symptoms for almost 24 hours from onset. When infants have bacterial infections, they occasionally show afebrile symptoms (e.g., lethargy or irritability) (10). In the present case, the patient had the impairment of left arm movement without not only fever or local findings but also lethargy or irritability, which made the diagnosis tricky. Also, he did not show any preceding history or trauma; therefore, it was difficult to determine whether the left arm muscle was the primary cause of concern or was it a sequela of infections such as septicemia. In terms of the cause of monoplegia, it was undetermined whether the secondary peripheral motor nerve paralysis due to inflammation or myositis itself caused muscular dysfunction because a neurophysiological examination was not performed.

Table 1. Comparison of the clinical features of pediatric patients with primary pyomyositis

Citation	Present case	Emmanuel (1999)	Pia <i>et al.</i> (2006)	Chiu <i>et al.</i> (2009)	Unnikrishnan <i>et al.</i> (2010)
Country	Japan	Nigeria	US	Taiwan	UK
No. of patients	1	31	45	24	13
Male, n (%)	1 (-)	15 (48)	31 (69)	13 (54)	7 (54)
Age, range (year)	0.1	0-15	0.1-15	0.1-15	4-15
Symptoms					
Fever	+ (delayed)	10	42	20	13
Swelling	+ (delayed)	31	26	8	N/D
Local pain	+ (delayed)	31	45	5	N/D
Paralysis	+	-	-	-	N/D
Pathogens					
MSSA	+	16*	10	10	10
MRSA	-	-	16	4	-
Other GPC	-	2*	1	3	1
GNRs	-	-	-	2	-
GNC	-	-	-	1	-
Unknown	-	15	18	4	2
Site <sup>§</sup>					
Upper limbs	+	4	1	2	-
Lower limbs	-	18	24	14	4
Truncus	-	9	8	7	2
Buttock	-	0	13	2	7
Others	-	4	3	-	-
Therapy duration	24 days	N/D	N/D	2-7 weeks	3-6 weeks
Days before present	1	2-12	N/D	N/D	3-21
Comorbidity	None	1	0 <sup>†</sup>	1	5

MSSA, methicillin-sensitive *Staphylococcus aureus*; MRSA, methicillin-resistant *Staphylococcus aureus*; GPC, gram-positive cocci; GNRs, gram-negative rods; GNC, gram-negative cocci; +, present; -, absent; N/D, no data; <sup>§</sup>, including multifocal site; \*, including multi-pathogen; <sup>†</sup>, excluded with this study

## CONCLUSION

Here we report the case of Japanese primary pyomyositis following one-day afebrile upper limb monoplegia in an infant. When infants exhibit afebrile symptoms without any causative history, bacterial infection should be suspected.

## CONFLICT OF INTERESTS

The authors declare no conflict of interest.

## ACKNOWLEDGEMENTS

The authors would like to thank the patient and his family and the medical staff who participated in the patient's care. The authors declare no conflict of interest. Also, no funding was received that could influence this article.

## REFERENCES

- Berger S : Infectious Diseases of the World-2019 edition. Gideon Informatics, Incorporated, Los Angels, 2019
- Chiedozi LC : Pyomyositis. Review of 205 cases in 112 patients. *Am J Surg* 137 : 255-259, 1979
- Falagas ME, Rafailidis PI, Kapaskelis A, Peppas G : Pyomyositis associated with hematological malignancy : case report and review of the literature. *Int J Infect Dis* 12 : 120-125, 2008
- Ameh EA : Pyomyositis in children : analysis of 31 cases. *Ann Trop Paediatr* 19 : 263-265, 1999
- Pannaraj PS, Hulten KG, Gonzalez BE, Mason EO, Jr., Kaplan SL : Infective pyomyositis and myositis in children in the era of community-acquired, methicillin-resistant *Staphylococcus aureus* infection. *Clin Infect Dis* 43 : 953-960, 2006
- Chiu NC, Hsieh MC, Chi H, Huang FY : Clinical characteristics of pyomyositis in children : 20-year experience in a medical center in Taiwan. *J Microbiol Immunol Infect* 42 : 494-499, 2009
- Unnikrishnan PN, Perry DC, George H, Bassi R, Bruce CE : Tropical primary pyomyositis in children of the UK : an emerging medical challenge. *Int Orthop* 34 : 109-113, 2010
- Maddox JL, Jr., Riordan TP, Odom RB : Pyomyositis in a neonate. *J Am Acad Dermatol* 10 : 391-394, 1984
- O Falesi M, Regazzoni BM, Wyttenbach M, Wyttenbach R, Bianchetti MG, Riavis M : Primary pelvic pyomyositis in a neonate. *J Perinatol* 29 : 830-831, 2009
- Overturf GD, Balfour G : Osteomyelitis and sepsis : severe complications of fetal monitoring. *Pediatrics* 55 : 244-247, 1975