

Rowan University

Rowan Digital Works

Stratford Campus Research Day

25th Annual Research Day

May 6th, 12:00 AM


Use of Point of Care Ultrasound in the Emergency Department for Diagnosis of Femoral Pseudoaneurysm

Stephen Janssen
Rowan University

Jeffrey Gardecki
Rowan University

Giovanna Finocchio
Jefferson Health NJ

Follow this and additional works at: https://rdw.rowan.edu/stratford_research_day

 Part of the [Cardiovascular Diseases Commons](#), [Diagnosis Commons](#), [Emergency Medicine Commons](#), and the [Equipment and Supplies Commons](#)

Let us know how access to this document benefits you - share your thoughts on our [feedback form](#).

Janssen, Stephen; Gardecki, Jeffrey; and Finocchio, Giovanna, "Use of Point of Care Ultrasound in the Emergency Department for Diagnosis of Femoral Pseudoaneurysm" (2021). *Stratford Campus Research Day*. 85.

https://rdw.rowan.edu/stratford_research_day/2021/may6/85

This Poster is brought to you for free and open access by the Conferences, Events, and Symposia at Rowan Digital Works. It has been accepted for inclusion in Stratford Campus Research Day by an authorized administrator of Rowan Digital Works.

Stephen Janssen, DO, PGY3*, Jeffery Gardecki, DO**, Giovanna Finnochio, DO**

*Rowan University School of Osteopathic Medicine, Stratford, NJ **Jefferson Health NJ, Cherry Hill, NJ

INTRODUCTION

Iatrogenic Pseudoaneurysm after puncture or intervention of the femoral artery is a rare complication of arterial surgical intervention occurring in 0.05-0.50% of diagnostic and therapeutic catheterizations and can present weeks after initial presentation (4). Today we present a 57-year-old gentleman 3 months status post femoral artery stent who presented with swelling to his right groin. Point of care ultrasound was used to diagnose an actively bleeding pseudoaneurysm with hematoma who ultimately went for repeat stenting. This case shows how point of care ultrasound can expedite diagnosis and intervention and is a useful tool for the emergency physician at initial presentation.

BACKGROUND

An aneurysm occurs when there is a pathologic dilatation of the arterial vessel wall that contains all three layers (the intima, media and adventitia), whereas a pseudoaneurysm is a dilatation of the arterial wall, but it does not contain all three layers.

Pseudoaneurysm development after arterial puncture is a rare but known complication of interventional and diagnostic arterial access. Pseudoaneurysm development occurs due to inadequate hemostasis after arterial wall injury leading to the development of a pseudocapsule. When a patient is unable to develop a hemostatic plug, hematoma forms, after which a pseudocapsule is developed to limit further extravasation.

Commonly pseudoaneurysm is due to traumatic injury but can also be secondary to iatrogenic injury from interventional access (8). Patients at risk for pseudoaneurysm development include those with deficits in clotting factors, thrombocytopenia, anticoagulation, surgery and increased sheath size (4). The femoral artery is the most common site of access for interventional and diagnostic catheterization procedures, thus making it also the most common site of iatrogenic pseudoaneurysm formation, with an incidence of 0.05-0.50% of all cases. Presentation varies, but commonly patients with femoral artery pseudoaneurysm formation will present with pain and swelling to the groin. Examination may show pulsatile mass, thrill or bruit to the groin. Diagnosis is typically made via CT angiogram or formal arterial ultrasound. Point of care ultrasonography can be used by the emergency medicine physician to rapidly diagnose pseudoaneurysm and expedite definitive management.

CASE REPORT

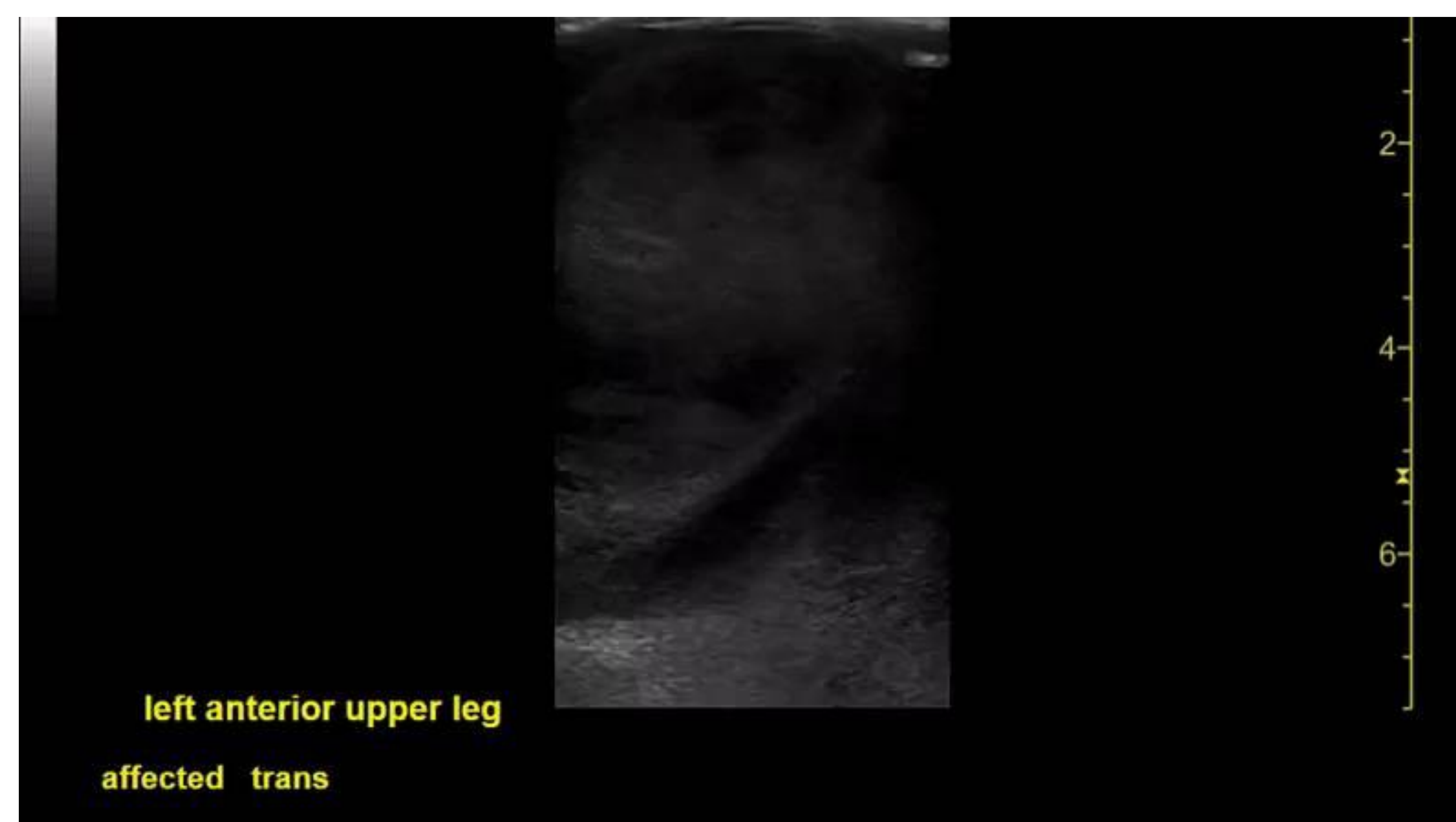
A 57 year old man with multiple comorbidities presented to the emergency department with difficulty ambulating. Patient was known to have a left superficial femoral artery stent placed 2 months prior at our facility. Patient began to have progressive swelling and bruising to his left groin over two weeks with increasing pain and difficulty ambulating. At time of presentation the patient denied trauma to the area, numbness, weakness or paresthesias to the lower extremity. Review of systems revealed no chest pain, shortness of breath, headache, dizziness, or abdominal pain or vision changes.

Past medical history included coronary artery disease, end stage renal disease on hemodialysis, autosomal dominant polycystic kidney disease, atrial fibrillation for which he takes Eliquis, schizophrenia, anemia, hyperlipidemia and colon cancer. The patient's surgical history was significant for a prior superficial femoral artery stent placement in 3 months prior.

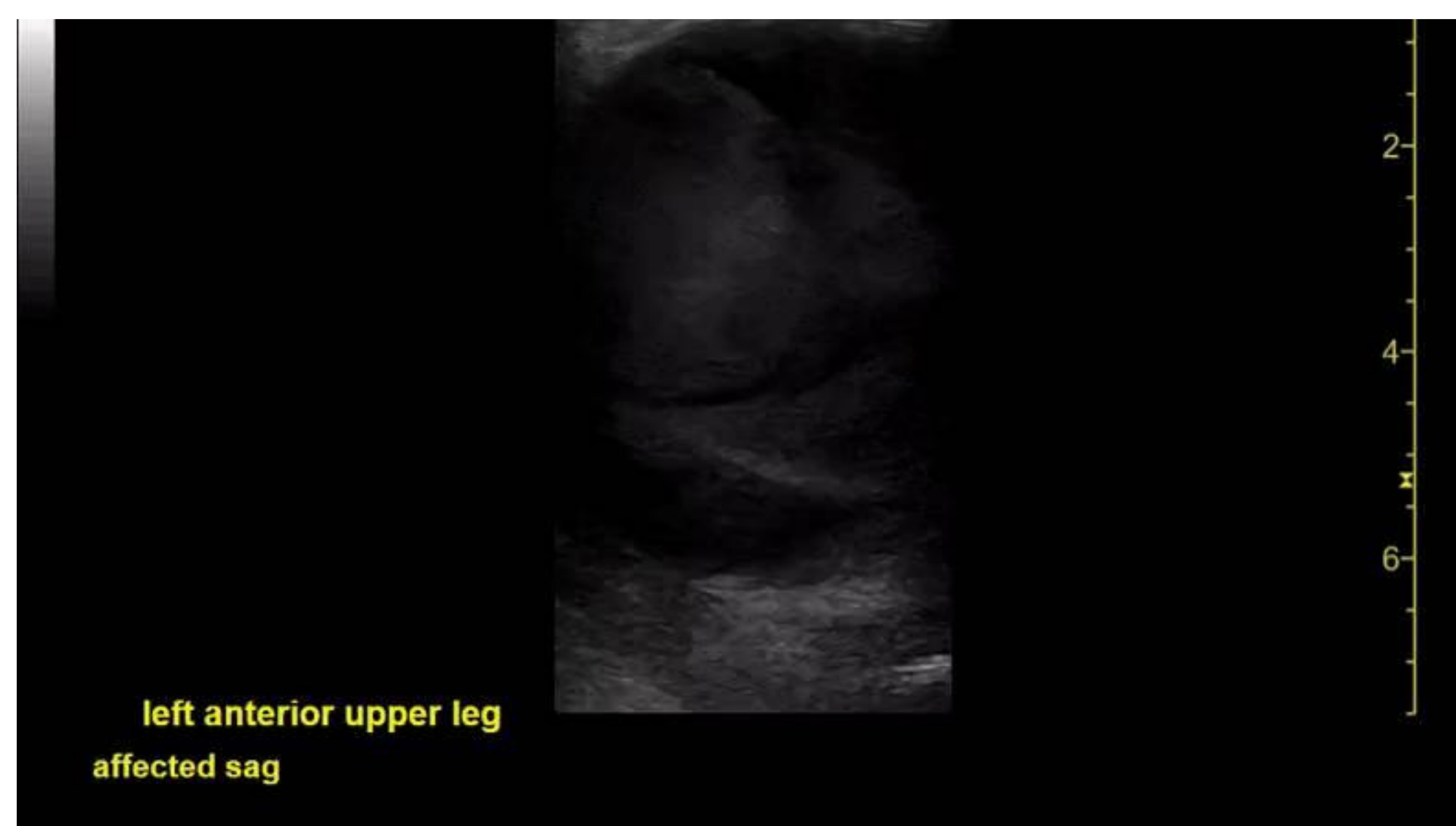On arrival the patient's vitals were blood pressure of 87/53, temperature of 99.4 degrees Fahrenheit, heart rate of 117, respiratory rate of 17 with a SPO2 of 96% on room air. Initial examination revealed a pale and chronically ill male who was acutely alert. Heart S1S2 with a regular rhythm. Lungs were clear bilaterally. Abdomen was soft, nontender and non peritoneal. Examination of the left groin and lower extremity revealed a large approximately 10-centimeter mass to the left groin with mild erythema that was nontender and non pulsatile, no bruit or thrill was appreciated at initial examination. Distally the left lower extremity was neurologically intact with palpable dorsalis pedis and medial tibialis pulses.

In the ED point of care ultrasound was performed using the linear 5-10 megahertz linear transducer. The probe was placed over the groin mass in linear and transverse orientation over the area of maximal fluctuance. Imaging revealed a large echogenic fluid filled structure about 0.5 centimeters deep extending to about 5 cm deep. The fluid appeared to be swirling around the cavity (figures 1 and 2). This swirling echogenic fluid can be seen with active arterial extravasation and raised suspicion for an actively hemorrhaging pseudoaneurysm.

Laboratory analysis was significant for a hemoglobin of 6.5, for which the patient was given 1 unit of packed red blood cells, platelet count of 115, INR 2.07 and a creatinine of 6.85 (which is the patient's baseline for his known end stage renal disease). Computed tomography angiogram was performed in the emergency department which revealed a large hematoma arising from a femoral artery pseudoaneurysm with active hemorrhage surrounding the patient's previously placed stent measuring 14.6 x 9.4 x 13.1 centimeters. Vascular surgery was consulted and the patient was transferred to another hospital where he underwent proximal left superficial femoral artery stenting. Patient did well postoperatively, but his hospital course was complicated by Serratia bacteremia likely secondary to a mycotic aneurysm. He was treated with antibiotics, started on Plavix and discharged 19 days later.



- Transverse view of left groin on ultrasound demonstrating pseudoaneurysm formation



- Sagittal view of left groin on ultrasound demonstrating pseudoaneurysm formation

DISCUSSION

- Pseudoaneurysm formation post intervention is a rare but dangerous complication and can present to the emergency department with varied presentation. Physical examination alone oftentimes is unable to accurately make the diagnosis. Other pathologies that can present similarly include abscess, post operative infection, hematoma, among others. Oftentimes diagnosis is made via formal arterial ultrasound or computed tomography imaging. The time to obtain these images can delay surgical consultation and increase time to definitive management. The use of point of care ultrasound can be a great tool for the emergency physician to quickly identify signs of pseudoaneurysm to narrow differential and expedite care. These ultrasound findings include a fluid filled structure with layered, variable echogenicity; many times, a pulsatile nature can be appreciated on ultrasound as well which can create what has been termed a "swirl sign" appearance from active hemorrhage. The use of doppler can be used to better see swirling and further help diagnose pseudoaneurysm on ultrasound and has been described further in the literature (1, 2), but as was the case in our patient, is not always needed.

CONCLUSION

Pseudoaneurysm formation can present many diagnostic challenges to the emergency medicine clinician. Oftentimes physical examination alone cannot accurately diagnose this condition. Our case shows how point of care ultrasound can be used as an adjunct to narrow differential diagnosis and expedite expert consultation for appropriate further imaging and intervention. Point of care ultrasound is a fast, noninvasive reliable and cost-effective modality that continues to show its versatility and utility to the emergency medicine clinician.

REFERENCES

1. Rozen G, Samuels DR, Blank A. The to and fro sign: the hallmark of pseudoaneurysm, *Isr Med Assoc J*, 3 (2001), pp. 781-782
2. Mahmoud MZ, Al-Saadi M, Abuderman A, et al. To-and-fro" waveform in the diagnosis of arterial pseudoaneurysms
3. Gupta P, Lyons S, Hedgire S. Ultrasound imaging of the arterial system, *Cardiovasc Diagn Ther*, 9 (suppl 1) (2019), pp. S2-S13
4. Kresowik TF, Khoury MD, Miller BV, et al. A prospective study of the incidence and natural history of femoral vascular complications after percutaneous transluminal coronary angioplasty. *J Vasc Surg*, 13 (1991), pp. 328-333
5. Canter DM, Difranco MA, Landefeld K, et al. Emergency Point-of-Care Ultrasound Diagnosis of a Femoral Artery Pseudoaneurysm, *The Journal of Emergency Medicine*, Volume 60, Issue 1, 2021, Pages 77-79
6. Alerhand S, Cherneykina M, Wei HS, Barricella RL. Point-Of-Care Ultrasound Diagnosis of Medial Plantar Artery Pseudoaneurysm Secondary to Penetrating Injury. *J Emerg Med*. 2020 May;58(5):781-784
7. Montorfano MA, Pla F, Vera L, Cardillo O, Nigra SG, Montorfano LM. Point-of-care Ultrasound and Doppler Ultrasound Evaluation of Vascular Injuries in Penetrating and Blunt Trauma. *Crit Ultrasound J*. 2017 Dec
8. Delf J, Ramachandran S, Mustafa S, Saeed A, Kandiyil N. Factors associated with pseudoaneurysm development and necessity for reintervention: a single centre study. *Br J Radiol*. 2019