



THE AGA KHAN UNIVERSITY

eCommons@AKU

Section of Pulmonary & Critical Care

Department of Medicine

9-28-2021

Persistence of post-COVID lung parenchymal abnormalities during the three-month follow-up

Ali Bin Sarwar Zubairi

Aga Khan University, ali.zubairi@aku.edu

Anjiya Shaikh

Aga Khan University, anjiya.shaikh@scholar.aku.edu

Syed Muhammad Zubair

Aga Khan University, syed.zubair@aku.edu

Akbar Shoukat Ali

Aga Khan University, akbar.shoukatali@aku.edu

Safia Awan

Aga Khan University, safia.awan@aku.edu

See next page for additional authors

Follow this and additional works at: https://ecommons.aku.edu/pakistan_fhs_mc_med_pulm_critcare



Part of the [Critical Care Commons](#), [Pulmonology Commons](#), [Respiratory Tract Diseases Commons](#), and the [Virus Diseases Commons](#)

Recommended Citation

Zubairi, A., Shaikh, A., Zubair, S. M., Ali, A. S., Awan, S., Irfan, M. (2021). Persistence of post-COVID lung parenchymal abnormalities during the three-month follow-up. *Advances in Respiratory Medicine*, 89(5), 477-483.

Available at: https://ecommons.aku.edu/pakistan_fhs_mc_med_pulm_critcare/174

Authors

Ali Bin Sarwar Zubairi, Anjiya Shaikh, Syed Muhammad Zubair, Akbar Shoukat Ali, Safia Awan, and Muhammad Irfan

Ali Bin Sarwar Zubairi¹, Anjiya Shaikh², Syed Muhammad Zubair¹, Akbar Shoukat Ali¹, Safia Awan¹, Muhammad Irfan¹

¹Department of Medicine, Aga Khan University Hospital, Karachi, Pakistan

²Medical College, Aga Khan University, Karachi, Pakistan

Persistence of post-COVID lung parenchymal abnormalities during the three-month follow-up

Abstract

Introduction: COVID-19-associated pulmonary sequelae have been increasingly reported after recovery from acute infection. Therefore, we aim to explore the characteristics of persistent lung parenchymal abnormalities in patients with COVID-19.

Material and methods: An observational study was conducted in patients with post-COVID lung parenchymal abnormalities from April till September 2020. Patients ≥ 18 years of age with COVID-19 who were diagnosed as post-COVID lung parenchymal abnormality based on respiratory symptoms and HRCT chest imaging after the recovery of acute infection. Data was recorded on a structured pro forma, and descriptive analysis was performed using Stata version 12.1.

Results: A total of 30 patients with post-COVID lung parenchymal abnormalities were identified. The mean age of patients was 59.1 (SD 12.6), and 27 (90.0%) were males. Four HRCT patterns of lung parenchymal abnormalities were seen; organizing pneumonia in 10 (33.3%), nonspecific interstitial pneumonitis in 17 (56.7%), usual interstitial pneumonitis in 12 (40.0%) and probable usual interstitial pneumonitis in 14 (46.7%). Diffuse involvement was found in 15 (50.0%) patients, while peripheral predominance in 15 (50.0%), and other significant findings were seen in 8 (26.7%) patients. All individuals were treated with corticosteroids. The case fatality rate was 16.7%. Amongst the survivors, 32.0% recovered completely, 36.0% improved, while 32.0% of the patients had static or progressive disease.

Conclusion: This is the first study from Southeast Asia that identified post-COVID lung parenchymal abnormalities in patients who had no pre-existing lung disease highlighting the importance of timely recognition and treatment of this entity that might lead to fatal outcome.

Key words: COVID-19, SARS-CoV-2, pulmonary sequelae, lung parenchymal abnormalities

Adv Respir Med. 2021; 89: 477–483

Introduction

The coronavirus disease 2019 (COVID-19) caused by the novel coronavirus severe acute respiratory syndrome coronavirus 2 (SARS-CoV-2) has posed a global economic, psychosocial, political and medical challenge. As patients recover from COVID-19 disease, we are approaching an era where physicians would encounter COVID-19-associated pulmonary sequelae. These could be infectious, like COVID-19-associated pulmonary aspergillosis (CAPA) [1]; or noninfectious which could include COVID-19-associated

interstitial lung disease (ILD). The previous epidemics of coronavirus due to severe acute respiratory distress syndrome coronavirus (SARS-CoV) and middle east respiratory syndrome coronavirus (MERS-CoV) also led to the development of pulmonary fibrosis [2, 3].

ILD covers a wide spectrum of pulmonary parenchymal disorders of both known and unknown etiology. Different radiological and histopathologic patterns of ILD have been described, some of them include usual interstitial pneumonitis (UIP), nonspecific interstitial pneumonitis (NSIP), and organizing pneumonia (OP) [4]. Similar patterns

Address for correspondence: Ali Bin Sarwar Zubairi, Section of Adult Infectious Diseases, Department of Medicine, Aga Khan University, Karachi, Pakistan; e-mail: ali.zubairi@aku.edu

DOI: 10.5603/ARM.a2021.0090 | Received: 08.03.2021 | Copyright © 2021 PTChP | ISSN 2451–4934 | e-ISSN 2543–6031

This article is available in open access under Creative Commons Attribution-Non-Commercial-No Derivatives 4.0 International (CC BY-NC-ND 4.0) license, allowing to download articles and share them with others as long as they credit the authors and the publisher, but without permission to change them in any way or use them commercially.

can also occur as a result of pulmonary infections, like pneumocystis pneumonia or cytomegalovirus pneumonitis [5, 6].

The precise diagnosis of lung parenchymal abnormalities during COVID-19 pandemic remains challenging, mainly because invasive testing like bronchoscopies, open lung biopsies or autopsies are rarely performed in COVID-19 patients due to risk of disease transmission. Although there are multiple reports on the importance of CT in diagnosing COVID-19 infection, there is little or no data on the clinical presentation and management of patients with post-COVID lung parenchymal abnormalities. Myall *et al.* described the cohort of patients with persistent inflammatory interstitial lung disease with remarkable improvement on early initiation of steroids [7]. The rationale of the study was that certain patients after recovery from COVID-19 infection might present with new, persistent or worsening respiratory symptoms due to long-term COVID-19-associated pulmonary sequelae which are usually underdiagnosed. Hence via this study, we aim to emphasize that diagnosing post-COVID lung parenchymal abnormalities with proper follow-up is of utmost importance so that early and proper management can be facilitated and fatal outcomes can be prevented.

Material and methods

Ethical approval

Approval of the Ethical Review Committee (ERC) of the Aga Khan University Hospital located in Karachi, Pakistan was obtained.

Study design and setting

This single-center observational study was performed between April 1, 2020 and September 15, 2020 at the Aga Khan University Hospital, the largest tertiary care center located in Karachi, Pakistan. We retrospectively collected the demographic, clinical, laboratory and radiological data of patients presenting with post-COVID lung parenchymal abnormalities from medical records. Disease severity of patients with COVID-19 infection was classified according to the WHO classification [8]. High-resolution computed tomography (HRCT) of the chest findings, treatment and outcomes were recorded.

Study subjects

Patients who were seen in the outpatient Pulmonology clinic or inpatient consultation service at the Aga Khan University Hospital owing to persistent respiratory symptoms after recovery

from COVID-19 infection were included in the study. Follow-up imaging was performed 8 to 12 weeks after recovery from acute infection and was compared with previous imaging for disease progression, improvement or resolution.

Identification of post-COVID lung parenchymal abnormality

The identification of post-COVID lung parenchymal abnormality in our study was based on “new, persistent and/or worsening of respiratory symptoms and identification of lung parenchymal abnormality pattern on HRCT imaging of the chest after the initial recovery phase of acute COVID-19 infection defined as 8 to 12 weeks after the onset of infection with no previous history of lung disease. They were identified by specialists in ILD clinic or on inpatient consultation”.

Inclusion and exclusion criteria

Adult patients (aged 18 and above) who were confirmed for SARS-CoV-2 by nasopharyngeal and/or oropharyngeal swabs for real-time RT-PCR at initial presentation and underwent chest imaging on subsequent follow-up visits were included in our study. The patients with pre-existing lung disease and those with incomplete medical records were excluded.

Operational definition of outcomes

We have defined outcomes as complete recovery, improvement and progression of the disease process. The patients were labelled as completely recovered if they returned to their baseline functional status and chest imaging showed complete clearance of lung infiltrates after the identification of post-COVID lung parenchymal abnormalities. Improvement was defined as subjective improvement in functional status but not to the baseline and at least 50% clearance of radiological infiltrates. The patients whose symptoms persisted with interval worsening of functional status and no significant improvement or worsening of lung infiltrates were defined as progression of the disease process.

HRCT chest analysis

The key HRCT chest findings of post-COVID lung parenchymal abnormalities were defined using standard taxonomy described in the literature with interstitial patterns including but not limited to diffuse ground-glass opacities with or without traction bronchiectasis (NSIP), basal and peripheral reticular opacities with honey combing (UIP) and peripheral and peribronchovascular consol-

idation with or without ground-glass opacities (OP) [9]. The main HRCT findings were described as ground-glass opacities (GGO), consolidation, honeycombing/fibrosis and interlobular septal thickening/reticulation. Other HRCT findings included crazy paving, reverse halo sign, traction bronchiectasis and emphysematous cysts. The distribution of pulmonary involvement was reported as either peripheral or diffuse.

Statistical analysis

Statistical analyses were performed using STATA version 12.1 (StataCorp LLC, College

Station, Texas, USA). Quantitative data were presented as mean \pm standard deviation (SD) or as median with inter-quartile range (IQR), while percentages of the total, unless stated otherwise, were used to represent qualitative (categorical) data.

Results

As shown in Table 1, our cohort included 30 patients, 27 were males (90.0%) with an average age of 59.14 ± 12.60 . Common presenting symptoms of COVID-19 disease were fever (30, 100.0%), cough (19, 63.3%) and shortness of breath (23, 76.7%). During initial COVID-19 disease, 16 (53.3%) patients had severe disease and 14 (46.7%) had critically ill disease. All individuals required supplemental oxygen. Out of 14 critically ill patients, 12 (85.7%) were treated with non-invasive ventilation (NIV) and 2 (14.3%) patients were treated with invasive mechanical ventilation.

All patients in our cohort were found to have bilateral lung disease. Four HRCT patterns of lung parenchymal abnormalities were seen (Table 2). Diffuse involvement was found in 15 (50.0%) patients, while peripheral predominance in 15 (50.0%) and other significant findings were seen in 8 (26.7%) study subjects.

All patients were treated with corticosteroids (0.5–1 mg/kg/day) for average duration of 8 to 12 weeks. Two individuals were treated with pirfenidone for fibrotic lung disease. Home oxygen was needed in 28 (93.3%) patients.

Table 1. Clinical and demographic characteristics of patients with post-COVID lung parenchymal abnormalities (n = 30)

Variables	Findings
Age [years], mean \pm SD	59.1 \pm 12.6
Gender, n (%)	
Male	27 (90.0)
Female	3 (10.0)
Comorbidities, n (%)	
Diabetes mellitus	14 (46.7)
Hypertension	13 (43.3)
Chronic obstructive pulmonary disease	1 (3.3)
Chronic liver disease	1 (3.3)
Malignancy	1 (3.3)
Ischemic heart disease	1 (3.3)
Inflammatory bowel disease	1 (3.3)
Chronic kidney disease	1 (3.3)
Smoking, n (%)	
Current smokers	3 (10.0)
Ex-smokers	8 (26.7)
Non-smokers	19 (63.3)
Symptoms on presentation with COVID-19, n (%)	
Fever	30 (100)
Shortness of breath	23 (76.7)
Cough	19 (63.3)
Fatigue	9 (30.0)
Headache	2 (6.7)
Persistent respiratory symptoms, n (%)	
Persistent cough	13 (43.3)
Persistent shortness of breath	29 (96.7)
Severity of COVID-19 Disease on initial presentation, n (%)	
Non-severe	0 (0)
Severe	16 (53.7)
Critically ill	14 (46.7)
Treatment given for post-COVID lung parenchymal abnormalities, n (%)	
Home oxygen	28 (93.3)
Prednisolone	30 (100.0)
Pirfenidone	2 (6.7)

COVID-19 — coronavirus disease 2019; SD — standard deviation

Table 2. Radiological patterns of post-COVID lung parenchymal abnormalities (n = 30)

Variables	Findings
Main findings, n (%)	
Patchy consolidation with ground glass opacity (OP pattern)	10 (33.3)
Diffuse ground glass opacities (NSIP pattern)	17 (56.7)
Honeycombing/Fibrosis (UIP pattern)	12 (40.0)
Interlobular Septal Thickening/Reticulation (probable UIP)	14 (46.7)
Distribution, n (%)	
Peripheral	15 (50.0)
Diffuse	15 (50.0)
Other findings, n (%)	
Crazy paving	2 (6.7)
Reverse halo sign	1 (3.3)
Traction bronchiectasis	4 (13.3)
Emphysematous cysts	1 (3.3)

COVID-19 — coronavirus disease 2019; OP — organizing pneumonia; NSIP — nonspecific interstitial pneumonia; UIP — usual interstitial pneumonia

A total of eight subjects had pulmonary functions test (PFT). Median and IQR of forced vital capacity (FVC) was 92.5% (43.2%–102.7%). Four patients had normal pulmonary functions. However, three persons had reduced FVC. Diffusion capacity of the lungs for carbon monoxide (DL_{CO}) was done in three cases, out of which two patients had moderately reduced and one individual had normal DL_{CO}.

Five patients died during the disease course; 4 (80.0%) patients died due to hypoxic respiratory failure, while 1 (20.0%) succumbed to superimposed aspergillus infection. Majority of the study subjects who died; 3 (60.0%), had progressive disease with UIP pattern. The CT images of 3 patients with different patterns of lung parenchymal abnormalities are shown in Figure 1–3. Out of the 25 alive patients, 8 (32.0%) recovered completely, 9 (36.0%) improved, while 8 (32.0%) patients had static or progressive disease.

Discussion

Our study found four distinct lung parenchymal abnormalities associated with COVID-19 disease. Development of lung parenchymal abnormalities amongst survivors of COVID-19 disease has been reported during the ongoing pandemic, however, data is limited to case reports [10–12]. Literature from the previous outbreaks of viral infections such as SARS and MERS, in 2002 and 2012 respectively, reported that clinico-radiological changes persisted in approximately one-third of patients even after 12 weeks of discharge [2, 3].

The majority of our patients who developed lung parenchymal abnormalities were males, which

is reported in literature with certain ILDs-like idiopathic pulmonary fibrosis [13, 14]. COVID-19-associated fibrosis is one of the lung insults already described with previous coronavirus infections [2, 3], and there are emerging studies now reporting COVID-19-associated early pulmonary fibrosis. In the initial papers, Pan *et al.* and Zhou *et al.* reported fibrotic changes in the imaging features of patients with COVID-19 pneumonia [15, 16]. Since then, fibrotic lung parenchymal remodelling [17, 18], fibrosing diffuse alveolar damage (DAD) [19] and honeycombing [20] have also been confirmed after invasive testing such as cryobiopsies and autopsies in smaller cohorts. Li Yan *et al.* described DAD on autopsy of 30 patients with COVID-19, showing 43% developing fibrosing patterns while 25% showing organizing pattern [19].

Post-infectious secondary OP is also a known entity, well described with certain viruses like Cytomegalovirus and Influenza-A (H1N1) [6, 21]. Pathology in patients who recovered from SARS-CoV has shown fibrogranulation tissue proliferation and organizing pneumonia-like patterns [22] while MERS-associated organizing pneumonia has also been documented [23, 24]. Studies of COVID-19 CT imaging, coupled with postmortem lung biopsies and autopsies during the ongoing pandemic, suggest the development of a secondary OP, which at present remains an underrecognized complication [25].

A distinct feature of organizing pneumonia and NSIP is the resolution with corticosteroid treatment. Although the use of corticosteroids has been recommended in the treatment of COVID-19 disease [26], there is limited data on response of prolonged or higher dose corticoste-

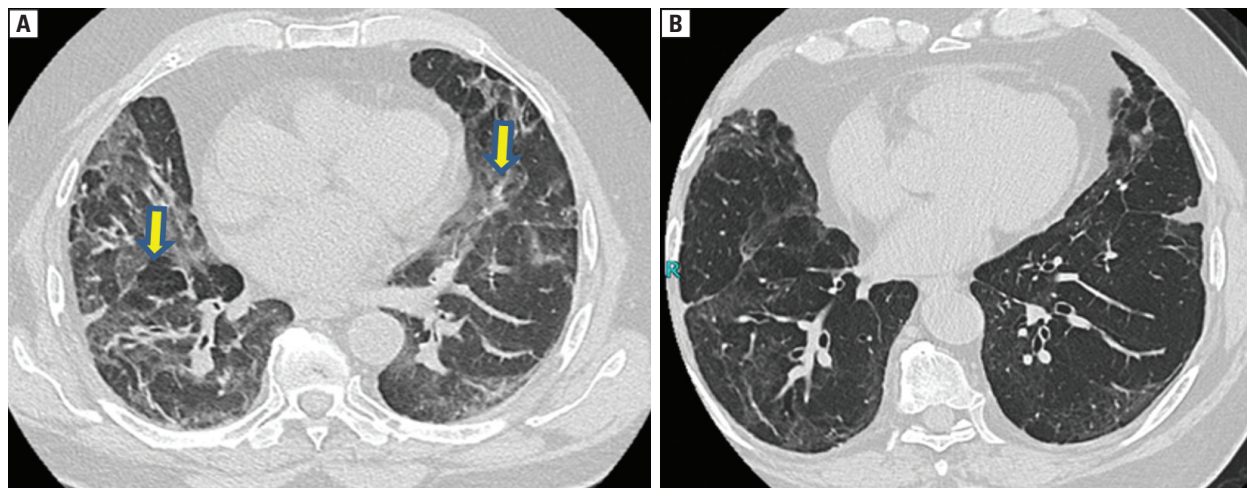


Figure 1. HRCT of the chest showing **A.** ground glass opacities (GGOs) and interlobular septal thickening (yellow arrow showing GGOs and septal thickening); and **B.** interval reduction in GGOs and septal thickening after initiation of corticosteroids

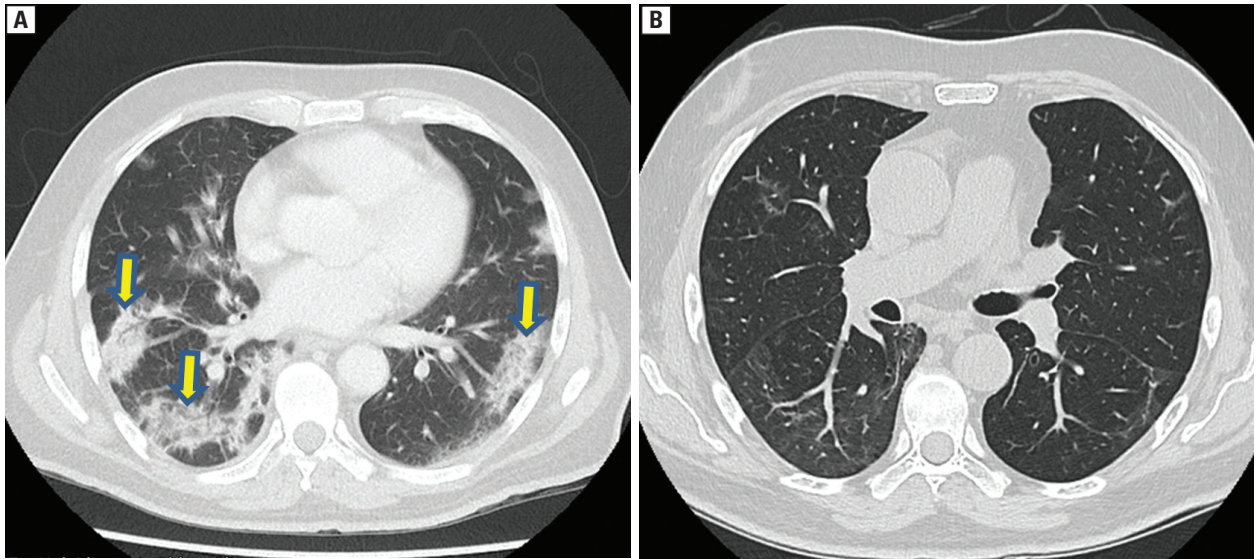


Figure 2. HRCT of the chest showing **A.** peripheral patchy areas ground glass opacities (GGOs) with consolidation consistent with an OP (organizing pneumonia) pattern (yellow arrow pointing towards peripheral patchy GGOs); and **B.** near complete resolution of peripheral patchy consolidation after initiation of corticosteroids

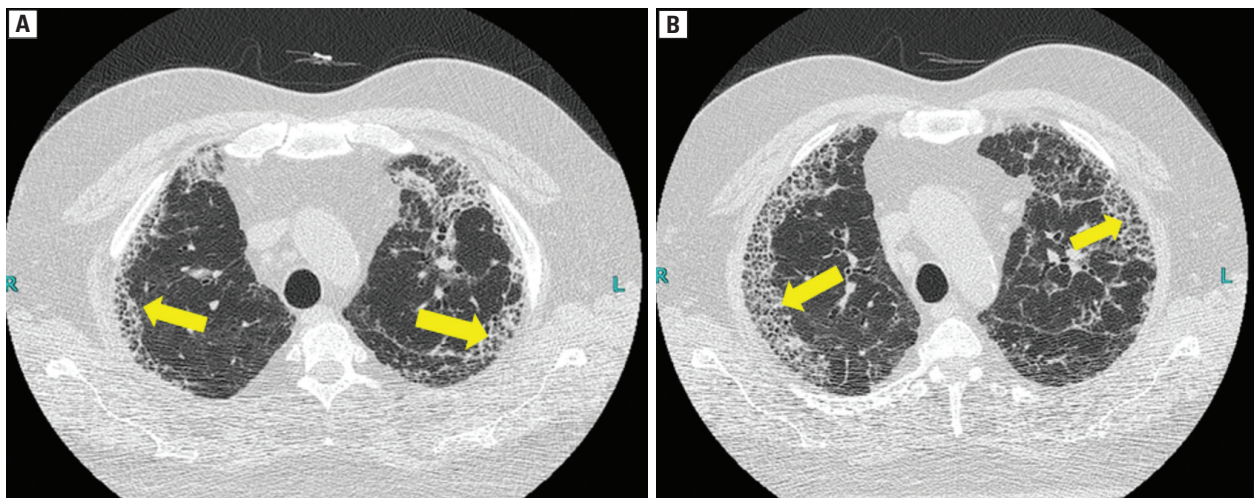


Figure 3. HRCT of the chest showing **A.** honeycombing and reticulation (yellow arrow showing honeycombing); and **B.** persistent and worsening of honeycomb fibrosis (yellow arrow showing honeycombing)

roids in post-COVID lung parenchymal abnormalities. Myall *et al.* described the cohort of patients in which thirty individuals with post-COVID organizing pneumonia pattern were treated with corticosteroids with significant improvement [7].

In our cohort, most patients developed a predominant OP or NSIP pattern with severe to critically ill disease. Most persons with an OP and NSIP pattern improved significantly with steroids, showing both clinical and radiological improvement. The patients showing UIP pattern, however, largely remained static or progressed. Majority of the deaths in our cohort were in the patients showing UIP pattern.

Disease severity did not seem to have a significant impact on development of any particular pattern of lung parenchymal abnormality. This proves that these reported lung microstructure changes are not only a result of post-ARDS fibrosis or ventilator-induced lung damage, but also a consequence of the direct virus-induced injury and aberrant local immune response leading to lung parenchymal abnormalities. Combet *et al.* recently described a case of a spontaneously breathing patient who developed rapid honeycombing following COVID-19 disease which responded to high-dose steroids and nintedanib [27]. Tale *et al.* also reported a similar case of a patient with

persistent hypoxemia after recovery from moderate COVID-19 disease with 3-week follow-up HRCT showing architectural distortion, interlobar septal thickening and traction bronchiectasis [28]. These case reports reiterate our stance that predisposed patients who are moderately ill, and do not require mechanical ventilation can also develop early fibrotic changes. However, study conducted by Han *et al.* had findings contrary to that of ours. They extrapolated that in patients with age greater than 50, increased heart rate on admission, increased duration of hospital stay, non-invasive mechanical ventilation and extensive CT involvement at initial CT were risk factors for fibrotic changes at 6-month follow-up [29]. Post-viral pulmonary fibrosis associated with previous coronaviruses has been seen in patients with critical disease leading to ARDS with longer duration of illness requiring ICU stay and invasive mechanical ventilation [2]. However, SARS-CoV-2 has shown to induce fibrosis in patients who did not require invasive mechanical ventilation or ICU stay in our study.

To the best of our knowledge, this is a first case series emphasizing and presenting data of 30 patients with different patterns of post-COVID lung parenchymal abnormalities along with their follow-up from a low to middle income country.

Our study has several limitations which include, among others, the absence of histopathologic confirmation of lung parenchymal abnormalities. Transbronchial and open lung biopsies were not performed due to the cost, invasive nature of procedure and risk of transmission of COVID-19; therefore, our patients were diagnosed solely on clinical and radiological grounds. A limited number of PFTs and DL_{CO} were performed to assess the physiologic function.

Conclusion

Post-COVID lung parenchymal abnormalities are an increasingly recognized clinical entity. A close follow-up is essential in these patients, as they may require prolonged treatment with corticosteroids in relatively higher doses. The long-term effects of post-COVID lung sequelae are yet to be determined, and a longitudinal follow-up will help us further explore the nature of the disease.

Ethics approval and consent to participate

Approval of the Ethical Review Committee (ERC) of the Aga Khan University Hospital located in Karachi, Pakistan was obtained (ERC Refer-

ence # 2020-5269-11494) and informed consent requirement was waived because of retrospective nature of the study.

Conflict of interest

The authors declare that they have no competing interests.

References:

- Nasir N, Farooqi J, Mahmood SF, et al. COVID-19-associated pulmonary aspergillosis (CAPA) in patients admitted with severe COVID-19 pneumonia: An observational study from Pakistan. *Mycoses*. 2020; 63(8): 766–770, doi: [10.1111/myc.13135](https://doi.org/10.1111/myc.13135), indexed in Pubmed: [32585069](https://pubmed.ncbi.nlm.nih.gov/32585069/).
- Das KM, Lee EY, Singh R, et al. Follow-up chest radiographic findings in patients with MERS-CoV after recovery. *Indian J Radiol Imaging*. 2017; 27(3): 342–349, doi: [10.4103/ijri.IJRI_469_16](https://doi.org/10.4103/ijri.IJRI_469_16), indexed in Pubmed: [29089687](https://pubmed.ncbi.nlm.nih.gov/29089687/).
- Venkataraman T, Frieman MB. The role of epidermal growth factor receptor (EGFR) signaling in SARS coronavirus-induced pulmonary fibrosis. *Antiviral Res*. 2017; 143: 142–150, doi: [10.1016/j.antiviral.2017.03.022](https://doi.org/10.1016/j.antiviral.2017.03.022), indexed in Pubmed: [28390872](https://pubmed.ncbi.nlm.nih.gov/28390872/).
- Azadeh N, Limper AH, Carmona EM, et al. The role of infection in interstitial lung diseases: A review. *Chest*. 2017; 152(4): 842–852, doi: [10.1016/j.chest.2017.03.033](https://doi.org/10.1016/j.chest.2017.03.033), indexed in Pubmed: [28400116](https://pubmed.ncbi.nlm.nih.gov/28400116/).
- Cuadrado MM, Ahmed A, Carpenter B, et al. Cytomegalovirus pneumonitis complicated by a central peribronchial pattern of organising pneumonia. *Respir Med Case Rep*. 2017; 20: 184–187, doi: [10.1016/j.rmcr.2017.02.005](https://doi.org/10.1016/j.rmcr.2017.02.005), indexed in Pubmed: [28316929](https://pubmed.ncbi.nlm.nih.gov/28316929/).
- Messina M, Scichilone N, Guddo F, et al. Rapidly progressive organising pneumonia associated with cytomegalovirus infection in a patient with psoriasis. *Monaldi Arch Chest Dis*. 2007; 67(3): 165–168, doi: [10.4081/monaldi.2007.489](https://doi.org/10.4081/monaldi.2007.489), indexed in Pubmed: [18018757](https://pubmed.ncbi.nlm.nih.gov/18018757/).
- Myall KJ, Mukherjee B, Castanheira AM, et al. Persistent post-COVID-19 interstitial lung disease. An observational study of corticosteroid treatment. *Ann Am Thorac Soc*. 2021; 18(5): 799–806, doi: [10.1513/AnnalsATS.202008-1002OC](https://doi.org/10.1513/AnnalsATS.202008-1002OC), indexed in Pubmed: [33433263](https://pubmed.ncbi.nlm.nih.gov/33433263/).
- WHO. COVID-19 Clinical management: living guidance. 2021. <https://www.who.int/publications/i/item/WHO-2019-nCoV-clinical-2021-1>.
- Demedts M, Costabel U. ATS/ERS international multidisciplinary consensus classification of the idiopathic interstitial pneumonias. *Eur Respir J*. 2002; 19(5): 794–796, doi: [10.1183/09031936.02.00492002](https://doi.org/10.1183/09031936.02.00492002), indexed in Pubmed: [12030715](https://pubmed.ncbi.nlm.nih.gov/12030715/).
- Hani C, Trieu NH, Saab I, et al. COVID-19 pneumonia: A review of typical CT findings and differential diagnosis. *Diagn Interv Imaging*. 2020; 101(5): 263–268, doi: [10.1016/j.diii.2020.03.014](https://doi.org/10.1016/j.diii.2020.03.014), indexed in Pubmed: [32291197](https://pubmed.ncbi.nlm.nih.gov/32291197/).
- Okamori S, Lee Ho, Kondo Y, et al. Coronavirus disease 2019-associated rapidly progressive organizing pneumonia with fibrotic feature: Two case reports. *Medicine (Baltimore)*. 2020; 99(35): e21804, doi: [10.1097/MD.00000000000021804](https://doi.org/10.1097/MD.00000000000021804), indexed in Pubmed: [32871900](https://pubmed.ncbi.nlm.nih.gov/32871900/).
- Wu Y, Xie YL, Wang X. Longitudinal CT findings in COVID-19 pneumonia: case presenting organizing pneumonia pattern. *Radiol Cardiothorac Imaging*. 2020; 2(1): e200031, doi: [10.1148/ryct.2020200031](https://doi.org/10.1148/ryct.2020200031), indexed in Pubmed: [33778545](https://pubmed.ncbi.nlm.nih.gov/33778545/).
- Kalafatis D, Gao J, Pesonen I, et al. Gender differences at presentation of idiopathic pulmonary fibrosis in Sweden. *BMC Pulm Med*. 2019; 19(1): 222, doi: [10.1186/s12890-019-0994-4](https://doi.org/10.1186/s12890-019-0994-4), indexed in Pubmed: [31771560](https://pubmed.ncbi.nlm.nih.gov/31771560/).
- Fernández Pérez ER, Daniels CE, Schroeder DR, et al. Incidence, prevalence, and clinical course of idiopathic pulmonary fibrosis: a population-based study. *Chest*. 2010; 137(1):

- 129–137, doi: [10.1378/chest.09-1002](https://doi.org/10.1378/chest.09-1002), indexed in Pubmed: [19749005](https://pubmed.ncbi.nlm.nih.gov/19749005/).
15. Pan Y, Guan H, Zhou S, et al. Initial CT findings and temporal changes in patients with the novel coronavirus pneumonia (2019-nCoV): a study of 63 patients in Wuhan, China. *Eur Radiol.* 2020; 30(6): 3306–3309, doi: [10.1007/s00330-020-06731-x](https://doi.org/10.1007/s00330-020-06731-x), indexed in Pubmed: [32055945](https://pubmed.ncbi.nlm.nih.gov/32055945/).
 16. Zhou S, Zhu T, Wang Y, et al. CT Features of Coronavirus Disease 2019 (COVID-19) Pneumonia in 62 Patients in Wuhan, China. *AJR Am J Roentgenol.* 2020; 214(6): 1287–1294, doi: [10.2214/AJR.20.22975](https://doi.org/10.2214/AJR.20.22975), indexed in Pubmed: [32134681](https://pubmed.ncbi.nlm.nih.gov/32134681/).
 17. Grillo F, Barisione E, Ball L, et al. Lung fibrosis: an undervalued finding in COVID-19 pathological series. *Lancet Infect Dis.* 2021; 21(4): e72, doi: [10.1016/S1473-3099\(20\)30582-X](https://doi.org/10.1016/S1473-3099(20)30582-X), indexed in Pubmed: [32735785](https://pubmed.ncbi.nlm.nih.gov/32735785/).
 18. Chen JY, Qiao K, Liu F, et al. Lung transplantation as therapeutic option in acute respiratory distress syndrome for coronavirus disease 2019-related pulmonary fibrosis. *Chin Med J (Engl).* 2020; 133(12): 1390–1396, doi: [10.1097/CM9.0000000000000839](https://doi.org/10.1097/CM9.0000000000000839), indexed in Pubmed: [32251003](https://pubmed.ncbi.nlm.nih.gov/32251003/).
 19. Li Y, Wu J, Wang S, et al. Progression to fibrosing diffuse alveolar damage in a series of 30 minimally invasive autopsies with COVID-19 pneumonia in Wuhan, China. *Histopathology.* 2021; 78(4): 542–555, doi: [10.1111/his.14249](https://doi.org/10.1111/his.14249), indexed in Pubmed: [32926596](https://pubmed.ncbi.nlm.nih.gov/32926596/).
 20. Schwensen HF, Borreschmidt LK, Storgaard M, et al. Fatal pulmonary fibrosis: a post-COVID-19 autopsy case. *J Clin Pathol.* 2020 [Epub ahead of print], doi: [10.1136/jclin-path-2020-206879](https://doi.org/10.1136/jclin-path-2020-206879), indexed in Pubmed: [32723800](https://pubmed.ncbi.nlm.nih.gov/32723800/).
 21. Torrego A, Pajares V, Mola A, et al. Influenza A (H1N1) organising pneumonia. *BMJ Case Rep.* 2010; 2010, doi: [10.1136/bcr.12.2009.2531](https://doi.org/10.1136/bcr.12.2009.2531), indexed in Pubmed: [22736390](https://pubmed.ncbi.nlm.nih.gov/22736390/).
 22. Hwang DM, Chamberlain DW, Poutanen SM, et al. Pulmonary pathology of severe acute respiratory syndrome in Toronto. *Mod Pathol.* 2005; 18(1): 1–10, doi: [10.1038/mod-pathol.3800247](https://doi.org/10.1038/mod-pathol.3800247), indexed in Pubmed: [15272286](https://pubmed.ncbi.nlm.nih.gov/15272286/).
 23. Ajlan AM, Ahyad RA, Jamjoom LG, et al. Middle East respiratory syndrome coronavirus (MERS-CoV) infection: chest CT findings. *AJR Am J Roentgenol.* 2014; 203(4): 782–787, doi: [10.2214/AJR.14.13021](https://doi.org/10.2214/AJR.14.13021), indexed in Pubmed: [24918624](https://pubmed.ncbi.nlm.nih.gov/24918624/).
 24. Kim I, Lee JE, Kim KH, et al. Successful treatment of suspected organizing pneumonia in a patient with Middle East respiratory syndrome coronavirus infection: a case report. *J Thorac Dis.* 2016; 8(10): E1190–E1194, doi: [10.21037/jtd.2016.09.26](https://doi.org/10.21037/jtd.2016.09.26), indexed in Pubmed: [27867585](https://pubmed.ncbi.nlm.nih.gov/27867585/).
 25. Kory P, Kanne JP. SARS-CoV-2 organising pneumonia: Has there been a widespread failure to identify and treat this prevalent condition in COVID-19?. *BMJ Open Respir Res.* 2020; 7(1), doi: [10.1136/bmjresp-2020-000724](https://doi.org/10.1136/bmjresp-2020-000724), indexed in Pubmed: [32963028](https://pubmed.ncbi.nlm.nih.gov/32963028/).
 26. Horby P, Lim WS, Emberson JR, et al. RECOVERY Collaborative Group. Dexamethasone in hospitalized patients with COVID-19. *N Engl J Med.* 2021; 384(8): 693–704, doi: [10.1056/NEJMoa2021436](https://doi.org/10.1056/NEJMoa2021436), indexed in Pubmed: [32678530](https://pubmed.ncbi.nlm.nih.gov/32678530/).
 27. Combet M, Pavot A, Savale L, et al. Rapid onset honeycombing fibrosis in spontaneously breathing patient with COVID-19. *Eur Respir J.* 2020; 56(2), doi: [10.1183/13993003.01808-2020](https://doi.org/10.1183/13993003.01808-2020), indexed in Pubmed: [32631838](https://pubmed.ncbi.nlm.nih.gov/32631838/).
 28. Tale S, Ghosh S, Meitei SP, et al. Post-COVID-19 pneumonia pulmonary fibrosis. *QJM.* 2020; 113(11): 837–838, doi: [10.1093/qjmed/hcaa255](https://doi.org/10.1093/qjmed/hcaa255), indexed in Pubmed: [32814978](https://pubmed.ncbi.nlm.nih.gov/32814978/).
 29. Han X, Fan Y, Alwalid O, et al. Six-month follow-up chest CT findings after severe COVID-19 pneumonia. *Radiology.* 2021; 299(1): E177–E186, doi: [10.1148/radiol.2021203153](https://doi.org/10.1148/radiol.2021203153), indexed in Pubmed: [33497317](https://pubmed.ncbi.nlm.nih.gov/33497317/).