

# A pulmonary ligament approach for portal robotic segmentectomy of the lateral and posterior basal segments: a case report

著者名	MITSUBOSHI Shota , SHIDEI Hiroaki , KOEN Akihiro , MAEDA Hideyuki , AOSHIMA Hiroe , ISAKA Tamami , KANZAKI Masato
journal or publication title	Journal of Medical Case Reports
volume	15
number	1
page range	196
year	2021
URL	<a href="http://hdl.handle.net/10470/00033005">http://hdl.handle.net/10470/00033005</a>

doi: 10.1186/s13256-021-02789-3

CASE REPORT

Open Access



# A pulmonary ligament approach for portal robotic segmentectomy of the lateral and posterior basal segments: a case report

Shota Mitsuboshi, Hiroaki Shidei, Akihiro Koen, Hideyuki Maeda, Hiroe Aoshima, Tamami Isaka and Masato Kanzaki\*

## Abstract

**Background:** Thoracoscopic segmentectomy of the lateral and posterior basal segments is extremely technically challenging. Appropriate segmentectomy requires exposure and recognition of the branches of the bronchi and pulmonary vessels deep in the lung parenchyma. Although various approaches for these segmentectomies have been reported, the use of a pulmonary ligament approach is rational because it does not require any interlobar separation. Here, we report a successful case of portal robotic segmentectomy of the lateral and posterior basal segments through the pulmonary ligament approach.

**Case presentation:** A 60-year-old Japanese man with a history of low anterior resection for rectal cancer was referred to our department because of a lung nodule. His chest computed tomography revealed a 15-mm tumor in the left posterior basal bronchus. Robotic left S9–10 segmentectomy through the pulmonary ligament was performed with five-port incisions.

**Conclusions:** An extremely technically challenging thoracoscopic segmentectomy of the lateral and posterior basal segments was performed through the pulmonary ligament using a robotic surgical system.

**Keywords:** Robot-assisted thoracoscopic surgery, Segmentectomy, Pulmonary ligament, Thoracoscopy, Intersegmental septum

## Background

In Japan, the national health insurance began covering robotic pulmonary segmentectomy for malignant lung tumors in 2020, in consideration of the increasing number of domestic robot-assisted thoracoscopic surgical (RATS) procedures being performed. Recently, robotic segmentectomy has been reported to have been performed safely and have excellent perioperative outcome and safety [1–3].

However, thoracoscopic segmentectomy of the lateral (S9) and posterior basal (S10) segments is extremely

technically challenging. Appropriate segmentectomy requires exposure and recognition of the branches of the bronchi and pulmonary vessels deep in the lung parenchyma [1–3]. The branches of the pulmonary vein are especially far from the interlobar fissure. Although various approaches for these segmentectomies have been reported, the use of a pulmonary ligament (PL) approach is rational because it does not require any interlobar separation.

Here, we report successful case of portal robotic S9 and S10 (S9–10) segmentectomy through the PL approach.

\*Correspondence: [kanzaki.masato@twmu.ac.jp](mailto:kanzaki.masato@twmu.ac.jp)  
Department of Thoracic Surgery, Tokyo Women's Medical University, 8-1 Kawada-cho, Shinjuku-ku, Tokyo 162-8666, Japan



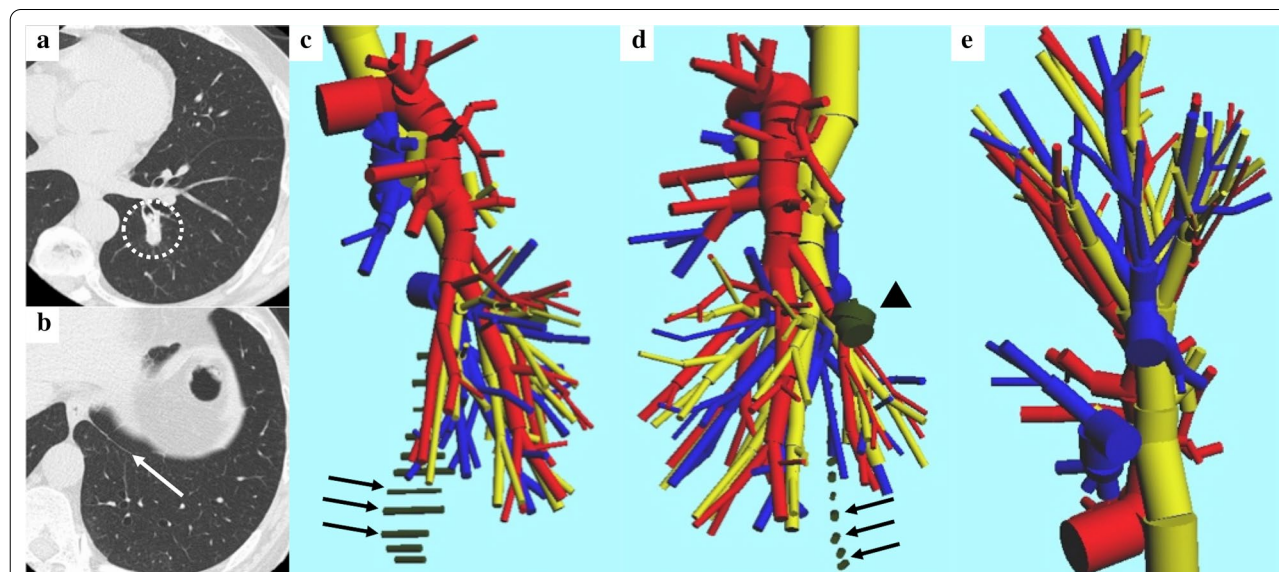
© The Author(s) 2021. **Open Access** This article is licensed under a Creative Commons Attribution 4.0 International License, which permits use, sharing, adaptation, distribution and reproduction in any medium or format, as long as you give appropriate credit to the original author(s) and the source, provide a link to the Creative Commons licence, and indicate if changes were made. The images or other third party material in this article are included in the article's Creative Commons licence, unless indicated otherwise in a credit line to the material. If material is not included in the article's Creative Commons licence and your intended use is not permitted by statutory regulation or exceeds the permitted use, you will need to obtain permission directly from the copyright holder. To view a copy of this licence, visit <http://creativecommons.org/licenses/by/4.0/>. The Creative Commons Public Domain Dedication waiver (<http://creativecommons.org/publicdomain/zero/1.0/>) applies to the data made available in this article, unless otherwise stated in a credit line to the data.

### Case presentation

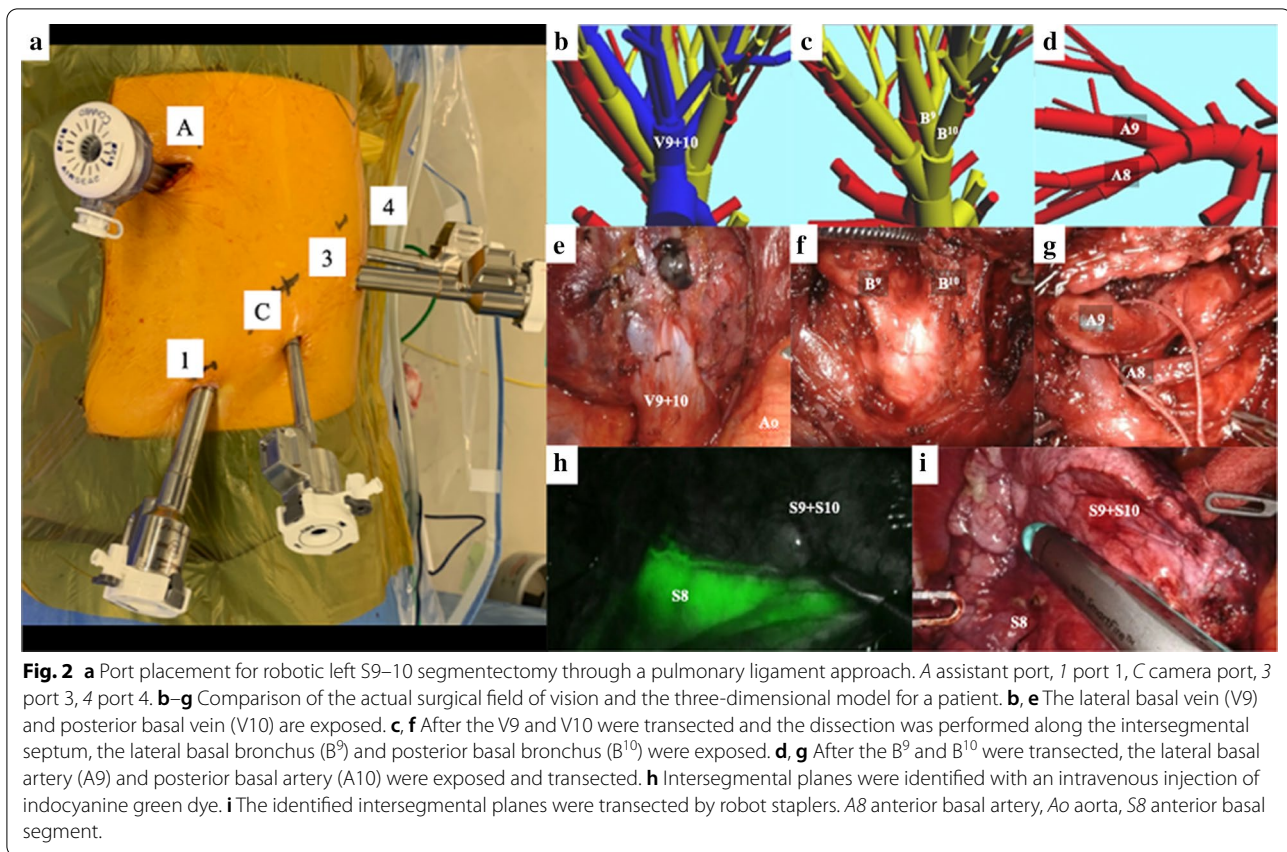
A 60-year-old Japanese man with a history of low anterior resection for rectal cancer 4 years ago was referred to our department because of a lung nodule detected on chest radiography during a routine medical checkup. He had no symptoms and presented with a body temperature of 35.9°C, blood pressure of 106/65 mmHg, heart rate of 59 beats per minute, and oxygen saturation of 99% on room air. His laboratory examination results were within normal limits. As his chest computed tomography (CT) revealed a 12-mm tumor in the left posterior basal bronchus during postoperative follow-up, he underwent six cycles of chemotherapy with mFOLFOX6 and bevacizumab at standard doses. After chemotherapy, he underwent chest and abdomen CT scans, which confirmed that the tumor deeply seated in the segment had been growing continuously up to 15 mm (Fig. 1a, b). Fluorodeoxyglucose positron emission tomography (FDG-PET) revealed an abnormal uptake of FDG, with a maximum standardized uptake value of 2.28 in the tumor. Hence, the patient was treated with a portal robotic S9–10 segmentectomy through a PL approach.

On the basis of the patient's actual three-dimensional (3-D) pulmonary model, created using an in-house software as presented in the preoperative CT images, the involvement of the pulmonary vessels and bronchi were identified and the location and extent of tumor invasion were assessed to determine the surgical procedure (Fig. 1c–e) [4–6].

Under general anesthesia with single-lung ventilation and lateral decubitus positioning, RATS S9–10 segmentectomy was performed with five-port incisions, including an assistant port as a carbon dioxide (CO<sub>2</sub>) insufflation port. With the pleural space as the entry point, a 12-mm trocar (AirSeal access ports, ConMed, Utica, NY, USA) was inserted as an assistant port in the fifth intercostal space (ICS) anteriorly in the anterior axillary line. Moreover, two 8-mm robotic trocars were inserted, one as a port for the robotic camera in the ninth ICS at the middle axillary line and the other as port 4 on the posterior side of the tip of the scapula. Two 12-mm robotic trocars were inserted in port 1 and 3 in the eighth ICS anteriorly along the anterior axillary line and in the ninth ICS along the posterior axillary line, respectively, after which the da Vinci Xi surgical system (Intuitive Surgery, Sunnyvale, CA, USA) was docked (Fig. 2a). All four robotic arms were used. A CO<sub>2</sub> insufflation system (AirSeal system, ConMed) was used at a set pressure of 5 mmHg. The robotic instruments were manipulated through a 12-mm port mounting a 12–8-mm reducer. Fenestrated bipolar forceps, a permanent cautery spatula, and Cadiere forceps were inserted through ports 1, 3, and 4 (Intuitive Surgical), respectively. After lifting the left lower lobe using the Cadiere forceps, the PL was incised up to the inferior pulmonary vein. The basal pulmonary vein was exposed, and both the lateral (V9) and posterior basal veins (V10) were transected using robot staplers (Fig. 2b, e). Next, the intersegmental septum was



**Fig. 1** a, b Chest computed tomography revealing a 15-mm tumor in the left posterior basal bronchus (dotted circle) and the pulmonary ligament (white arrow). c–e Preparation of a reconstructed 3-D pulmonary model of patients with metastatic lung tumor. The red color indicates the pulmonary arteries, blue color indicates the pulmonary veins, yellow color indicates the trachea and bronchi, and black color indicates the tumor (arrow head) and the pulmonary ligament (arrows).



dissected to expose the bronchi and pulmonary arteries. First, the targeted bronchi were exposed and transected, followed by the targeted pulmonary arteries (Fig. 2c, d, f, g). An intravenous injection of indocyanine green was administered, and observation under fluorescence navigation revealed intersegmental planes, which were marked using the fenestrated bipolar forceps and permanent cautery spatula, after which the target S9–10 segments were resected using the robot staplers (Fig. 2h, i). An additional movie file shows this procedure in detail (Additional file 1).

The final histopathological investigations confirmed the resected tumor to be a lung metastasis of rectal cancer. The postoperative course was uneventful. Postoperatively, he received no adjuvant chemotherapy. No recurrence was observed for 6 months after the operation.

### Discussion and conclusions

Since March 2009, we have performed a complete thoracoscopic segmentectomy of S9–10 through a PL approach while viewing two-dimensional (2-D) images on a video monitor in 37 patients with primary lung cancer and metastatic lung tumors [4]. The PL is contiguous with the intersegmental septum and can be easily

surgically separated from the lung parenchyma, such as the medial basal segment (S7) and S10 of the right lung and the anterior basal segment (S8) and S10 of the left lung. Thus, interlobar separation of the lungs is not mandatory to expose the inferior pulmonary vein. By allowing accurate thoracoscopic treatment of the peripheral vessels and the segmental bronchi, 3-D images can be used to visualize the positional relationships among the target pulmonary vessels and bronchi [7, 8]. In comparison with the conventional 2-D thoracoscopic S9 or S10 segmentectomy through a PL approach, portal robotic S9–10 segmentectomy is feasible. The use of robotic surgical systems yields accurate 3-D high-definition images with improved ergonomics that allows surgeons to conduct accurate and improved intuitive maneuvers, which reduces the burden on the assistant surgeon. Compared with the conventional 2-D thoracoscopic surgery through a PL approach, multijointed robotic forceps allow easy mobilization on the diaphragmatic surface of the inferior lobe to the cranial side and easy dissection of the intersegmental septum to expose the pulmonary vessels and bronchi in the RATS procedure. While our previously reported video-assisted thoracoscopic surgical (VATS) technology may confer a higher risk of incomplete lymph

node dissection than the traditional procedures would, the RATS technique articulates lymphadenectomy, which is difficult to execute with thoracoscopy and can be easily performed with robotic instruments [9]. RATS removes the physiological tremor known in VATS. This results in an excellent level of precision necessary for such a challenging case [10]. Early-stage lung cancer, metastatic lung tumors, and benign tumors arising in the lung center are considered good indications for the RATS technique. Furthermore, the learning curve for RATS is reported to be shorter than that for thoracoscopic surgery [9]. Although S9–10 segmentectomy thorough the PL approach is extremely technically challenging, the RATS technique is considered faster to master.

#### Abbreviations

RATS: Robot-assisted thoracoscopic surgical; S9: Lateral segment; S10: Posterior basal segment; PL: Pulmonary ligament; S9–10: Lateral and posterior basal segments; 3-D: Three-dimensional; CT: Computed tomography; FDG-PET: Fluorodeoxyglucose positron emission tomography; CO<sub>2</sub>: Carbon dioxide; ICS: Intercostal space; V9: Lateral veins; V10: Posterior basal veins; 2-D: Two-dimensional; S7: Medial basal segment; S8: Anterior basal segment; VATS: Video-assisted thoracoscopic surgical.

#### Supplementary Information

The online version contains supplementary material available at <https://doi.org/10.1186/s13256-021-02789-3>.

**Additional file 1.** After the left lower lobe was lifted up using Cadiere forceps, the pulmonary ligament was incised up to the inferior pulmonary vein. The basal pulmonary vein was exposed, and both the lateral basal vein and posterior basal vein were transected using robot staplers. Next, the intersegmental septum was dissected to expose the bronchi and pulmonary arteries. The targeted bronchi, such as the lateral basal bronchus and posterior basal bronchus, were first exposed and transected, followed by the targeted pulmonary arteries as the lateral basal artery and posterior basal artery. An intravenous injection of indocyanine green was administered, and observation under fluorescence navigation revealed intersegmental planes, which were marked using fenestrated bipolar forceps and permanent cautery spatula, after which the target S9–10 segments were resected using robot staplers.

#### Acknowledgements

The authors would like to thank Enago (<http://www.enago.jp/>) for the English language review.

#### Authors' contributions

SM drafted the manuscript. MK performed the surgery. HS, AK, HM, HA, and TI assisted in performing the surgery. MK critically revised the manuscript. All authors read and approved the final manuscript.

#### Funding

The authors received no financial support for the research, authorship, and publication of this article.

#### Availability of data and materials

All the data and materials supporting our findings are included within the article.

#### Declarations

#### Ethics approval and consent to participate

Not applicable.

#### Consent for publication

Written informed consent was obtained from the patient for publication of this case report and any accompanying images. A copy of the written consent is available for review by the Editor-in-Chief of this journal.

#### Competing interests

MK has received honoraria from Intuitive Surgical Japan. All other authors declare no competing interests.

Received: 9 January 2021 Accepted: 15 March 2021

Published online: 25 April 2021

#### References

- Liang H, Liang W, Zhao L, Chen D, Zhang J, Zhang Y, et al. Robotic versus video-assisted lobectomy/segmentectomy for lung cancer: a meta-analysis. *Ann Surg*. 2018;268:254–9.
- Nguyen D, Gharagozloo F, Tempesta B, Meyer M, Gruessner A. Long-term results of robotic anatomical segmentectomy for early-stage non-small-cell lung cancer. *Eur J Cardiovasc Surg*. 2019;55:427–33.
- Pardolesi A, Park B, Petrella F, Borri A, Gasparri R, Veronesi G. Robotic anatomic segmentectomy of the lung: technical aspects and initial results. *Ann Thorac Surg*. 2012;94:929–34.
- Kikkawa T, Kanzaki M, Isaka T, Onuki T. Complete thoracoscopic S9 or S10 segmentectomy through a pulmonary ligament approach. *J Thorac Cardiovasc Surg*. 2011;149:937–9.
- Kanzaki M, Wachi N, Onuki T. Simulating video-assisted thoracoscopic lung resection using a virtual 3-dimensional pulmonary model on a personal computer. *J Thorac Cardiovasc Surg*. 2011;142:243–4.
- Kanzaki M, Kikkawa T, Shimizu T, Maeda H, Wachi N, Isaka T, et al. Presurgical planning using a three-dimensional pulmonary model of the actual anatomy of patient with primary lung cancer. *Thorac Cardiovasc Surg*. 2013;61:144–50.
- Oizumi H, Kanauchi N, Kato H, Endoh M, Suzuki J, Fukaya K, et al. Anatomic thoracoscopic pulmonary segmentectomy under 3-dimensional multidetector computed tomography simulation: a report of 52 consecutive cases. *J Thorac Cardiovasc Surg*. 2011;141:678–82.
- Liu C, Liao H, Guo C, Pu Q, Mei J, Liu L. Single-direction thoracoscopic basal segmentectomy. *J Thorac Cardiovasc Surg*. 2020;160:1586–94.
- Kanzaki M. Current status of robot-assisted thoracoscopic surgery for lung cancer. *Surg Today*. 2019;49:795–802.
- Bouabdallah I. Robotic left S<sup>9–10</sup> lung segmentectomy: how I do it? *J Vis Surg*. 2020;6:44.

#### Publisher's Note

Springer Nature remains neutral with regard to jurisdictional claims in published maps and institutional affiliations.