

Department of obstetrics and gynecology, General Hospital Pula

COMPARISON OF A RE-ANALYZED VAGINAL HYSTERECTOMY TO A CLASSICAL ONE

*Davor Zoričić, Dragan Belci, Dino Bečić, Tomislav Perkov**Original scientific paper*

Key words: vaginal hysterectomy, ten-step vaginal hysterectomy, Heaney method, postoperative recovery

SUMMARY. Objective. To evaluate advantages of a re-analyzed vaginal hysterectomy (the ten-step vaginal hysterectomy – TSVH) as compared to a traditional technique of vaginal hysterectomy. **Patients and methods.** A prospective randomized study involving 66 patients with pelvic organ prolapse; 46 operations were performed using the classical technique of vaginal hysterectomy (modified Heaney method) and 20 using the TSVH. **Results.** TSVH results in shorter operating time, shorter hospital stay, and significantly less need for analgesia compared to the Heaney method. There is no difference in blood loss, pain intensity and degree of patient satisfaction 7 days after surgery. **Conclusion.** The ten-step vaginal hysterectomy which is a structured method based on the analysis of several possible surgical steps seems to be simple to perform, teach and learn. Because of its didactic presentation, this method can successfully promote vaginal hysterectomy when teaching new generations of gynecological surgeons, and should be adopted for routine clinical use.

Introduction

The first vaginal hysterectomy was performed by Langenbeck in 1813. Since then, the vaginal approach underwent numerous modifications (1). Most of the techniques are results of local traditions and often based on the surgeon's habits and personal views.

The ten-step vaginal hysterectomy (TSVH) as analyzed and introduced by Michael Stark and associates (2,3) results from the analysis of all steps in several methods with the aim to simplify the procedure by performing only the most essential and logical steps and to omit those that are not essential (4,5).

In his original study, Stark defined the steps which are common to all the methods and then analyzed them for optimal performance and sequence during the operation. Only the most essential steps were left, and a part of them was modified, as he believed that every step in each operation should have a definite purpose and be performed in an optimal way.

In order to find out if the TSVH is feasible, a prospective study was conducted. This paper outlines our first experiences with the TSVH.

Material and methods

Between October 2008 and April 2011 81 patients referred to the Department of Gynecology and Obstetrics of the General Hospital Pula for vaginal hysterectomy for benign pathology were invited to participate in

a prospective randomized observation study (*Figure 1*). Women with pelvic organ prolapse stage II and III according to Pelvic Organ Prolapse Quantification System (POP-Q) were included. Key exclusion criteria were no prolapse or pelvic organ prolapse stage I (the most distal portion of the prolapse is ≥ -1 cm from the plane of hymenal ring) or IV (complete vaginal eversion), previous pelvic organ prolapse surgery, suspicion of malignancy and/or ovarian cyst greater than 4 cm.

A total of 66 patients were included in the study; 46 operations were performed using the modified Heaney method, and 20 using ten-step vaginal hysterectomy. Both groups of patients did not differ significantly in age or parity (*Table 1*). Written informed consent was taken from all patients after explaining the procedure. Every patient was completely evaluated by an anesthetist before deciding the type of anesthesia. Spinal anesthesia was used in most of our patients.

We analyzed operation time (from the start of incision at cervico-vaginal junction to the end of vaginal cuff closure), intraoperative bleeding (measured as number of erythrocytes and hemoglobin level before and 7 days after surgery), the subjective experience of pain 24 hours and 7 days after surgery (expressed in a length 100 mm visual analogue scale (VAS) and the need of postoperative analgesics), patient satisfaction 7 days after surgery, and the duration of hospitalization. As discharge parameters we used absence of fever, resumption of normal bowel motility and urinary function and patient comfort. The data were stored in a data base

Table 1. Patients age and parity distribution (*P<0,078)

	Ten-step hysterectomy (N=20)	Modified Heaney method (N=46)
Age (mean values)*	59,8±8,8	63,5±8,5
Parity		
0	1 (5%)	0 (0%)
1–2	12 (60%)	34 (74%)
3 and more	7 (35%)	12 (26%)

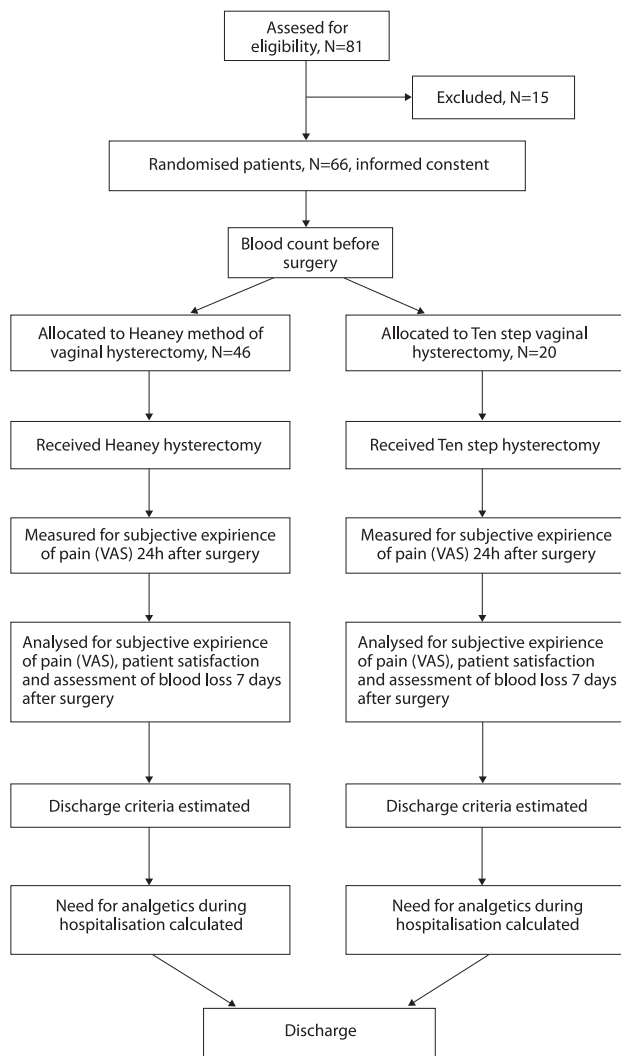


Figure 1. Study design flowchart

and analyzed. The Mann-Whitney U test is used to compare differences between two groups. The level of significance was $P < 0,05$.

Ten-step vaginal hysterectomy – method description

1. Incision of the vaginal wall

The TSVH can be used in non-prolapsed or prolapsed uterus. In a non-prolapsed uterus, a circular incision,

1,5 cm above the external os, is made. It starts at the front aspect and continues around the cervix with good exposure. After wards the vaginal wall is pushed upwards around the cervix with a surgical forceps or a swab to enable exposure of the bladder in the front and the pouch of Douglas in the back. In case of a prolapsed uterus a drop-like incision separates the vaginal wall beginning under the urethra and encircling the cervix (Figure 2). Thereafter, the tip of the drop is pulled down while separating it gently with contra-pressure of a swab from the bladder, and the rest of the vaginal wall is circularly separated with a surgical forceps, thus exposing the pouch of Douglas.

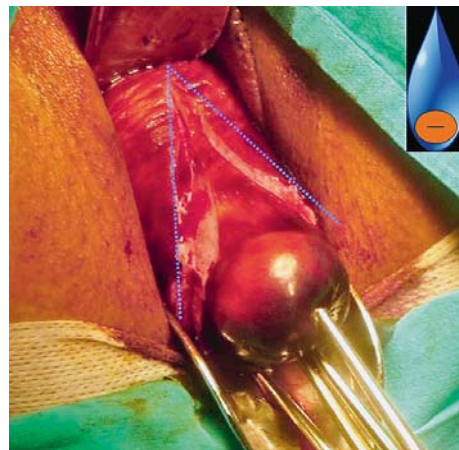


Figure 2. Drop-like incision in a prolapsed uterus

2. Detaching the bladder from the uterus

In a non-prolapsed uterus, the bladder is pushed upwards with an open swab on the surgeon's finger until the anterior peritoneum is exposed but not opened. In a prolapsed uterus, the bladder is separated from the cervix and pushed all the way up.

3. Opening the posterior peritoneum

The uterus is pulled towards the os pubis and the exposed peritoneum is grasped with surgical forceps while being opened with big curved scissors. The scissors are then introduced into the pouch of Douglas and pushed back while being opened in order to expose the insertions of the sacro-uterine ligaments.

4. Dissection of the lower part of the uterus

The relatively bloodless sacro-uterine ligaments, together with the paracervical tissues, which are anatomically in different planes, are clamped together. This is done by a designed maneuver: one blade of an open clamp is placed under the insertion of the sacro-uterine ligament, the instrument rotates towards the uterus while the uterus is being contra-rotated (Figure 3). Both anatomical structures are now included between the blades of the instrument while it is being closed. Both structures are cut and ligated leaving the suture material with its full length. This is repeated on the contralateral side.

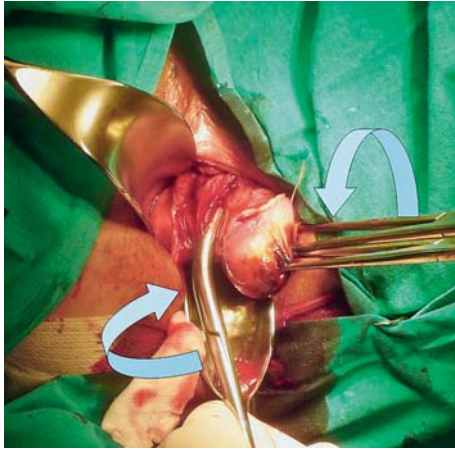


Figure 3. Dissection of the lower part of the uterus

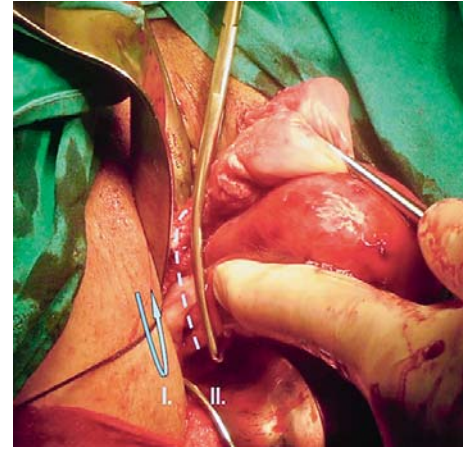


Figure 4. Dissection of the upper part of the uterus

Table 2. Comparison of surgical technique between two types of vaginal hysterectomy.

Steps	Modified Heaney method	Ten-step vaginal hysterectomy
I. incision of vaginal wall	circular incision around the cervix	drop like incision of anterior vaginal wall and around the cervix (circular incision in non-prolapsed uterus)
II. detaching the bladder from uterus	bladder is pushed up wards until the anterior peritoneum is exposed and opened if possible	bladder is pushed upwards until the anterior peritoneum is exposed but not opened
III. opening the posterior peritoneum	posterior peritoneum is grasped with surgical forceps and opened; insertions of the sacro-uterine ligaments are exposed	
IV. dissection of the lower part of uterus	sacro-uterine ligaments are clamped separately from paracervical tissues	sacro-uterine ligaments and the paracervical tissues are clamped together
V. cutting and ligating the uterine arteries	uterine arteries are exposed, clamped, cut and ligated	
VI. opening the anterior peritoneum	uterus is pulled down, two fingers are placed behind the fundus to lift the peritoneum which is opened under direct vision	
VII. dissection of the upper part of uterus	round and ovarian ligaments are clamped separately and ligated	round and ovarian ligaments and the blood vessels are clamped together and ligated
VIII. peritoneal closure	YES	NO
IX. reconstruction of the pelvic floor	round and sacro-uterine pedicles are plicated to the vaginal cuff, sutures of the round and uterosacral pedicles are tied in the midline after the vaginal wall was sutured	pedicles of round and sacro-uterine ligaments with the paracervical tissues are ligated to each other in midline
X. closing the vaginal wall	vaginal wall is sutured with interrupted sutures longitudinally (figure of 6 sutures)	vaginal wall is sutured continuously (longitudinally or transversely)

5. Cutting and ligating the uterine arteries

With a slight traction of the uterus, both uterine arteries are now exposed, clamped, cut and ligated.

6. Opening the anterior peritoneum

The uterus is pulled down with gentle rotating movements of the tenaculi and two fingers are placed behind the fundus to lift the anterior peritoneum which is opened under vision with scissors.

7. Dissection of the upper part of the uterus (and appendages)

The round and ovarian ligaments and the blood vessels are clamped together and ligated. The ligature should be placed as lateral as possible from the clamp. The uterus is cut away with scissors medial to the instrument. A transfixion suture is placed between the

clamp and the ligature keeping the full length of the suture material. The ligature, which is placed before and lateral to the transfixion, will prevent bleeding, should this transfixion suture slip away or tear by traction (Figure 4).

8. The ‘non-stage’ – leaving the peritoneum open.

The pelvic parietal peritoneum is attached to the pelvic ligaments. The ligation of the ligaments to each other will create a peritoneal continuity but at the same time enable drainage. Liquid blood is absorbed by the peritoneum within hours. This is the time to correct enterocele should it be indicated.

9. Reconstruction of the pelvic floor.

The pedicles of round and sacro-uterine ligaments with the paracervical tissues are ligated to each other.

10. Closing the vaginal wall

The vaginal wall is closed continuously. It is recommended in sexually active women to close the vagina transversely. This will prevent dyspareunia as the suturing line will be located in the anterior wall. Differences between two techniques of vaginal hysterectomy are shown in *Table 2*.

Results

Vaginal hysterectomy was successfully performed in all cases, and no intraoperative or early postoperative complications occurred.

The ten-step vaginal hysterectomy proved to be significantly shorter compared to the modified Heaney method. It also resulted in a significantly less need for postoperative analgesia and a shorter hospital stay (*Table 3*).

There was no statistically significant difference between the two groups concerning blood loss measured as difference of erythrocytes number and hemoglobin level before surgery and 7th day after surgery (*Figure 5*). Assessment of postoperative pain using VAS 24 hours and on the 7th day after the procedure did not show any statistically significant difference (*Table 4*). Also, no statistically difference was found in patient satisfaction on the 7th postoperative day (*Table 5*).

Discussion

Since its introduction in the 19th century, the vaginal hysterectomy underwent numerous modifications. Several described methods retained a number of steps that are the result of tradition and personal opinions. This study demonstrated that patients who undergo ten-step vaginal hysterectomy have shorter operation time, reduced analgesia requirements and shorter hospital stays

Table 3. Comparison of operation time, use of analgesics and duration of hospital stay

	Ten-step hysterectomy		Modified Heaney method		Statistical significance
	Mean value±SD	Median (25th-75th percentile)	Mean value±SD	Median (25th-75th percentile)	
Operation time (min.)	30±5	30 (25–35)	43±7,7	45 (38–48)	<0,001
Need for analgesics (hours)	28±10,4	30 (25–35)	40,8±12,8	40 (32–48)	0,001
Hospital stay (days)	7,5±0,8	7 (7–8)	9,5±2	9 (8–10)	<0,001

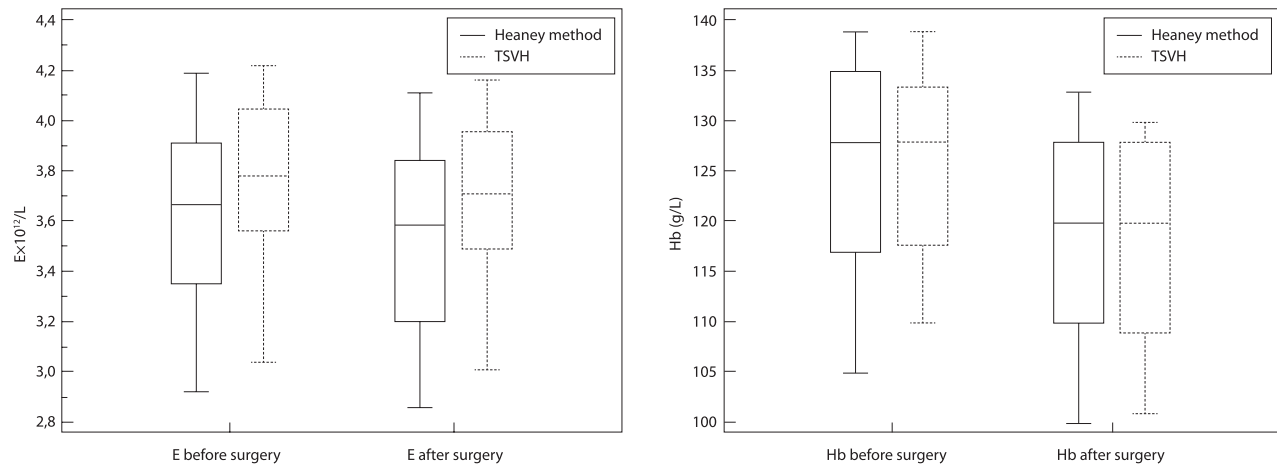


Fig. 5. Comparison of number of erythrocytes and hemoglobin level measured before surgery and 7th day after surgery)

Table 4. Assessment of postoperative pain (VAS measured 24h and 7th day after surgery)

	Ten-step hysterectomy		Modified Heaney method		Statistical significance
	Mean value±SD	Median (25th-75th percentile)	Mean value±SD	Median (25th-75th percentile)	
VAS 24h after procedure	7.35±2.72	8 (5–10)	7.3±2.52	8 (5–9,75)	0,963 (NS)
VAS 7 th day after procedure	2±3.16	0,5 (0–3,5)	2.13±2.77	1 (0–3,75)	0,918 (NS)

Table 5. Patient satisfaction 7th day after surgery

	Ten-step hysterectomy		Modified Heaney method		Statistical significance
	Mean value±SD	Median (25th-75th percentile)	Mean value±SD	Median (25th-75th percentile)	
VAS 7 th day after procedure	9,6±0,7	10 (9,5–10)	7,8±4,04	10 (8–10)	0,221 (NS)

than those who undergo modified Heaney operation. Our results support the claim that there is benefit in clear, anatomically based logic of operation which ensures its uninterrupted sequence and requires a minimal number of instruments. For example, according to our personal experience drop-like incision of the vaginal vault has obviously advantages over the conventional technique of cystocele repair which is often time-consuming. Furthermore, technique of clamping and ligation of ligaments and reconstruction of pelvic floor and vaginal vault represents seemingly small but ultimately significant differences compared to the classical technique of vaginal hysterectomy. And finally, the omission of certain procedures such as clamping of sacrouterine ligaments separately from paracervical tissues or closure of the parietal peritoneum does not have effect on final result (6,7).

Like every operation, vaginal hysterectomy and its modifications should be examined critically by considering any step that has been kept due to traditions and personal opinions and experiences while analyzing its necessity and its way of performance. Kudo et al. showed that the omission of certain steps in operation reduces intraoperative complications with similar results (8). With the approach of eliminating unnecessary steps, intra and postoperative complications will be reduced, the duration of the procedure shortened, and the cost of treatment lowered. Optimizing the operation method positively affects patients due to faster postoperative recovery and shorter hospital stay with outcomes that are just as good or better. In the end usually the simplest method seems to be most logical and effective.

With overall technological advancement and the introduction of endoscopy into clinical practice, laparoscopic surgery is increasingly becoming the method of choice for hysterectomy. However, numerous studies have shown that vaginal hysterectomy has advantages and is the method of choice for patients with benign conditions (9). A study by Miekleet al. showed more intraoperative complications when abdominal hysterectomy or LAVH is performed in comparison to vaginal hysterectomy (10). A longer operating time with higher treatment costs were recorded, although the postoperative recovery after LAVH is significantly shorter. Campbell et al. showed that vaginal hysterectomy gives best results with the shortest hospital stay and lower costs, and that LAVH is considered an alternative to abdominal hysterectomy (11). Kelly et al. showed that the impact of vaginal hysterectomy on dysfunction of bladder, anal sphincter and sexual functions is lower when compared to LAVH and abdominal hysterectomy (12). Similar results on the improvement of sexual function were obtained by Stoutjesdijk et al. (13). Al-Kadri et al. found that vaginal hysterectomy has fewer intraoperative short-term and long-term postoperative complications as compared to total abdominal hysterectomy (14). Regardless of the shorter postoperative recovery when LAVH is performed (15,16), the vaginal approach should be considered in patients who need a hysterectomy

for benign conditions because, among other things, this approach results in a quick recovery, no visible scars and fewer intraoperative and postoperative complications (17). In achieving this goal the ten-step vaginal hysterectomy, because of its didactic presentation, can successfully promote vaginal hysterectomy among new generations of gynecological surgeons.

Conclusion

The ten-step vaginal hysterectomy is the result of a critical analysis of vaginal hysterectomy methods based both on anatomical and up-to-date physiological principles. As compared to a traditional Heaney technique this method of vaginal hysterectomy indicates a shorter operation time, less need for analgesics and a shorter hospital stay, which means less treatment costs.

Shortening the duration of surgery is not only based on leaving out certain procedures, but it is based on a clear, anatomically based logic of operation which ensures its uninterrupted sequence and requires a minimal number of instruments.

The ten-step vaginal hysterectomy which is a structured method based on the analysis of several possible surgical steps seems to be simple to perform, teach and learn. Because of its didactic presentation, this method can successfully promote vaginal hysterectomy when teaching new generations of gynecological surgeons, and should be adopted for routine clinical use.

Literature

1. Gray LA. Vaginal hysterectomy. *Ann Surg.* 1954;139(5):666–75.
2. Stark M, Gerli S, Di Renzo GC. An example for an optimized technique: The Ten-Step.
3. Vaginal Hysterectomy, in: *Progress in Obstetrics and Gynaecology* (2006);17:358–68.
4. Von Theobald P. Simplified vaginal hysterectomy. *J Chir* 2001;138(2):93–98.
5. Atlas of pelvic surgery, Online edition, <http://www.atlasofpelvicsurgery.com/5Uterus/9TotalVaginalHysterectomy/chap-5sec9.html>
6. Janschek EC, Hohlagschwandtner M, Nather A, Schindl M, Joura EA. A study of nonclosure of the peritoneum at vaginal hysterectomy. *Arch Gynecol Obstet* 2003;267:213–6.
7. Royal College of Obstetrics and Gynaecology. *Peritoneal Closure Guideline No. 15.* 2002.
8. Kudo R, Yamauchi O, Okazaki T, Sagae S, Ito E, Hashimoto M. Vaginal hysterectomy without ligation of the ligaments of the cervix uteri. *Surg Gynecol Obstet* 1990;170:299–305.
9. Aarts JWM, Nieboer TE, Johnson N, Tavender E, Garry R, Mol BWJ, Kluivers KB. Surgical approach to hysterectomy for benign gynaecological disease. *Cochrane Database of Systematic Reviews* 2015, DOI: 10.1002/14651858.CD003677.pub5
10. Meikle SF, Nugent EW, Orleans M. Complications and recovery from laparoscopy assisted vaginal hysterectomy compared with abdominal and vaginal hysterectomy. *Obstet Gynecol* 1997;89:304–11.

11. Campbell ES, Xiao H, Smith MK. Types of hysterectomy. Comparison of characteristics, hospital costs, utilization and outcomes. *J Reprod Med* 2003;48:943–9.

12. Kelly JL, O’Riordain DS, Jones E, Alawi E, O’Riordain MG, Kirwan WO. The effect of hysterectomy on ano-rectal physiology *International Journal of Colorectal Disease* Volume 13, Number 3, 116–8.

13. Stoutjesdijk JA, Vierhout JA, Spruijt JW, Massolt ET. Does vaginal reconstructive surgery with or without vaginal hysterectomy or trachelectomy improve sexual wellbeing? A prospective follow-up study. *IntUrogynecol J Pelvic Floor Dysfunct.* 2006Feb;17(2):131–5.

14. Al-Kadri HM, Al-Turki HA, Saleh AM. Short and long term complications of abdominal and vaginal hysterectomy for benign disease. *Saudi Med J.* 2002Jul;23(7):806–10.

15. Cosson M, Rajabally R, Querleu D, Crepin G. Long term complications of vaginal hysterectomy: a case control study. *Eur J ObstetGynecolReprod Biol.* 2001Feb;94(2):239–44.

16. Hidelbaugh D, O’Mara P, Conboy E. Clinical and financial analyses of laparoscopically assisted vaginal hysterectomy versus abdominal hysterectomy. *J Am Gynecol Laparosc.* <http://www.ncbi.nlm.nih.gov/pubmed/9138877> – # 1994 Aug; 1(4 Pt 1): 357–61.

17. Choosing the route of hysterectomy for benign disease. ACOG Committee Opinion No. 444. American College of Obstetricians and Gynecologists. *Obstet Gynecol* 2009;114:1156–8.

Corresponding author: Davor Zoričić, Odjel ginekologije i porodništva, Opća bolnica Pula. E-mail: davor.zoricic@pu.t-com.hr

Paper received: April 11th 2015; *accepted August 24th 2016*

Odjel ginekologije i porodništva, Opća bolnica Pula

USPOREDBA TEN-STEP OPERACIJE I KLASIČNE VAGINALNE HISTEREKTOMIJE

Davor Zoričić, Dragan Belci, Dino Bečić, Tomislav Perkov

Izvorni znanstveni rad

Ključne riječi: ten-step vaginalna histerektomija, postoperativni oporavak

SAŽETAK. Cilj rada. Evaluacija prednosti Ten step vaginalne histerektomije (TSVH) u odnosu na klasičnu metodu. **Ispitanice i metode.** Studijom je obuhvaćeno 66 pacijentica s prolapsom maternice II. i III. stupnja od kojih je 20 operirano TSVH metodom, a 46 klasičnom vaginalnom histerektomijom (modificirana metoda po Heaney-u). Dvije skupine bolesnica uspoređivane su prema dužini trajanja operacije, intraoperativnom krvarenju, trajanju postoperativne primjene analgetika, zadovoljstvu bolesnica i dužini hospitalizacije. TSVH metoda rezultat je analize nekoliko operacijskih tehnika i ima za cilj izvesti logične te anatomske i fiziološke utemeljene poteze, a izostaviti one koje nisu neophodne, već su rezultat navike. Ukratko, operacija započinje rezom prednje stijjenke rodnice koji se nastavlja oko porcije i formira oblik kaplje, nakon čega slijedi odvajanje mokraćnog mjehura od sluznice rodnice i vrata maternice te otvaranje peritoneuma Duglasovog prostora. Nakon disekcije sakrouterinih ligamenata i paracervikalnog tkiva koji se podvezuju u jednom hvatu, podvezuju se uterine arterije i otvara uteroezikalna eskavacija, nakon čega slijedi disekcija okruglih ligamenata i jajovoda s pripadajućim svezama. Peritoneum se ne šiva, zdjelično dno rekonstruira se spajanjem bataljaka ligamenata, a stijjenka rodnice zatvara produžnim šavom. **Rezultati.** Istraživanje je pokazalo da TSVH traje bitno kraće u odnosu na klasičnu histerektomiju, a bolesnice liječene tom metodom iziskivale su vremenski kraću postoperativnu primjenu analgetika i brže su otpuštane iz bolnice. Intraoperativni gubitak krvi i zadovoljstvo bolesnica zahvatom bili su podjednaki u obje skupine ispitanica. **Zaključak.** TSVH traje kraće u odnosu na klasičnu histerektomiju, iziskuje manju potrošnju analgetika i troškove liječenja, te omogućuje brži postoperativni oporavak. Imajući u vidu rezultate ove studije mišljena smo da bi ta operacija trebala imati svoje mjesto u kliničkoj praksi svakog ginekološkog odjela, tim više jer je jednostavnija za učenje i lakša za izvođenje u odnosu na do sada korištene metode.