

NORMAL ULTRASONOGRAPHIC FEATURES OF LOGGERHEAD (*CARETTA CARETTA*) EYES

GIUSEPPINA MENNONNA¹, BARBARA LAMAGNA², ANDREA AFFUSO³,
ADELAIDE GRECO¹, FABIANA MICIELI², DARIO COSTANZA¹, SANDRA
HOCHSCHEID³ & LEONARDO MEOMARTINO¹

¹Interdepartmental Centre of Veterinary Radiology, University of Naples Federico II,
Via F. Delpino 1, 80137 Naples, Italy

²Department of Veterinary Medicine and Animal Production, University of Naples Federico II,
Via F. Delpino 1, 80137 Naples, Italy

³Marine Turtle Research Center, Stazione Zoologica Anton Dohrn, Via Nuova Macello 16,
80055 Portici, Italy

Mennonna, G., Lamagna, B., Affuso, A., Greco, A., Micieli, F., Costanza, D., Hochscheid, S. & Meomartino, L.: Normal ultrasonographic features of loggerhead (*Caretta caretta*) eyes. *Nat. Croat.*, Vol. 29, Suppl. 1, 3-10, 2020, Zagreb.

The Loggerhead sea turtle (*Caretta caretta*) is widely distributed in the Mediterranean Sea but, like other sea turtles, it is considered a threatened species. Improving anatomical knowledge on normal aspects of the species is important for correct diagnosis and proper therapy and, therefore, for improving the chances of a complete recovery and a fast reintroduction into the wild for a greater number of sea turtle bycatch and other mishaps. For this reason, 15 Loggerhead turtles, with clinically healthy eyes, were submitted to ocular ultrasonographic (US) examinations. The US exam was quick, non-invasive, and simple to perform and permitted researchers to assess all the ocular features.

Keywords: Loggerhead, sea turtle, eye, ultrasound, biometric

Mennonna, G., Lamagna, B., Affuso, A., Greco, A., Micieli, F., Costanza, D., Hochscheid, S. & Meomartino, L.: Ultrazvučni nalaz normalnih značajki oka glavate želve (*Caretta caretta*). *Nat. Croat.*, Vol. 29, Suppl. 1, 3-10, 2020, Zagreb.

Glavata želva (*Caretta caretta*) je široko rasprostranjena u Sredozemnom moru, no, kao i ostale vrste morskih kornjača, smatra se ugroženom vrstom. Bolje poznavanje anatomije vrste važno je za pravilnu dijagnostiku i terapiju, a time se povećavaju šanse potpunog izliječenja i brzog povratka u divljinu za veliki broj slučajno ulovljenih ili ozlijeđenih morskih kornjača. Iz tog razloga petnaest glavatih želvi podvrgnuto je ultrazvučnom pregledu očiju. Ultrazvučni pregled bio je brz, neinvazivan, jednostavan za provedbu i omogućio je znanstvenicima pregled svih očnih funkcija.

Ključne riječi: glavata želva, morska kornjača, oko, ultrazvuk, biometrija

INTRODUCTION

The Loggerhead sea turtle (*Caretta caretta*) belongs to the Cheloniidae family. The distribution of this species is worldwide, included the Mediterranean Sea. In the Mediterranean Sea the nesting sites are mainly in the southern regions such as the coasts of Greece, Turkey and North Africa. In Italy, nesting occurs mainly along the coastlines of Sicily and Calabria (MINGOZZI *et al.*, 2007). Loggerhead turtles are also commonly encountered along the south-western coasts of Italy in the Tyrrhenian Sea, where ju-

veniles and adults utilize the rich local shallow habitats for foraging (HOCHSCHEID *et al.*, 2013, MAFFUCCI *et al.*, 2013).

These animals are threatened by multiple human activities: pollution of the seas, ingestion of fish-hooks and other foreign bodies (LAZAR & GRAČAN, 2011; SANTOS *et al.*, 2015), such as plastic bags that are confused with plankton, incidental catch in fisheries, propeller injuries, as well as, the destruction of nesting sites. The loggerhead sea turtle has been considered endangered for a long time (IUCN/SSC, 2002) but, thanks to the international efforts to protect the species, it has been reclassified as vulnerable (HOCHSCHEID *et al.*, 2018). In recent decades, the interest of the scientific community in these animals has increased. In order to improve the preservation and the treatments of these animals, the knowledge of the normal anatomy is mandatory and diagnostic imaging techniques represent a valuable means to reach this goal (VALENTE *et al.*, 2006; VALENTE, 2007; PEASE *et al.*, 2010; MENNONNA *et al.*, 2015; DE MAJO *et al.*, 2016; PEASE *et al.*, 2017). The sense organs, especially the sight, of these ancient animals concern biologists and veterinarians, particularly for their visual abilities both in water and out (NORTHMORE & GRANDA, 1991; OLIVER *et al.*, 2000; BARTOL *et al.*, 2002; MATHGER *et al.*, 2007; CROGNALE *et al.*, 2008). Often, turtles with ocular injuries are presented to veterinarians who work in rescue centers; therefore the knowledge of normal eye features is of a paramount importance.

Ultrasonography (US) has already been used to study the eye and to establish the normal biometrics in many species (PENNINCK *et al.*, 2001; HOLLINGSWORTH *et al.*, 2007; SPAULDING, 2008; LEHMKUHL *et al.*, 2010; DAR *et al.*, 2013; LAURIDSEN *et al.*, 2014; THAÍS *et al.*, 2014; SOMMA *et al.*, 2015; RAPOSO *et al.*, 2017; MEOMARTINO *et al.*, 2018).

The aim of this study was to describe the normal ultrasonographic features and dimensions of the eyes in the Loggerhead sea turtle (*Caretta caretta*).

MATERIALS AND METHODS

The ultrasonographic exams were performed on live Loggerhead sea turtles and the study was approved by the Italian Ministry of the Environment and the Protection of Natural and Marine Resources (protocol number 24471).

Thirty US of the eye were performed on fifteen Loggerhead sea turtles rescued from the south of the Tyrrhenian Sea and admitted at the Marine Turtle Research Centre (MTRC) of the Anton Dohrn Zoological Station in Portici (NA). All the turtles included were preventively submitted to a complete ophthalmic exam and had normal eyes. The straight length of the carapace (SCL) and the body weight (BW) were measured and recorded for all the turtles.

All the animals were manually gently restrained and sterile topical anesthetic (Novesin, oxybuprocaine hydrochloride 0.4%; Novartis Farma spa, Italy) was instilled before B-mode US. Twelve turtles were examined at the MTRC; the remaining three were examined at the Interdepartmental Center of Veterinary Radiology, during diagnostic investigations required for conditions not involving the eyes. Two ultrasound devices, equipped with a 12-MHz linear probe, were used: MyLab30[®] (Esaote, Florence, Italy) at the MTRC and Mylab Class C[®] (Esaote, Florence, Italy) at the Interdepartmental Center of Veterinary Radiology. The eye was coupled to the probe with a copious amount of sterile gel (Sterile Aquasonic 100; Parker La. Inc., Fairfield, NJ, USA) and the probe footprint was held in a horizontal and vertical position for the correspo-

nding US scans, until optimal images were obtained (Fig. 1). The ocular dimensions were measured using the US device software calipers. The following measurements were obtained for each eye: the polar axis (PA), the distance from the corneal surface to posterior wall of the retinal layer; the equatorial axis (EA), the maximal diameter perpendicular to the PA; the corneal thickness (CT), the distance between the two lines of the cornea; the anterior chamber depth (ACD), the distance from the posterior line of the cornea to the anterior capsule of the lens; the lens thickness (LT), the distance between the anterior and the posterior capsules; the vitreous chamber depth (VCD), the distance from the posterior capsule of the lens to the retinal surface (Fig. 2).

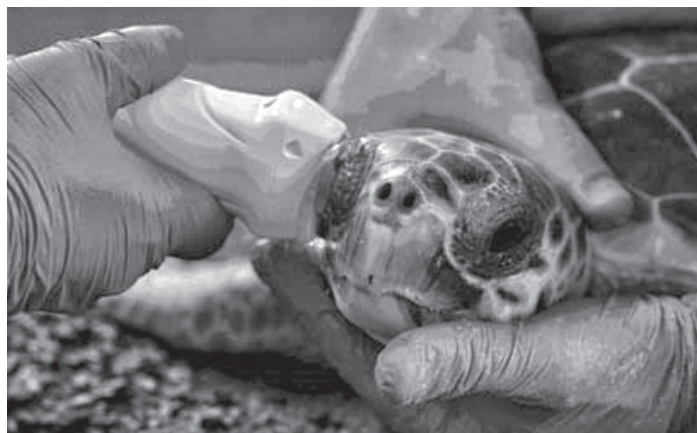

Fig. 1. The photo shows an ultrasonographic exam in progress: the turtle is gently restrained and the probe is placed on the right eye in a vertical position.

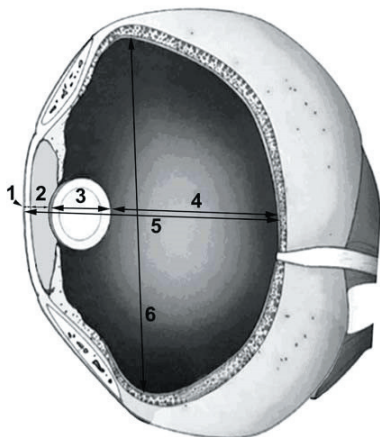


Fig. 2. Schematic drawing of the Loggerhead eye with the measurements performed. Legend: 1 = corneal thickness; 2 = anterior chamber depth; 3 = lens thickness; 4 = vitreous chamber depth; 5 = polar axis; 6 = equatorial axis.

Data collected were analyzed for normality with the Shapiro-Wilk test and reported as Mean \pm SD or Median (range) if normally or not normally distributed respectively. Differences between right and left eye in PA, EA, CT, ACD, LT, were analyzed with 2-sided Student's t-test or Mann Whitney test, according to their distribution. Correlation between SCL or BW and other variables were tested using Pearson's r or Spearman's r_s correlation coefficients, according to the distribution. Significance was set for $P < 0.05$. Data analysis was performed with dedicated software (JMP[®] 8.0.2, SAS Institute Inc., Cary, NC, USA).

RESULTS

The sample was composed of 11 sub-adults (SCL < 65 cm) and 4 juveniles (SCL < 40 cm). Only 5 individuals were sexed as 2 males and 3 fe-

males. The mean SCL was 47.18 cm (± 10.22 ; range 33.2-61.0 cm) and the mean BW was 18.79 kg (± 12.6 ; range 6-32.7 kg).

The US exam of the eye was successfully performed on all the turtle but some difficulties were encountered because of the retraction reflex, particularly present in this species. Each exam lasted from 3 to 5 minutes. Starting from the eyelid, the US features of the eye were as described below: the cornea was formed by two hyperechoic parallel lines and showed a slight anterior convexity; the anterior chamber was thin and anechoic; the lens was formed by two hyperechoic convex lines, representing the anterior and posterior capsules, delimiting an anechoic parenchyma, and was relatively small compared to the eyeball; the scleral ossicle appeared as two hyperechoic lines at the level of the limbus followed by a shadowing artifact, obscuring the equatorial borders of the lens and, sometimes, of the eye; the vitreous chamber was anechoic; the retinal layer was regular and no optic disc was visible; on some occasions, the cartilaginous portion of the posterior sclera was easily visible (Fig. 3).

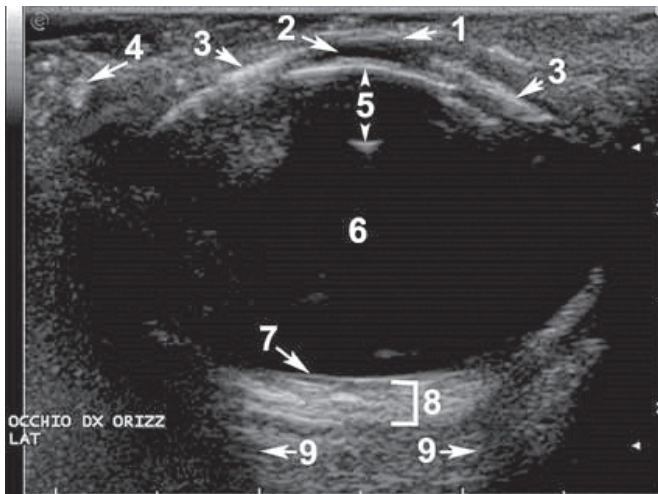


Fig. 3. Ultrasonographic image of the Loggerhead eye in the horizontal scan. Legend: 1 = cornea; 2 = anterior chamber; 3 = scleral ossicle; 4 = salt gland; 5 = anterior and posterior capsule of the lens; 6 = vitreous body; 7 = retinal layer; 8 = scleral cartilage; 9 = artifact shadowing from scleral ossicle.

Except for the CT, no statistical differences were found between right and left eye and the mean (\pm Dev.St.) are summarized in Tab. 1.

The SLC was significantly correlated only with VCD ($p=0.01$) while BW correlated with PA ($p<0.01$), EA ($p<0.01$), LT ($p=0.01$) and VCD ($p<0.01$) (Fig. 4).

Tab. 1. - Mean (\pm Dev.St.) of the measurements performed, expressed in mm. * Statistical difference between right and left eyes ($P < 0.01$).

	Right Eye	Left Eye	Pooled Eyes
Polar Axis	18.41 (± 1.51)	18.60 (± 1.73)	18.50 (± 1.11)
Equatorial Axis	23.28 (± 2.40)	23.43 (± 2.51)	23.35 (± 2.41)
Corneal Thickness*	0.62 (± 0.12)	0.52 (± 0.06)	0.57 (± 0.11)
Anterior Chamber Depth	0.83 (± 0.16)	0.82 (± 0.18)	0.83 (± 0.16)
Lens Thickness	4.46 (± 0.50)	4.40 (± 0.41)	4.43 (± 0.45)
Vitreous Chamber Depth	11.41 (± 0.97)	11.26 (± 1.08)	11.34 (± 1.01)

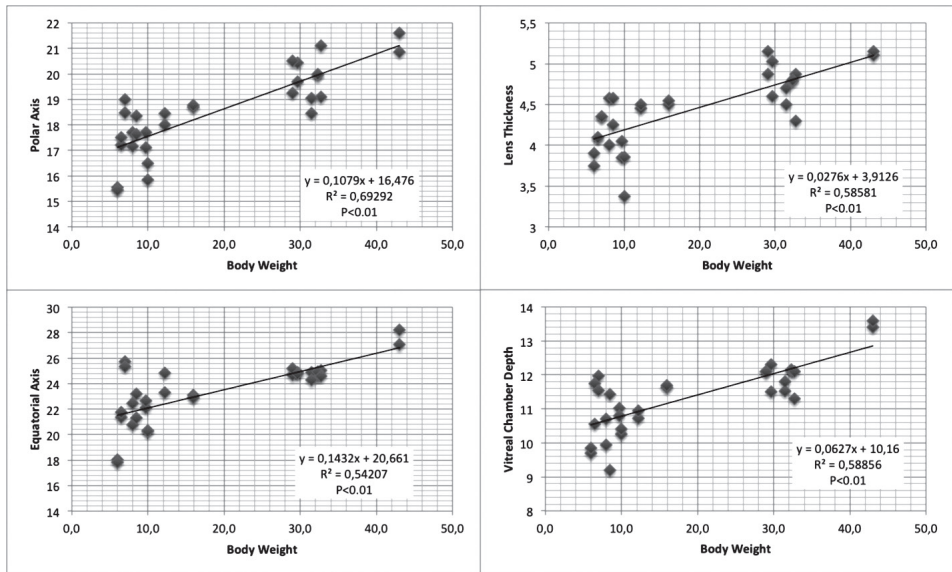


Fig. 4. Linear correlation Body weight with Polar axis, Equatorial axis, Lens thickness, and Vitreous chamber depth.

DISCUSSION

In the Loggerhead sea turtle the eye is placed within the skull (MADER *et al.*, 2017), dorsally and laterally; they have three keratinized eyelids, two mobile, dorsal and ventral, and a non-mobile medial lid, called a “secondary lid” (WYNEKEN, 2001). As in other animal species the ocular globe is formed by three layers that, starting from the outside to the inside, are the following: the sclera and, anteriorly, the cornea, formed by connective tissue; the uvea, the intermediate and vascularized layer; the retina, the inner sensory layer. In these animals there are two supporting structures, posteriorly the scleral cartilage and anteriorly the scleral ossicle (WYNEKEN, 2001; ARENCIBIA *et al.*, 2006; BRUDENALL *et al.*, 2008; JONES *et al.*, 2012).

This study provides the normal ocular ultrasonographic and biometric features in the loggerhead sea turtle (*Caretta caretta*). Compared to mammalian species, the ocular globes in these reptiles have a spheroidal shape, with a polar axis shorter than equatorial one. They also present a slight corneal curvature, as well as a very thin anterior chamber and a relatively small lens.

The US examination was quite easy to perform on awake animals, however some difficulties resulted from the presence of the scleral ossicle and the retraction reflex, very pronounced in this species. The scleral ossicle, due to the shadowing artifact, did not permit the complete visualization of the equatorial border of the lens or, on some occasions, of the eyeball. In addition, sea turtles, like other species of reptiles, such as lizards and crocodiles, have two muscles, retractor oculi and protractor oculi, which insert on the sclera and determine the movement towards the inside and the outside

of the eye within the orbit. On the other hand, the absence of fur facilitates the transmission and the progression of the ultrasound beam.

Our results showed a good correlation between eye dimensions and body weight as already reported (RAPOSO *et al.*, 2017). Interestingly, the ocular dimensions in our sample were quite similar to those obtained in a previous study, in spite of the larger mean weight of those turtles (RAPOSO *et al.*, 2017). We speculate that the ocular dimensions correlate with body dimensions during growth but, in the subadult subjects, they attain their final dimensions.

Loggerhead sea turtles, like other species of sea turtles, can be affected by several eye diseases and many of those can make the anterior portions of the eye opaque (İŞLER *et al.*, 2014; MADER *et al.*, 2017), and prevent a normal ophthalmic examination. Conversely, ultrasonography allows the evaluation of the interior of the eye, even when it is obscured from direct visualization by any disease resulting in ocular opacity (MACKEY & MATOON, 2015). Therefore, the US exam has to be considered an important complementary technique for studying the eye in this species of reptiles.

The B-mode US features presented are useful for clinical evaluation and provide reliable information about the normal dimensions and intraocular anatomy of loggerhead eyes. Our results also showed that the ultrasonography of the eye is a quick, simple and safe exam to perform in Loggerhead sea turtles. The use of general purpose US devices equipped with relatively high-frequency probes (10-12 MHz) allows images of all the ocular structures to be obtained. Moreover, the US exam does not require sedation and it can be performed on conscious animals just after the instillation of eye anesthetic drops. In the authors' opinion, ultrasonography of the eye should become a routine in the examination of Loggerhead sea turtles.

Received April 1, 2019

REFERENCES

- ARENCEBIA, A., RIVERO M.A., DE MIGUEL I., CONTRERAS S., CABRERO A. & ORO'S J., 2006: Computed tomographic anatomy of the head of the loggerhead sea turtle (*Caretta caretta*). *Research in Veterinary Science* **81**, 165–169
- BARTOL, S. M. & MUSICK J.A., 2002: Sensory Biology of sea turtle. In: *The Biology of Sea Turtles*, Volume II cap. 3, 80-99
- BRUDENALL, D.K., SCHWAB I.R. & FRITSCHES K.A., 2008: Ocular morphology of the Leatherback sea turtle (*Dermochelys coriacea*). *Vet Ophthalmol.* **8**, 99-110.
- CROGNALE, M. A., ECKERT S. A., LEVENSON D. H. & HARMS C. A., 2008: Leatherback sea turtle *Dermochelys coriacea* visual capacities and potential reduction of bycatch by pelagic longline fisheries. *Endang Species Res* **5**, 249–256.
- DAR, M., TIWARI D. K., PATIL D. B. & PARIKH, P. V., 2013: B-scan ultrasonography of ocular abnormalities: a review of 182 dogs. *Iranian Journal of Veterinary Research* **15**, 122-126
- DE MAJO M., MACRI F., MASUCCI M., COCI G., PENNISI M.G., 2016: Clinical ultrasonography in loggerhead sea turtles (*Caretta caretta*): imaging of pathological features. *Veterinari Medicina*, **61**, 155–161
- HOLLINGSWORTH, S. R., HOLMBERG B. J., STRUNK A., OAKLEY A. D., SICKAFOOSE L. M. & KASS P. H., 2007: Comparison of ophthalmic measurements obtained via high-frequency ultrasound imaging in four species of snakes. *American Journal of Veterinary Research*, **68**, 1111-1114.
- HOCHSCHEID, S., TRAVAGLINI A., MAFFUCCI F., G. C. HAYS, F. BENTIVEGNA, 2013: Since turtles cannot talk: What beak movement sensors can tell us about the feeding ecology of neritic loggerhead turtles, *Caretta caretta*. *Mar. Ecol.* **34**, 321-333.
- HOCHSCHEID, S., KASKA, Y. & PANAGOPOULOU, A. (Eds.), 2018: *Sea Turtles in the Mediterranean Region: MTSG Annual Regional Report 2018*. Draft Report of the IUCN-SSC Marine Turtle Specialist Group, 2018

- İŞLER C. T., ALTUĞ M., CANTEKİN Z., ÖZSOY Ş. Y., YURTAL Z. & DEVECİ M. Z. Y., 2014: Evaluation of the eye diseases seen in Loggerhead Sea turtle (*Caretta caretta*). *Revue Méd. Vét.*, **165**, 9-10.
- IUCN/SSC International Union for Conservation of Nature and Natural Resources/Species Survival Commission 2002 IUCN red list of threatened species. IUCN, Balmar, Arlington, VA, available at www.redlist.org
- JONES, M. E. H., WERNEBURG, I., CURTIS N., PENROSE R., O'HIGGINS P., FAGAN M. J. & EVANS S. E., 2012: The Head and Neck Anatomy of Sea Turtles (Cryptodira: Chelonioida) and Skull Shape in Testudines, *PLOS ONE* **7**, Issue 11.
- LAURIDSEN, H., DA SILVA M. O., HANSEN K., JENSEN H. M., WARMING M., WANG T. & PEDERSEN M., 2014: Ultrasound imaging of the anterior section of the eye of five different snake species. *BMC Veterinary Research* **10**, 313.
- LAZAR, B. & GRAČAN R., 2011: Ingestion of marine debris by loggerhead sea turtles, *Caretta caretta*, in the Adriatic Sea. *Marine Pollution Bulletin*, **62**, 43-47
- LEHMKUHL, R. C., ALMEIDA M. F., MAMPRIM M. J. & VULCANO L. C., 2010: B-mode ultrasonography biometry of the Amazon Parrot (*Amazona aestiva*) eye. *Vet Ophthalmology* **13**, 26-28.
- MACKEY, C.S. & MATOON J.S., 2015: The Eye. In: MATOON J.S. AND NYLAND T.G. *Small animal diagnostic ultrasound*. 3rd Ed., p. 128-154.
- MADER, D. R., COLITZ C. R. H., STACY B. A. & WINEKEN J., 2017: Special Senses. In MANIRE C.A., NORTON T.M., STACY B.A., INNIS C.J., HARMS C.A.: *Sea Turtle Health & Rehabilitation*, J.Ross Publishing, p. 465-480.
- Mathger L. M., Litherland L. And Fritsches K. F. 2007: An Anatomical Study of the Visual Capabilities of the Green Turtle, *Chelonia mydas*. *Copeia* (1), p. 169-179.
- MAFFUCCI F., D'ANGELO I., HOCHSCHEID S., CIAMPA M., DE MARTINO G., TRAVAGLINI A., TREGLIA A. & BENTIVEGNA F., 2013: Sex ratio of juvenile loggerhead turtles in the Mediterranean Sea: Is it really 1:1? *Mar. Biol.* **160**, 1097-1107.
- MENNONNA, G., MURINO C., MAFFUCCI F., AFFUSO A., DE GIROLAMO P., HOCHSCHEID S. & MEOMARTINO L., 2015: The Role of Diagnostic Imaging In Loggerhead Sea Turtle (*Caretta caretta*) Conservation, *Proceeding of the IX International Symposium On Wild Fauna Košice (Slovakia)*.
- MEOMARTINO, L., PASOLINI M. P., LAMAGNA B., MENNONNA G., AULETTA L., MURINO C., DELLAVALLE G. & ESPOSITO L., 2018: Ocular ultrasonographic and biometric features of European brown hares (*Lepus europaeus*). *Anat Histol Embryol.* **47**, 250-253.
- MINGOZZI, T., MASCIARI G., PAOLILLO G., PISANI B., RUSSO M. & MASSOLO A., 2007: Discovery of a regular nesting area of loggerhead turtle *Caretta caretta* in southern Italy: a new perspective for national conservation; *Biodiversity and Conservation* **16**, 3519-3541.
- NORTHMORE, D. P. M. & GRANDA A. M. 1991: Ocular dimensions and schematic eyes of freshwater and sea turtles. *Visual Neuroscience*, **7**, 627-635.
- OLIVER, L. J., SALMON M., WYNEKEN J., HUETER R. & CRONIN T.W., 2000: Retinal Anatomy of hatchling sea turtles: Anatomical specializations and behavioral correlates. *Marine and Freshwater Behaviour and Physiology* **33**, 233-248.
- PEASE, A., BLANVILLAIN G., ROSTAL D., OWENS D. & SEGARS A., 2010: Ultrasound imaging of the inguinal region of adult male loggerhead sea turtles (*Caretta caretta*); *Journal of Zoo and Wildlife Medicine* **41**, 69-76
- PEASE, A., DI BELLO A., RIVERA S. & VALENTE A. L. S., 2017: Diagnostic Imaging- In *Sea Turtle Health and Rehabilitation*, Chapter: 6, Publisher: J. ROSS, Editors: C.A. MANIRE, T.M. NORTON, B.A. STACY, C.J. INNIS, C.A. HARMS, pp.123-146.
- PENNINCK, D., DANIEL, G. B., BRAWER, R., & TIDWELL, A. S., 2001: Cross-sectional imaging techniques in veterinary ophthalmology. *Clinical Techniques in Small Animal Practice*, **16**, 22-39.
- RAPOSO, A.C.S., MURAMOTO C., PIRES T.T., DÓREA NETO F.A., BRITO V.J.S.C. & ORIÀ A.P., 2017: Normal sonographic aspects of the eye in healthy sea turtles. Poster 16, Abstracts: Annual Scientific Meeting of the European College of Veterinary Ophthalmologists, Estoril, Portugal. *Veterinary Ophthalmology* **20**, 4, E1-E14.
- SANTOS, R. G., ANDRADES R., BOLDRINI M. A. & MARTINS A. S., 2015: Debris ingestion by juvenile marine turtles: An underestimated problem, *Marine Pollution Bulletin* **93**, 37-43
- SOMMA, AT, LIMA L, LANGE RR, TURNER-GIANNICO A & MONTIANI-FERREIRA F., 2015: The eye of the red-eared slider turtle: morphologic observations and reference values for selected ophthalmic diagnostic tests. *Vet Ophthalmol.* **18** Suppl **1**, 61-70.
- SPAULDING, K., 2008: Eye and Orbit- In *Atlas of small animal Ultrasonography*, Capter 2, Editors: D. PENNINCK & M.A. d'ANJOU, 1st Edn., Iowa, USA, Blackwell Publishing Co., p. 49-90.

- THAÍIS, R. W. N. S., CAMPOS T. P. S., PERES G. F. GONÇALVES R. H. S., FERRAZ P. E. B., NÉSPOLI V. R. F. & SOUSA A. P. R., 2014: Intraocular pressure, ultrasonographic and echobiometric findings of juvenile Yacare caiman (*Caiman yacare*) eye. *Veterinary Ophthalmology* **18**, s1.
- VALENTE, S. A. L., CUENCA R., PARGA M. L., LAVÍN S., FRANCH J. & MARCO I., 2006: Cervical and coelomic radiologic features of the loggerhead sea turtle, *Caretta caretta*. *The Canadian Journal of Veterinary Research* **70**, 285–290.
- VALENTE, S. A. L., 2007: Diagnostic Imaging in Loggerhead turtle (*Caretta caretta*). Master's Thesis Universitat Autònoma de Barcelona.
- WYNEKEN, J., 2001: Sense Organs- In: *The Anatomy of Sea Turtles*, p. 146-152.

SUMMARY

Normal ultrasonographic features of loggerhead (*Caretta caretta*) eyes

G. Mennonna, B. Lamagna, A. Affuso, A. Greco, F. Micieli, D. Costanza,
S. Hochscheid & L. Meomartino

Fifteen Loggerhead sea turtles admitted to the Marine Turtle Research Center of the Anton Dohrn Stazione Zoologica of Naples and with healthy eyes underwent ocular ultrasonography in order to assess the normal features and dimensions of the eyes. Polar axis (PA), equatorial axis (EA), corneal thickness (CT), anterior chamber depth (ACD), lens thickness (LT), and vitreous chamber depth (VCD) were measured. The sample was composed of 11 sub-adults and 4 juveniles with a mean SCL of 47.18 cm (± 10.22 ; range 33.2-61.0 cm) and a mean BW of 18.79 kg (± 12.6 ; range 6-32.7 kg). Compared to mammals, the ocular globes in these species have a spheroidal shape in which the PA is shorter than EA, a lesser pronounced convexity of the cornea and relatively small lens. Results show that ocular dimensions, in particular PA ($p < 0.01$), EA ($p < 0.01$), LT ($p = 0.01$) and VCD ($p < 0.01$) were correlated with body weight. In these animals several eye diseases are described, so knowing the normal features and dimensions of the eye allows a quicker diagnosis. Ultrasonographic exam performed using general purpose devices was demonstrated to be feasible in this species and must be considered particularly useful when the transparency of the anterior portion of the eye is lost.