

NONCARDIOGENIC PULMONARY EDEMA AFTER CESAREAN SECTION

VESNA VUCELIĆ and ŽELJKO VUČIČEVIĆ

Sestre milosrdnice University Hospital Centre, University of Zagreb School of Medicine, University Department of Medicine, Department of Intensive Care Medicine, Zagreb, Croatia

Acute dyspnea during and after pregnancy should bring a number of important conditions to the mind of a physician. Pulmonary embolism, amniotic fluid embolism, pneumonia, aspiration and pulmonary edema must be considered. Although pulmonary edema is a very rare condition, the most common contributing factors include the administration of tocolytic agents, underlying cardiac disease, iatrogenic fluid overload and preeclampsia. We report on a case of noncardiogenic pulmonary edema in a 36-year-old woman a few hours after cesarean section. The acute event was probably due to iatrogenic fluid overload combined with hemodynamic effects of oxytocin in interaction with hemodynamic changes at the end of pregnancy. The patient was successfully treated with diuretics and oxygen therapy, and after a few hours her chest radiograph and respiratory status were normal.

Key words: noncardiogenic pulmonary edema, cesarean section, iatrogenic fluid overload

Address for Correspondence: Vesna Vucelić, MD
Sestre milosrdnice University Hospital Centre
University Department of Medicine
Department of Intensive Care Medicine
Vinogradska cesta 29
HR-10000 Zagreb, Croatia
Phone: +385 1 3787 955; Fax: +385 1 3787 788
Mobile phone: +385 98 613 826;
E-mail: vesnavucelic@gmail.com

INTRODUCTION

Pulmonary edema is a rare complication in pregnancy and it can present in the antepartum, intrapartum and postpartum period. The most common causes are preexisting cardiac disease (25.5%), cardiac failure secondary to tocolytic use (25.5%), iatrogenic fluid overload (21.5%) and preeclampsia (18%) (1,2). We must also keep in mind sepsis and multiple gestations. In total, 0.08% of pregnancies are complicated by acute pulmonary edema (3). The accumulation of fluid in the interstitial and alveolar space can impair gas exchange. Early recognition by health care providers and appropriate interventions are essential (4).

We present a case of acute noncardiogenic pulmonary edema in a 36-year-old female following cesarean section, which was successfully treated with diuretics and oxygen therapy.

CASE REPORT

A 36-year-old woman was transferred from Department of Gynecology and Obstetrics to our Intensive care unit (ICU) due to progressive dyspnea after cesarean section. She had no history of cardiac disease, hypertension, allergies or respiratory tract infection. Three weeks before delivery, she noticed progressive hand and lower limb swelling. In the 28th week of pregnancy, gestational diabetes was diagnosed and treated with diabetic diet. During 2011, she was treated for ovarian hyperstimulation syndrome with consequential chronic, small, left pleural effusion. This was her second, spontaneous pregnancy. Day before and on the day of surgery, she received in total 2500 mL of saline infusion, followed by 520 mL of concentrated red blood cells and 35 IU of oxytocin i.v. The newborn's Apgar score was 10/10. Eight hours later, she started to complain of dyspnea and cough.

Upon arrival to the ICU, physical examination showed reduced breath sounds, crepitations on the right side of the lungs, tachycardia up to 110 bpm, blood pressure of 150/90 mm Hg, respiratory rate of 25 breaths/min, and oxygen saturation on pulse oxymetry of 89% on room air. Apart from sinus tachycardia, the electrocardiogram was normal. An urgent chest x-ray was done in Fowler's position and was indicative of pulmonary edema with small, chronic left pleural effusion (Fig. 1). Echocardiography was within the normal limits. Laboratory tests revealed only slightly increased values of white blood cells, C-reactive protein, and D-dimers. Procalcitonin level was normal. Capillary blood gas analysis was as follows: pH 7.48, pCO₂ 3.6 kPa, base excess -2.0 mmol/L, bicarbonates 19.9 mmol/L, pO₂ 6.89 kPa, and oxygen saturation 89%.

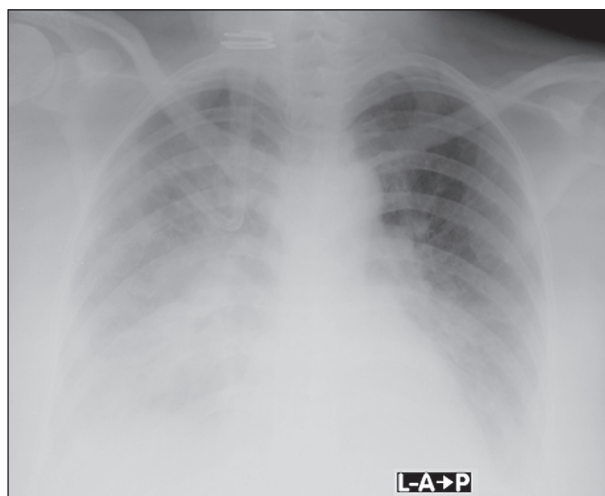


Fig. 1. Noncardiogenic pulmonary edema with small left pleural effusion.

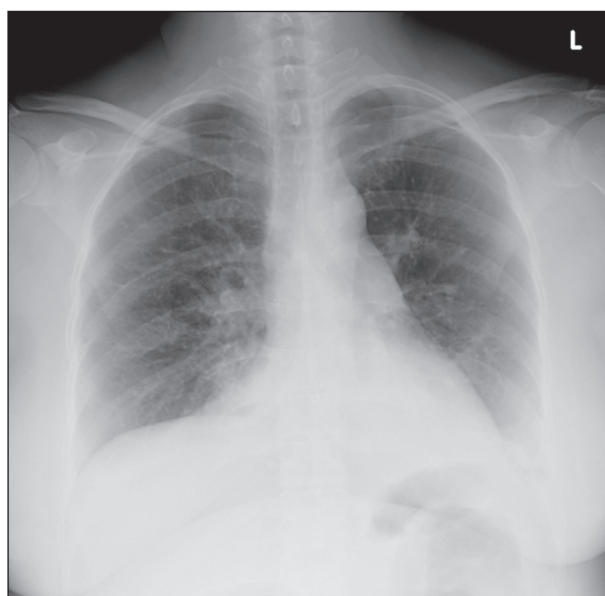


Fig. 2. Follow up radiograph: resolved pulmonary edema 24 hours after therapy.

The immediate treatment consisted of oxygen (4 L/min by nasal catheter), 40 mg of furosemide intravenously, and low molecular weight heparin prophylaxis. Diuretic therapy was continued for the next 24 hours until the total urine output reached 5500 mL. Two days later, clinical and laboratory findings were normal, and chest x-ray showed complete resolution of pulmonary edema. Oxygen saturation was 96% on room air, and the patient was discharged from the hospital.

DISCUSSION

As mentioned before, during delivery there are many causes of acute dyspnea of cardiogenic and noncardiogenic origin. Regardless of its low incidence, morbidity and mortality are significant (5). As in our patient, the most common cause of pulmonary edema is iatrogenic fluid overload. A series of physiologic events result in major alterations in intravascular volume. Blood volume increases by 45 percent by the third trimester of pregnancy, intracapillary pressure rises, intravascular oncotic pressure falls secondary to hemodilution, and cardiac output increases by 1 to 1.5 L/min. These hemodynamic changes are a consequence of decreased excretion of water and sodium that occurs due to the effects of the gravid uterus (6,7). Rapid infusion of 0.9% saline solution, transfusion of concentrated red blood cells with preexisting increased blood volume, and salt and water retention secondary to the administration of oxytocin, made our patient volume overloaded. Oxytocin causes water intoxication due to its antidiuretic effect, usually when it is administered in high doses (40-50 IU) and combined with fluid overload. Therefore, a slow intravenous drip of oxytocin is recommended to avoid this adverse effect (4,8,9). Echocardiography should be the key tool to exclude the silent cardiac disease (4). Once diagnosed, patients should be managed with oxygen therapy, diuretics and close observation. A small percentage of patients may need mechanical ventilation.

CONCLUSION

Acute pulmonary edema after delivery has a wide variety of etiologies, and it can be a life-threatening complication. Appropriate resuscitation is a priority. This syndrome responds rapidly to diuretics and oxygen administration, and clinical improvement is normal within 24 hours.

R E F E R E N C E S

1. Farrer J, Sullivan JT. Pulmonary edema in pregnancy. In: Pacheco LD, Saade GR, Hankins GDV, eds. *Maternal Medicine*. Fali grad izdanja: McGraw-Hill, 2015; 137-55.
2. Popović-Grle S, Vrbica Ž, Turčić P. Plućne bolesti i trudnoća. In: Đelmiš J, Orešković S *et al.* *Fetalna medicina i opstetricija*. Zagreb: Medicinska naklada, 2014; 504-16. (in Croatian)
3. Dunne C, Meriano A. Acute postpartum pulmonary edema in a 23-year-old woman 5 days after cesarean delivery. *CJEM* 2009; 11: 178-81.
4. Tandale SR, Patil SS, Raje D, Siddiqi M. Acute pulmonary edema following caesarean delivery. *J Clin Case Rep* 2015; 5: 1. Available at URL: <http://dx.doi.org/10.4172/2165-7920.1000481> (accessed on Jan 27, 2015)
5. Ho MP, Cheung WK, Tsai KC. Acute postpartum pulmonary edema: a case report. *J Emerg Crit Care Med* 2010; 21: 157-60.
6. Bhattacharya AK. A 24-year-old woman with pulmonary edema after labor and delivery. *Lung India* 2006; 23: 133-4.
7. Vrsalović M. Kardiovaskularne bolesti tijekom trudnoće. In: Košec V, Kuna K, eds. *Intrapartalni nadzor*. Zagreb: Medicinska naklada, 2017; 182-8. (in Croatian)
8. Heytens L, Camu F. Pulmonary edema during cesarean section related to the use of oxytocic drugs. *Acta Anaesthesiol Belg* 1984; 35: 155-64.
9. Prueksaritanond S, Ali AM, Aronu GN *et al.* An uncommon cause of shortness of breath in a young puerpera. *Case Rep Obstet Gynecol* Volume 2013, Article ID 710620. Available at URL: <http://dx.doi.org/10.1155/2013/710620> (accessed on Mar 5, 2013)

S A Ž E T A K

NEKARDIOGENI EDEM PLUĆA NAKON CARSKOG REZA

V. VUCELIĆ i Ž. VUČIČEVIĆ

Klinički bolnički centar Sestre milosrdnice, Sveučilište u Zagrebu, Medicinski fakultet, Klinika za unutarnje bolesti, Zavod za intenzivnu medicinu, Zagreb, Hrvatska

Pojava akutne dispneje za vrijeme i nakon trudnoće treba pobuditi sumnju na nekoliko važnih diferencijalnih dijagnoza kao što su plućna tromboembolija, embolija amnionskom tekućinom, pneumonija, aspiracija i plućni edem. Plućni edem se javlja rijetko i obično je precipitiran tokolizom, već postojećom bolesti srca, volumnim preopterećenjem ili preeklampsijom. Opisujemo slučaj 36-godišnje bolesnice s nekardiogenim edemom pluća koji se manifestirao nekoliko sati nakon carskog reza kao rezultat volumnog opterećenja te istodobnog antidiuretskog djelovanja oksitocina i hemodinamskih promjena pred kraj trudnoće. Bolesnica je uspješno liječena diureticima i oksigenoterapijom. Nekoliko sati kasnije kontrolna slika srca i pluća i respiracijski status bili su normalni, a bolesnica nedugo zatim otpuštena iz bolnice.

Ključne riječi: nekardiogeni edem pluća, carski rez, jatrogeno volumno preopterećenje