

## TUMOR ANTIGENS IN PROSTATE CANCER STRESSFUL COMMUNICATIVE PROBLEMS OF MODERN MAN

### TUMORSKI ANTIGENI U KARCINOMU PROSTATE, STRESNI KOMUNIKATIVNI PROBLEMI SUVREMENOG ČOVJEKA

*Tvrтко Hudolin<sup>1</sup>, Ahmad El-Saleh<sup>1</sup>, Ljiljana Hlupić<sup>2</sup>, Željko Kaštelan<sup>1</sup>*

*Department of Urology, Zagreb University Hospital Center, Zagreb, Croatia<sup>1</sup>; Department of Pathology, Zagreb University Hospital Center, Zagreb, Croatia<sup>2</sup>*

*Odjel za urologiju, Klinički bolnički centar Zagreb, Zagreb, Hrvatska<sup>1</sup>; Odjel za patologiju, Klinički bolnički centar Zagreb, Zagreb, Hrvatska<sup>2</sup>*

#### *Abstract*

This study investigated the immunohistochemical expression of the cancer testis antigen SSX in prostate cancer. SSX expression, with varying staining intensities, was observed in 83% of cancer samples. Substantial heterogeneity of expression was observed within individual samples. SSX expression was significantly higher in Gleason score 7 than in Gleason score 6 cancer ( $p=0.008$ ). Tumours demonstrating capsular invasion had higher SSX expression than did tumours without capsular invasion ( $p=0.005$ ). SSX expression did not correlate significantly with prostate-specific antigen level or tumour size. Further studies are needed to investigate SSX expression in prostate cancer and its potential implications for diagnosis and immunotherapy.

#### *Sažetak*

U ovom radu istraživali smo imunohistokemijsku ekspresiju karcinom testis antigena SSX u karcinomu prostate. SSX ekspresija različitog intenziteta je pokazana u 83% uzoraka karcinoma. Pokazana je također i značajna heterogenost ekspresije unutar individualnih uzoraka. SSX ekspresija je bila značajno više u Gleason zbroju 7, nego u Gleason zbroju 6 karcinoma prostate ( $p=0.008$ ). Tumori koji su zahvatili kapsulu prostate imali su također značajniju SSX ekspresiju nego tumori koji nisu zahvatili kapsulu ( $p=0.005$ ). SSX ekspresija nije korelirala značajno s vrijednostima prostata-specifičnog antigena ili veličinom tumora. Daljnje studije su potrebna da bi se istražila ekspresija SSX antigena u karcinomu prostate s potencijalnim implikacijama i na dijagnostiku i na imunoterapiju karcinoma prostate.

#### **Introduction**

SSX is one of the cancer testis antigens (CTA), a group of proteins expressed in a limited number of healthy tissues and in a large variety of tumours of unrelated histological origins /1/. CTA have been shown to induce humoral and cellular immune responses. Therefore, a number of them are under evaluation as vaccines in active specific tumour immunotherapy /2/, /3/, /4/. Among the CTA, MAGE-A3/4, LAGE-1, NY-ESO-1 and SSX have been shown to be expressed in patients with prostate cancer /5/, /6/, /7/. Thus, immunotherapy for prostate cancer targeting one or a combination of these antigens may be possible. The generation of specific monoclonal antibodies (mAb) has per-

mitted the identification of CTA in tumour tissues. The expression of these antigens is frequently focal /8/, making it necessary to explore relatively large portions of tumour tissues in order to obtain precise data. In this study, we used immunohistochemistry (IHC) to investigate the expression of SSX in tissue sections of the whole organ and correlated SSX expression with prostate-specific antigen (PSA) levels and histological tumour features important for determining prognosis and selecting treatment.

#### **Patients and methods**

### Tissue samples

Prostate specimens from 53 patients (mean age 66, range 55-76 years) who underwent radical prostatectomy at the Urology Clinic of the Zagreb Clinical Hospital Center from 2005 to 2007 were assessed in this study. The patients' PSA values, determined before surgery, ranged from 0.2 to 28.6 ng/mL (mean 9.05 ng/mL). In all patients, before surgery, the existence of distant metastases was ruled out by preoperative diagnostic testing, including complete laboratory tests, thorax radiography, computed tomography of the pelvis, bone scintigraphy if necessary, and, depending on the results of the latter, targeted bone radiography. The existence of metastases in regional lymph nodes was ruled out by immediate intraoperative and subsequent histopathological analysis of tissues embedded in paraffin blocks. In the patients studied, the clinical disease stages ranged from T1 to T3N0M0 /9/.

### Immunohistochemistry

Entire prostates, surgically removed together with the base of the seminal vesicles, were formalin-fixed and embedded in paraffin blocks that were cut into 4 - 5µm sections and HE stained in order to determine a histopathological diagnosis. Gleason grade and score were determined in a standard manner /10/. One patient (2%) had Gleason score 5 cancer, 19 (36%) had Gleason score 6 cancer, 31 (58%) had Gleason score 7 cancer, and 2 (4%) had Gleason score 8 cancer. The mAb anti-SSX (E3AS), a gift from Dr. Diederik de Bruijnwas (University Medical Center Nijmegen, Netherlands) was used for immunohistochemical staining /11/. Tissue sections of 3-5 µm thickness were cut from paraffin-embedded tissue blocks and placed on object slides (Menzel-Glaser, Germany). Slides with tissue sections were incubated for 20 minutes at 60°C. Sections were then deparaffined and pretreated for 3x5 minutes in 10 mmol/L EDTA pH 9.0 in a microwave oven at 800 W power. Subsequently, tissue slides were

washed with PBS-buffer (pH 7.2) and endogenous peroxidase activity was blocked by a 5-minute treatment with H<sub>2</sub>O<sub>2</sub> (Dako-No.S2023). Slides were then washed with PBS-buffer and incubated for 30 minutes with SSX2 mAb, E3AS diluted at 1:200 at room temperature. After a wash in PBS-buffer, the secondary biotinylated antibody (Dako-No.K0690) was added for a 30-minute incubation. Slides were then washed with PBS-buffer and treated with streptavidin-horseradish peroxidase (Dako-No.K0690) for 30 minutes. Tissue sections were washed once more in PBS-buffer and then Chromogen (Dako-No.K3468) was added for 5 minutes. Slides were washed in distilled water, stained with hemalaun (Dako-No.S2020) for 1 minute, washed with water, dehydrated with alcohol (96%), cleared with xylene and mechanically covered. Testes tissues expressing SSX were used as a positive control throughout the study, whereas normal prostatic tissues and unstained tumour cells served as a negative control. IHC staining results were semiquantitatively expressed as follows: 1) negative response (-): no staining in tumour cells; 2) weak positive response (+): up to 10% of tumour cells positive; 3) moderate positive response (++) : 11 – 50% of tumour cells positive; 4) strong positive response (+++): over 50% of tumour cells positive.

### Statistical analysis

Statistical analysis was carried out using StatSoft Statistica data analysis software, version 6.1. The chi-square test and Spearman rank correlation were used throughout this work, and differences were considered statistically significant at 5% (p<0.05).

### Results

Expression of SSX, as detectable by E3AS mAb staining, was observed in 44/53 (83%) of carcinoma samples, with varying staining results. In all cases IHC staining was only detectable in the cytoplasm (Fig.1).

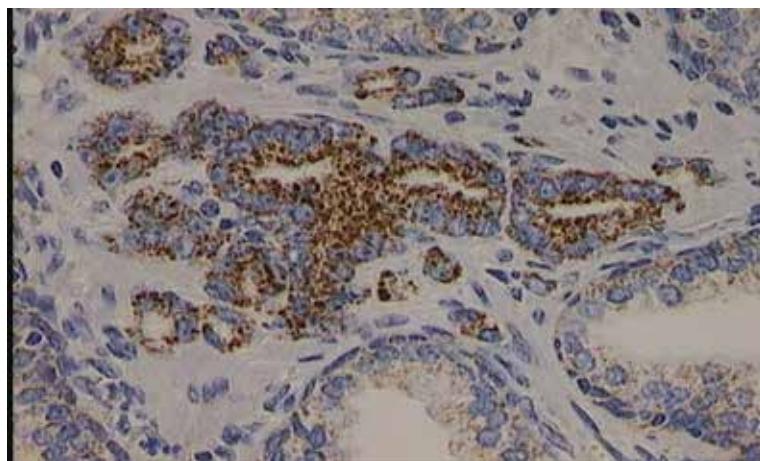


Figure 1. IHC expression of SSX in cytoplasm of prostate tumour cells (x400).

Substantial heterogeneity could be observed in individual tissue samples, with areas of strong positivites co-existing with SSX-negative areas.

However, positivites involving more than 50% of tumour cells (+++) were observed in 18/53 (34%) cases (Table 1).

Table 1. Distribution of SSX expression levels in cancerous prostatic tissue amongst all patients and correlation of SSX expression with Gleason score and prostatic capsule status. Data represent numbers and (in parentheses) percentages of patients. The data for Gleason scores 5 and 8 are not shown because the number of patients with these scores (3) was too small for statistical analysis. P values indicate significance levels for differences in SSX expression.

SSX Expression Level	Total Study Population	Gleason Score		Prostatic capsule Status	
		6	7	negative	positive
0	9 (17%)	7 (37%)	1 (3%)	9 (26%)	0
+	9 (17%)	4 (21%)	4 (13%)	8 (23%)	1 (6%)
++	17 (32%)	4 (21%)	12 (39%)	11 (31%)	6 (33%)
+++	18 (34%)	4 (21%)	14 (45%)	7 (20%)	11 (61%)
<b>Total</b>	<b>53</b>	<b>19 (36%)</b>	<b>31 (58%)</b>	<b>35 (66%)</b>	<b>18 (34%)</b>
		<b>p=0.008</b>		<b>p=0.005</b>	

When comparing Gleason score and SSX expression, the chi-square test showed that patients with Gleason score 7 had in most cases higher levels of SSX expression than did patients with Gleason score 6 ( $p=0.008$ ). Tumours that had infiltrated the prostatic capsule had in most cases higher levels of SSX expression than did those that had not infiltrated the capsule ( $p=0.005$ ) (Table 1). SSX expression did not correlate significantly with PSA level ( $p=0.13$ ) or with tumour size (range 0.5-4 cm, mean 2.4 cm) ( $p=0.22$ ). The number of patients with seminal vesicle invasion (6) was too small for adequate statistical analysis. In some samples, where tumour tissue coexisted with areas of benign prostatic hyperplasia (BPH), SSX expression was also detectable in some of the areas of BPH, although staining was less intense in these areas and involved low numbers of cells.

### Discussion and conclusion

It has been shown that SSX is a prostate cancer antigen and that it can be immunologically recognized in patients with prostate cancer /12/. Proving that SSX is present in prostate cancer samples and that it can be recognized by immune system provides a basis for possible immunotherapy using vaccination with this antigen, alone or in combination with other CTA. Expression of CTA is often focal, and within a single tissue sample, areas with strong positivities may co-exist with CTA-negative areas. In prior studies, we showed that this was the case for MAGE-A1, MAGE-A3/4 and NY-ESO-1 /13/ expression in prostate cancer, and in the present study, we have shown that is also the case for SSX expression in prostate cancer. Performing staining of sections of the whole excised prostate allowed us to carry out a detailed evaluation of SSX expression at the protein level, together with nearby areas of normal and BPH tissue. In contrast, studies limited to bioptic materials or tissue microarrays /14/ might result in underestimation of CTA expression. We found that cancers with higher Gleason scores had higher levels of SSX expression; we also found that SSX expression was higher in prostate cancers that invaded the prostate capsule. Recently, it has been demonstrated that expression of SSX—like the expression of other members of the CTA group—is elevated in metastatic disease /15/, /16/. The latter finding, together with our results, leads us to the conclusion that SSX expression is higher in more advanced or more aggressive forms of prostate cancer. This conclusion is in accordance with

previous studies that have shown CTA expression to be higher in less differentiated, higher-grade tumours (e.g., in high-grade bladder cancer) /17/. At our institution radical prostatectomy is usually performed only in patients with a Gleason score of 7 or less because of the higher likelihood of organ-confined disease; therefore, we only had limited access to tumours with higher Gleason scores. Although our study did include some patients with Gleason score 8, the number was too small for adequate statistical analysis. Bioptic samples of tumours with Gleason scores 8-10 were excluded because of the known heterogeneity of CTA expression. In our study, neither PSA level nor tumour size correlated significantly with SSX expression. A PSA value  $> 4$  ng/mL is suspicious for prostate cancer, but the PSA level can be influenced not only by cancer but by other factors such as inflammation and BPH. Furthermore, it has been shown that patients with a PSA level of  $< 4$  ng/mL, which is considered to be “normal,” can have aggressive, high-grade forms of prostate cancer /18/. SSX expression has also been detected in BPH in the presence or absence of neoplastic transformation, although in low numbers of cells. Sugita et al. /19/ have reported expression of the NY-ESO-1 gene, a member of the CTA group, in 42% of breast cancers together with weak but detectable expression in as much as 68% of benign breast tissue. They suggested that benign lesions might actually represent, at least in part, early stages of malignant transformation. The eventual pre-cancerous nature of SSX-positive cells in BPH deserves careful study. SSX is a recognized prostate cancer tumour antigen, although weak SSX expression has also been detected in some samples of BPH. We found that SSX expression in prostate cancer increased with higher Gleason scores and with the presence of capsular invasion—i.e., in more aggressive forms of the disease. Further studies are needed to investigate SSX expression in prostate cancer (especially in more advanced forms of the disease) and its potential implications regarding both diagnosis and immunotherapy.

### References

- /1/ Zendman AJ, Ruiter DJ, Van Muijen GN. Cancer/testis-associated genes: identification, expression profile, and putative function. *J Cell Physiol* 2003;194:272-88

- /2/ Marchand M, Punt CJ, Aamdal S, Escudier B, Kruit WH, Keilholz U et al. Immunisation of metastatic cancer patients with MAGE-3 protein combined with adjuvant SBAS-2: a clinical report. *Eur J Cancer* 2003;39:70-7
- /3/ Thurner B, Haendle I, Röder C, Dieckmann D, Keikavoussi P, Jonuleit H et al. Vaccination with mage-3A1 peptide-pulsed mature, monocyte-derived dendritic cells expands specific cytotoxic T cells and induces regression of some metastases in advanced stage IV melanoma. *J Exp Med* 1999;190:1669-78
- /4/ Nestle FO, Alijagic S, Gilliet M, Sun Y, Grabbe S, Dummer R et al. Vaccination of melanoma patients with peptide- or tumor lysate-pulsed dendritic cells. *Nat Med* 1998;4:328-32
- /5/ Hudolin T, Juretic A, Spagnoli GC, Pasini J, Bandic D, Heberer M et al. Immunohistochemical expression of tumor antigens MAGE-A1, MAGE-A3/4 and NY-ESO-1 in cancerous and benign prostatic tissue. *Prostate* 2006;66:13-8
- /6/ Lethé B, Lucas S, Michaux L, De Smet C, Godelaine D, Serrano A et al. LAGE-1, a new gene with tumor specificity. *Int J Cancer* 1998;76:903-8
- /7/ Dubovsky JA, McNeel DG. Inducible expression of a prostate cancer-testis antigen, SSX-2, following treatment with a DNA methylation inhibitor. *Prostate* 2007;67:1781-90
- /8/ Juretic A, Spagnoli GC, Schultz-Thater E, Sarcevic B. Cancer/testis tumour-associated antigens: immunohistochemical detection with monoclonal antibodies. *Lancet Oncol* 2003;4:104-9
- /9/ Greene FL, Page DL, Fleming ID, editors. *Prostate. AJCC Cancer Staging Manual*, 6th ed. New York: Springer Verlag; 2002, 309 p.
- /10/ Eble JN, Sauter G, Epstein JI, Sesterhenn IA, editors. *WHO Pathology and Genetics of Tumours of the Urinary System and Male Genital Organs*. Lyon: IARC Press; 2004, 179 p.
- /11/ dos Santos NR, Torensma R, de Vries TJ, Schreurs MW, de Bruijn DR, Kater-Baats E et al. Heterogeneous expression of the SSX cancer/testis antigens in human melanoma lesions and cell lines. *Cancer Res* 2000;60:1654-62
- /12/ Dubovsky JA, McNeel DG. Inducible expression of a prostate cancer-testis antigen, SSX-2, following treatment with a DNA methylation inhibitor. *Prostate* 2007;67:1781-90
- /13/ Hudolin T, Juretic A, Spagnoli GC, Pasini J, Bandic D, Heberer M et al. Immunohistochemical expression of tumor antigens MAGE-A1, MAGE-A3/4 and NY-ESO-1 in cancerous and benign prostatic tissue. *Prostate* 2006;66:13-8
- /14/ Dubovsky JA, McNeel DG. Inducible expression of a prostate cancer-testis antigen, SSX-2, following treatment with a DNA methylation inhibitor. *Prostate* 2007;67:1781-90
- /15/ Ibidem
- /16/ Nakada T, Noguchi Y, Satoh S, Ono T, Saika T, Kurashige T, et al. NY-ESO-1 mRNA expression and immunogenicity in advanced prostate cancer. *Cancer Immun* 2003;31:3-10
- /17/ Kurashige T, Noguchi Y, Saika T, Ono T, Nagata Y, Jungbluth A et al. NY-ESO-1 expression and immunogenicity associated with transitional cell carcinoma: correlation with tumor grade. *Cancer Res* 2001;61:4671-4
- /18/ Thompson IM, Pauler DK, Goodman PJ, Tangen CM, Lucia MS, Parnes HL et al. Prevalence of prostate cancer among men with a prostate-specific antigen level  $\leq$  4.0 ng per milliliter. *N Engl J Med* 2004;350:2239-46
- /19/ Sugita Y, Wada H, Fujita S, Nakata T, Sato S, Noguchi Y et al. NY-ESO-1 expression and immunogenicity in malignant and benign breast tumors. *Cancer Res* 2004;64:2199-204