

Internal Hernias in Acute Abdomen: Review of Literature and Report of four Cases

Marijan Tepeš¹, Iva Kirac², Elizabet Glavan² and Marko Doko²

¹General Hospital Vukovar, Department of Surgery, Vukovar, Croatia

²»Sestre Milosrdnice« University Hospital Center, Department of Surgery, Zagreb, Croatia

ABSTRACT

Internal hernias are very rare in clinical practice. Because of a wide range of symptoms that can sometimes be non-specific, surgeons often disregard internal hernias in the spectrum of differential diagnosis in acute abdomen. Finding the diagnosis before an internal hernia causes an acute abdomen is sometimes difficult despite modern diagnostic tools. Reason for diagnosis delay is mostly because of wide range of symptoms and variable time period of abdominal pain before patients visit the physician. Furthermore, the delayed diagnosis can put patients in dangerous life threatening condition because internal hernias can cause acute bowel or intestinal obstruction. In such cases high mortality has been recorded so internal hernias presenting as acute abdomen may need operations as soon as possible. Performance of image studies could easily lead to a specific diagnosis and the best surgical strategy. Occasionally, an urgent laparotomy is the only diagnostic procedure and treatment. Here we present four patients with developed acute abdomen due to internal hernia and a course of treatment along with a review of the literature.

Key words: internal hernia, acute abdomen, ileus, intestinal obstruction, emergency

Introduction

Internal hernia is defined as herniation of viscera through natural or unnatural aperture within the peritoneal cavity, which can be congenital or acquired^{1,2}. Internal hernias rarely cause small bowel obstruction with incidence of 0.2–0.9%^{1,3}. Myers classified internal hernias according to their location: paraduodenal (53%), pericecal (13%), within foramen of Winslow (8%), transmesenteric and transmesocolic (mesocolic) (8%), intersigmoid (6%), and retroanastomotic (5%), other 7% are paravesical and pelvic hernias³. In children, transmesenteric (mesocolic) hernias are the most common type of internal hernia, occurring in 35% of this population⁴. The majority of internal hernias originate from congenital abnormalities which have occurred during internal organ rotation, mostly due to abnormalities in their attachments. Other explanations for the development of internal hernias are atrophy of omentum, dilatation of the Winslow foramen, as a result of increased intra-abdominal pressure and finally, iatrogenic due to abdominal surgery⁵. Nonspecific symptoms and variations in their intensity and severity, are charac-

teristic for internal hernias². Many internal hernias are asymptomatic throughout one's life, while others can cause nonspecific symptoms such as intermittent abdominal pain accompanied by nausea or vomiting, especially after large meals. Nonspecific slight pain can often disappear by changing the position. However, symptoms such as obstructive jaundice, biliary colic, secondary pancreatitis and sometimes just palpable abdominal mass can also occur. If internal hernia presents as an acute abdomen, the underlying problem is usually the intestinal obstruction. In such cases, mortality rate of up to 50% has been recorded⁶. Despite various diagnostic methods, which can be helpful in reaching the diagnosis, CT has been proved as the best method for detecting internal hernias even in a symptom free stage. When feasible, urgent CT is the most useful diagnostic method, demonstrating defect location, and/or signs of infrequent congenital anomalies. Finally, treatment of internal hernias consists of closing the defect with sutures or in some cases, application of bio-organic or synthetic mesh. Herein, we report four cases of acute abdomen caused by internal hernias along with the review of literature.

First Case

Thirty one year old male patient was admitted through the emergency surgical service for severe suddenly occurring pain in upper abdomen, which rapidly intensified during several hours, followed by nausea and vomiting. Patient had no history of previous trauma nor abdominal surgery, nor we did find any predisposing factor or incident which could be the cause of the condition. Clinical examination revealed a painful tenderness in the upper abdomen with signs of muscle guarding and poor bowel

movements. Plain abdominal X-ray showed multiple air fluid levels and dilated intestinal loops. Laboratory findings showed only mild leukocytosis. Due to the presentation of acute abdomen emergency laparotomy was indicated. Intraoperatively, incarcerated mesocolic hernia, about 20 cm in diameter, with hernial ring of 6 centimetres in diameter was found, the arrow indicates the diameter of hernial ring (Figure 1). Approximately 100 cm of intestines, part of jejunum and part of ileum was found within the hernial sac. The arrows indicate the border hernia sac (Figure 2).

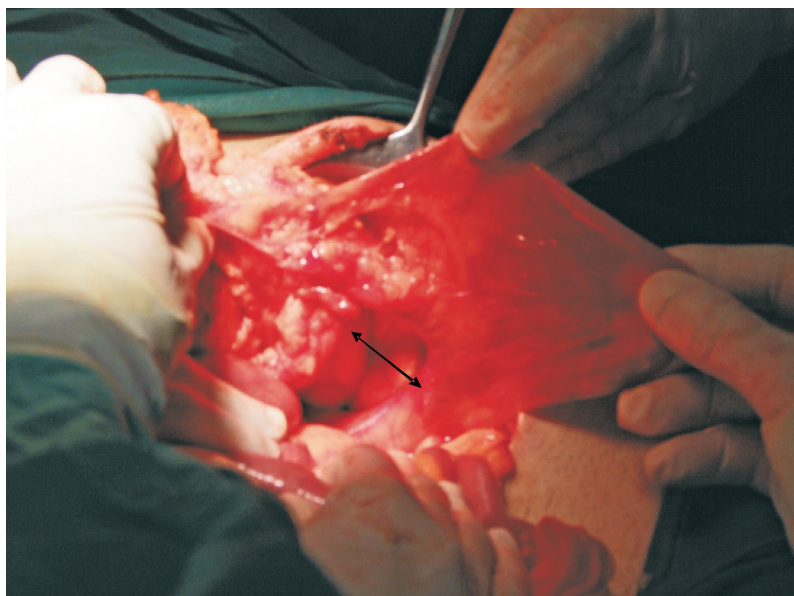


Fig.1. Incarcerated mesocolic hernia, about 20 cm in diameter, with hernial ring of 6 centimetres in diameter.

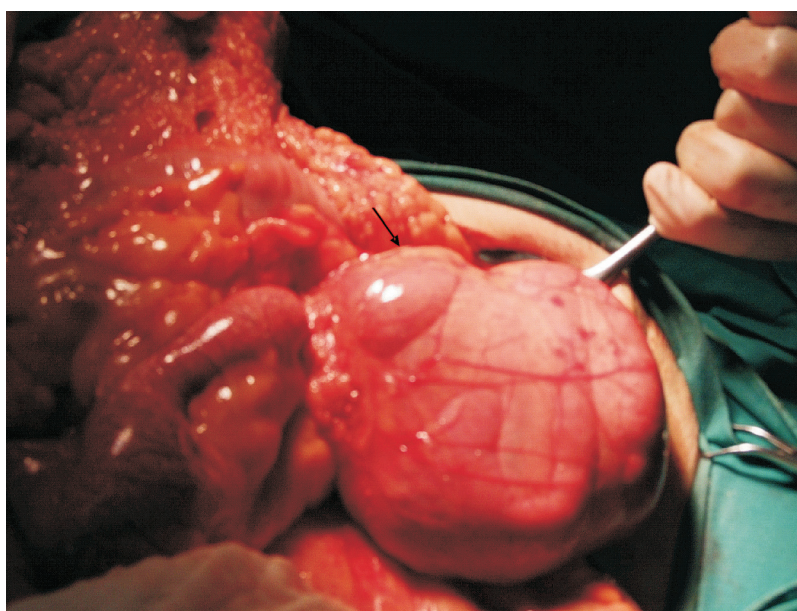


Fig. 2. Approximately 100 cm of intestines, part of jejunum and part of ileum was found within the hernial sac. The arrows indicate the border hernia sac.

Orally from the point of obstruction the bowel wall was thick and dotted with petechiae. A few minutes after desincarceration the incarcerated intestines gained normal colour and peristalsis. We resected the hernial sac and closed the opening with sutures. Postoperative course was uneventful and the patient was discharged on the 7th postoperative day. During the 6 month follow-up period, patient had no disturbances in bowel passage and did not report any abdominal discomfort.

Second Case

Sixty one year old female patient was admitted through the emergency department for severe abdominal pain lasting for a few hours, followed by nausea and vomiting. Patient had a hysterectomy and a lumpectomy on her left breast three years earlier for benign conditions. Due to thrombosis of cervical veins, she was on warfarin anticoagulant therapy. Clinical examination revealed a painful tenderness in the upper abdomen with signs of muscle guarding and poor bowel movements. Plain abdominal X-ray showed multiple air fluid levels and dilated intestinal loops. Laboratory findings showed only mild leukocytosis. CT showed thickening of ileum, after the transition from jejunum to ileum. Due to the presentation of acute abdomen patient was urgently transferred to surgical department and emergency laparotomy was indicated. Intraoperatively, incarcerated mesenteric hernia, about 20 cm in diameter, with hernial ring of 6 centimetres in diameter was found. Since the content of hernial sac 50 cm of ileum was gangrenous, the changed part of ileum was resected and bipolar stoma was formed. Hernial opening was closed with sutures. Postoperative course was uneventful and the patient was discharged on the 10th postoperative day. During the early follow-up period, patient had no disturbances in bowel passage and did not report any abdominal discomfort.

Third Case

This was the case of a sixty six year old male patient who underwent Miles' resection for rectal adenocarcinoma (Dukes C) fifteen months prior to presentation. On previous follow up, 3 months earlier, there were no signs of disease recurrence. His weight loss was considerable in last three months. On the last follow up his CEA level was elevated (64 µg/L) and he was scheduled for a CT the following week. He also had abdominal discomfort which had lasted for a couple of months. In the past couple of days he evacuated only small amounts of stool through. There was no stool output in the 12 hours prior to our exam, abdomen was distended and patient started vomiting. Physical examination revealed distended abdomen was diffusely painful, and peristalsis was pronounced. Patient had no signs of parastomal hernia. On plain abdominal X-ray, a distended loop of small intestines was shown. Patient refused to undergo CT of the abdomen. On follow through X-ray exam the contrast did not pass the jejunum. Despite,

the indication for surgery and receiving the explanation of his current status, patient explicitly refused surgical treatment for the following 16 hours. Initially, unremarkable leukocyte levels and CRP have, while the output on NG tube was over 1400 ml of Miserere. At that point he gave his consent to the operation. Intraoperatively, we found a necrotic loop of ileum, 65 cm in length, which was trapped behind the colostomy and was in torsion. This was not the case of incarcerated parastomal hernia because parastomal hernias are defined as the bulging of peristomal skin indicating the passage of one or more loops of bowel through a fascial defect around the stoma and into the subcutaneous tissues. There were no fascial defects in this case. We resected the loop and formed a terminoterminal ileoileal anastomosis. Due to prolonged preoperative septic state, patient had a protracted stay in ICU. Despite antibiotics and supportive care, patient passed away in ICU due to multiorgan failure.

Fourth Case

Seventy one year old male patient presented with pain in the upper abdomen which lasted for a week. The pain was slightly exacerbated in the last 48 hours, he vomited once, but had regular stools. The patient noticed he had lost weight in the past couple of months. He underwent mitral valve replacement 10 years ago and was referred from a rehabilitation facility where he was recovering after a stroke. Abdomen was slightly distended, painful in the upper parts, peristalsis was pronounced. Digitorectal exam showed normal stool remnants. Apart from modest leukocytosis, laboratory results were unremarkable. Chest X-ray demonstrated a right sided lobar pneumonia. Plain abdominal X-ray showed aeroliquid levels in the upper abdomen. Based on these findings an explorative laparotomy was indicated. Intraoperatively, an adhesion stretched from omentum to small intestines and loops of small intestines were incarcerated in the hole that the adhesion and the omentum formed. Loops were viable, with normal colour and peristalsis. Adhesiolysis and desincarceration were performed. Postoperative recovery was uneventful. Patient received antibiotic treatment for pneumonia and was transferred to Pulmology Department for further treatment. We cannot explain the cause of omental adhesion and small intestine by previous cardiothoracic surgery as well as pneumonia. There is no written evidence that the patient had surgery in the abdomen and there were no signs of surgical intervention in the abdomen.

Discussion

The main problem of internal hernias lies in the unpredictable development of acute intestinal obstruction which is often preceded by a variable period of abdominal discomfort of intangible cause. Timely preoperative diagnosis proved to be the biggest challenge in treating internal hernias and this is the main reason why most internal hernias are diagnosed during explorative laparotomy.

Congenital internal hernias seem to be the most common, with 3:1 male to female ratio, usually affecting younger population¹. However, the prevalence of internal hernia is more common in the general population than previously thought^{7,8}. Chronic symptoms are present in approximately 70% of patients. Nevertheless, 66% of all patients regardless of the manifestation of symptoms eventually develop acute obstruction or strangulation⁹. Sometimes patients have nonspecific symptoms that last for years. Time from onset of symptoms to diagnosis spans from several weeks to a couple of years. In fact, Tong recorded that chronic symptoms can last from 2 months to 20 years before the patient is correctly diagnosed (1.8 years on average)⁹. The patients who have no history of nonspecific symptoms, approximately one third of them, are also at risk of suddenly developing acute abdomen. In our series some patients had a history of intermittent non-specific pain, however rapid progression of symptoms at presentation was observed: vomiting, severe pain and muscle guarding. According to a recent study by Hsiu-Ping Fan, abdominal rebound tenderness, advanced leukocytosis ($>18,000/\text{mm}^3$), or a high level of manual band form ($>6\%$) were the positive predictive factors for bowel ischemia, whereas a history of chronic intermittent abdominal pain was a negative indicator¹⁰. In such cases, delaying the operation with further imaging would not be indicated¹¹. On the other hand, internal hernias can be completely asymptomatic and be diagnosed only during autopsy.

The onset of symptoms of the bowel obstruction in internal hernias might be explained by disproportion in size of hernia ring and large hernial sac with long intestinal segment that can be irreversibly damaged. In our first case, hernial ring was 6 cm in diameter and hernial sac was 20 cm in diameter and contained 100 cm of small intestine. In this case a relatively small hernial ring might be responsible for the sudden and unpredictable obstruction. In the other three cases where hernial openings were wider, there was a history of abdominal discomfort.

CT scan is the method of choice for making a diagnosis of internal hernia in the absence of acute symptoms^{11,12}. CT scan has also high sensitivity in predicting small bowel obstruction, again the time spent in diagnostic trials with the exception of emergency laboratory blood tests and plain abdominal X-ray can affect the outcome of treatment⁷. Furthermore, in most cases of internal hernias CT scans are correctly interpreted only after the surgical procedure¹³.

Time to surgical intervention is extremely important so it is imperative to perform rapid diagnostic studies,

avoiding time lost before surgical indication and this is evident in our second case, in which the operation was delayed by a thorough diagnostic approach, and the third case, in which the patient had been refusing surgical intervention for 16 hours: the consequences were necrosis of the small bowel which required resection. Surgical treatment consists of hernia repair with restoration of normal anatomy if possible, where the defective, unnatural opening, must be closed with sutures or sometimes with application of bio-organic or synthetic mesh¹¹. Hernias through the great omentum are not true hernias because they have no hernial sac; the treatment of such hernias may consist of closing the defect with sutures or removal of part or all of the greater omentum, which we did in second case. Abdominal operations often create new intra-abdominal spaces by disrupting the normal anatomy. Boundaries of these spaces may become potential hernial openings. Attention during these operations should be paid to closing the potential places of incarceration when possible. The incidence of internal hernia is lower after abdominal operations when mesenterial/mesocolic defect was closed with sutures¹⁴. Cruz-Muñoz, in 2079 patients undergoing Roux-en-Y gastric bypass, compared groups with and without closing of mesentery defect with sutures. The group in which the mesentery defect was closed had a significantly lower incidence of internal hernia, than the group in which the mesentery defect was not closed (0.1% vs. 10%)¹⁴. As for technique, there is no difference in outcome results when using intermittent or continuous suturing¹⁵, and there is no consensus on best suturing technique for closure of the defect. After the surgery for internal hernia there were no reports of recurrence of the chronic symptoms and it seems that surgery also reduces the risk of intestinal obstruction and strangulation. Moreover, to our knowledge, recurrence of internal hernia was not recorded after the surgical treatment. Laparoscopic treatment has been established as safe and effective alternative to open approach, with all benefits of minimally invasive surgery^{11,16}. These cases stress the need of considering internal hernias in differential diagnosis of acute abdomen, with a high risk of incarceration and intestinal damage, which requires a prompt reaction to perform rapid diagnostic studies, avoiding time lost before surgical indication, although some critical presentations are absolutely direct indication of laparotomy. According to our experience and considering the potential for development of fatal complications we suggest that the internal hernias should be surgically treated regardless of whether the patient has symptom history or not because of the risk of developing intestinal obstruction^{13,16}.

REFERENCES

1. TAURO LF, VIJAYA G, D'SOUZA CRS, RAMESH HC, SHETTY SR, HEGDE BR, DEEPAK J, Saudi Journal of Gastroenterology, 13 (2007) 141. — 2. FREDIANI S, ALMBERGER M, IACONELLI R, AVVENTURIERI G, MANGANARO F, *Hernia*, 14 (2010) 105. — 3. MA M, (Ed) *Dynamic radiology of the abdomen: normal and pathologic anatomy*. 6th ed. (New York: Springer; 2005). — 4. KUNDARAGI NG, VINAYAGAM S, MUDALI S, *The Indian Journal of Radiology and Imaging*, 24

(2014) 171. — 5. LIU Z, WANG Y, LIANG CH, *Br J Radiol*, 81 (2008) 50. — 6. IRIBARREN MD, VÁZQUEZ AR, PARGA GC, BARREIRO GF, CARDAMAS PD, IRIBARREN NL, GIL PG, *Revista española de enfermedades digestivas: organo oficial de la Sociedad Española de Patología Digestiva*, 101 (2009) 72. — 7. MOON CH, CHUNG MH, LIN KM, *JSL-Soc Laparoend*, 10 (2006) 90. — 8. YOO H, MERGELAS J, SEIBERT D, *J Clin Gastroenterol*, 31 (2000) 226. — 9. TONG RS, SENGUPTA S,

- TJANDRA JJ, ANZ J Surg, 72 (2002) 69. — 10. FAN H-P, YANG AD, CHANG Y-J, JUAN C-W, WU H-P, Surg Today, 38 (2008) 899. — 11. PARMAR B, PARMAR R, Journal of Minimal Access Surgery, 6 (2010) 122. — 12. AKYILDIZ H, ARTIS T, SOZUER E, AKCAN A, KUCUK C, SENSOY E, Int Surg, 7 (2009) 334. — 13. ARMSTRONG O, HAMEL A, GRIGNON B, PELTIER J, HAMEL O, LETESSIER E, LE NEEL JC, ROBERT R ROGEZ JM, Surg Radiol Anat, 29 (2007) 333. — 14. DE LA CRUZ-MUÑOZ N, CABRERA JC, CUESTA M, HARTNETT S, ROJAS R, Surg Obes Relat Dis, 7 (2011) 176. — 15. HOPE WW, SING RF, CHEN AY, LINCOURT AE, GERSIN KS, KUWADA TS, HENIFORD BT, JSLS-J Soc Laparoend, 14 (2010) 213. — 16. BITTNER JG, EDWARDS MA, HARRISON SJ, LI K, KARMIN PN, MELLINGER JD, JSLS-J Soc Laparoend, 13 (2009) 242.

M. Tepeš

*General Hospital Vukovar, Department of Surgery, Županijska 72, 32000 Vukovar, Croatia
e-mail: mtepes@gmail.com*

UNUTARNJE HERNIJE I AKUTNI ABDOMEN: PREGLED LITERATURE I PRIKAZ ČETIRI SLUČAJA

SAŽETAK

Unutarnje hernije su vrlo rijetke u kliničkoj praksi. Zbog velikog raspona simptoma koji katkada mogu biti nespecifični, kirurzi često mogu podcjeniti unutarnje hernije kao dio diferencijalne dijagnoze akutnog abdomena. Pronalazak dijagnoze prije nego što unutarnja hernija uzrokuje akutni abdomen je teško unatoč modernoj dijagnostici. Razlog za kasni pronalazak dijagnoze je širok raspon simptoma i varijabilno vrijeme javljanja samih simptoma prije nego pacijent posjeti liječnika. Kasno postavljanje dijagnoze unutarnje hernije može ugroziti život pacijenta jer unutarnje hernije mogu uzrokovati akutnu crijevnu opstrukciju. U takovim slučajevima zabilježen je visok mortalitet zbog čega unutarnje hernije sa simptomima akutnog abdomena treba operirati što prije. Slikovna dijagnostika može lako dovesti do specifične dijagnoze i najbolje kirurške strategije. Ovdje prikazujemo četiri pacijenta sa unutarnjom hernijom koji su razvili akutni abdomen te tijek liječenja zajedno sa pregledom literature.