

Unilateral Eyelid Involvement as Single Presentation of Discoid Lupus Erythematosus: A Clinical Conundrum

**Denitza Zheleva¹, Razvigor Darlenski¹, Elena Obreshkova²,
Maria Balabanova³, Nikolay Tsankov¹**

¹Department of Dermatology and Venereology, Tokuda Hospital Sofia, Sofia, Bulgaria; ²Department of Dermatology and Venereology, Military Medical Academy, Sofia, Bulgaria; ³Department of Dermatology and Venereology, Sofia Faculty of Medicine, Sofia Medical University, Sofia, Bulgaria

Corresponding author:

Denitza Zheleva, MD
Tokuda Hospital Sofia
Department of Dermatology and Venereology
Sofia
Bulgaria
dr.d.jeleva@gmail.com

ABSTRACT We report a case of a 30-year-old woman with discoid lupus erythematosus (DLE) involving only a single lower eyelid. The diagnostic delay is explained by the unspecific clinical and histopathology picture and lack of specific changes in the first biopsy specimen taken. The diagnosis was based on later histological and immunological studies. Palpebral involvement has rarely been reported as the first and sole manifestation of the disease.

KEY WORDS: unilateral, lower eyelid, discoid lupus erythematosus

Received: June 2, 2014

Accepted: January 30, 2015

INTRODUCTION

Systemic lupus erythematosus (SLE) is a multiorgan autoimmune disease of unknown etiology with many clinical manifestations. The skin is involved in up to 85% of systemic lupus erythematosus (SLE) cases and may be the only organ involved in chronic cutaneous lupus erythematosus (CCLE) (1). Discoid lupus erythematosus (DLE) is the most common subtype of CCLE in clinical practice. It is characterized by chronic, scarring lesions mainly involving the face or neck, but also found elsewhere, mostly on sun exposed areas. Involvement of the scalp leading to scarring alopecia is very common in patients with DLE. The typical skin lesions can be diagnosed easily, although palpebral involvement as a sole manifestation is very rarely reported. With distribution above the neck, the so-called localized form of DLE can be

separated from a disseminated DLE (DDLE) if present below the neck as well. In 1982, the diagnosis criteria for SLE were published by the American College of Rheumatology (ACR), revised in 1997, and are currently used in clinical practice. Concerning cutaneous manifestations, the ACR criteria include malar rash, discoid rash, photosensitivity, and oral ulcers. DLE lesions are common in SLE; on the other hand, SLE may uncommonly develop in patients with CCLE. All patients should be diagnosed and treated at an early stage to avoid eyelid dysfunction resulting from scarring, synechia, trichiasis, entropion, and ectropion. A case of a 30-year-old Caucasian woman with unilateral discoid lupus erythematosus lesion on her left lower eyelid is presented. This case demonstrates the wide range of differential diagnoses in such cases.

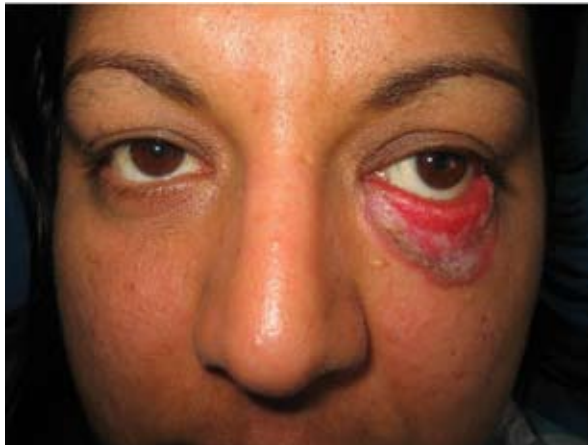

Figure 1. Unilateral involvement of the left lower eyelid with madarosis.

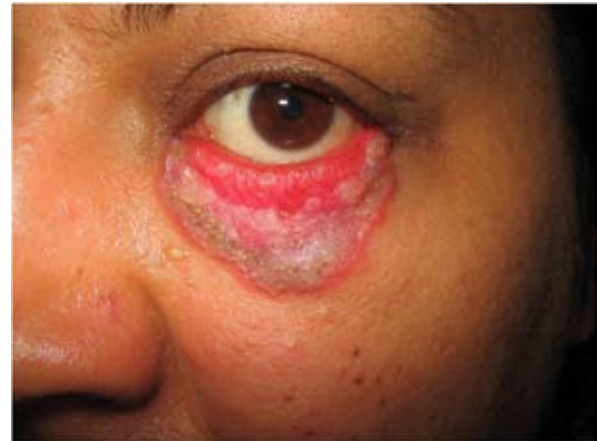

Figure 2. Semi-annular erythematous plaque with scales and follicular plugging.

CASE REPORT

A 30-year-old Caucasian woman presented with semi-annular plaque on her left lower eyelid. A well-demarcated plaque with a raised erythematous border and whitish scales in the center was seen. In the peripheral zone slightly expressed follicular hyperkeratosis with depression and atrophy were visible (Figure 1, Figure 2). The eyelid rim was inflamed with loss of eyelashes. No further involvement of the skin and its appendages was seen. Subjectively, itching and oozing were reported by the patient, aggravated upon sun exposure.

Six months earlier the patient had had a nodular lesion, 5 mm in diameter, involving the left lower eyelid rim. It was excised due to ulceration. The histopathological examination showed a picture of a chronic inflammatory process. Three months later it progressed into the large erythematous plaque observed upon admission at our clinic.

In the differential diagnosis, we discussed Lisch epithelial corneal dystrophy (LECD), Woringer-Kolopp disease, Jessner-Kanoff lymphocytic infiltration, pseudolymphoma, cutaneous lymphoma, and necrobiosis lipoidica. Psoriasis, seborrheic and atopic dermatitis, polymorphic light eruption, lymphocytic infiltration, and superficial epithelial tumors were excluded due to the clinical and morphological characteristics of the localized lesion. Peripheral blood count, biochemistry, kidney and renal function tests, and urine examination tests were within normal ranges. Anti-nuclear antibodies were negative.

Upon admittance we did not have the original histopathological specimens, so we repeated the skin biopsy. Routine staining revealed a thickened basal cell membrane, hyperkeratosis, and atrophy of the epi-

dermis (Figure 3). There was perivascular and periadnexal lymphocytic inflammatory infiltrate throughout the dermis (Figure 4). Immunohistopathology stains were positive for CD3(+), CD4(-) CD8(+), Bcl-2 (+), and CD20(+), so the immunomorphologic structure of the infiltrate did not allow diagnosing the process as reactive lymphocytic infiltration or T-cell lymphoma. The diagnosis of DLE was made based on the clinical picture and histopathological features.

We started treatment with chloroquine phosphate 500 mg daily, with a reduction of the dose to 250 mg daily in 2 weeks. Considering the risk of severe and sometimes irreversible toxicity, the patient underwent initial (base line) and periodic ophthalmologic examinations. Topical therapy included tacrolimus 0.1% ointment and sun protection cream. No steroid cream was applied. Clinical signs improved in six

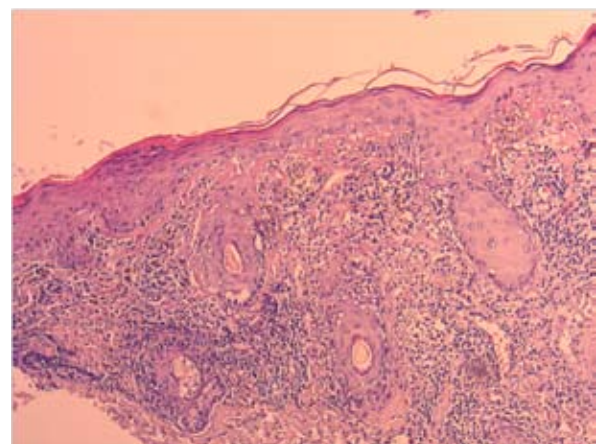


Figure 3. Histopathology of the eyelid lesion: Thickened basal cell membrane, hyperkeratosis, and atrophy of the epidermis (hematoxylin and eosin; $\times 100$).

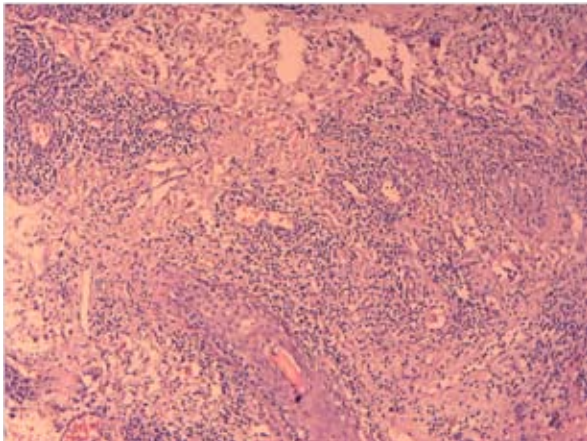


Figure 4. Histopathology of the eyelid lesion: Perivascular and periadnexal lymphocytic inflammatory infiltrate throughout the dermis (hematoxylin and eosin; $\times 100$).

weeks. The patient was examined every six months and subsequent worsening was observed due to the poor compliance of sunscreen use instructions and outdoor work in a sunny area (Figure 5).

DISCUSSION

The clinical spectrum of cutaneous lupus erythematosus involves a wide range of conditions. The typical features of DLE include localized inflammatory scarring lesions, mainly involving the face and/or the neck (2). Periocular involvement occurs uncommonly and may progress from eyelid erythema to scarring and madarosis (3). DLE may rarely present as periorbital erythema and edema (4). In our case, the disease was limited to the skin and the lesions had the appearance of DLE, including atrophy, scarring, and follicular plugging. Palpebral lesions may rarely be the presenting or sole manifestation of the disease (3), and lower eyelid involvement is seen in 6% of patients with chronic, cutaneous lupus erythematosus (5). The spectrum of ocular manifestations and complications of LECD include meibomian gland dysfunction, blepharitis, trichiasis, madarosis, conjunctivitis, chronic eyelid edema, and eyelid plaques. In our case the eyelid was the only skin area affected by the disease.

A large group of diseases should be considered in differential diagnosis of DLE, including psoriasis, seborrheic and atopic dermatitis, and polymorphic light eruption (7). DLE could be suspected in cases of therapy-resistant and persisting inflammatory eyelid lesions (8). The non-specific changes in our case require further investigation to exclude autoimmune and proliferative skin diseases. Reaching the right di-

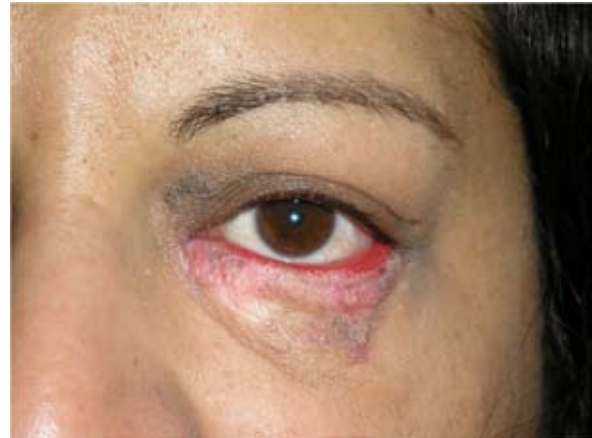

Figure 5. Post treatment: Persistent loss of eyelashes.

agnosis might take different amount of time, but performing a skin biopsy with routine histopathological and immunologic tests can definitively establish the diagnosis. Patients with widespread involvement often have hematologic and serologic abnormalities, are more likely to develop systemic lupus erythematosus, and are more difficult to treat (2). Our patient had no laboratory and immunologic data indicating systemic involvement.

There is a need for steroid-free topical treatment for LE. With the development of topical calcineurin inhibitors, tacrolimus and pimecrolimus, an alternative has become available (9). Our report suggests that every patient with persistent periorbital lesions should undergo histological and immunofluorescent evaluation, and DLE should be included in the differential diagnosis. Our patient continues to receive follow-up examinations.

CONCLUSION

We report unilateral palpebral involvement as a sole presentation of DLE. The wide clinical spectrum in patients with DLE shows us the high index of suspicion necessary in reaching the correct diagnosis.

References

1. Uva L, Miguel D, Pinheiro C, Freitas JP, Gomes MM, Filipe P. Cutaneous manifestations of systemic lupus erythematosus. *Autoimmune Diseases* 2012; Article ID 834291:1-15.
2. Frith P, Burge SM, Millard PR, Wojnarowska F. External ocular findings in lupus erythematosus: a clinical and immunopathological study. *Br J Ophthalmol* 1990;74:163-7.
3. Selva D, Chen CS, James CL, Huilgol SC. Discoid lu-

- pus erythematosus presenting as madarosis. *Am J Ophthalmol* 2003;136:545-6.
4. Serarslan G, Atik E, Sarikaya G. Periorbital edema and erythema: an unusual localization of DLE in a patient with psoriasis. *J Dermatol* 2011;38:486-8.
 6. Yaghoobi R, Feily A, Behrooz B. Palpebral involvement as a presenting and sole manifestation of Discoid Lupus Erythematosus. *Scientific World Journal* 2010;10:2130-1.
 5. Pianigiani E, Andreassi A, De Aloe G. Chronic erythematous desquamative plaques of the eyelids: discoid lupus erythematosus (DLE). *Arch Dermatol* 2002;138:527-32.
 7. Acharya N, Pineda R 2nd, Uy HS, Foster CS. Discoid lupus erythematosus masquerading as chronic blepharoconjunctivitis. *Ophthalmology* 2005;112:e19-23.
 8. Huey C, Jakobiec FA, Iwamoto T, Kennedy R, Farmer ER, Green WR. Discoid lupus erythematosus of the eyelids. *Ophtalmology* 1983;90:1389-98.
 9. Michael Sticherling. Update on the use of topical calcineurin inhibitors in cutaneous lupus erythematosus. *Biologics* 2011;5:21-31.

