

Chalazion Management – Surgical Treatment Versus Triamcinolon Application

Dubravka Biuk¹, Suzana Matić¹, Josip Barać¹, Marija Jelić Vuković¹, Egon Biuk² and Mate Matić³

¹ »J. J. Strossmayer« University, Osijek University Hospital Centre, Department of Ophthalmology, Osijek, Croatia

² »J. J. Strossmayer« University, Osijek University Hospital Centre, Department of Orthopedic Surgery, Osijek, Croatia

³ »J. J. Strossmayer« University, Osijek University Hospital Centre, Department of Oncology and Radiotherapy, Osijek, Croatia

ABSTRACT

The aim of the study was to compare the length of treatment and efficiency of applied therapy in two groups of patients with chalazion who underwent surgical procedure or got triamcinolone application in chalazion. Our study included 30 patients with chalazions that persisted for about one month. All of them were resistant to applied topical antimicrobial therapy. These patients were divided in two groups. 15 patients underwent surgical procedure that included incision, excochleation and excision of the capsule of chalazion, while other 15 patients underwent triamcinolone application directly in chalazion (dosage of 2–4 mg). Patients were followed up a day after therapy, two weeks after therapy and one month after applied therapy. We found that chalazion treatment with triamcinolone application directly in the lesion was to be more comfortable for patients, took less time to treat and needed no additional topical antimicrobial therapy.

Key words: chalazion, surgical treatment, triamcinolone application, length of therapy

Introduction

Chalazion or meibomian cyst is a chronic inflammatory lipogranuloma caused by the blockage of gland orifices and stagnation of sebaceous secretions in the tarsus of an eyelid. It can affect individuals of all ages, appears more frequently in adults, can present as uniform or multiple, as well as recurrent clinical formation. Some are more common on the upper eyelid¹, which can be explained by the presence of more glands on the upper eyelid by anatomical distribution. They vary in size, are sometimes even not visible, but just as palpable resistance in the tarsus. Eversion of the eyelid usually shows an inflamed chalazion through the tarsal conjunctiva, which further on becomes whitish granuloma with potential to rupture. Chalazion usually causes local symptoms such as irritation, inflammation and cosmetic disfigurement. Bigger lesions can induce mechanical ptosis and cause blurred vision from induced astigmatism² by pressing the cornea and rarely, they can lead to conjunctivitis or cellulitis³.

They rarely disappear spontaneously (25–50%)^{4,5}, and mainly require treatment that includes eyelid hygiene, massage, warm compresses, antibiotic drops and sometimes even systemic per oral administration of tetracy-

cline (patients with acne rosacea or seborrhoeic dermatitis). Some smaller chalazia may disappear spontaneously, while some have good therapeutic answer to conservative treatment, but a higher percentage of chalazia react only to a surgical approach as the only method of treatment. Surgical treatment includes steroid injections, CO₂, laser treatment, lesion excision, and curettage or total excision. The success of conventional surgical treatment of chalazia ranges between 60–89%, while conservative treatment may be successful in 25–77% cysts^{6,7,8}.

The pathological analysis of chalazia confirmed chronic lipogranulomatous inflammatory changes⁸, probably as a result of chronic irritation with low virulent microorganisms. Histologically, a chalazion, described as an epitheloid granuloma, is composed predominantly of corticosteroid-sensitive histiocytes, mononuclear granulocyte cells, lymphocytes, plasma cells, polymorphonuclear cells and eosinophils⁹.

It is essentially important to distinguish chalazia and malignant lesions such as sebaceous cell carcinoma¹⁰ which has very similar clinical presentation, but fortunately its appearance is extremely rare¹¹. The mean age

of patients with sebaceous gland carcinoma is between 57 and 68 years¹². Therefore, it is obligatory to perform a histological verification of resected tissue in this group of patients.

Patients and Methods

This study was conducted at the Department of Ophthalmology, Clinical Hospital Osijek, Europska avenija 14–16, 31000 Osijek, Croatia. All subjects included in this study were patients with clinical presentation of chalazion who were referred to ophthalmological examination by their family physician. They all started with conservative therapy (local antibiotic drops, massage, warm, dry bandages) under his recommendation. The study included 30 patients with primary chalazion who were divided into two randomly selected groups. The first group of patients (N=15) was treated by intraleisional triamcinolone acetonide injection (TA) (0.1 to 0.2 mL (40 mg/mL) and the second group of patients (N=15) were treated surgically (incision, excochleation) (IC).

Every patient underwent the whole routine ophthalmological examination with the assessment of the lesion size. The study included patients with primary chalazion >2 mm.

We estimated the size of the chalazion before and after the procedure, time to resolution, recurrence and complications of treatment (skin pigment changes, skin atrophy, pyodermsation and post-surgical hematoma). Success was defined as at least an 80% decrease in the size of the lesion with no recurrence. If the lesion did not disappear or if it decreased in size to 1 mm or less in diameter on subsequent visits, the same procedure carried out primarily was repeated.

For the assessment of the pain in patients during and after the treatment we used a simplified version of the 11-point Numerical Rating Scale¹³, in which patients reported the level of pain they felt during the surgery (Goawalla used the same scale in his study). Patients were asked to score their overall experience of pain on a scale of 0 to 10, in which 0 meant – I did not feel anything during the surgery, and 10 meant – I felt the worst pain I have suffered so far in life.

To assess the patient satisfaction with the chosen treatment option, Likert scale of satisfaction was selected. The scale has five levels of satisfaction, in which one (1) meant – I am very unsatisfied and five (5) meant – I am extremely satisfied.

Exclusion criteria were: acutely infected chalazia with preseptal cellulitis, recurrent chalazion, extremely small chalazion (≤ 2 mm), and patients under 18 years of age.

Technique of Triamcinolone acetonide (TA) injection: Triamcinolone acetonide can be applied in the chalazion transcutaneously or through conjunctiva. In this study, Triamcinolone acetonide (TA) was applied transcutaneously after a local anesthetic administration (EMLA 5% ointment) on the site of the injection with the aim to avoid pain. A twenty eight (28) gauge needle on a 1-ml in-

sulin syringe was used to inject 0.2 mL of 40 mg/mL Triamcinolone acetonide (TA). Following the administration of the drug, no local antibiotic therapy or occlusion of the eye was applied. The patient was instructed to apply gentle digital massage over the chalazion for 5 minutes three times a day for 5 days.

Surgical treatment included local application of 2% lignocaine with 1:10 000 adrenaline transcutaneously, eversion of the eyelid with a cyst clamp, vertical incision of tarsal conjunctiva and curettage of the cyst content. After the surgical procedure, an antibiotic ointment and ocular compressive occlusion was done. Patients were kept in the clinic until any bleeding had stopped and they all got Chloramphenicol ointment four times a day for 1 week to apply in the eye.

Patients were followed up 7 days after the surgery due to the evaluation of possible local complications and 3 weeks after the surgery to assess the withdrawal of the chalazion.

Statistics

Collected data were summarized in Microsoft Excel tables and the descriptive statistic was analysed by SPSS 16.0 software (SPSS Inc., Chicago, IL, USA). To compare among the groups Mann-Whitney U-test was utilized and the level of significance was set at $p < 0.05$. The values are presented as median with range.

Results

Chalazion resolution

The results of our study showed equal effectiveness of both therapy approach. In the first group of patients (triamcinolone acetonide administration-TA), there was a withdrawal of lesions in 13 patients (86%), while the withdrawal of the lesions in the second group of patients was noticed in 12 patients (80%). Two patients had yellow deposits and three patients had haematoma at the site of transcutaneous injection of triamcinolone acetonide (TA). Three patients had palpebral haematoma after the surgical procedure. There were no serious complications noticed, such as prolonged increase in intraocular

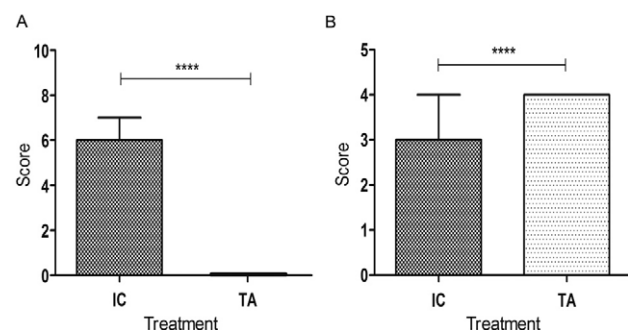


Fig. 1. Reported pain (A) and satisfaction with treatment (B) on the scale 0–10 and 1–5, respectively. IC – surgical treatment, TA – triamcinolone acetonide treatment, $p < 0.0001$.

pressure (all patients in the first group (TA) underwent the measurement of intraocular pressure by Goldmann applanation tonometry before triamcinolone acetonide application and on several controls later on), atrophy of the orbital fat, depigmentation of the overlying skin, vascular occlusion or visual loss in the first group of patients who got triamcinolone acetonide.

Pain experienced during treatment

There was a significant difference in pain sensation between observed groups of patients. The pain scores were highest in the I/C group with a median score 6 (5,7). In the triamcinolone acetonide group (TA), patients did not feel the pain at all and a median score was 0 (0,0).

Therapeutical approach and patients satisfaction

The results of the study showed that patients who got Triamcinolone acetonide (TA) in the lesion were more satisfied than the patients who underwent classical incision and curettage of the gland content (I/C group). The median in the first group was 4 (4,4) and in the second group 3 (2,4). However, the patients who underwent curettage were also satisfied with clinical result but they were mostly unsatisfied with pain they suffered during and after the surgery, so as discomfort caused by a compressive occlusion of the eye after the treatment.

Discussion

Chalazion belongs to the most common ocular pathology that requires surgical intervention. Conventional surgical procedure includes tarsal conjunctival incision and curettage of the inflamed gland content. In most cases, the procedure passes without any complications.

A Canadian survey of ophthalmologists had suggested that chalazion surgery should not be trivialized and should be treated with the same respect as any other ocular surgery¹⁴. In many institutions it is done as a one-stop procedure on the day of the patient's first visit. We believe that this approach is not appropriate because the patients are not prepared mentally for a surgical intervention. Recently, the options for simple and highly effective chalazion treatment are intralesional steroid injections. The steroid intralesional injection for the treatment of chalazion was first described by Leinfelder in 1964.¹⁵ Since then, many studies proclaim the efficacy of intralesional corticosteroid injection and have shown equal effectiveness of both methods of chalazion treatment^{9,16,17}.

The results of the Goawalla study from 2007 suggest that a single transconjunctival 0.2 mL injection of 40 mg/mL of TA followed by repeated digital massage at home, has the efficacy comparable to incision and curettage in the treatment of chalazia, with similar patient satisfaction, less pain and patient inconvenience¹. Patients who were treated with intralesional triamcinolone acetonide application (TA) had less visits to ophthalmologists, had no need for antibiotic therapy and analgesics.

They needed no compressive occlusion of the eye, like patients who underwent classical curettage of chalazion who had eye occlusion for 24 hours. Although both methods are equally effective, it could be concluded that each of them has its field of indication. The steroid therapy is the most effective when the chalazion has not been secondarily infected. In that case, surgical procedure has the advantage. The advantage of triamcinolone application must also be given when chalazion localization is close to the lacrimal drainage system with the aim to avoid possible surgical damage. The method of choice when treating chalazion in children and younger patients is definitely triamcinolone acetonide application (TA), because these patients may have a substantial psychological aversion to surgery (which involves an anesthetic injection plus the surgical procedure) as opposed to an injection only.

Surgical treatment (incision, curettage) has advantage when treating infected lesions, patients who did not respond to 2 or 3 triamcinolone acetonide (TA) injections, chalazia close to the lacrimal drainage system, patients suffering from glaucoma and patients with suspicious adenocarcinomatous lesions where the histopathological verification of resected material is necessary. There were no complications while performing any of these two methods of chalazion treatment. While performing surgical incision and curettage, it is of importance to follow up the patient to detect scar formation at the site of the incision, which can induce local irritation symptoms. The most common side effect of intralesional application of triamcinolone acetonide (TA) is local depigmentation of the skin, appearing rarely when the drug is applied transconjunctivally. The conjunctival approach minimizes the risk of inadvertent penetration of the globe. Ho¹⁸ documented that two out of 48 patients who underwent subcutaneous intralesional triamcinolone acetonide injection were affected by localized skin depigmentation, while in the Goawalla study none of the 56 patients that underwent this procedure suffered this adverse effect. In our study, two patients had local skin depigmentation. One possible explanation for this could be that although the injection is aimed at being deposited intralesionally, occasionally a small portion of triamcinolone acetonide (TA) may be deposited by the needle on the way in or out of the injection site. Another explanation is the concentration of the drug that was used in the treatment, although the concentration of triamcinolone acetonide (TA) used in Ho's study was 10 mg/mL, while in our study was used a dilution of 40 mg/mL. The average time of resolution of the chalazion after one triamcinolone acetonide (TA) injection was a two and a half weeks, which is in correlation with the study of Simon et al¹⁹.

Conclusion

In conclusion, we can say that both methods are equally effective in the treatment of chalazia. Intralesional application of triamcinolone acetonide (TA) has the

advantage when treating children, patients having local or systemic allergic reactions to anesthesia, as well when having chalazion close to the lacrimal drainage system. Although serious side effects of this treatment are rare (rupture of the eyeball, loss of vision due to micro embolism), this therapeutic approach is not widely accepted by ophthalmologists, probably because of fear, since the incision and drainage do not have such serious potential side effects.

lism), this therapeutic approach is not widely accepted by ophthalmologists, probably because of fear, since the incision and drainage do not have such serious potential side effects.

REFERENCES

1. GOAWALA A, LEE V, Clin Experimental Ophthalmol, 35 (2007) 706. DOI: 10.1111/j.1442-9071.2007.01617.x. — 2. COSAR CB, RAPUANOB CJ, COHEN EJ, LAIBSON PR, Cornea, 20 (2001) 890. — 3. RUMELT S, RUBIN PA, Int Ophthalmol Clin, 36 (1996) 207. — 4. DUA HS, NILAWAR DV, Am J Ophthalmol, 94 (1982) 424. — 5. COTTRRELL DG, BPSANQUET RG, FAWCETT IM, BMJ, 287 (1983) 1595. — 6. GARRETT GW, GILLESPIE ME, MANNIX BC, Ann Ophthalmol, 20 (1988) 196. — 7. BOHIGIAN GM, Ann Ophthalmol, 11 (1979) 1397. — 8. PERRY HD, SERMIUK RA, Ophthalmology, 87 (1980) 218. — 9. PIZZARELLO LD, JAKOBEIC FA, HOELDT AJ, PODOLSKY MM, SLIVER DN, AM J Ophthalmol, 85 (1978) 818. — 10. ZURCHER M, HINTSCHICH CR, GAMER A, BUNCE C, COLLIN JR, Br J Ophthalmol, 82 (1998) 1049. DOI: org/10.4321/S0365-6691201000200005. — 11. SHIELDS JA, DE-

MIRCI H, MARR BE, EAGLE RC Jr, SCHIELDS CL, Ophthalmology, 111 (2004) 2151. DOI: 10.4103/0974-620X.71885. — 12. EPSTEIN GA, PUTTRMAN AM, Ophthalmol Surg, 14 (1983) 935. DOI: 10.4103/0974-620X.71885. — 13. BOLTON JE, WILKINSON RC. J Manipulative Physiol Ther, 21 (1998) 1. — 14. SMYTHE D, HURWITZ JJ, TAYFOUR F, Can J Ophthalmol, 25 (1990) 252. — 15. LEINFELDER PJ, Am J Ophthalmol, 58 (1964) 1078. — 16. CASTERM J, STENBERG T, Acta Ophthalmol (Copenh), 61 (1983) 938. DOI: 10.1038/nmat1625. — 17. GARRET GW, GILLESPIE ME, MANNIX BC, Ann Ophthalmol, 20 (1986) 196. — 18. HO SY, LAI JSM, HKMJ, 8 (2002) 18. — 19. BEN SIMON GJ, HUANG L, NAKRA T, SCHWARCZ RM, McCANN JD, GOLDBERG RA, Ophthalmology, 112 (2005) 913. DOI: 10.1016/j.ophtha.2004.11.037.

D. Biuk

»J. J. Strossmayer« University, Osijek University Hospital Centre, Department of Ophthalmology, Europske avenije 14–16, Osijek, Croatia
e-mail: egon.biuk@os.t-com.hr

LIJEČENJE HALACIONA – KIRURŠKI ZAHVAT NASUPROT INJEKCIJAMA TRIAMCINOLONA

SAŽETAK

Cilj ovog istraživanja je usporedba dužine liječenja i efikasnosti terapije primjenjene u dvije grupe bolesnika s kliničkim nalazom halaciona koji su prošli kirurški zahvat ili su dobili triamcinolon acetamid direktno u halacion u svrhu liječenja. Studija je obuhvatila 30 bolesnika s kliničkim nalazom halaciona prisutnim najmanje mjesec dana. Svi bolesnici bili su otporni na lokalno primijenjenu antimikrobijalnu terapiju te su podijeljeni u dvije grupe. Petnaest (15) bolesnika liječeno je klasičnim kirurškim načinom koji uključuje inciziju, ekskoleaciju i eksciziju kapsule halaciona, dok je ostalih petnaest ispitanika dobilo triamcinolon acetamid direktno u halacion (doza 2-4 mg). Bolesnici su praćeni nakon dan, dva tjedna i mjesec dana nakon primijenjene terapije. Rezultati ukazuju da je primjena triamcinolon acetamida direktno u halacion puno ugodnija za bolesnike, trajanje liječenja kraće te nije potrebna dodatna antimikrobijalna topička terapija.