

Focal Porokeratosis of Nuchae: Case Report

**Daška Štulhofer Buzina, Svjetlana Rajič, Jaka Radoš, Branka Marinović,
Jasna Lipozenčić**

University Hospital Center Zagreb, Department of Dermatology and Venereology,
School of Medicine University of Zagreb, Zagreb, Croatia

Corresponding author:

Daška Štulhofer-Buzina, MD, MS
University Hospital Center Zagreb
Department of Dermatology and Venereology
School of Medicine University of Zagreb
HR- 10000 Zagreb
Croatia
daska.stulhofer-buzina@zg.htnet.hr

Received: January 29, 2010

Accepted: October 12, 2010

SUMMARY Porokeratosis is the common name of several diseases of unknown pathogenesis, which are similar in clinical appearance. It was first described in 1893 and was thought to be a disorder of sweat glands, hence the name porokeratosis. The lesion that can be found in all cases is annular, with atrophic center, and hyperkeratotic outer ring. Cases of porokeratosis have been linked with genetic heritage, excessive ultraviolet exposure, kidney failure, and state of immunosuppression, but no definitive link has been established. As a rare condition, its main feature is that the correct diagnosis can be delayed for a significant period of time. Porokeratotic lesions have a high incidence of malignant transformation and are considered premalignant. We present a case where a porokeratotic lesion was unsuccessfully treated as a psoriatic lesion for more than a year in a patient with previously diagnosed psoriasis. A skin biopsy was performed at our department, which revealed classic cornoid lamella and thus led to the correct diagnosis. The lesion was excised. Additional diagnostic tests revealed normal kidney function and intact immune system. A follow-up protocol was established for the patient, ensuring timely diagnosis of any future porokeratotic lesions. Porokeratosis, especially when there are only few lesions, is not difficult to manage – once it is diagnosed. A diagnosis of porokeratosis may also aid in identifying a serious systemic disease such as kidney failure. Importantly, a misdiagnosis of porokeratosis may lead to development of skin cancer.

KEY WORDS: porokeratosis, psoriasis, misdiagnosis

INTRODUCTION

Porokeratosis is a group of disorders of keratinization characterized by annular lesions with atrophic center and hyperkeratotic outer ring. The disorder was originally described in 1893 independently by two authors, Mibelli and Respighi (1,2). The cause of porokeratosis is still unknown. However, nowadays this condition is considered

a genodermatosis with an autosomal dominant mode of inheritance. In patients with genetic predisposition, external triggering factors such as irradiation, infective agents, trauma, and immunosuppression can determine the activation of abnormal clone of epidermal keratinocytes (3-7). According to the published reports, porokeratotic lesions

undergo malignant alteration in around 10% of cases, usually in Bowen's disease, planocellular or basal cell carcinoma (8). Accordingly, porokeratoses are considered a premalignant condition (9). This uncommon disease is characterized by annular, gyrate plaques with central atrophy and sharply elevated hyperkeratotic borders. Mibelli named this condition porokeratosis, believing that it involved the pores of the sweat ducts (3). Porokeratoses can only be diagnosed by skin biopsy and histopathology. The latter would reveal a formation called cornoid lamella (10). Although cornoid lamella is not specific for porokeratosis, the diagnosis of porokeratosis cannot be established without it. There are several forms of porokeratosis: classic porokeratosis (porokeratosis of Mibelli), disseminated superficial actinic porokeratosis, disseminated superficial porokeratosis, linear porokeratosis, punctate porokeratosis, and porokeratosis palmaris et plantaris disseminata. The most common form is disseminated superficial actinic porokeratosis, which typically appears in elderly females. It is characterized by multiple small brown hyperkeratotic lesions, usually located on the extensor surfaces of extremities. Classic porokeratosis of Mibelli is a rare disease, as are all other forms of porokeratosis, which appears primarily in young males. In classic porokeratosis, there is usually one or several lesions that can be located anywhere on the skin. Still, the most common sites of classic porokeratosis are the extremities. Despite the wide variety of clinical presentation of porokeratoses, the histopathologic, immunohistochemical, and ultrastructural features are the same. Treatment of porokeratosis does not show encouraging results (10). Isolated or smaller lesions can be treated by excision, cryotherapy, or laser therapy (11,12). Topical treatment by 5-fluorouracyl, tretinoin, diclofenac, imiquimod, and photodynamic therapy is sometimes successful (13-18). Systemic treatment by retinoids can lead to remission, but therapy discontinuation may lead to recurrence (19). Due to its rarity, porokeratoses are often misdiagnosed and treated unsuccessfully. Here we present a case where a single porokeratotic lesion in an elderly male patient was treated as psoriasis for a year.

CASE REPORT

A 68-year-old male patient was referred to our department because of a lesion in the nuchal region, first noticed a year before. During the last 8 years, the patient had been treated for erythema-squamous lesions located on the elbows and

dorsal sides of hands. These lesions were treated as psoriasis, with intermittent topical corticoids and keratolytic agents that led to regression. When the nuchal lesion was noticed, the same therapy was applied, without success (Fig. 1). The patient's family history was negative for dermatologic diseases. He took therapy for hypertension and uric arthritis. Overall, he felt 'healthy'. When younger, he had been frequently exposed to sunlight without adequate protection. On dermatologic examination, an erythematous solitary papule with atrophic central area was detected in the nuchal region, measuring 10x8 mm. Skin biopsy was performed, with the excised part of the skin containing both peripheral and central area. Histopathology revealed multiple parakeratotic columns (cornoid lamella) within the epidermis. Underneath, in the upper malpighian layer, some of the keratinocytes appeared vacuolated and dyskeratotic. A moderate focal lymphohistiocyte infiltrate and elastosis were observed in the upper dermis. Such a histopathologic finding is the hallmark of classic porokeratosis of Mibelli (Fig. 2). As it was isolated lesion, complete excision was performed. Additional diagnostic tests were carried out to exclude the possible immune disorders or chronic renal failure, since porokeratosis may be linked with these conditions. The tests included complete and differential blood count, serum concentrations of urea and creatinine, and kidney ultrasound examination. All the tests came out negative. The patient was informed about the nature of porokeratosis. Strict sunlight protection was emphasized and a follow-up protocol was scheduled.

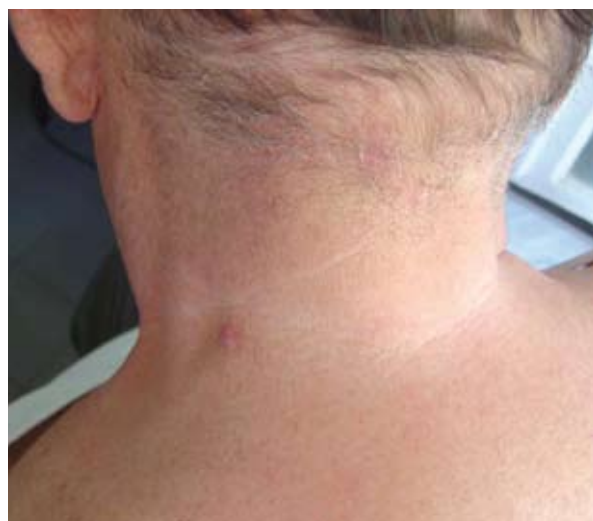

Figure 1. Porokeratotic lesion in the nuchal region, after biopsy.

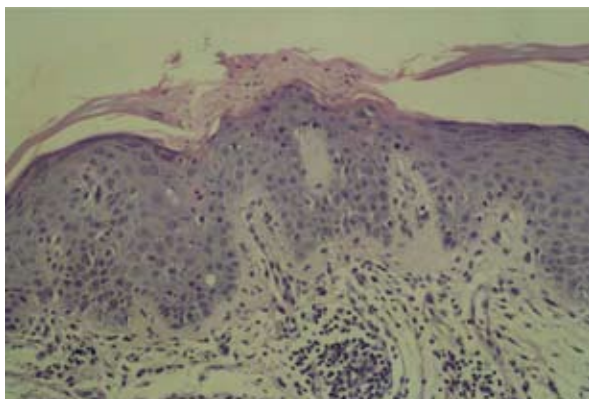


Figure 2. Multiple parakeratotic columns (cornoid lamella) within the epidermis. In the upper malpighian layer, some of the keratinocytes are vacuolated and dyskeratotic. A moderate focal lymphohistiocyte infiltrate and elastosis in the upper dermis. (HE stain, X40)

DISCUSSION

Porokeratosis is a rare disease, which is commonly misdiagnosed, most frequently as psoriasis (20). The frequent misdiagnosis reminds us of the potential danger of porokeratosis. On the one hand, the development or sudden flare-up of porokeratosis can be a sign of a serious condition, such as immunodeficiency or kidney failure (21-24). On the other hand, porokeratosis represents a form of clonal keratinocyte expansion with chromosomal instability, which in many cases undergoes malignant transformation to basal cell or spinocellular carcinoma. This emphasizes the necessity of long-term follow-up of patients with porokeratosis (9,25). However, the crucial element of porokeratosis treatment is its recognition. In misdiagnosed cases, a life-threatening disease can develop unnoticed and porokeratosis can turn into carcinoma. Recognition of porokeratosis makes all the difference. The possible systemic disorders can easily be diagnosed using standard diagnostic procedures, and meticulous follow-up of porokeratotic lesions with biopsies and excisions of suspect lesions can prevent uncontrolled malignant transformation. Patients must avoid UV exposure (without protection), use of tanning beds and even phototherapy.

CONCLUSION

In the case report presented, a systemic cause of the development of porokeratosis was not found. Immune disorders as well as kidney failure were ruled out. This case of porokeratosis can therefore be classified as a sporadic case (26).

The patient was advised to consistently use sun protection (UVA and UVB sunscreens), and periodic dermatologic examinations were scheduled. The patient was followed up for two years without recurrence.

References

1. Mibelli V. Contributo allo studio della ipercheratosi dei canali sudoriferi (porokeratosis). *G Ital Mal Venerae Pelle* 1893;28:313-35.
2. Respighi E. Di una ipercheratosi non ancora descritta. *G Ital Mal Venerae Pelle* 1893;28:356-86.
3. Patrizi A, D'Acunto C, Passarini B, Neri I. Porokeratosis in the elderly: a new subtype of disseminated superficial actinic porokeratosis. *Acta Dermatol Venereol* 2000;80:302-4.
4. Leow YH, Soon YH, Tham SN. Report of 31 cases of porokeratosis at the National Skin Center. *Ann Acad Med Singapore* 1996;25:837-41.
5. Herranz P, Pizarro A, De Lucas R, Robayna MG, Rubio FA, Sanz A, *et al.* High incidence of porokeratosis in renal transplant recipients. *Br J Dermatol* 1997;136:176-9.
6. Rodríguez EA, Jakubowicz S, Chinchilla DA, Carril A, Viglioglia PA. Porokeratosis of Mibelli and HIV-infection. *J Dermatol* 1996;35:402-4.
7. Tsambaos D, Spiliopoulos T. Disseminated superficial porokeratosis: complete remission subsequent to discontinuation of immunosuppression. *J Am Acad Dermatol* 1993;28:651-2.
8. Otsuka F, Huang J, Samara K, Asahina A, Ishibashi Y. Disseminated porokeratosis accompanying multicentric Bowen's disease. Characterization of porokeratotic lesions progressing to Bowen's disease. *J Am Acad Dermatol* 1990;23:355-9.
9. Sasson M, Krain AD. Porokeratosis and cutaneous malignancy. A review. *Dermatol Surg* 1996;22:339-42.
10. Schamroth JM, Zlotogorski A, Gilead L. Porokeratosis of Mibelli. Overview and review of the literature. *Acta Derm Venereol* 1997;77:207-13.
11. Itoh M, Nakagawa H. Successful treatment of disseminated superficial actinic porokeratosis with Q-switched ruby laser. *J Dermatol* 2007;34:816-20.
12. Carranza DC, Haley JC, Chiu M. Facial porokeratosis. *Skinmed* 2008;7:51-2.
13. Grover C, Goel A, Nanda S, Khurana N, Reddy BS. A case of extensive linear porokerato-

- sis with evaluation of topical tretinoin *versus* 5-fluorouracil as treatment modalities. *J Dermatol* 2005;32:1000-4.
14. Danby W. Treatment of porokeratosis with fluorouracil and salicylic acid under occlusion. *Dermatol Online J* 2003;9:33.
 15. Vlachou C, Kanelleas AI, Martin-Clavijo A, Berth-Jones J. Treatment of disseminated superficial actinic porokeratosis with topical diclofenac gel. *J Eur Acad Dermatol Venereol* 2008;22:1343-5.
 16. Ahn SJ, Lee HJ, Chang SE, Lee MW, Choi JH, Moon KC, Koh JK. Case of linear porokeratosis: successful treatment with topical 5% imiquimod cream. *J Dermatol* 2007;34:146-7.
 17. Erbagci Z, Tuncel AA, Erbagci I. Successful treatment of porokeratosis with topical imiquimod in 2 immunosuppressed cases. *J Drugs Dermatol* 2006;5:668-71.
 18. Nayeemuddin FA, Wong M, Yell J, Rhodis E. Topical photodynamic therapy in disseminated actinic porokeratosis. *Clin Exp Dermatol* 2002;27:703-6.
 19. Danno K, Yamamoto M, Yokoo T, Ohta M, Ohno S. Etretinate treatment in disseminated porokeratosis. *J Dermatol* 1988;15:440-4.
 20. De Simone C, Paradisi A, Massi G, Proietti H, Capponi A, Amerio PL, Capizzi R. Giant verrucous porokeratosis of Mibelli mimicking psoriasis in a patient with psoriasis. *J Am Acad Dermatol* 2007;57:665-8.
 21. Kanitakis J, Euvrard S, Faure M, Claudy A. Porokeratosis and immunosuppression. *Eur J Dermatol* 1998;8:459-65.
 22. Zenarola P, Melillo L, Lomuto M, Carotenuto M, Gomes VE, Marzocchi W. Exacerbation of porokeratosis: a sign of immunodepression. *J Am Acad Dermatol* 1993;1035-6.
 23. Lee HJ, Cho SB, Lee KH, Lee JH. A case of porokeratosis associated with chronic renal failure. *J Eur Acad Dermatol Venereol* 2006;20:1373-5.
 24. Hernandez MH, Lai CH, Mallory SB. Disseminated porokeratosis associated with chronic renal failure: a new type of disseminated porokeratosis? *Arch Dermatol* 2000;136:1568-9.
 25. Otsuka F, Someya T, Ishibashi Y. Porokeratosis and malignant skin tumors. *J Cancer Res Clin Oncol* 1991;117:55-60.
 26. Malhotra SK, Puri KJ, Goyal T, Chahal KS. Linear porokeratosis. *Dermatol Online J* 2007;13:15.

Erratum corrigé

In *Acta Dermatovenerologica Croatica* Volume 18, Number 3 in the article 'Expression of E-selectin in the skin of patients with atopic dermatitis: morphometric study' by the error of authors instead of Gordana Gregorović name of Gordana Gregurek was printed.