

Neurofibromatosis Type 1 Associated with Dysplastic Nevus Syndrome

Zrinjka Paštar¹, Jasna Lipozenčić¹, Suzana Kovačević², Samir Čanović², Ana Didović-Torbarina², Anamarija Vukasović³

¹University Department of Dermatology and Venereology, Zagreb University Hospital Center and School of Medicine, Zagreb; ²Department of Ophthalmology, Zadar General Hospital, Zadar; ³University Department of Nuclear Medicine, Dubrava University Hospital, Zagreb, Croatia

Corresponding author:

Professor Jasna Lipozenčić, MD, PhD
University Department of Dermatology and Venereology
Zagreb University Hospital Center and School of Medicine
Šalata 4
HR-10000 Zagreb
Croatia
jasna.lipozencic@zg.htnet.hr

Received: October 22, 2008

Accepted: April 17, 2009

SUMMARY Neurofibromatosis type 1 (NF-1) is an autosomal dominant disorder that primarily affects the development and growth of neural cell tissues. It causes tumors to grow on nerves and produces other abnormalities such as skin changes and bone deformities. Dysplastic nevus syndrome (DNS) represents multiple atypical nevi associated with polygenetic inheritance pattern and may rarely occur together with NF-1. DNS type A is a marker of increased melanoma risk, while melanoma has been rarely reported in patients with NF-1. We describe a case of NF-1 type A with DNS presenting with multiple neural tumors, *cafe-au-lait* spots, hamartomas in globus pallidus and pigmented melanocytic iris hamartomas (Lisch nodules). The importance of close follow up of nevi in such patients with NF-1 and DNS for the development of melanoma as well as other NF-1 associated skin disorders and with multidisciplinary approach to other associated diseases is highlighted.

KEY WORDS: neurofibromatosis type 1, dysplastic nevus syndrome, melanoma

INTRODUCTION

Neurofibromatosis type 1 (NF-1) is the most common phakomatosis, an autosomal dominant disorder with one of the highest mutation rates (1,2). NF-1 by mutation of the tumor suppressor activity gene encoding neurofibromin protein affects primarily the development and growth of neural cell tissues and the regulation of melanogenesis (3). NF-1 is characterized by tumors originating from the neural crest, especially brain tumors and en-

doctrine malignancies, and produces skin changes, vascular and skeletal dysplasias (1,3,4). Dysplastic nevus syndrome (DNS) represents multiple atypical melanocytic nevi associated with polygenetic inheritance pattern. Although rare, it may occur together with NF-1 (4,5). DNS type A is a marker of increased melanoma risk, while melanoma has been rarely reported in NF-1 (2,4-6). We present a case of NF-1 associated with DNS type A.

CASE REPORT

A 17-year-old boy was referred to our Department for clinical and dermoscopic follow up of DNS. NF-1 was diagnosed at the age of four when the patient began developing *café au lait* maculae, and appendicitis and a volvulus of ileum because of ganglioneuromatosis of the gastrointestinal tract. At the age of 15, axillary and inguinal freckles, and numerous subcutaneous nodular neurofibromas started to appear.

Physical examination revealed greenish skin discoloration, numerous *café au lait* maculae, axillary and inguinal freckles, numerous subcutaneous nodular neurofibromas on the trunk and extremities, and more than 50 dysplastic nevi (Fig. 1A-C), mainly a combination of reticular, globular and unspecific global pattern on dermoscopy.

Additionally, scoliosis, discrete trunk asymmetry and incomplete painful extension of the knees were present. Periodically he had radicular pain in his legs and right shoulder. On the last check-up, additional findings were observed: slit-lamp examination showed multiple pigmented iris hamartomas (Lisch nodules); nuclear magnetic resonance (NMR) showed multiple neurofibromas in subcutaneous and paratracheal muscle region; all along the spinal cord but mainly in the left nuchal region and lumbosacral region bilaterally, within the spinal canal, intervertebral foramina and paraspinally, and also in the retroperitoneal and pelvic region NMR showed multiple neurofibromas that were in concordance with pain; NMR revealed hamartoma in the area of globus pallidus on the left side of crura cerebri; x-ray of distal metaphysis

of the right lower leg showed an ovoid transparent zone.

Family history for NF-1 was positive as the father had the disease. The linkage analysis using polymorphic gene markers of NF-1 (exon 5 RsaI polymorphism) revealed the pHHH202/RsaI haplotype that is inherited through generations (Fig. 2). As there was no family history of DNS and melanoma, the diagnosis of DNS type A (sporadic DNS without melanoma) was established (7,8).

DISCUSSION

The knowledge of the migration, differentiation and physiologic phenotypes of the tissues of the neural crest is essential for understanding the pathogenesis of NF-1. Neurocristopathy is a term that unites a variety of dysgenetic, hamartomatous and neoplastic conditions originating in the neural crest (9). These tumors are peripheral sheath tumors, mostly malignant schwannoma, astrocytoma, glioblastoma but also endocrine malignancies such as pheochromocytoma and thyroid medullary carcinoma (3,4). Malignant transformation of the nerve sheath tumors is characterized by acceleration in growth and change in configuration, and it has been reported in 2%-40% of patients with NF-1 (9).

The association between congenital melanocytic nevi and NF-1 has been reported in 1%-15% of patients (5,10,11). An increased risk of giant congenital melanocytic nevi has also been reported in patients with NF-1 (5,12,13). Moreover, melanocytic nevi were identified in 11% of patients with NF-1 (5,10). Additionally, neurofibromas in

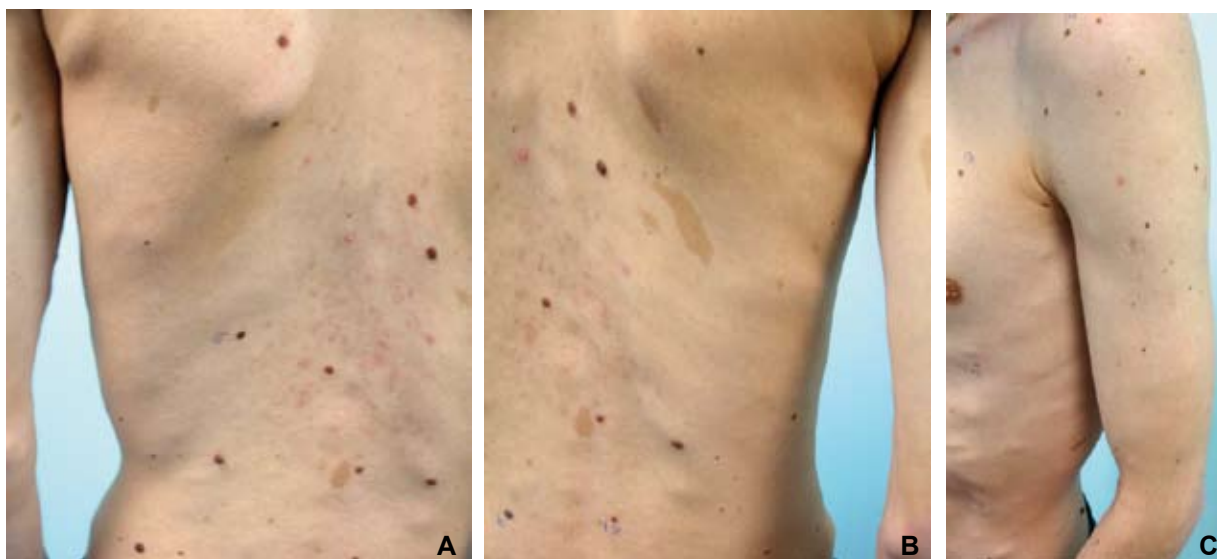


Figure 1A-C. Numerous subcutaneous nodular neurofibromas, *café au lait* spots, and dysplastic nevi.

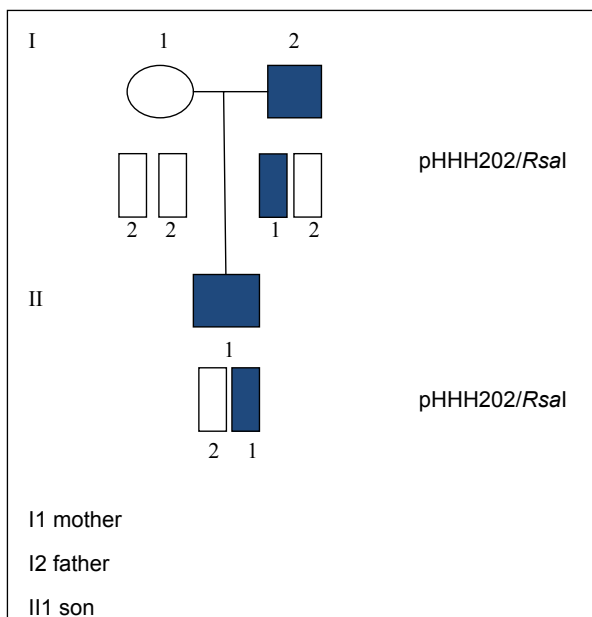


Figure 2. The linkage analysis using polymorphic gene markers of NF-1 (exon 5 RsaI polymorphism) revealed pHHH202/RsaI haplotype that is inherited through generations.

patients with NF-1 are reported to be associated with melanocytic nevi but not with sporadic neurofibromas (10). Moreover, reports of melanocytic malignancies such as uveal, leptomeningeal, mu-

cosal, penile, cutaneous melanoma, and melanoma within congenital nevi in association with NF-1, and also cutaneous melanoma in association with both NF and DNS are rare, and an increased risk has not been clearly demonstrated (Table 1) (2-4,9,13-17). According to Guillot *et al.*, an increase in melanoma incidence in patients with NF1 remains hypothetical but a small series of malignant melanoma arising in NF-1 patients displays a large female predominance, higher thickness and frequent association with a second neoplasia (4).

Furthermore, NF-1 patients have an increased number of melanocytes in the *café au lait* spots as well as in their normal skin, suggesting a proliferative process of melanocytes in NF-1 (2,9). The melanocyte, a neural crest derivative, is not only responsible for one of the most prominent features of NF, *café au lait* maculae, but also for melanocytic pigmented iris hamartomas, choroidal multifocal and bilateral nevi, uveal nevi in general, cutaneous nevi and congenital giant melanocytic nevi (5,9). Uveal nevi in general, but mainly choroidal nevi may present an increased risk for the development of uveal melanoma, although some studies did not detect such an association (18-20).

The possible mechanism of the occurrence of malignancies with NF-1 is a mutation of the neurofibromin protein that participates in cell prolifer-

Table 1. Cases of neurofibromatosis (NF) with melanoma and/or atypical nevi, and/or congenital melanocytic nevi

Authors (ref. no.)	Comments
Bin Amer Y, <i>et al.</i> (3)	NF-1 with metastatic melanoma arising from giant melanocytic nevi within speckled lentiginous nevus
Guillot B, <i>et al.</i> (4)	11 patients with both melanoma and NF-1 among 4 centers using registers for both disease (671 cases of NF-1 and 2618 of melanoma); this retrospective multicenter study revealed female predominance, higher tumor thickness and frequent association with second neoplasia
Gutzmer R, <i>et al.</i> (6)	Allelic loss of the NF-1 gene locus described in 67% of desmoplastic neurotropic melanoma (DNM) and 5% of common melanomas; these data may suggest a role of NF-1 in the pathogenesis of DNM
Stokkel MP, <i>et al.</i> (9)	Two sisters with melanoma, NF and multiple atypical nevi from a family with familial atypical multiple mole syndrome
Ball NJ, <i>et al.</i> (10)	Melanocytic nevi associated with neurofibromas in NF-1, but not with sporadic neurofibromas: a retrospective case-control study of 226 cases
Brasfield RD, <i>et al.</i> (12)	Six melanomas in NF patients, three arising in giant congenital nevus
Doherty SD, <i>et al.</i> (13)	A case with segmental NF and melanoma within large congenital nevus
Mastrangelo MJ, <i>et al.</i> (14)	Case history of a patient with NF and a nodular melanoma unrelated to a <i>café-au-lait</i> spot or congenital nevus
Gach JE, <i>et al.</i> (15)	Multiple congenital melanocytic nevi with neurofibroma-like lesions complicated by melanoma
Silfen R, <i>et al.</i> (16)	A case of NF-1 and giant congenital hairy nevi
Gallino G, <i>et al.</i> (17)	Three clinical cases of cutaneous melanoma and NF-1

eration control by inactivation of p21 ras. Furthermore, the neurofibromin protein is a regulator of melanogenesis as an activator of the tyrosinase gene promoter (3,4,13). Moreover, in sporadic melanoma cell lines, mutations in NF-1 gene have been described (3,4). Also, allelic loss of the NF-1 gene locus has been described in desmoplastic neurotropic melanoma (6). However, two cases of melanoma associated with NF in two first degree relatives from a family with DNS have been described (9). Furthermore, multiple congenital melanocytic nevi presenting with neurofibroma-like lesions complicated by melanoma have been reported (15). DNS distinguishes type A, B, C, D-1 and D-2 differentiating between sporadic and familial type and connection to positive melanoma history (7,8). DNS is a marker of the melanoma risk and the risk rises with the type of DNS (8). Hence, in our patient there was NF-1 with a still unknown increased risk of melanoma and DNS type A with a known risk of cutaneous and ocular melanoma, thus presenting a complex problem.

CONCLUSION

A case of NF-1 with DNS type A presenting with multiple neural tumors, *café au lait* spots, hamartomas in globus pallidus and pigmented iris hamartomas is described. Although NF and cutaneous melanoma are both diseases of neuroectodermal origin, reports of their association are rare and the relation between cutaneous melanoma and NF has not yet been definitely established. Additionally, the effect of NF-1 mutations in melanoma risk patients with both NF-1 and DNS is not known. Although DNS could possibly be seen as the underlying disease, research into pigmentary disturbance in NF-1 is necessary to give definitive explanation.

We emphasize the importance of close follow up of nevi in patients with NF-1 and DNS for the development of melanoma as well as other NF-1 associated skin disorders, and the multidisciplinary approach to other associated diseases.

References

1. Paštar Z, Lipozenčić J, Budimčić D, Tomljanović-Veselski M. Neurofibromatosis – review of the literature and case report. *Acta Dermatovenerol Croat* 2006;14:167-71.
2. De Schepper S, Boucneau J, Lambert J, Messiaen L, Naeyaert JM. Pigment cell-related manifestations in neurofibromatosis type 1: an overview. *Pigment Cell Res* 2005;18:13-24.
3. Bin Amer Y, Al-Khenaizan S. Fatal malignant melanoma in a child with neurofibromatosis type 1. *Int J Dermatol* 2007;46:967-70.
4. Guillot B, Dalac S, Delaunay M, Baccard M, Chevrant-Breton J, Dereure O, *et al.*; French Group of Cutaneous Oncology. Cutaneous malignant melanoma and neurofibromatosis type 1. *Melanoma Res* 2004;14:159-63.
5. Aber CG, Alvarez Connelly E, Schachner LA. Syndromes involving melanocytic lesions. In: Soyer HP, Argenziano G, Hofmann-Wellenhof R, Jorh R, editors. *Color atlas of melanocytic lesions of the skin*. 1st ed. Berlin, Heidelberg: Springer-Verlag; 2007. pp. 164-72.
6. Gutzmer R, Herbst RA, Mommert S, Kiehl P, Matiaske F, Rütten A, *et al.* Allelic loss at the neurofibromatosis type 1 (NF1) gene locus is frequent in desmoplastic neurotropic melanoma. *Hum Genet* 2000;107:357-61.
7. Kopf AW, Friedman RJ, Rigel DS. Atypical mole syndrome. *J Am Acad Dermatol* 1990;22:117-8.
8. Hofmann-Wellenhof R, Spyer HP. Atypical (dysplastic) nevus. In: Soyer HP, Argenziano G, Hofmann-Wellenhof R, Jorh R, editors. *Color atlas of melanocytic lesions of the skin*. 1st ed. Berlin, Heidelberg: Springer-Verlag; 2007. pp. 87-96.
9. Stokkel MP, Kroon BB, van der Sande JJ, Nering H. Malignant cutaneous melanoma associated with neurofibromatosis in two sisters from a family with familial atypical multiple mole melanoma syndrome. Case reports and review of the literature. *Cancer* 1993;72:2370-5.
10. Ball NJ, Kho GT. Melanocytic nevi are associated with neurofibromas in neurofibromatosis type I, but not sporadic neurofibromas: a study of 226 cases. *J Cutan Pathol* 2005;32:523-32.
11. Wander JV, Das Gupta TK. Neurofibromatosis. *Curr Probl Surg* 1977;14:1-81.
12. Brasfield RD, Das Gupta TK. Von Recklinghausen's disease: a clinicopathological study. *Ann Surg* 1972;175:86-104.
13. Doherty SD, George S, Prieto VG, Gershenwald JE, Duvic M. Segmental neurofibromatosis in association with a large congenital nevus and malignant melanoma. *Dermatol Online J* 2006;12:22.

14. Mastrangelo MJ, Goepf CE, Patel YA, Clark WH Jr. Cutaneous melanoma in a patient with neurofibromatosis. *Arch Dermatol* 1979;115:864-5.
15. Gach JE, Carr RA, Charles-Holmes R, Harris S. Multiple congenital melanocytic naevi presenting with neurofibroma-like lesions complicated by malignant melanoma. *Clin Exp Dermatol* 2004;29:473-6.
16. Silfen R, Skoll PJ, Hudson DA. Congenital giant hairy nevi and neurofibromatosis: the significance of their common origin. *Plast Reconstr Surg* 2002;110:1364-5.
17. Gallino G, Belli F, Tragni G, Ferro F, Massone PP, Ditto A, *et al.* Association between cutaneous melanoma and neurofibromatosis type 1: analysis of three clinical cases and review of the literature. *Tumori* 2000;86:70-4.
18. Harbour JW, Brantley MA Jr, Hollingsworth H, Gordon M. Association between choroidal pigmentation and posterior uveal melanoma in a white population. *Br J Ophthalmol* 2004;88:39-43.
19. Harbour JW, Brantley MA Jr, Hollingsworth H, Gordon M. Association between posterior uveal melanoma and iris freckles, iris naevi, and choroidal naevi. *Br J Ophthalmol* 2004;88:36-8.
20. Smith JH, Padnick-Silver L, Newlin A, Rhodes K, Rubinstein WS. Genetic study of familial uveal melanoma: association of uveal and cutaneous melanoma with cutaneous and ocular nevi. *Ophthalmology* 2007;114:774-9.

KAKO ĆETE SE RIJEŠITI NABORA

ŠTO SAM NAUČILA OD JEDNOG SPECIJALISTE ZA KOZMETIKU

Za vrijeme spavanja koža na licu pustiti i najlakše apsorbira hranive sastojine Biocela, koji se sada nalazi u kremi Tokalon, ružičaste boje. Time nestaju bore, znakovi umora i ostale pogrješke tena. Izjutra se pojavi svježa, jasna i lijepa nova koža koja se je nalazila ispod stare. Na taj način izgleda svaka žena za 10-15 godina mlađa.

Ovo mi je rekao jedan znameniti pariški kozmetičar, kada mi je pripovijedao o sjajnom pronalasku bečkog sveučilišnog profesora Dra Stejskala, koji je otkrio Biocel. On je dokazao da uzrok borama i omlohavljenim ličnim mišićima nije starost nego pomanjkanje Biocela u koži. Ovo dragocjeno sredstvo za pomladjivanje, koje se dobiva od mladih životinja, nalazi se pomiješano u kremi Tokalon, ružičaste boje. Pokušajte večeras i već sutra ćete izgledati mlađjom.

How to solve wrinkles - use Tokalon cream; year 1929.
(from the collection of Mr. Zlatko Puntijar)