

# Immediate Implantation in Infected Tooth Sockets

Joško Viski<sup>1</sup>, Slađana Milardović<sup>1</sup>, Davor Katanec<sup>2</sup>, Denis Vojvodić<sup>1</sup> and Ketij Mehulić<sup>1</sup>

<sup>1</sup> University of Zagreb, School of Dental Medicine, Department of Prosthodontics, Zagreb, Croatia

<sup>2</sup> University of Zagreb, School of Dental Medicine, Department of Oral Surgery, Zagreb, Croatia

## ABSTRACT

*Although immediate implantation has not been previously recommended in infected sites, it is now becoming a procedure of choice in modern implant dentistry. We report a case of a 65-year-old male patient, who required multiple tooth extractions in the lower jaw and fabrication of a new overdenture in the lower jaw and a complete denture in the upper jaw. Immediate implantation in infected tooth sockets followed extraction. Two NobelReplace™ Tapered implants (Nobel BioCare, Zürich, Switzerland), one 13 mm long and 4.3 mm wide and the other 13 mm long and 5.0 mm wide, were placed in the position 33 and 43. The site was sutured and a temporary denture was fabricated by adjusting the old denture. After a period of three months the implant site was reopened and healing abutments were placed. Impressions were made using the Impregum Penta Soft (3M ESPE, St. Paul, Minn, USA) polyether material. Ball Abutment Titanium™ was used as a patrix attachment and a matrix was inserted into the denture. Clinical examination and x-ray analysis after six months showed no significant changes of the implants. Bone resorption was within standard values. Although it is still a controversial subject, immediate implantation in infected sites can be a safe and predictable procedure if surgical protocols are followed. However, further research is needed to draw firm conclusions.*

**Key words:** implants, immediate implantation, infection, periodontitis, tooth socket

## Introduction

Immediate implantation is a growing trend in modern implant dentistry. It has become a preferred procedure for both dentists and patients. Immediate placement of an implant after tooth extraction has several advantages. It maintains the horizontal and vertical dimensions of osseous tissues and keeps implants at the same angulations as the pre-existing natural teeth<sup>1</sup>. It can also be performed without raising a flap, which altogether reduces the number of surgical procedures, postoperative complications and treatment time and costs<sup>2–4</sup>. With evolution of implant protocols and implant surfaces, it has become a predictable procedure.

Despite these advantages, there are clinical cases where immediate implant placement has not been recommended so far<sup>5</sup>. Infected implant sites have been considered unsuitable for implant placement because of their lower osseointegration values. Implant protocols required extraction of the affected tooth and delayed implant placement<sup>6–10</sup>.

Numerous attempts to review such protocols have been made. Novaes et al. state that immediate implanta-

tion in infected tooth sockets can be successful if certain preoperative and postoperative measures are followed, such as antibiotic administration, meticulous cleaning, and alveolar debridement<sup>11</sup>. Lindeboom et al. and Siegenthaler et al. reported no higher complication rate of implant placement and success in infected sites than in non-infected sites<sup>12,13</sup>.

## Case Description and Results

We report a case of a 65-year-old male patient who visited the Department of Prosthodontics of the School of Dental Medicine, University of Zagreb. He was not satisfied with his upper and lower denture and complained of a pain in the area of the lower right canine. He reported no significant conditions in his general medical history. During intraoral examination a complete acrylic upper denture and a ball attachment retained lower overdenture were found. Both dentures were in poor condition and in need of replacement (Figure 1). The upper jaw was edentulous. Both distal areas of the lower jaw were

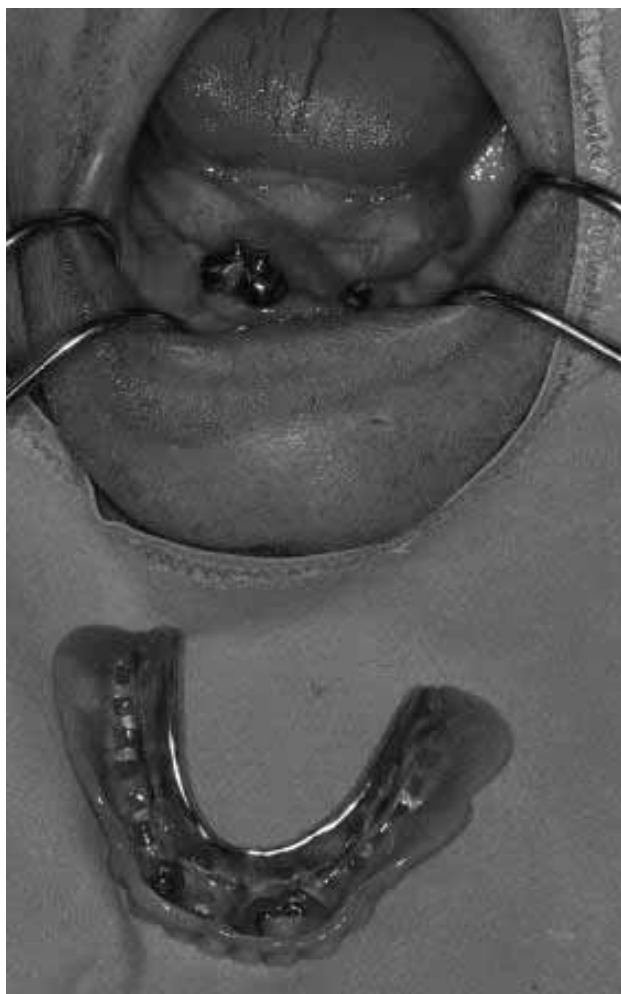

Fig. 1.

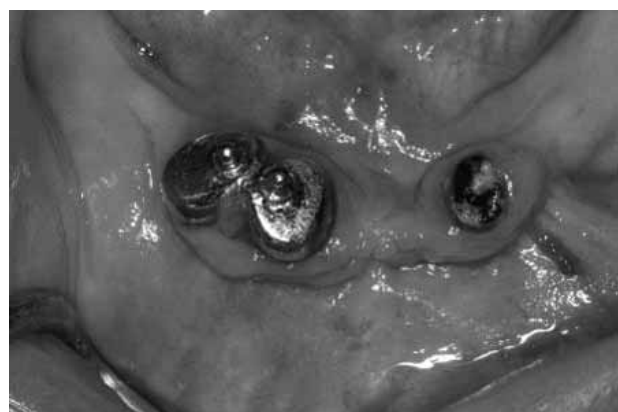


Fig. 2.

edentulous and showed class III alveolar ridge resorption according to the classification by Kent et al.<sup>14</sup>. The remaining teeth in the mandible were severely compromised. Both the tooth 42 and the tooth 43, previously restored with modified crowns with ball attachments, had severe periodontal problems. Inflammation of the sur-

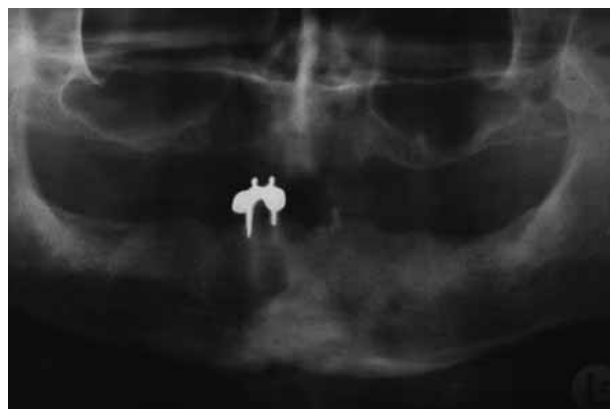

Fig. 3.

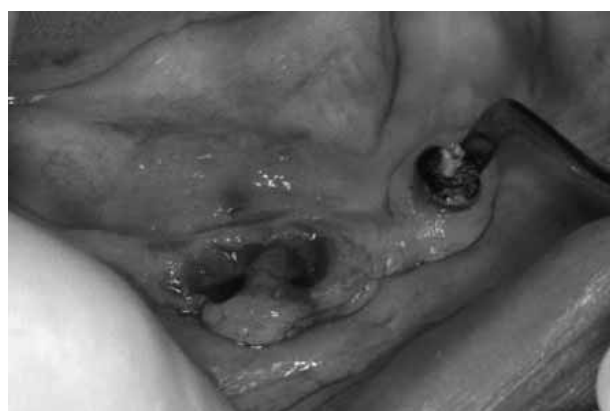

Fig. 4.

rounding gingiva, bleeding and pus were visible (Figure 2). We also found a radix relictæ of the tooth 33 in a similar condition. It had also been previously restored with a modified crown with ball attachments, but the tooth crown had fractured and only the root remained had fractured and only the root remained. Orthopantomographic (OPG) x-ray images were made, which confirmed our initial findings (Figure 3).

A complete treatment plan for both the upper and the lower jaw was devised in consultation with the patient. It was decided to fabricate a new complete acrylic upper denture due to favourable ridge condition. An overdenture supported by two dental implants was chosen for the lower jaw due to the degree of ridge resorption. It was also decided, by obtaining the patient's informed consent, to perform immediate implant placement. The surgical procedure was performed by the implant team from the Department of Oral Surgery at the School of Dental Medicine in Zagreb. The remaining teeth 42, 43 and the residual root of the tooth 33 were extracted atraumatically with the use of a periosteal elevator (Figure 4). After extraction, meticulous alveolar debridement, cleaning and irrigation with metronidazole solution (0.5% Metronidazol Genericon solution for intravenous infusion, Genericon Pharma G.m.b.H., Graz, Austria) and saline fluid were

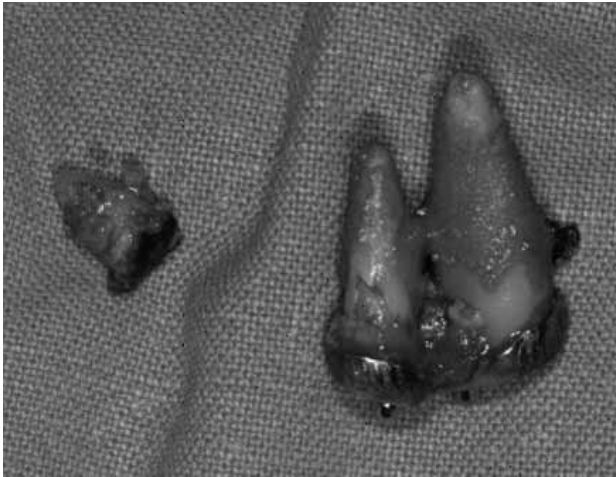


Fig. 5.

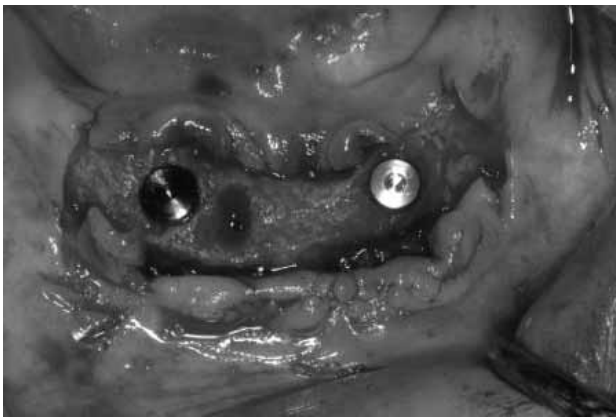


Fig. 6.

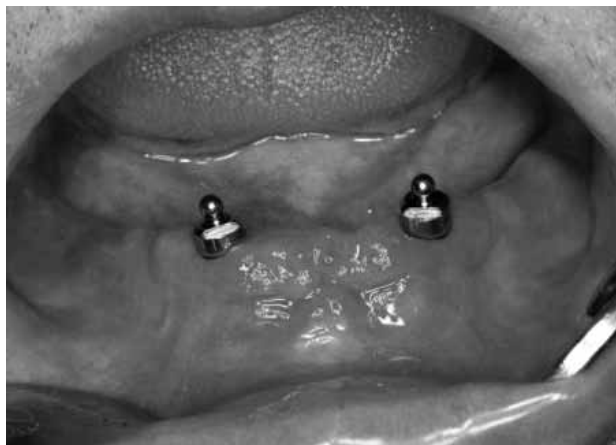

Fig. 7.

performed to remove any residual infected granulation tissue and bone. The extracted teeth and the residual tooth root showed periodontal damage (Figure 5). After cleaning and debridement, a Wasmund flap technique was used and two Two NobelReplace™ Tapered implants

(Nobel BioCare, Zürich, Switzerland), one 13 mm long and 4.3 mm wide and the other 13 mm long and 5.0 mm wide, were placed in the position 33 and 43 (Figure 6). The site was sutured and a temporary denture was fabricated by adjusting and lining the old denture with a silicone lining material. According to the literature that was consulted, antibiotic treatment was prescribed using 2 g amoxicillin a day (Amoxicilin 500 mg, Belupo d.d., Koprivnica, Croatia) and 1.2 g metronidazol a day (Medazol 400 mg, Belupo d.d., Koprivnica, Croatia), 5 days prior to and 10 days after implantation<sup>11–13</sup>. Ibuprofen 1.2 g a day for 3 days was prescribed for regulation of pain and swelling (Neofen forte, Belupo d.d., Koprivnica, Croatia). No corticosteroids were prescribed for the patient. The patient was given instruction how to maintain oral hygiene and a 0.2% chlorhexidine digluconate antibacterial oral mouthwash (Corsodyl, Glaxo Smith Kline, Brentford, Middlesex, United Kingdom) was prescribed for a ten day period. After 10 days there were no signs of post-operative reactive inflammation and the antibiotic treatment was suspended. The patient reported no side effects commonly associated with use of these antibiotics. After



Fig. 8.

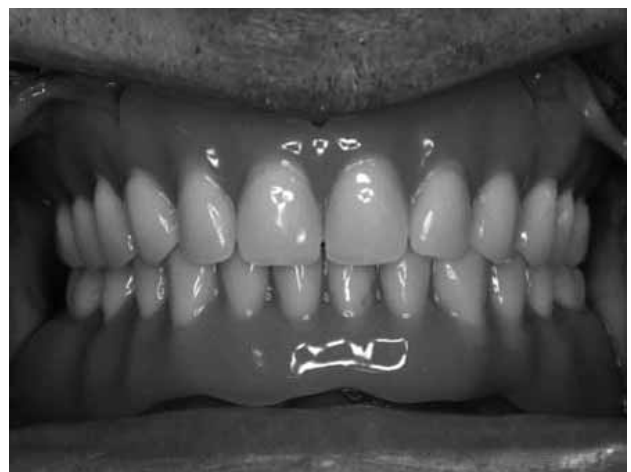


Fig. 9.



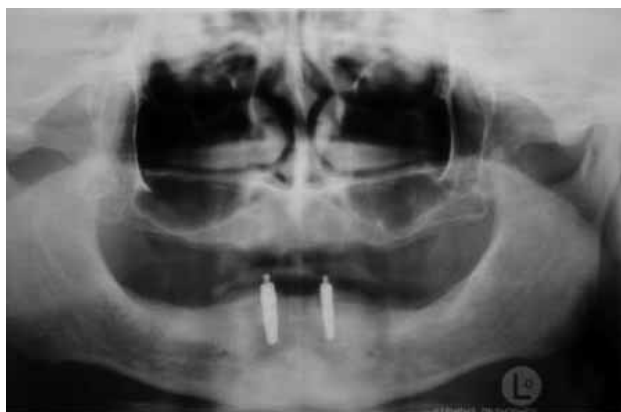

Fig. 10.

a period of three months the implant site was reopened and healing abutments were placed. Two Ball Abutment Titanium™ abutments were used for the fabrication of attachments (Figure 7). Impressions were made using the Impregum Penta Soft (3M ESPE, St. Paul, Minn., USA) polyether impression material. The lower overdenture was fabricated and implant attachments were inserted into the denture (Figure 8). The upper denture was also fabricated at the same time (Figure 9). The patient was very satisfied with his new restoration. He was given specific instructions how to maintain oral hygiene and a series of follow-up appointments were scheduled. Both at the six-month and 1-year follow-up appointment no clinically visible changes of the implants' condition were established. The patient reported no complications with his implants, lower overdenture and upper complete denture. An OPG was done at the six-month follow-up appointment, which also showed good bone levels (reduction of approximately 1.5 mm) around the implants, with no visible peri-implant inflammation (Figure 10). The patient was scheduled for further follow-ups every six months.

## Discussion

Immediate implantation is still a very controversial subject with an ongoing debate. Goldberg openly criticises the concept and questions of justification for the violation of the well-established principle of avoidance of foreign body placement into infected sites. He also raises the question of egregious overuse and possible side effects of antibiotics<sup>15</sup>. However, Casap defends the concept

## REFERENCES

1. PECORA G, ANDREANA S, COVANI U, DE LEONARDIS D, SCHIFFERLE RE, *J Endod*, 22 (1996) 135. — 2. GABRIĆ PANDURIĆ D, KATANEC D, GRANIĆ M, KOMLJENOVIC-BLITVA D, BASHA M, SUSIĆ M, *Coll Antropol*, 32 (2008) 529. — 3. BERSANI E, COPPEDE AR, DE PAULA PINTO PRATA HH, *Int J Periodontics Restorative Dent*, 30 (2010) 291. — 4. LAUC T, KOBLER P, *Coll Antropol*, 22 Suppl (1998) 251. — 5. QUIRYNEN M, GIJBELS F, JACOBS R, *Periodontol* 2000, 33 (2003) 129. — 6. ATTARD NJ, ZARB GA, *J Prosthet Dent*, 94 (2005) 242.

with the emphasis on alveolar debridement and cleaning of the infected site. He also indicates that antibiotic use in such cases may in the long term reduce the amount of antibiotics due to a reduced number of surgical procedures and targeted approach<sup>16</sup>.

A recent animal model study showed that the bone-implant connection in infected tooth sockets was significantly lower than in non-infected sites, but both the control and the experimental groups showed clinically acceptable results<sup>17</sup>. Another earlier animal model study also using histomorphometric analysis revealed no significant difference in the percentage of bone to implant contact between infected and healthy sites. All implants were successfully osseointegrated and no signs of inflammation or exudation were observed during the healing period<sup>18</sup>. A multicenter study analyzed implant failure with respect to reasons for tooth extraction over a period of 3 years. Immediate implant placement into sites with periodontal lesions was not described as a risk factor of implant failure<sup>19</sup>.

Bone level reduction around the placed implants was approximately 1.5 mm. Hämmerle et al. previously demonstrated that bone is resorbed to a level apical to the smooth neck portion of the implant<sup>20</sup>. This finding is also in agreement with the results from previous studies, where implants were placed into fresh extraction tooth sockets or into healed bone according to standard procedures<sup>21</sup>. The vertical bone loss observed at the implant sites results from the vertical implant position and the changes caused by the biological process of tissue integration<sup>13</sup>.

## Conclusion

Immediate implantation in infected tooth sockets can be a successful procedure as shown in this case if certain protocols are followed. However, further longitudinal studies are required to draw firm conclusions.

## Acknowledgements

This study was supported by the Ministry of Science, Education and Sports (MSES) of the Republic of Croatia 065-0650446-0435 and 065-0000000-0424.

The paper was presented as a poster presentation at the 3rd International Congress of the Croatian Society of Dental Implantology of the Croatian Medical Association.

— 7. LAZZARA RJ, *Int J Periodontics Restorative Dent*, 9 (1989) 332. — 8. BECKER W, DAHLIN C, LEKHOLM U, BERGSTROM C, VAN STEENBERGHE D, HIGUCHI K, BECJER BE, *Clin Implant Dent Relat Res*, 1 (1999) 27. — 9. SCHROPP L, KOSTOPOULOS L, WENZEL A, *Int J Oral Maxillofac Implants*, 18 (2003) 189. — 10. GELB DA, *Int J Oral Maxillofac Implants*, 8 (1993) 388. — 11. NOVEAS AB JR, NOVEAS AB, *Int J Oral Maxillofac Implants*, 10 (1995) 609. — 12. LINDEBOOM JA, TJIOOK Y, KROON FH, *Oral Surg Oral Med Oral Pathol Oral Radiol*

- Endod, 101 (2006) 705. — 13. SIEGENTHALER DW, JUNG RE, HOLDEREGGER C, ROOS M, HÄMMERLE CH, Clin Oral Implants Res, 18 (2007) 727. — 14. KENT JN, QUINN JH, ZIDE MF, FINGER IM, JARCHO M, ROTHSTEIN SS, J Am Dent Assoc, 105 (1982) 993. — 15. GOLDBERG MH, J Oral Maxillofac Surg, 66 (2008) 1081. — 16. CASAP N, J Oral Maxillofac Surg, 66 (2008) 2415. — 17. CHANG SW, SHIN SY, HONG JR, YANG SM, YOO HM, PARK DS, OH TS, KYE SB, Oral Surg Oral Med Oral Pathol Oral Radiol Endod, 107 (2009) 197. — 18. NOVAES AB JR, MARCACCINI AM, SOUZA SL, TABA M JR, GRISI MF, Int J Oral Maxillofac Implants, 18 (2003) 391. — 19. GRUNDER U, POLIZZI G, GOENÉ R, HATANO N, HENRY P JACKSON WJ, KAWAMURA K, KÖHLER S, RENOUEARD F, ROSENBERG R, TRIPLETT G, WERBITT M, LITHNER B, Int J Oral Maxillofac Implants, 14 (1999) 210. — 20. HÄMMERLE CH, BRÄGGER U, BÜRGIN W, LANG NP, Clin Oral Implants Res, 7 (1996) 111. — 21. HÄMMERLE CH, BRÄGGER U, SCHMID B, LANG NP, Int J Oral Maxillofac Implants, 13 (1998) 522.

J. Viskić

University of Zagreb, School of Dental Medicine, Department of Prosthodontics, Gundulićeva 5, 10000 Zagreb, Croatia  
e-mail: viskic@sfzg.hr

## IMEDIJATNA IMPLANTACIJA U INFICIRANU ALVEOLU

### SAŽETAK

Iako se imedijatna implantacija dosada nije preporučivala u inficiranim područjima, odnedavno postaje postupak izbora u suvremenoj implantologiji. Prikazan je slučaj 65-godišnjeg muškarca kojem je bilo indicirano višestruko vađenje zubi u donjoj čeljusti i izrada nove pokrovne proteze te izrada potpune proteze u gornjoj čeljusti. Implantacija u inficiranu alveolu izvršena je odmah po vađenju zubi. Dva NobelReplace™ Tapered implantata (Nobel BioCare, Zürich, Švicarska), jedan dužine 13 mm i širine 4,3 mm te drugi dužine 13 mm i širine 5,0 mm, postavljeni su u područje 33 i 43. Mjesto je zašiveno, a prilagodbom stare proteze pacijent je privremeno opskrbljen. Nakon tri mjeseca postavljene su nadogradnje za cijeljenje. Otisci su uzeti korištenjem polieterskog materijala Impregum Penta Soft (3M ESPE, St. Paul., Minn., SAD). Ball Abutment Titanium™ korišten je kao patrica, a matrica je dodana u protezu. Klinički pregled i rendgenska analiza nakon šest mjeseci nisu pokazali nikakve značajne promjene na implantatima. Razina resorpcije kosti oko implantata ostala je unutar standardnih vrijednosti. Iako je imedijatna implantacija u inficiranoj alveoli još uvijek sporna tema, ovakav postupak može biti siguran i predvidljiv ako se prati kirurški protokol. Međutim, potrebna su daljnja klinička istraživanja za donošenje konačnih zaključaka.