

After 40 Years Gossypiboma Caused Spleen Abscess

Mihovil Ivica¹, Mario Ledinsky¹, Božo Radić¹, Aleksandar Savić¹, Davor Tomas², Dinko Vidović¹, Mladen Tomljenović¹, Mario Zovak¹, Aljoša Matejčić¹ and Branimir Nevajda¹

¹ Department of Surgery, University Hospital »Sestre milosrdnice«, Zagreb, Croatia

² Department of Pathology, University Hospital »Sestre milosrdnice«, Zagreb, Croatia

ABSTRACT

We report a case of spleen abscess caused by foreign body (gossypiboma) after 40 years. After physical examination, laboratory, ultrasonography and CT findings with diagnosis of acute abdomen, 73 years old woman had undergone laparotomy. Operation revealed intraabdominal spleen abscess. Capsulotomy and drainage of the collection was performed before splenectomy. Histological examination showed foreign body material surrounded by chronic inflammation, foreign body-type multinucleated giant cells, extravasated red blood cells and fibroblastic proliferation. From anamnesis we found that woman was operated only once during a life with diagnosis of extrauterine pregnancy, 40 years ago. Spleen abscess caused by gossypiboma after 40 years was never described before. However, diagnosis like this is very well known but rarely published because medical-legal implication. Education, professionalism and cooperation of all persons involved in surgical procedure are very important to prevent accidentally mistakes.

Key word: gossypiboma, spleen, abscess

Introduction

There are many cases of foreign bodies (gossypiboma) left after surgical procedure. We report very unusual case of spleen abscess caused by gossypiboma after 40 years.

Case Report

We report unusual case of spleen abscess caused by left surgical gauze. One night, a 73-year old woman was admitted to our hospital with fever (38.7°C) and strong pain in left upper abdominal quadrant. Routine laboratory testing revealed leukocytes number count $16.2 \times 10^9/L$ (normal $3.4-9.7 \times 10^9/L$) and CRP 162 mg/L (normal <5.0 mg/L). Standard abdominal X-ray didn't suggest any findings, but abdominal ultrasonography (Figure 1) and CT (Figure 2) showed left subfrenical dense collection adjacent to spleen. Under the impression of intra-abdominal abscess and positive acute abdominal signs, exploratory laparotomy was performed. At laparotomy focal abscess on upper spleen pole was found. After cap-

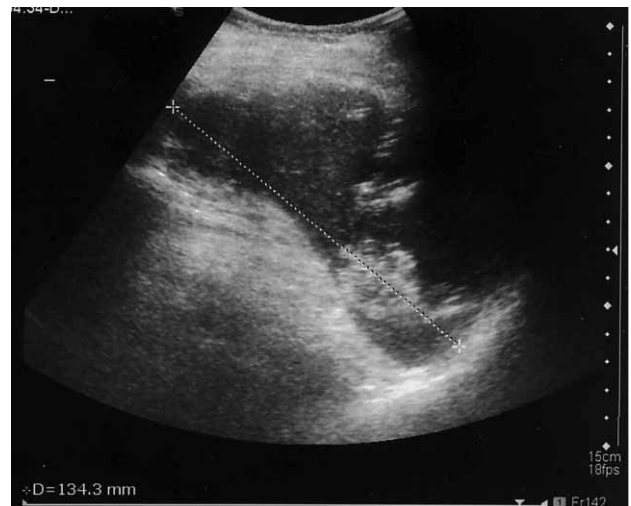

Fig. 1. Ultrasonography of spleen: shows enlarged spleen with collection of necrotic material in the upper pole with the diameter of 13.4 cm.

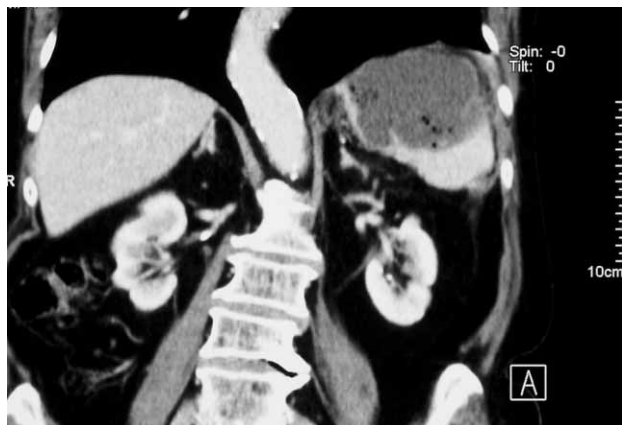

Fig. 2. CT finding (with intravenous contrast): by lateral pole of spleen there is an aero-liquid collection, coefficient absorption 20 HU that can not be imbibed with a contrast, dimension 13 × 7 cm which indicates formed spleen abscess.

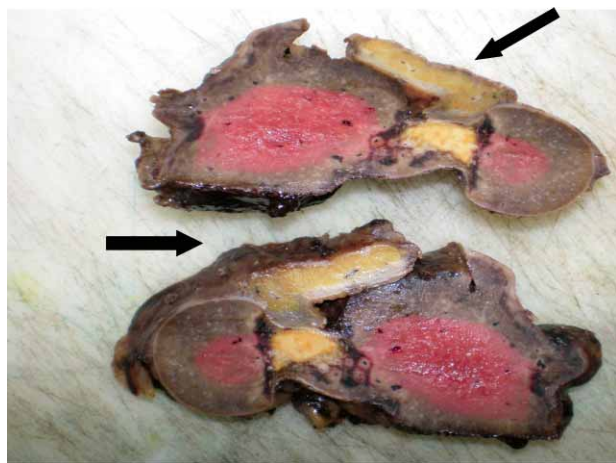


Fig. 3. Macroscopic finding: shows spleen tissue, with formed necrotic abscess (arrows) that penetrates spleen tissue.

sular resection and drainage of collection, splenectomy was performed (Figure 3). Pathology findings confirmed granulomatous inflammation with massive fibrosis and foam cell and multinucleated giant cell infiltrations with inorganic fragments in spleen. Inorganic fragment were identified as gauze cotton fibers (Figure 4). Anamnesis revealed that woman had extrauterine pregnancy and was operated 40 years ago.

REFERENCES

1. OKTEN AI, ADAM M, GEZERCAN Y, Eur Spine J, 15 (2006) 626. — 2. CHENG TC, CHOU AS, JENG CM, CHANG PY, LEE CC, J Chin Med Assoc, 70 (2007) 565. — 3. GIFFORD RR, PLAUT MR, MCLEARY RD, JAMA, 223 (1973) 1040. — 4. STOLL A, Surg Neurol, 30 (1988) 235. — 5. SUN HS, CHEN SL, KUO CC, WANG SC, KAO YL, J Chin Med Assoc, 70 (2007) 511. — 6. ERDIL A, KILCILER G, ATES Y, TUZUN A, GULSEN M, KARADEREN N, DAGALP K, Intern Med, 47 (2008) 613. —

Discussion

Gossypiboma is a term used to indicate cotton-based (Latin-gossypium) foreign bodies that are in a »place of concealment« (Kiswahili-boma) following surgery. Cases like this are very well known but rarely published because of medical-legal implication. Although precautions are taken to avoid leaving such materials behind, mistakes do happen and the resultant foreign bodies can cause various clinical and radiological manifestations^{1–3}.

In the early period after surgery, these materials left after surgery can lead to infections and abscess formation. However, some remain clinically asymptomatic for many years, and then cause a foreign body reaction in the surrounding tissue, with new clinical signs indicating significant mass effect^{3–5}. Cases of intraabdominal foreign bodies found after many years^{6–9} and in many forms^{4,10–14} are known from literature, but we didn't find any case of spleen abscess caused by gossypiboma after 40 years (PUBMED search). Radiopaque threads impregnated into surgical gauzes were first introduced by Cahn in 1929¹⁵, but did not come into general use in many countries till today. In conclusion, education, professionalism and cooperation of all persons involved in surgical procedure are very important to prevent accidental mistakes.

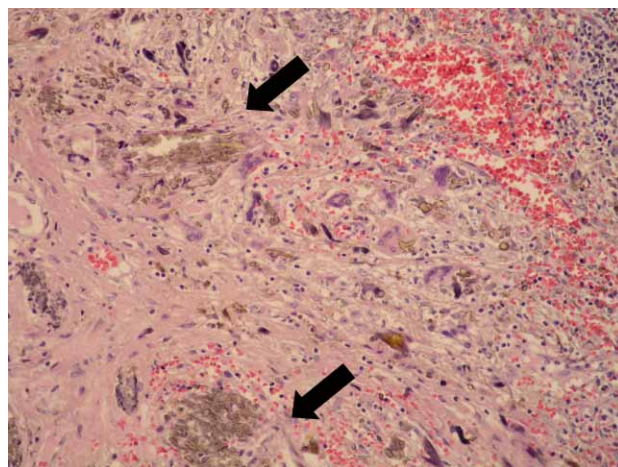


Fig 4. Microscopic finding (HE stain ×200): shows the presence of partially necrotic, foreign body (arrows) material which is surrounded by chronic inflammation, foreign body-type multinucleated giant cells, extravasated red blood cells and fibroblastic proliferation. These findings confirm the diagnosis of gossypiboma.

7. BOTET DEL CASTILLO FX, LÓPEZ S, REYES G, SALVADOR R, LLAURADÓ JM, PEÑALVA F, Br J Surg, 82 (1995) 227. — 8. O'CONNOR AR, COAKLEY FV, MENG MV, EBERHARDT SC, AJR Am J Roentgenol, 180 (2003) 481. — 9. O'CONNOR AR, COAKLEY FV, Semin Ultrasound, CT MR 25 (2004) 290. — 10. TAYLOR FH, ZOLLINGER RW II, EDGERTON TA, HARR CD, SHENOY VB, J Thorac Imaging, 9 (1994) 56. — 11. KATO K, SUZUKI K, SAI S, MURASE T, HARUTA J,

Hinyokika Kyo (Acta urologica Japonica), 46 (2000) 491. — 12. SAKAYAMA K, FUJIBUCHI T, SUGAWARA Y, KIDANI T, MIYAWAKI J, YAMAMOTO H, Skeletal Radiol, 34 (2005) 221. — 13. MBOTI B, GEBHART M, LARSIMONT D, ABDELKAFI K, Acta Orthop Belg, 67

(2001) 513. — 14. KALBERMATTEN DF, KALBERMATTEN NT, HERTEL R, Skeletal Radiol, 30 (2001) 415. — 15. RYMER CA, MCCARTHY JD, Am J Surg, 128 (1974) 103.

Mihovil Ivica

*University Hospital »Sestre milosrdnice«, Vinogradska cesta 29, 10000 Zagreb, Croatia
E-mail: mihovil.ivica@gmail.com*

NAKON 40 GODINA GOSIPIBOMA JE UZROK APSCESU SLEZENE

S A Ž E T A K

Sa sumnjom na akutni abdomen primljena je 73 godine stara bolesnica na odjel kirurgije. Nakon kliničkog pregleda, laboratorijskih, ultrazvučnih i CT nalaza potvrđuje se dijagnoza te se bolesnica podvrgava laparatomiji. Operacijom se otkriva intrabdominalni apsces slezene, izvede se kapsulotomija i drenaža sadržaja nakon čega se učini splenektomija. Na histološkim preparatima uklonjenog tkiva utvrđeno je da se radi o komadićima stranog tijela okruženom kroničnom upalom, multinuklearnom stanicama tipa stranog tijela, crvenim krvnim stanicama te fibroblastičnom proliferacijom. Iz anamneze se doznaje da je dosada pacijentica operirana samo jednom u životu, prije 40 godina, radi dijagnoze ekstra-uterine trudnoće. Ovakav slučaj apscesa slezene uzrokovanom gossypibomom, nakon 40 godina, nikada nije opisan u literaturi. Premda su ovakvi slučajevi vrlo dobro poznati u liječničkoj praksi, rijetko se opisuju zbog medicinsko-pravnih implikacija. Edukacija, profesionalizam i suradnja svih osoba, uključenih u liječenje osoba koje idu na operativni zahvat je od iznimne važnosti da bi se spriječile slučajne pogreške kao što je ova.