

Therapeutic Effect of Amniotic Membrane in Persistent Epithelial Defects and Corneal Ulcers in Herpetic Keratitis

Natasa Brijačak¹, Iva Dekaris², Alenka Gagro³ and Nikica Gabrić²

¹ Department of Ophthalmology, General Hospital »Virovitica«, Virovitica, Croatia

² Eye Clinic »Svjetlost«, Zagreb, Croatia

³ Institute of Immunology, Zagreb, Croatia

ABSTRACT

Amniotic membrane transplantation (AMT) promotes rapid epithelialization and reduces stromal inflammation and ulceration in HSV-1 keratitis. 18 patients with non-healing epithelial defect or corneal ulcer caused by herpetic keratitis were included in the study. All patients were treated by AMT. Corneal epithelial cells in patients suffering from herpetic keratitis secreted 5 ± 4.8 pg/ml of IL-1 α and 0.16 ± 0.47 pg/ml of IL-1 β (mean \pm SD). IL-1 α level was significantly higher as compared to controls ($p < 0.005$). Amniotic membranes that were used to treat investigated patients contained 339.87 ± 105 pg/ml of IL-1 α . In herpetic keratitis pro-inflammatory cytokine IL-1 α is secreted from corneal epithelial cells in significantly higher level than in controls. Beneficial effect of the AMT in such patients could be explained by the fact that AM secretes its natural antagonist IL-1 α .

Key words: herpetic keratitis, amniotic membrane, interleukin-1, interleukin-1 receptor antagonist

Introduction

Infection with HSV is extremely common and about 90% of the population is seropositive for HSV antibodies. Herpes simplex virus (HSV) is a leading infectious cause of blindness in humans and accounts for 3% of corneal transplants performed in the United States each year¹. There aren't so many patients with herpes simplex keratitis (HSK) in developed countries, thanks to therapy and hygiene, compared with the great number in undeveloped countries. This kind of virus is responsible for more than 1.5 million blindness that occur annually worldwide.

In humans, primary ocular HSV infection is often mild or subclinical. Recurrent infection inflicts greater corneal damage through the accumulation over time of virus-induced lesions, such as stromal opacification and neovascularization. As a result, recurrent herpetic ocular infections have the greatest potential to impair sight¹. Ocular manifestations of HSV infection include blepharitis, conjunctivitis or infectious epithelial keratitis². HSV immune stromal keratitis occurs in some patients after

epithelial manifestation of the diseases; often is recurrent and can cause permanent dense stromal scars and lead to severe vision loss. The main characteristic of immune stromal keratitis is stromal inflammation. The overlying epithelium is almost always intact except in situations of concomitant infectious epithelial keratitis or neurotrophic ulceration.

Herpetic stromal keratitis (HSK) and attendant corneal lesions have been attributed to an immunopathologic process that is orchestrated by T cells. CD4⁺ T cells are the principal mediators orchestrating the inflammatory response. Besides neutrophils, T cells and macrophages contribute to tissue destruction in the cornea³. Although T cells may play a key role in both tissue damage and repair, their activity is modulated by the actions of other cells and cytokines. Accordingly, the release of interleukin (IL)-1 and tumor necrosis factor (TNF)- α from damaged corneal cells and infiltrating cells may comprise an initial response to virus infection that complements later T-cell-mediated events.

Amniotic membrane (AM)

In 1995, Kim and al. showed experimentally that the use of preserved amniotic membrane graft is efficient in the corneal surface reconstruction in rabbits after epithelial removal and lamellar keratectomy. AM comprises from structures that improve healing of the epithelium defects: the basement membrane and growth factors^{4–9}. When used as a graft or a patch, amniotic membrane can promote healing of persistent corneal ulcers of different causes, although healing sometime ends with corneal scars (loss of vision!)^{10–13}.

Corneal inflammations in HSK may result in persistent corneal defects or corneal ulcer. In majority of these patients conservative therapy will fail, so corneal transplantation may be needed. However, corneal graft rejection rate in patients with herpetic keratitis rise to 50%, so neither this operation is ideal for these patients. It has been already shown that amniotic membrane transplantation (AMT) may be a method of choice in such cases, as a first step procedure. It offers the following advantages over conventional corneal transplantation – ease of surgery and avoidance of allograft rejection. Even if corneal transplantation is later needed, it can be performed after AMT, when the ocular surface is not inflamed⁹.

The aim of this study was to determine if AM modifies the course of stromal keratitis induced by herpes simplex virus type 1 (HSV-1). It is not known yet which pro-inflammatory cytokines are responsible for persistent epithelial corneal defects in patients with HSK, or whether the beneficial effect of the AMT could be explained by its potential secretion of anti-inflammatory cytokines, apart from her passive effect (because it acts as a substrate for epithelial growth). This study was set to give the answers to the previous questions in patients with herpetic keratitis unresponsive to the conventional treatment. Therefore, we have investigated whether human epithelial corneal cells of patients with herpetic keratitis produce pro-inflammatory cytokines IL-1 α and IL-1 β in significantly higher level compared with healthy corneal epithelial cells, and could we possibly explain the beneficial effect of the AMT in such patients by the fact that AM secretes the natural antagonist of these cytokines – IL-1ra (receptor antagonist)^{14–20}.

Patients and Methods

Clinical results

The present study included 18 patients (11 men and 7 women) with persistent corneal epithelial defect or ulcer caused by herpetic stromal keratitis and unresponsive to conventional treatment. Mean patients age was 54 \pm 17 (range 40–77). Inclusion criteria for the study were: persistent corneal epithelial defect caused by herpetic keratitis (which lasts longer than 30 days) or corneal ulcer of same etiology (lasting longer than 30 days) or significant corneal thickening (more than 75% of corneal depth) that threatens eye perforation. The study didn't include patients with herpetic stromal keratitis and intact epi-

thelium and patients which responded well to the conventional treatment (acyclovir ointment or oral). Patients with other inflammatory anterior eye segment disease were also excluded from the study. Patients were checked for their visual acuity, slit lamp appearance, digital tonometry, fundus and corneal swab (must have been sterile), both pre- and postoperatively.

AM was obtained shortly after elective cesarean delivery when human immunodeficiency virus, human hepatitis type B and C, and syphilis had been excluded by serological tests. Under a lamellar-flow hood, the placenta was cleaned of blood clots with sterile Earle's Balanced Salt Solution containing 50 μ g/ml penicillin, 50 μ g/ml streptomycin, 100 μ g/ml neomycin and 2.5 μ g/ml amphotericine B. The amnion was separated from the rest of the chorion by blunt dissection through the potential spaces situated between these 2 tissues, and flattened onto a nitrocellulose paper size of 0.45 μ m, with the epithelium/basement membrane surface up (2.4–6.10). AM were stored before transplantation at –80°C in sterile vial containing InOsol (Opsia, Toulouse, France): glycerol at the ratio of 1:1.

All patients receiving amniotic membrane had parbulbar anaesthesia with 2% lidocaine. Epithelial defect caused by HSV was debrided under the microscope with the use of blunt knife (usual procedure for better epithelial healing). AM was removed from the storage medium, peeled off the nitrocellulose filter paper and transferred to the recipient eye. AM was placed on the entire surface of the cornea and surrounding conjunctiva and secured by interrupted 10–0 Vicryl sutures to the perilimbal conjunctiva^{2,4,6,10}. After amniotic membrane transplantation (AMT) all patients received subconjunctival injection of 0.5 ml garamycin and 0.5 ml dexamethason. All patients received standard postoperative treatment with tobramycin ointment and drops. AM dissolved over the period of two to three weeks after surgery and sutures were removed.

Postoperatively the patients were followed 1st, 7th and 30th day to evaluate the beneficial effect of the AMT. Surgical success was defined as the cessation of stromal inflammation, complete epithelialisation of the cornea and formation of a visible stromal thickness. Surgical failure was defined as persistence or recurrence of herpetic keratitis before the dissolution of the AM, or a lack of epithelial or stromal wound healing. The follow up period ranged from 5 to 15 months. All complications of AMT were documented.

Cytokine detection

The number of corneal cells collected during »debridement« was counted and the corneal cells were cultivated at 37 °C for 24 hours, then stored at –80 °C in the sterile bottles containing tissue culture (Inosol-Opsia, Toulouse, France). The concentrations of IL-1 α and IL-1 β were measured in corneal epithelial cells using commercially available ELISA systems (ELISA-R&D Systems, USA) according to the respective manufacturer's protocols. Corneal epithelial cells of a healthy donor from

the eye bank were used as controls (n=10). Only corneas that couldn't be used for transplantation in patients (due to the lack of endothelial corneal cells), were used for controls.

Student t-test was used to compare the concentrations of IL-1 α and IL-1 β to the controls. A p value of less than 0.005 was considered significant.

Results

Clinical results

Patients preoperative best corrected visual acuities (BCVA) are listed in Figure 1. Amniotic membrane transplantation (AMT) was performed once in 16 patients and twice in two patients.

The surgical success of AMT defined as the cessation of stromal inflammation, complete epithelialisation of the cornea and formation of the normal stromal thickness, was noticed in 89% of patients occurring in 16.4 days (range 10–30 days) (Figure 2). An example of such case is shown on Figure 3a and b.

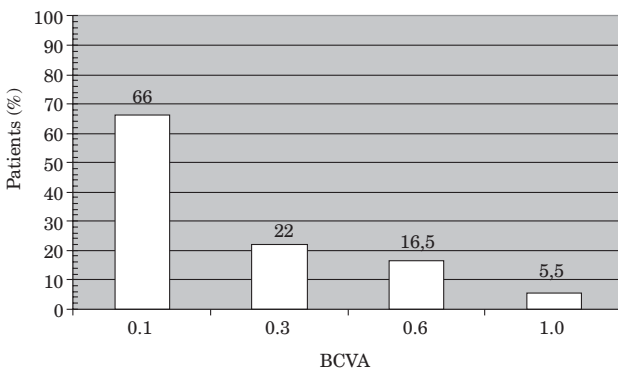


Fig. 1. Preoperative best corrected visual acuities (BCVA) in patients suffering from persistent epithelial defect or ulcer caused by herpetic keratitis.

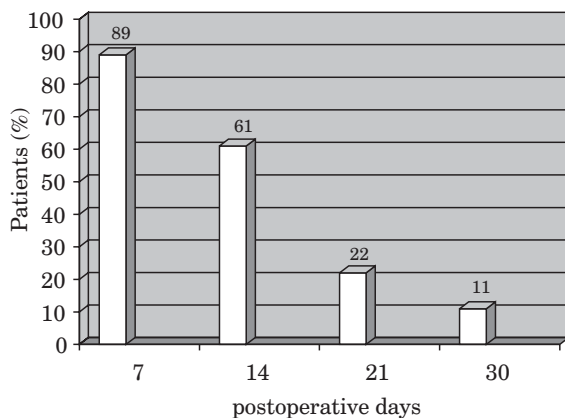


Fig. 2. Surgical success (cessation of stromal inflammation, complete epithelialisation of the cornea and formation of a visible stromal thickness) in patients receiving amniotic membrane graft due to persistent epithelial defect or ulcer caused by herpetic keratitis.

Visual acuity improved in all patients except in two (Figure 4). No serious postoperative complications occurred during the follow up of 17 months (e.g. superinfection, hypopion).

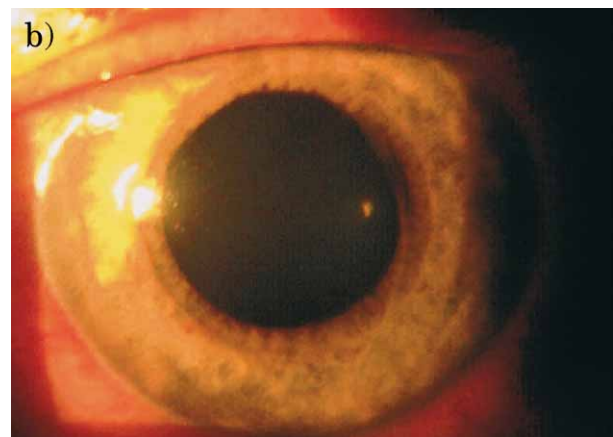
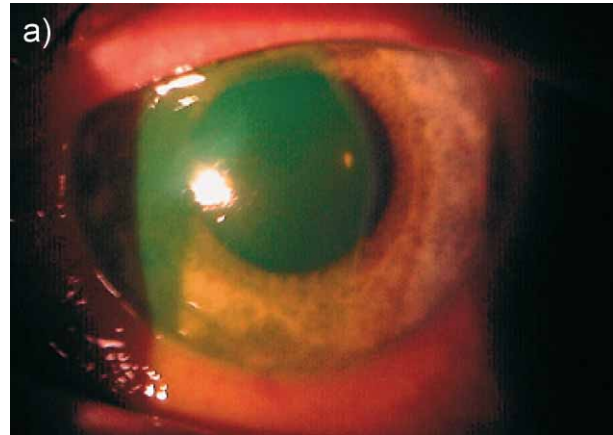


Fig. 3. Patient with herpetic keratitis and persistent epithelial defect before (a) and after (b) amniotic membrane transplantation.

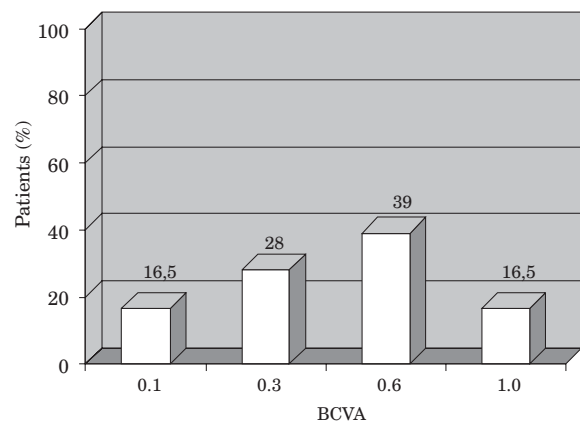


Fig. 4. Postoperative (after amniotic membrane transplantation) best corrected visual acuity (BCVA) in patients with persistent epithelial defect or ulcer caused by herpetic keratitis.

IL-1 α and IL-β levels in corneal epithelial cells (CEC)

Samples collected by therapeutic »debridement« contained various number of corneal epithelial cells (Figure 5) due to the fact that the quantity of sample was guided by surgeons decision of how much tissue should be taken away for the better corneal healing.

Corneal epithelial cells in patients suffering from herpetic keratitis secreted 5 ± 4.8 pg/ml of IL-1α; significantly higher as compared to controls (healthy epithelial corneal cells; 1.38 ± 0.71 pg/ml) ($p < 0.005$) (Figure 6). The level of IL-1 beta (0.16 ± 0.47 pg/ml) wasn't significantly different to controls. Amniotic membranes that were used to treat investigated patients contained 339.87 ± 105 pg/ml of IL-1ra.

Discussion

The amniotic membrane has been used in general surgery as a graft for burned skin, for reconstruction of artificial vagina, for repairing omphaloceles, and to prevent tissue adhesion in surgeries of the head, abdomen

and pelvis. Many of these applications used fresh rather than preserved AM and some of them recorded undesirable allograft rejection⁴⁻⁷.

It has been experimentally shown that AM could be efficiently used for ocular surface reconstruction because of its basement membrane and secretion of growth factors⁴⁻⁶. The thick basement membrane is an ideal substrate to support growth of epithelial cells, facilitate migration of epithelial cells, reinforce adhesion of basal epithelial cells and promote epithelial differentiation. An avascular amniotic stroma might contain the important property of reducing formation of vascularized granulation tissues in postoperative healing. Some authors report the presence of growth factors in the avascular stroma. The stromal matrix can also exclude inflammatory cells by rendering them into rapid apoptosis, and contains various forms of protease inhibitors. AMT was associated with a suppression of inflammation, rapid epithelisation and reduction of neovascularization^{4-9,10-13}.

Rapid healing and reduction of ocular surface inflammation following AMT can be explained by the following mechanisms⁹: AM provides a new basement membrane, which is an important substrate for supporting adhesion and growth of epithelial progenitor cells, including stem cells; it exerts an anti-inflammatory effect; stromal matrix of AM has a direct anti-scarring effect, and it may promote nerve regeneration by maintaining nerve growth factor signaling.

It has been shown that mouse corneas with herpetic stromal keratitis produce higher level of IL-1α and TNF-α compared with the noninfected controls^{14,15}. It is also shown in some recent studies that these cytokines induce neovascularization and that IL-1α and IL-1β can cause corneal neovascularization and act pro-inflammatory in the corneal tissue. Having this in mind, researchers are trying to use natural antagonist of IL-1, IL-1 receptor antagonist (ra) as a potential anti-inflammatory drug in several inflammatory eye diseases. IL-1ra is a naturally occurring IL-1 isoform with high-affinity binding to IL-1 receptors, but without agonistic activity even at high concentrations; hence capable of profound down-regulation of IL-1 mediated responses¹⁶⁻²². Furthermore, expression of IL-1, a potent pro-inflammatory cytokine that can be produced by corneal epithelial cells, is markedly suppressed by AM. These data collectively indicate that the amniotic membrane may have both direct anti-inflammatory effect by suppressing inflammatory cells, and also an indirect effect through promotion of rapid epithelial healing⁶.

Results of our study have shown that AMT significantly modifies the course of necrotizing stromal keratitis induced by HSV, similar as in mouse model. We have shown that human epithelial corneal cells produce pro-inflammatory cytokine IL-1. Beneficial effect of AMT in these patients could be explained by the fact that AM produce its natural antagonist IL-1ra (as shown in this study). Therefore, AM seems to have an active effect in the healing of epithelial corneal defects, not only an indirect one as usually thought. Namely, most authors ex-

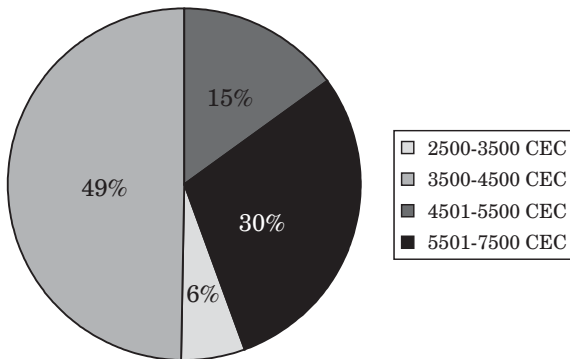


Fig. 5. Number of corneal epithelial cells (CEC) in samples obtained from patients with persistent epithelial defect or ulcer caused by herpetic keratitis.

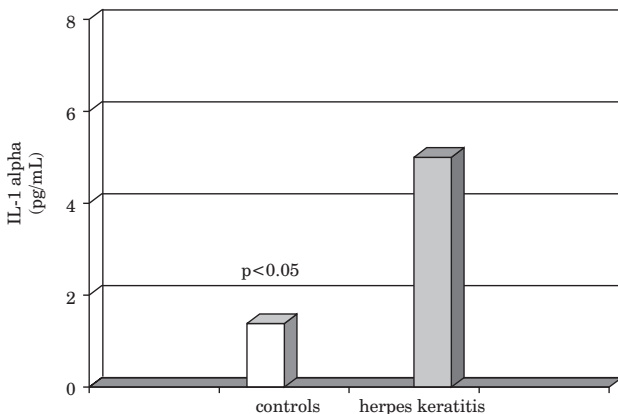


Fig. 6. Significant increase of IL-1α level in corneal epithelial cells of patients with persistent epithelial defect or ulcer ($p < 0.005$) caused by herpetic keratitis, as compared to controls.

plain activity of AM as just being a substrate to support growth of epithelial cells and healing of corneal tissue⁵⁻⁹.

In some patients HSV infection can end up in formation of dense scars and consequent loss of vision; then corneal transplantation has to be done. AMT is highly beneficial in these cases prior to corneal transplantation, since it decreases eye inflammation and increases the chance for subsequent successful corneal grafting. Clinically, it has been shown that the patients with neovascularization and stromal corneal inflammation often have graft rejection, but there are no final answers which are the mediators responsible for stimulation or suppression of corneal inflammation.

In this study we have shown that corneas of patients with herpetic keratitis produce significantly higher level

of pro-inflammatory cytokine IL-1 α as compared to healthy controls, and this data can help in planning a potentially favorable anti-inflammatory treatment in humans. One form of such treatment is a transplantation of amniotic membrane, since AM (as shown in this study) secretes IL-1ra which is the natural antagonist of IL-1.

Conclusion

AMT significantly modifies the course of immune stromal keratitis induced by HSV-1. It is associated with a suppression of inflammation, rapid epithelisation and reduction of stromal necrosis. Our data have also shown that IL-1 α and its antagonist IL-1ra regulate corneal inflammation in patients with stromal herpes keratitis.

REFERENCES

1. PEPOSE JS, LEIB DA, STUART PM, EASTY EL, Ocular Infection and Immunity (Mosby, St. Louis, 1996). — 2. MESARIĆ B, VITALE B, Imunološke bolesti oka (Školska knjiga, Zagreb, 1991). — 3. VERJANS GM, REMELJER L, MOOY CM, OSTERHAUS AD, Invest Ophthalmol Vis Sci, 41 (2000) 2607. — 4. DEKARIS I, GABRIĆ N, MRAVIČIĆ I, KARAMAN Ž, In: Nikica Gabrić, Iva Dekaris, Ljerka Henč-Petrinović (Eds) Očna banka (Nakladni zavod Globus, Zagreb, 2000). — 5. GABRIĆ N, MRAVIČIĆ I, DEKARIS I, KARAMAN Ž, MITROVIĆ S, Doc Ophth, 98 (2000) 273. — 6. HEILINGENHAUS A, BAUER D, MELLER D, STEUHL K, TSENG SCG, Invest Ophthalmol Vis Sci, 42 (2001) 1969. — 7. ADDS PJ, HUNT CJ, DART JK, Br J Ophthalmol, 8 (2001) 905. — 8. KIM JC, TSENG SCG, Cornea, 14 (1995) 473. — 9. TSENG SCG, Br J Ophthalmol, 85 (2001) 1400. — 10. HEILINGENHAUS A, LI H, HERNANDEZ GALINDO EE, KOCH JM, STEUHL KP, MELLER K, Br J Ophthalmol, 87 (2003) 1215. — 11. HEILINGENHAUS A, LI H, YANG Y, WASMUTH S, STEUHL KP, BAUER D, Invest Ophthalmol Vis Sci, 46 (2005) 4079. — 12. SHI W, CHEN M, XIE L, Ophthalmol, 114 (2007) 1476. — 13. KUBO

M, SONODA Y, MURAMATSU R, USUI M, Invest Ophthalmol Vis Sci, 42 (2001) 1539. — 14. KEADLE TL, USUI N, LAYCOCK KA, MILLER JK, PEPOSE JS, STUART PM, Invest Ophthalmol Vis Sci, 41 (2000) 96. — 15. STUMPF TH, SHIMELD C, EASTY DL, HILL TJ, Invest Ophthalmol Vis Sci, 42 (2001) 372. — 16. SOLOMON A, ROSENBLATT M, MONROY D, JI Z, PFLUGFELDER SC, TSENG SCG, Br J Ophthalmol, 85 (2001) 444. — 17. BISWAS PC, BANERJEE K, ZHENG M, ROUSE BT, Journal of Leukocyte Biology, 76 (2004) 868. — 18. BISWAS PC, BANERJEE K, KIM B, ROUSE BT, J Immunol, 172 (2004) 3736. — 19. DEKARIS I, YAMADA J, STREILEIN JW, DANA MR, Current Eye Research, 19 (1999) 456. — 20. FIDEL PLJR, ROMERO R, RAMIREZ M, CUTRIGHT J, EDWIN SS, LAMARCH COTTON DB, MITCHELL MD, Am J Reprod Immunol, 32 (1994) 1. — 21. KRUSE FE, JOUSSEN AM, ROHRSHNEIDER K, YOU L, SINN B, BAUMANN J, VOLCKER HE, Graefes Arch Ckin Exp Ophthalmol, 238 (2000) 68. — 22. DEKARIS I, GABRIĆ N, MARKOTIĆ A, LAZIĆ R, ČIMA I, BOSNAR D, In: Abstract book of ARVO (ARVO, Annual Meeting, 2003).

N. Brijačak

Department of Ophthalmology, General Hospital Virovitica, Gajeva 21, 33000 Virovitica, Croatia

TERAPEUTSKI UČINAK AMNIJSKE MEMBRANE U PERZISTENTNIH DEFEKATA EPITELA I ULKUSA UZROKOVANIH HERPETIČNIM KERATITISOM

SAŽETAK

U ovoj studiji praćen je učinak liječenja perzistentnih epitelnih lezija i ulkusa rožnice (u 18 pacijenata) transplantacijom amnijske membrane (TAM). Za vrijeme kirurškog zahvata abrazijom su skupljane stanice rožnice koje okružuju defekt, kultivirane su 24 h, te je mjerena produkcija IL-1a and IL-1b metodom ELISA. Ostatak transplantirane amnijske membrane je također kultiviran, te je mjerena koncentracija interleukin-1 receptor antagonista (IL-1ra) iz supernatanta amnijske membrane. Epitelne stanice rožnice u pacijenata sa stromalnim herpetičnim keratitisom izlučile su $5 \pm 4,8$ pg/ml IL-1a i $0,16 \pm 0,47$ pg/ml IL-1b (srednja vrijednost \pm SD). Razina IL-1 α bila je statistički značajno viša u kontrola ($p < 0,005$). Regresija upale rožnice i cijeljenje epitelnog defekta nakon TAM-a primijećeno je u 89% pacijenata. Vidna oštrina se poboljšala u svih pacijenata, osim u 2 slučaja. Nije bilo ozbiljnih nuspojava za vrijeme trajanja studije od 17 mjeseci. Amnijske membrane koje su upotrebljavane kod ispitivanih pacijenata lučile su $339,87 \pm 105$ pg/ml IL-1ra. U pacijenata sa stromalnim herpetičnim keratitisom epitelne rožnične stanice luče signifikantno više IL-1 α negoli kontrole. Korisno djelovanje TAM-a u ispitivanih pacijenata može se objasniti s činjenicom da amnijska membrana izlučuje prirodni antagonist tog citokina IL-1 ra.