

# The Advancement in the Early Diagnostics of Developmental Hip Dysplasia in Infants – The Role of Ultrasound Screening

Ivan Krolo<sup>1</sup>, Klaudija Višković<sup>2</sup>, Slavko Kožić<sup>3</sup>, Miljenko Marotti<sup>1</sup>, Ratimira Klarić-Čustović<sup>1</sup>, Nevja Banak-Zahtila<sup>2</sup>, Đurđica Ikić<sup>4</sup> and Loredana Premate-Milas<sup>4</sup>

<sup>1</sup> Department of Diagnostic and Interventional Radiology, University Hospital »Sestre milosrdnice«, Zagreb, Croatia

<sup>2</sup> Department of Radiology, Primary Health Care Center »Dr. Lino Peršić«, Labin, Croatia

<sup>3</sup> University Orthopaedic Hospital, Lovran, Croatia

<sup>4</sup> Department of Radiology, General Hospital »Pula«, Pula, Croatia

## ABSTRACT

*Developmental hip dysplasia (DDH) is a deformation of the locomotor system that can occur on previously normal bone structures in late fetal development. The study was undertaken to determine the value of continuous ultrasound screening in early diagnosis of DDH. In the area covered by the Labin Primary Health Center, clinical and ultrasound examination of the hips was performed in all children during the fourth month of life from 1989 to 2001. The incidence of DDH was 3.3%. The authors compared the obtained results with results of clinically examined hips in the period from 1968 to 1988 (incidence 1.7%), before the ultrasound diagnostics was introduced. The hip radiograms were performed only in children with clinically positive signs of higher degree of DHD. The ultrasound examination was performed with Hitachi EUB 410 real time linear transducer with a 5 MHz probe. The examiners used methods and criteria suggested by Graf. The most useful feature of the ultrasound method is that it allows the visualization of cartilaginous femoral head and its relationship to the acetabulum in infants. The method is non-invasive, repeatable, without risk of ionizing radiation or need for the contrast material administration. The results of the study revealed an important increase of DHD incidence after the introduction of ultrasound examination. US is highly sensitive in hip imaging and reveals the existence of a number of dislocated and subluxated hips that otherwise would be missed. The anomaly was discovered in the early period of life, which is very important for appropriate therapeutic effects.*

**Key words:** developmental hip dysplasia, ultrasound screening

## Introduction

The term developmental dysplasia of the hip – DHD represents a defect with its beginning in the very early fetal developmental period<sup>1</sup>. The spectrum of abnormalities may range from the simple newborn instability of the hip to the existence of a complete luxation of the femoral head with an insufficient development of the acetabulum in an older child<sup>2</sup>. The most known and used classification system was developed by Tönnes<sup>3</sup> according to which the severity of the dislocation is based on the relationship between the ossifying nucleus of the femoral head and the superolateral margin of the acetabulum. According to this classification, there are four degrees of dislocation<sup>3</sup>.

In different parts of the world DDH incidence varies from 0.1% (Hong Kong)<sup>4</sup> 1.5% (Salford, Great Britain)<sup>5</sup>, Sweden (2–4%)<sup>6</sup>. In Croatia the incidence varies from 2 to 3%<sup>7,8</sup>. The etiology of this anomaly can be a result of many factors: persistent joint laxity, mechanical forces which cause anatomical instability of the hip, detrimental intrauterine position, transient effects of estrogen during pregnancy etc.<sup>9</sup>. It is also known that the DHD of the hip is a disease with a potential congenital origin. The intrauterine development of the hip is chronologically parallel to the development of all limbs<sup>1</sup>.

An environmental origin is possibly equally important, since almost 20% of infants with it are born in a breech position<sup>11–14</sup>. In the 1980's modern medicine mastered the pathological mechanism of DHD and reduced its management to a simple treatment algorithm: a) in the perinatal period a combination of various physiological and environmental factors causes the capsule of the hip joint to become stretched; b) this provokes the femoral head to become displaced from the acetabulum; c) therefore all newborns should be screened with a simple clinical

examination which, if properly performed, will reveal the hip instability<sup>15,16</sup>.

It is well known that the Ortolani, Barlow and von Rosen tests of clinical instability are not completely reliable, since false positive, as well as, false negative results occur even in the hands of experienced examiners<sup>17</sup>. The Ortolani procedure permits a diagnosis in more than 90% of cases during the neonatal period; most are, in fact subluxation or »dislocatable« hips, since dislocations are uncommon in neonates. The aim of this maneuver is maximized by performing it, not only at birth but also within a check – up several days after birth, with a limitation of abduction to less than 180 degrees, which is equivalent to the classic »click« as a pathologic sign, and by remembering that most hip dislocations are unilateral<sup>18</sup>.

The pelvic radiography is an important part of the orthopedic examination for children with the dysplastic hips after the age of four months<sup>19</sup>. Various measurements have been advocated for the enhancement of this examination and extensive studies have been reported that define normal ranges at different ages for the acetabular index, the head-teardrop distance and the center edge angle (CE)<sup>20</sup>. Ultrasound is non – invasive and brings minimal risk to the patient's general well-being, since it is without the risk of ionizing radiation or the injection of contrast material. The most useful feature is that it allows a visualization of the cartilaginous femoral head and its relationship to the acetabulum in the young child<sup>16</sup>. The use of ultrasound as an additional diagnostic aid was initially popularized by Graf<sup>20</sup>.

Although plain radiography and ultrasound are the standard imaging modalities used for assessment of hip dysplasia, CT can provide precise information with regard to the reduction of the hip within the acetabulum in complicated cases and in the postoperative period<sup>21</sup>.

MRI can be useful in the preoperative and postoperative evaluation of the hip with many complications. MRI can be used to distinguish the labrum, capsule and acetabular cartilage. It can also be useful for detecting the complications of DHD and treatment such as avascular necrosis of the femoral head and joint effusion. MRI can demonstrate iliopsoas tendon compression, a ligamentum teres and pulvinar hypertrophy<sup>21</sup>.

It has been generally accepted that the treatment of DHD is easier and the results are better when diagnosed and treated early, before the child begins to walk. In some patients, instability of the hip at birth may progress to subluxation or luxation. The continuing growth of the child aggravates any deformation of bone in and around the hips, and the persistent abnormal position of the femoral head leads to the contracture of soft tissue structures<sup>22</sup>.

### Patients and Methods

In the period from 1968 to 2001, 9,178 infants were treated for developmental dislocation of the hip, in the orthopedic-pediatric out patient clinic in the health district of Labin, Croatia. Considering the hip anomalies this period can be divided into two sub-periods with different incidence: from 1968 to 1988 with the incidence of 1.7%; and from 1989 to 2001 with the incidence of 3.3%. The following characteristics of children with DHD were observed: sex, birth, weight, birth rank, season of birth, mothers age at birth, type of delivery, positive family history of hip instability or displacement, ossification of the femoral head in children five months old, and ultrasound imaging characteristics in the second period.

All children born in hospitals had a postnatal examination by a pediatrician within 72 hours of birth. The next clinical examination was performed in the pedi-

atric department of the Primary health care center at the end of the first month of life. This examination included both the Ortholani and Barlow tests for hip instability and a history was taken from mothers of any family history of hip instability. All hip abnormalities were recorded including instability, hip »click« or »clunk«, and apparent limitation or abduction. During the fourth month of life all infants were referred to orthopedic examination.

In the first period infants with no clinical abnormalities of the hips were discharged. Few infants with tighter hips than normal in abduction, but otherwise clinically normal, were followed up under regular survey until the tightness was fully resolved. After that radiography was made to exclude the development of hip dysplasia.

In the second period, the hips of all infants were sonographically examined on both sides. The ultrasound probe was done with Hitachi EUB 410 real time linear transducer with a 5 MHz linear probe. The examiners used criteria suggested by Graf<sup>23</sup>. A basic line was drawn through the iliac crest and crossed through the contact spot of the bone and capsule. An »inclination line« connected the osseous convexity with the labrum acetabulare. The third line was the »line of acetabular roof«. This line connected the lower edge of the ilium oss to the osseous convexity. The alpha angle characterized the distinguishing features of the osseous convexity. The beta angle, also known as the inclination angle, characterized the bone supplementing additional roofing by the cartilaginous convexity. Types of hips according to Graf were considered as: Ia, Ib, II+, IIa-, IIb, IIc, D, IIIa, IIIb, IV<sup>23–25</sup> (Table 1).

The type I according to Graf's classification represents clinically normal finding, type II dysplastic hip, type III subluxated hip and type IV luxated hip.

**TABLE 1**  
TYPES OF HIPS ACCORDING TO GRAF<sup>23–25</sup>

Hip type	$\alpha$ angle (°)	$\beta$ angle(°)	Bony roof contour	Cartilaginous rim
I A	$\geq 60$	$\leq 55$	Good	Narrow
I B	$\geq 60$	55–77	Good	Covers head
II	43–60	55–77	Satisfactory to deficient	Wide, covers head
III and IV	$\leq 43$	$\geq 77$	Poor	Wide, cranially displaced

If the initial examination demonstrated instability of the hip, the infant was scheduled for a repeated examination in two weeks time to see if spontaneous stabilization occurred. If the hip became stable, no splintage was used, but the infant was re-examined again in 4 weeks and thereafter at monthly intervals until nine months of age.

Statistical evaluations of data was based on chi-square test and test for proportional differences<sup>26</sup>. The »Statistics for Windows program« was used for statistical analysis.

**Results**

*Incidence*

In the first examination period (1968 – 1988) the incidence of DHD was 1.7% and in the second period (1989–2001) it was 3.3%, that is statistically significant at the level  $p = 0.0072$ .

The difference in proportion of children with dysplasia (1% for the first period and 3% for the second period) is statistically significant at the level  $p < 0.0001$ .

The difference in proportion of children with subluxation and luxation (0.7% for the first period and 0.3% for the second period) is statistically significant at the level  $p = 0.0422$ . The results are separately shown in Figures 1 and 2.

*Sex distribution*

Sex distribution for two examination periods is separately shown in Figures 3 and 4. In the first examination period (1968–1988) the percent of males with dysplasia was 0.8% and females 1.4%. The incidence is higher in females, that is statistically significant at the level  $p = 0.0146$ .

In the second examination period (1989–2001) the percent of males with dysplasia was 3.2% and females 2.7%.

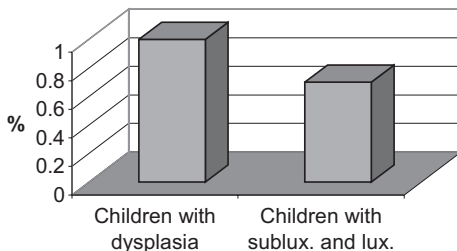


Fig. 1. Period A (1968–1988).

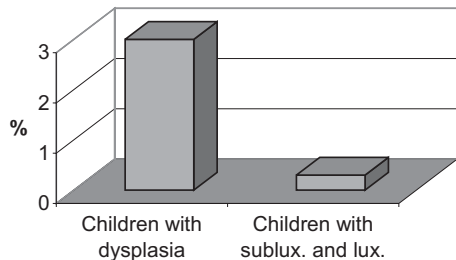


Fig. 2. Period B (1989–2001).

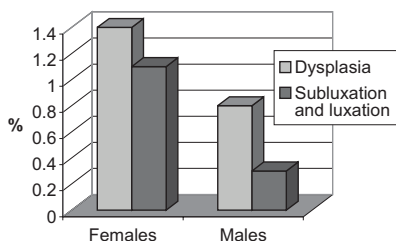


Fig. 3. Period A (1968–1988): Sex distribution.

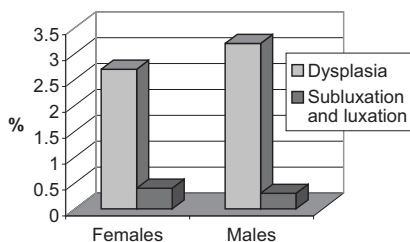


Fig. 4. Period B (1989–2001): Sex distribution.

There is no statistically significant difference.

In the first examination period (1968–1988) the percent of males with subluxation and luxation was 0.3% and females 1.1%. The difference in proportion is statistically different at the level  $p = 0.0146$ .

In the second examination period (1989–2001) the percent of males with subluxation and luxation was 0.3% and females 0.4%. The difference in proportion is not statistically significant.

*Results of ultrasound examinations*

According to Graf’s classification hips were distributed into types. Of 2,010 children 92.3% were type IA; 1.61% type IB; 5.22% type II A; 0.64% type IIB; 0.04 % type IIIB and 0.04% type IV (Figure 5).

Most children had an  $\alpha$  angle over 60 degrees,  $\beta$  angle 55 degrees, a good bony roof contour and a normal cartilaginous

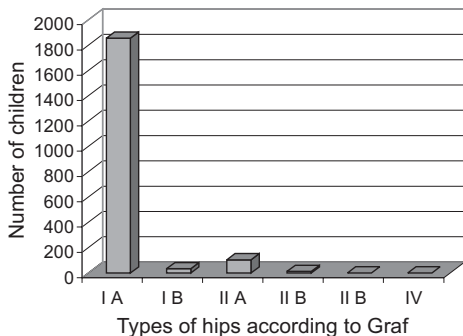


Fig. 5. Results of ultrasound examination.

rim (IA). Only 1.61% had  $\beta$  angle bigger than 55 degrees, with good bony roof contour and cartilaginous rim that covers femoral head (I B). There were 0.68% children with type II hip – the  $\alpha$  angle about 50 degrees,  $\beta$  angle bigger than 55 degrees, with deficient bony roof contour and wide cartilaginous rim that still covers the head. The percent of children with  $\alpha$  angle less than 43 degrees,  $\beta$  angle bigger than 77 degrees, with poor bony roof contour, cranially displaced cartilaginous rim was only 0.08 (type III and IV).

**Discussion**

In the ultrasound out patient clinic of Primary Health Care Center Labin 2,010 children were examined during the period of 13 years (from 1989 to 2001), in the fourth month of life. The incidence of developmental dysplasia of the hip (DHD) was in this period 3.3%. The results from this second period of examination were compared with the results of clinical examination of the hip before the possibility of ultrasound diagnostics. In the first period (from 1968 to 1988) the examination incidence was 1.7%.

In the first period the diagnosis and follow up of patients depended solely on the clinical judgment of the attending physician. Radiographic examination was done only exceptionally. Although the hips can be positioned in several different ways during filming, false – negative results may occur due to the inability of X-ray

imaging to show the cartilaginous portion of the infant hip joint. Because of the limits of diagnostic methods, a smaller number of children with lower level of DHD was detected until the age of four months. The introduction of ultrasound diagnostics enabled the detection of even moderate degrees of dislocation in early infancy, while it can be treated by simpler therapeutic methods with better results. This explains the increase in incidence in the second period.

The anomaly was found in various degrees of development, from dysplasia with apparent limitation of abduction to an obvious luxation with positive repositional phenomena and following secondary change of acetabulum and proximal part of femur.

The literature search revealed reports documenting higher incidence of DHD in females. The proportion was from 8.1 to 5.1<sup>27,28</sup>. In our population that was statistically significant only in the first examination period (shown in Figures 3 and 4).

This difference is believed to be the result of the increased levels of circulating estrogens at the time of birth and an increased susceptibility to them.

Ultrasound is non-invasive and poses minimal risk to the patient's general well-being. It has also provided new insight in the early pathomechanics of DHD and the normal growth of the cartilaginous infant hip. According to some authors (Harcke, 1994) two weeks of age is the best time for ultrasound screening, but infants with clicks or risk factors should be studied at 4 to 6 weeks of age. In the conditions of primary health care in the Labin health district, the authors have found most practical to scan high – risk infants and infants with uncertain clinical findings at the end of the first month of life. This allows spontaneous improvement of the mild DHD, thus avoiding repeated ultrasound scans and possibly unnecessary treatment.

In infants with clinically normal hips ultrasound examination was performed during the third month of life for the following reasons: it is extremely rare that infants with clinically stable and sonographically normal hips develop late DHD, it reduces the chances of over treatment and its associated complications, it is still the optimal time for therapeutic treatment if it is necessary and cost-effective.

The fact that ultrasound does not pose a physiologic hazard does not mean the procedure is without cost. The direct costs of purchasing and maintaining the equipment, training examiners to become proficient, and the time necessary to perform the procedure have a considerable impact on the costs for the individual and for society if used for routine screening. The results of cost – benefit analysis for ultrasound screening of neonatal hip in the Republic of Croatia have been published<sup>29</sup> and according to them, the introduction of ultrasound screening would result in the early detection and hence cheaper treatment. It would also reduce the need for hip endoprostheses, which is presently the most common surgical procedure at orthopedics departments.

Ultrasound improved accuracy in assessing the dislocation of the hip, eliminating over diagnosis that leads to unnecessary treatment.

It has also shown considerable value as a tool for assessing acetabular remodeling and improvement in the femoral head – acetabular relationship following a successful reduction. Ultrasound allowed earlier recognition of potential treatment failures, thus the authors were able to change to a more effective treatment in a much shorter period of time.

## Conclusion

In the first period of examination (from 1968 to 1988) clinical screening was performed in the fourth month of life in

all infants in the health district of Labin. Conventional radiography was done only in children with clinically high degree of dislocation.

In the second period of examination (from 1989 to 2001) ultrasound screening was done in the same chronological age in all infants (fourth month). The study was undertaken to determine the value of continuous, uniformed clinical and ultrasound screening. The results of the study revealed that the incidence of late discovered DHD had been high before the use of ultrasound was introduced. This method is repeatable without harmless effects. The authors can monitor the effects of treatment and sometimes complex treatments can be postponed and applied in

the right moment. Ultrasound monitoring allows minor degrees of development to be left untreated and most cases have a spontaneous resolution. If this fails, treatment can still be started. Regular sonographic imaging of infant under treatment also allows progress toward location to be monitored and harness treatment to be abandoned earlier if there is no satisfactory progress. It also reveals the number of dislocated and subluxed hips that otherwise would be missed.

Utilized together with newly developed imaging methods (CT and MRI) we should try to significantly advance the studies on DHD in our population, however, taking care of the rationality in their application.

## REFERENCES

1. JAMES, T., M. D. PIZUTILLO, G. D. McEWEN, J. Am. Ac. Orthop. Surg., 8 (2000) 4. — 2. TACHDJIAN, M., Orthopaedia paediatrica, Interamericana, Madrid, (1989) 322. — 3. TÓNIS, D.: Congenital dysplasia and dislocation of the hip (in children and adults). (Springer, Berlin-Heilderberg-New York, 1987). — 4. DE ROSA, P., Clin. Orthop., 225 (1987) 77. — 5. BARLOW, T. G., J. Bone Joint Surg., 44-B (1962) 292. — 6. GOSS, P. W., J. Paediatr. Child Health, 38 (2002) 469. — 7. STIPANIČEV, Š., Lij. vjes., 9 (1974) 562. — 8. STIPANIČEV, Š., Lij. vjes., 107 (1985) 370. — 9. STRINOVIĆ, B., Arh. zašt. majke i djeteta, 2 (1987) 117. — 10. SCHAUMANN, B. A., Coll. Antropol., 11 (1987) 383. — 11. WEINSTEIN, S. L., Clin. Orthop., 225 (1987) 62. — 12. ARONSSON, D. D., M. J. GOLDBERG, T. F. KLING, D. R. ROY, Pediatrics, 94 (1994) 201. — 13. ICE, G., Coll. Antropol., 27 (2003) 1. — 14. PROKOPEC, M., Coll. Antropol., 27 Suppl. 1 (2003) 1. — 15. POSINKOVIĆ, B., Pediatr. Croat., 37 (1993) 99. — 16. HENSINGER, R., J. Pediatr. Orthop., 15 (1993) 732. — 17. DUPPE, H., L. G. DANIELSON, J. Bone Joint Surg., 84 (2002) 878. — 18. BIALIK, V., G. M. BIALIK, S. BLAZER, P. SUJOV, M. BERANT, Pediatrics, 103 (1999) 93. — 19. ROSENBERG, H., RSNA Special Course in Ultrasound, (1996) 363. — 20. BROUGHAM, D., S. BROUGHTON, M. B. MENELAUS, J. Bone Joint Surg., 70 B (1988) 733. — 21. CONWAY, W., W. TOTTY, K. MCENERY, Radiology, 198 (1996) 297. — 22. HOLEN, K., A. TEGNANDER, S. H. EIKNES, T. TERJESEN., J. Bone Joint Surg., 81 B (1999) 846. — 23. VRDOLJAK, J., Coll. Antropol., 22 (1998) 107. — 24. CLARKE, N., H. T. HARCKE, P. McHUGH, M. S. LEEP, F. BORN, G. P. MACEWAN, J. Bone Joint Surg., 67 (1985) 406. — 25. RESNICK, D.: Bone and joint imaging. (W. B. Saunders Co., Philadelphia, 1996). — 26. ELBOURNE, D., C. DEZATEAUX, R. ARTHUR, N. M. CLARKE, A. GRAY, A. KING, A. QUINN, F. GARDNER, G. RUSSELL, Lancet, 360 (2002) 2009. — 27. RIDL-VIDAS, V., J. VRDOLJAK, D. ALAJBEG, Pediatr. Croat., 37 (1993) 63. — 28. BORGES, J. KUMAR, J. T. GUILLE, J. Bone Joint Surg., 177 (1995) 975. — 29. BRALIĆ, I., J. VRDOLJAK, L. KOVAČIĆ, Croatian Medical Journal, 42 (2001) 171.

I. Krolo

*Department of Diagnostic and Interventional Radiology, University Hospital  
»Sestre milosrdnice«, Vinogradska cesta 29, 10000 Zagreb, Croatia*

## **NAPREDAK U RANOJ DIJAGNOSTICI RAZVOJNOG POREMEĆAJA KUKA KOD DJECE – ULOGA ULTRAZVUČNOG PROBIRA**

### **S A Ž E T A K**

Razvojni poremećaj kuka predstavlja deformaciju lokomotornog sustava koja se pojavljuje na prethodno normalnim koštanim strukturama u kasnoj fazi fetalnog razvoja. Ovaj je rad učinjen da bi se odredila vrijednost kontinuiranog ultrazvučnog probira u ranoj dijagnostici razvojne dislokacije kuka. Na području Doma zdravlja Labin od 1989. do 2001. učinjen je klinički i ultrazvučni pregled sve dojenčadi u četvrtom mjesecu života. Incidencija je bila 3,3%. Autori su usporedili dobivene rezultate s rezultatima klinički pregledanih kukova u razdoblju od 1968. do 1988. (incidencija je iznosila 1,7%) prije uvođenja ultrazvučne dijagnostike. Radiološki pregled kukova učinjen je samo kod djece s visokim stupnjem klinički pozitivnog nalaza razvojne anomalije. Ultrazvučni pregled je učinjen Hitachi EUB 410 ultrazvučnim aparatom, linearnom sondom od 5 MHz. Autori su koristili kriterije po Grafu. Najznačajnija karakteristika ultrazvučne metode je vizualizacija hrskavične glave femura i njen odnos s acetabulumom kod djece. Metoda je neinvazivna, može se ponavljati, nema rizika ionizacijskog zračenja kao ni primjene kontrastnog sredstva. Rezultati studije pokazuju značajan porast incidencije razvojne anomalije nakon uvođenja ultrazvučnog pregleda. Ultrazvuk je vrlo senzitivan i otkriva određen broj dislociranih i subluksiranih kukova koji se drugim metodama ne mogu dijagnosticirati. Anomalija je bila otkrivena u ranoj životnoj dobi što je značajno za odgovarajući terapijski efekt.