

Intravitreal Bevacizumab (Avastin) in Treatment of Neovascular Age-related Macular Degeneration

Ratimir Lazić, Nikica Gabrić, Iva Dekaris, Borna Šarić and Morena Gavrić

Eye Clinic »Svjetlost«, Zagreb, Croatia

ABSTRACT

To evaluate the efficacy and safety of intravitreal bevacizumab in treatment of minimally classic and occult choroidal neovascularization secondary to age-related macular disease 48 eyes of 48 patients (mean age of 74.8) included in this prospective, noncomparative, interventional case series. Median follow-up was 18 weeks (6–24). Intravitreal bevacizumab injection of 0.05 mL (1.25 mg) was administered at baseline and in 6 week intervals until leakage resolved, and repeated in case of leakage recurrence. Visual acuity (VA) improved in the majority of patients (mean baseline VA=1.078 log MAR) by mean increase of 1.32 lines (last follow-up) ($p=0.001$). Central foveal thickness and total macular volume decreased by 51 μm ($p=0.01$) and 0.84 mm^3 ($p<0.0001$) respectively. No serious complications were observed. As initial therapy, intravitreal bevacizumab appears to be safe and effective. A significant functional and anatomical improvement was noted in majority of patients and maintained during follow-up.

Keywords: bevacizumab, ranibizumab, pegaptanib

Introduction

Photodynamic therapy has shown a positive effect in reducing the risk of visual loss in patients with occult choroidal neovascularization as shown by VIP Study Group,¹ and in minimally classic CNV as shown by Azab et al.² We also noticed from our own clinical experience that the verteporfin therapy has not produced as good results in treatment of minimally classic and occult lesions, as in treatment of classical CNV, so we were of an opinion that further investigation of novel approaches in treatment of such lesion subtypes is fully justified. The positive outcomes of antiVEGF therapy in treatment of neovascular AMD have been fully reported in several studies conducted by Avery et al.³ and Gragoudas et al.⁴ New antiVEGF agent, bevacizumab, has also been used in off-label treatment of neovascular AMD and neovascularization due to pathologic myopia, for several months now as described by Avery et al.,³ Michels et al.,⁵ Nguyen et al.,⁶ and Rosenfeld et al.⁷ Bevacizumab, a humanized monoclonal antibody directed against vascular endothelial growth factor, was already approved by Food and Drug Administration for the treatment of metastatic colorectal cancer as shown by He and Marshall.⁸ By inhibiting angiogenesis and decreasing vascular permeabil-

ity, bevacizumab can be an effective in treatment of a variety of ocular conditions including neovascular AMD. Pegaptanib (Macugen, Eyetech Pharmaceuticals, Inc., New York, NY) has shown positive results compared to usual care of AMD initially, but the mean visual acuity of the entire group declined over course of the years,⁴ as was the case with verteporfin therapy too.^{9,10} Ranibizumab (Lucentis, Genentech) is an antibody fragment derived from the same murine anti-VEGF antibody as bevacizumab. A phase III clinical trial recently demonstrated ranibizumab to be effective in treatment of neovascular AMD (Miller JW. Randomized, controlled phase III study of ranibizumab (Lucentis) for minimally classic or occult neovascular AMD. Paper presented at: ARSR meeting 2005. Montreal, Canada). Since the ranibizumab half-life appears to be shorter than bevacizumab half-life¹¹, and since ranibizumab has not been approved yet by regulatory agencies, and the proposed cost of the drug may turn to be higher than that of bevacizumab already on the market, we think it is fully justified to try to further evaluate bevacizumab in treatment of neovascular AMD as data on this topic is minimal.

In this study we focused on minimally classic and occult membranes, as those in our clinical practice present a main challenge, and according to our own clinical findings, do not respond very well to photodynamic therapy alone or when combined with intravitreal triamcinolone, although such a combination treatment has appeared to be more potent^{12–14}. So in this study we aimed at providing preliminary efficacy and safety results to help determine whether intravitreal bevacizumab can improve visual acuity and macular morphology parameters such as thickness and volume in patients with mentioned subtypes of neovascular AMD and therefore reverse the natural history of the disease, which is particularly unfavorable in those lesion subtypes.

Methods

There were 48 eyes of 48 patients included in this prospective, interventional, noncomparative case series. Patients were recruited by our retinal subdivision and were chosen in order to meet inclusion criteria. At baseline, all patients underwent VA measurement using EDTRS chart, slit lamp and fundus examination and IOP measurements. Fluorescein angiography was performed to identify lesion subtype and location and to verify active choroidal neovascular leakage. Also OCT scan was performed to verify exudation, and to measure foveal thickness and macular volume. Inclusion criteria were as follows: patient age 50, VA better or equal to 20/400, active leakage at FA and OCT scan, subfoveal lesion location, GLD of 7500 μm , no previous treatment. All patients were evaluated and treated every 6 weeks in case of presence of retinal edema, subretinal fluid (SRF) and/or pigment epithelial detachment (PED).

In conducting this study we adhered to the and the study was approved by the Ethics Committee of the Eye Clinic and written informed consent was obtained from the patients in the study describing the experimental nature of the bevacizumab off-label use and potential risks.

All the injections were performed in the operating room under microscope after povidone-iodine eye preparation. Patients received topical and subconjunctival anesthesia. Then 1.25 mg of bevacizumab (Avastin 100 mg / 4mL vial, Genantech Inc, San Francisco, USA) in a volume of 0.05 mL solution was administered intravitreally through pars plana by 27-gauge needle. No paracentesis was required due to small volume injected. After the injection, intraocular pressure, retinal artery perfusion and light appreciation from all 4 directions were checked. Patients were asked to come back for follow-up visits in 6-week intervals, when similar ophthalmologic examination was performed including VA measurement, IOP measurement, angiography and OCT scan.

An additional intravitreal application of bevacizumab was performed using the protocol already described in case of retinal edema, SRF and/or PED presence or recurrence.

The main outcome measures were a mean change in VA between baseline and last follow-up, measured using

EDTRS chart in logMAR units, a mean change in central foveal thickness (CFT) and total macular volume (TMV) (within 3000 μm radius from center of fovea) at baseline and last follow-up, measured by OCT (Stratus III OCT, Carl Zeiss) using 6 diagonal fast scan. Patients with PED were excluded from thickness and volume calculations due to the limitations of current software not including PED thickness in the calculation. The mean VA, foveal thickness and macular volume at the final follow-up were then compared with the baseline values, and statistically analyzed using paired t test to determine statistical significance between two corresponding groups.

Results

A total of 48 eyes of 48 patients with choroidal neovascularization due to AMD were included in the study, meeting the inclusion criteria described previously. There were 29 females and 19 males, with a mean age of 74.8 years (range 62–82). The mean lesion size was 3993 μm (range 500–7500). There were 38 minimally classic CNV membranes and 10 occult CNV membranes (2 associated with PED) as documented angiographically and by OCT scan. Both lesion subtypes responded with a reduction in leakage, as evaluated by an experienced retinologist. All 48 patients completed 6 week follow-up. Median follow-up was 18 weeks (6–24), while mean follow-up was 15.4 weeks.

At 6 weeks after injection 11 of 48 eyes showed resolution of leakage (macular edema, SRF, PED). Of the 40 eyes with 12 week follow-up, 30 showed leakage resolution. Of the 28 eyes completing 18 week follow-up, 17 demonstrated leakage resolution, and of 8 eyes completing 24 week follow-up, 7 demonstrated leakage resolution.

The mean VA at baseline was 20/250⁺ (1.078 logMAR), the mean central foveal thickness (CFT) was 389 μm , while the mean total macular volume (TMV) was 9.33 mm³. There was a significant mean increase in VA from baseline to the time of last follow-up visit of 1.32 lines ($p=0.001$) to 20/160⁻ (0.946 logMAR) (Figure 1). Furthermore there was a significant mean decrease in CFT from baseline to the time of last follow-up visit of 51 μm ($p=0.01$). (Figure 2). The mean macular volume at last follow-up decreased significantly by 0.84 mm³ ($p<0.0001$) compared to baseline. (Figure 3).

Fifteen patients, in whom leakage resolution was achieved initially at one point during follow-up, recurred with subretinal fluid and/or edema and required repeated injection. Those patients were followed-up for at least 12 weeks. Five of those patients with leakage recurrence responded to the additional injection with leakage resolution.

When treatment results were analyzed with respect to lesion size, lesions larger than 6000 μm maintained stable vision, but improvement in VA was not statistically significant. On the other hand, those lesions showed significant macular volume decrease what was maintained to the last follow-up visit.

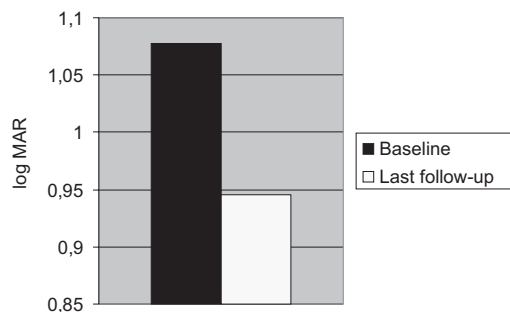


Fig. 1. There was a significant mean increase in best corrected visual acuity from baseline to the time of last follow-up visit of 1.32 lines ($p=0.001$). LogMAR=logarithm of minimum angle of resolution.

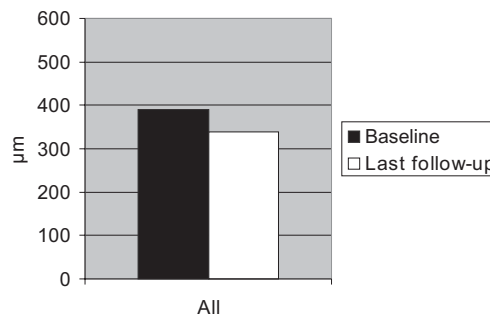


Fig. 2. There was a significant mean decrease in central foveal thickness from baseline (389 µm) to the time of last follow-up visit of 51µm ($p=0.01$).

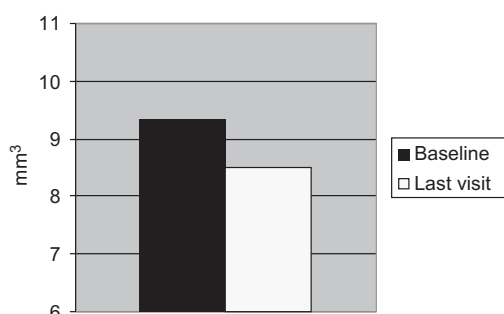


Fig. 3. The mean macular volume at last follow-up decreased significantly for 0.84 mm³ ($p<0.0001$) compared to baseline (9.33 mm³).

There were no adverse reactions to the treatment regimen. No patient developed inflammation, infection, trombo-embolic events or ocular toxicity. No patient required topical anti-glaucomatous therapy, other than what they had used previously for their preexisting glaucoma. No patient complained of significant vision blurring after bevacizumab injections or it disappeared usually within a few days. No major cataract progression was noted and 4 patients underwent cataract extraction during the study period.

Discussion

We are not aware of any study which evaluates intravitreal bevacizumab in treatment of minimally classic and occult choroidal neovascularization due to AMD. In fact, there are only a few studies evaluating efficiency of intravitreal bevacizumab in treatment of exudative AMD what was reported by Avery et al,³ Michels et al,⁵ and Rosenfeld et al.⁷ The mention studies report short term efficacy and safety profile of the treatment and do not differentiate between lesion subtypes. Also the largest and most complete study so far by Avery et al administered intravitreal bevacizumab to patients, majority of whom were already treated either by PDT, pegaptanib or both. Also the patients of all lesion subtypes were included in the Avery's study and follow-up was 8 weeks

for the majority of patients. Due to the previous treatment of AMD with either PDT and/or pegaptanib in the Avery's study, the general idea of how many injections were needed is somewhat tempered, but the Avery's study was an excellent study and the first one to give most complete data up to date on the bevacizumab efficacy, safety and dosing schedule. In our study patients received no previous treatment, they were of a minimally classic and occult lesion subtype and were followed for a longer period (median 18 weeks), and so the general idea of dosing schedule is proposed.

In our clinical practice we perform a treatment of choice for classical CNV which is obviously PDT, but we propose an alternative approach to our patients presenting with minimally classic or occult CNV (with/without PED) due to AMD as we noticed that clinical outcome of PDT in treatment of those lesions leads to stabilization rather than improvement of visual outcome what is consistent with TAP,^{9,15} VIP,¹ Wormald et al¹⁶ and Azab et al² studies. We hypothesize that one of possible theories for such an outcome in those lesion subtypes could be explained by a more difficult light activation of the drug absorbed by target tissue beneath retinal pigment epithelium. Minimally classic and occult membranes are located more deeply than classical membranes and their exposure to the light is somewhat blocked by blood, exudates and partially intact retinal pigment epithelium above them. In such lesions antiVEGF substance could have a better access to target structure by diffusion. At first, it was initially considered that a full-length antibodies, such as bevacizumab, wouldn't be able to penetrate full thickness retina^{11,17} and therefore no widespread investigation of the drug was carried out. But it has been recently shown that although having a full length antibody structure, bevacizumab can penetrate full thickness retina as described by Shahar et al.¹⁸ either because of higher doses used¹⁸ as opposed to first studies,¹¹ lack of ILM at fovea¹⁹ or compromised retinal barriers in macular degeneration^{3,20}.

Although not manufactured and labeled for intravitreal use, the drug was well tolerated with our patients. We have not observed trombo-embolic events nor intraocular toxicity what is consistent with findings by Manzano et al,²¹ and Shahar et al.¹⁸

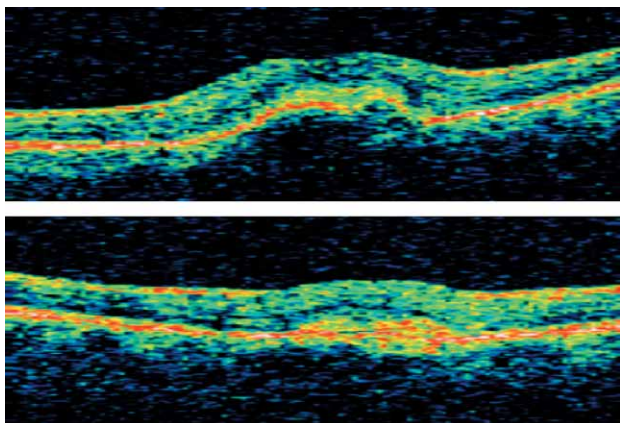


Fig. 4. Minimally classic lesion shown on OCT scan before therapy (left), and 6 weeks after treatment (right). Visual acuity increased from 20/200 to 20/125.

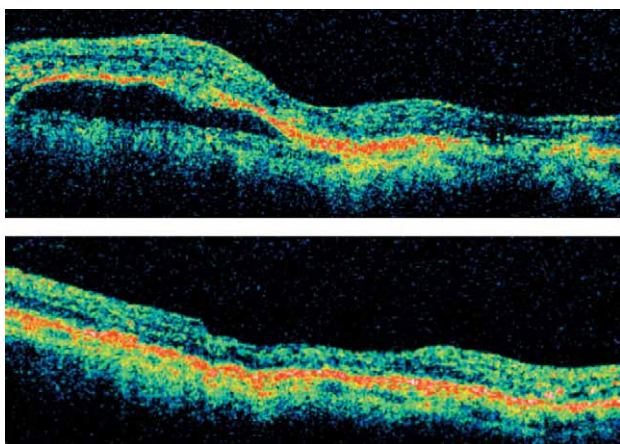


Fig. 5. Before therapy a large pigment epithelial detachment as shown on OCT scan (left), and 6 weeks after treatment (right) with complete resolution of sub-RPE fluid. Visual acuity increased from 20/200 to 20/80.

The proposed volume of the intravitreal bevacizumab is very small (0.05 mL), so we have not experienced any problems with intraocular pressure increase. There is always a risk of endophthalmitis, but since no paracentesis was needed to control the eye pressure, the risk

was even smaller. Also, the post-application period was well tolerated by patients, since bevacizumab is a clear solution not causing vitreal staining. Since the half-life of bevacizumab is quite long as reported by Ignoffo,²² we thought it would be appropriate to give bevacizumab in 6-week intervals as the optimum dosing regimen is still undetermined. This longer half-life may theoretically increase the risk of systemic toxicity but the intravitreal doses are 400 times smaller than when compared to systemic bevacizumab administration^{8,22}. In systemic bevacizumab administration a small but significant risk of thrombo-embolic events exists²³ but with 400-fold dose decrease in intraocular administration this may be of lesser concern. Also a mentioned study showed location of VEGF receptors at neurons at astrocytes²³ suggesting VEGF's neuroprotective role, therefore blockage of such receptors could in theory lead to decreased protection of ganglion cells and photoreceptors in anti-VEGF treated individuals. But the natural history of AMD is so damaging when left untreated so it is a question whether the possible long-term neuroprotection decrease could outweigh the clear short term treatment benefit.

Lesions smaller than 6000 μm , responded with functional improvement to the treatment what reiterates the importance of early detection and early treatment initiation.

We find our study to be a pivotal study in evaluation of treatment results of intravitreal bevacizumab for minimally classic and occult CNV due to AMD, and further studies including more participants and longer follow-up are needed to confirm our findings. Limitations of this study are clearly its interventional character, non-comparative nature and variability in follow-up. But the information provided clearly shows the reversed disease course in treated individual as the improvement of visual acuity and decrease in macular thickens and volume are not consistent with natural development of the disease.

Regardless of whether bevacizumab survives the arrival of newer, hopefully more potent anti-VEGF inhibitors e.g. ranicizumab (already in phase III of clinical trials), for now we have a very limited pool of agents we can choose from in pharmacological treatment of exudative AMD. And the longer bevacizumab half-life and its lower cost, if proven equally potent and safe as ranicizumab and pegaptanid, would certainly be of a great advantage.

REFERENCES

1. VERTEPORFIN IN PHOTODYNAMIC THERAPY STUDY GROUP, Am J Ophthalmol, 131 (2001) 541. — 2. AZAB M, BOYER DS, BRESSLER NM, BRESSLER SB, Arch Ophthalmol 123, (2005) 448. — 3. AVERY RL, PIERAMICI DJ, RABENA MD, Ophthalmology 113 (2006) 363. — 4. GRAGOUDAS ES, ADAMIS AP, CUNNINGHAM ET JR, N Engl J Med 351 (2004) 2805. — 5. MICHELS S, ROSENFELD PJ, PULIAFITO CA, Ophthalmology, 112 (2005) 1035. — 6. NGUYEN QD, SHAH S, TATLIPINAR S, Br J Ophthalmol., 89 (2005) 1368. — 7. ROSENFELD PJ, MOSHFEGHI AA, PULIAFITO CA, Ophthalmic Surg Lasers Imaging, 36 (2005) 331. — 8. HE AR, MARSHALL J, Clin Adv Hematol Oncol, 3 (2005) 555. — 9. TREATMENT OF AGE-RELATED

MACULAR DEGENERATION WITH PHOTODYNAMIC THERAPY (TAP) STUDY GROUP, Arc Ophthalmol, 119 (2001) 198. — 10. Treatment of Age-Related Macular Degeneration with Photodynamic Therapy (Tap) Study Group, Arc Ophthalmol 121 (2003) 1253. — 11. MORDENTI J, CUTHBERTSON RA, FERRARA N, Toxicol Pathol, 27 (1999) 536. — 12. SPAIDE RF, SORENSON J, MARANAN L, Ophthalmology, 110 (2003) 1517. — 13. JONAS JB, KREISSIG I, HUGGER P, Br J Ophthalmol, 87 (2003) 462. — 14. AUGUSTIN AJ, SCHIMDT-ERFURTH U, Ophthalmology, 113 (2006) 14. — 15. TREATMENT OF AGE-RELATED MACULAR DEGENERATION WITH PHOTODYNAMIC THERAPY (TAP) STUDY GROUP, Arch Ophthalmol, 117 (1999) 1329. — 16.

WORMALD R, EVANS J, SMEETH L, HENSHAW K, Cochrane Database Syst Rev CD002030, (2003). — 17. ROSENFELD PJ, SCHWARTZ SD, BLUMENKRANZ MS, Ophthalmology, 112 (2005) 1048. — 18. SHAHAR J, AVERY RL, HEILWEIL G, Retina, 26 (2006) 262. — 19. GREEN WR, SEBAG J, Vitreoretinal interface. In: RYAN SJ, OGDEN TE, HINTON DR (Eds): Retina. 3rd ed. Vol. 3. (Mosby, St. Louis, 2001). — 20. ROSEN-

FELD PJ, MOSHFEGHI AA, PULIAFITO CA., Ophthalmic Surg Lasers Imaging, 36 (2005) 331. — 21. MANZANO RP, PEYMAN GA, KHAN P, KIVILCIN M., Retina, 26 (2006) 257. — 22. IGNOFFO RJ, Am J Health Syst Pharm., 61 Suppl 5 (2004) 21. — 23. VAN WIJENGAARDEN P, COSTNER DJ, WILLIAMS KA., JAMA, 293 (2005) 1509.

R. Lazić

Eye Clinic »Sujetlost«, Bukovačka 27, 10000 Zagreb, Croatia

E-mail: ratimir.lazic@sujetlost.hr

INTRAVITREALNI BEVACIZUMAB (AVASTIN) U LIJEČENJU NEOVASKULARNE SENILNE MAKULARNE DEGENERACIJE

SAŽETAK

Istražiti učinkovitost i sigurnost intravitrealnog bevacizumaba u liječenju minimalno klasične i okultne koroidalne neovaskularizacije u sklopu senilne makularne degeneracije 48 očiju 48-riće pacijenata (prosječne starosti 74.8) u prospektivnoj, nekomparativnoj, intervencijskoj seriji. Praćenje se odvijalo tijekom mediana od 18 tjedana (6–24). Intravitrealnom injekcijom je primjenjeno 0.05 mL (1.25 mg) bevacizumaba u početku studije i u 6-to tjedanim razmacima do prestanka eksudacije, te ponovljeno u slučaju ponavljanja eksudacije. Vidna oštrina (VA) je poboljšana u većine pacijenata (srednja početna VA=1.078 log MAR) za prosječno 1.32 linije (zadnja kontrola) (P=0.001). Srednišnja fovealna debljina i ukupni makularni volumen smanjeni se za 51 μm (p=0.01) i 0.84 mm³ (p<0.0001). Značajne komplikacije nisu zabilježene. Intravitrealni primjenjen bevacizumab je učinkovit i siguran kao inicijalna terapija. Signifikantno funkcionalno i anatomske poboljšanje je zabilježeno u većine pacijenata i održavano tijekom praćenja.