

Giant Choroid Plexus Cyst as an Accidental Finding in an Older Man

Boris Božić, Krešimir Rotim and Karlo Houra

Department of Neurosurgery, University Hospital »Sestre milosrdnice«, Zagreb, Croatia

ABSTRACT

Choroid plexus cysts (CPC) are usually found at the end of the second trimester of pregnancy. Sometimes they can be accidentally found on prenatal ultrasound examinations. Vast majority of CPC resolve spontaneously by 28th weeks gestation. In the older aged group the choroid plexus cysts are extremely rare pathomorphologic medical entity. Since they are almost always asymptomatic, they are therefore accidentally found on brain magnetic resonance (MR) or computed tomography (CT) scans. They are usually located in the lateral ventricles and measure around 2 cm in diameter. We present a case of a 75-year old male with a giant choroid plexus cyst whose leading symptom was excruciating headache refractory to previous conservative therapy. He underwent surgery when osteoplastic craniotomy was performed with cyst fenestration and ablation. His recovery was uneventful with total regression of headaches. Reviewing the recent literature we did not find such a case considering the patients age and the size of the choroid plexus cyst.

Key words: brain, choroid plexus cyst, headache, surgery

Choroid plexus¹ (CP) is a structure found in the ventricles of the brain that produces cerebrospinal fluid. It develops from proliferation of the ependyma at an early ontogenic stage². Differential growth in the rhombencephalon during fifth gestational week results in formation of the pontine flexure which became transversely creased^{2,3}. Within this crease, or plica choroidea, the choroid plexus will develop⁴.

CP is made up of a network of capillary blood vessels covered by transporting epithelial cells. Sometimes the cerebrospinal fluid becomes trapped and forms pockets⁵ in the choroid plexus and those pockets are then called choroid plexus cysts (CPC)⁶. CPC are seen in 1–3% of all mid-trimester prenatal ultrasound examinations^{1,3}. The CPC may be seen in one or both sides of the brain, and generally have no effect on fetal development. On a large series of 1800 fetal ultrasound examinations at the Department of Obstetrics and Gynecology in the Charité hospital in Berlin, Bollemann and colleagues⁷ have found eleven CPC. Choroid plexus cysts are believed to be caused by abnormal folding of the epithelium lining of the choroid plexus which traps fluid and debris^{2,3}.

Even though CPC do have a weak association with fetal chromosome abnormalities, they are most strongly

associated with trisomy 18 (Edward syndrome)^{8–10}. Trisomy 18 is a disorder characterized by severe mental retardation and multiple abnormalities, such as cleft lip and palate, micrognathia, low set ears, club feet, clenched fists, intrauterine growth restriction, single umbilical artery, polyhydramnios and kidney abnormalities. More than 90% of such fetuses have an associated heart defect. The condition is not compatible with life, and only 5 to 10% of infants survive the first year after delivery. As an incidental finding they can be found in the newborns with neonatal teratomas and higeromas¹¹. More than 90% of CPC resolve spontaneously by 28th weeks gestation, and once resolved, the cysts do not recur. Rarely very large cysts may cause obstruction of the cerebrospinal fluid which may need surgical treatment after the infant is born. When an isolated CPC is detected on examination the American College of Obstetricians and Gynecologists recommends amniocentesis is necessary only if serum screening results are abnormal or the patient is older than 32 years at delivery⁹.

CPC in the middle aged and especially in the older aged people are extremely rare pathomorphologic medical entity and they rarely may be large enough to cause any symptoms. Since they are almost always asymptom-

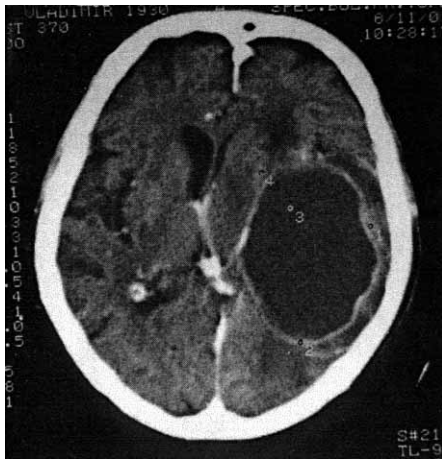

Fig. 1. A giant choroid plexus cyst in the left lateral ventricle in the 75-year old male patient (preoperative figure)

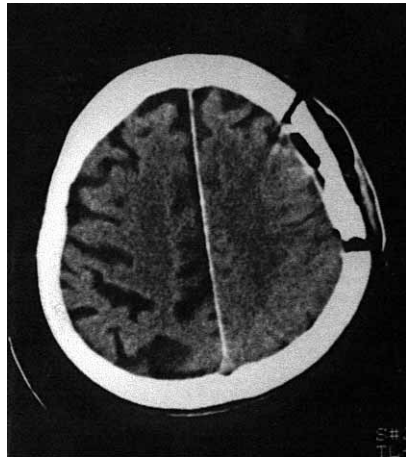

Fig. 2. Postoperative brain CT scan after cyst ablation and osteoplastic craniotomy

atic, they are therefore accidentally found on brain magnetic resonance (MR) or CT scans. Small asymptomatic cysts of the choroid plexus are a frequent incidental finding at necropsy^{12,13}. They are usually located in the lateral ventricles but sometimes may be found also in the fourth ventricle. Their size usually does not extend beyond 1.5–2 cm in diameter which was also true in the re-

search of Tamura¹² and colleagues who made an autopsy on patients with malignant tumors of choroid plexus.

A 75-year old male was admitted at our Department of Neurosurgery due to the excruciating headaches¹⁴ which lasted for couple of months and were refractory to previous conservative therapy with common painkillers. A brain CT scan revealed a large choroid plexus cyst measuring 70.2 x 47.4 x 56.7 mm in the left temporo-parietal region with the compression of the adjacent lateral ventricle (Figure 1). After a complete neuroradiological evaluation, the patient underwent surgery. A left sided temporo-parietal osteoplastic craniotomy was performed followed by semicircular dural incision and corticotomy. After entering in the lateral ventricle the cyst was totally resected and removed in the microsurgical manner. The dura was closed in watertight manner to prevent the cerebrospinal fluid leak and the bone was replaced and fixated (Figure 2). A pathohistological analysis of resected cyst revealed fragments of a cyst wall covered by a single row of cuboidal cells folded into villi, at luminal surface, resembling choroid plexus epithelium. Epithelial cells displayed extensive EMA and S-100 immunoreactivity (Figure 3). The patient's postoperative recovery was uneventful with total regression of headaches.

In the end we would like to emphasize once more that while reviewing the recent literature we did not find such a case of a choroid plexus cyst considering the patients age and the size of the cyst.

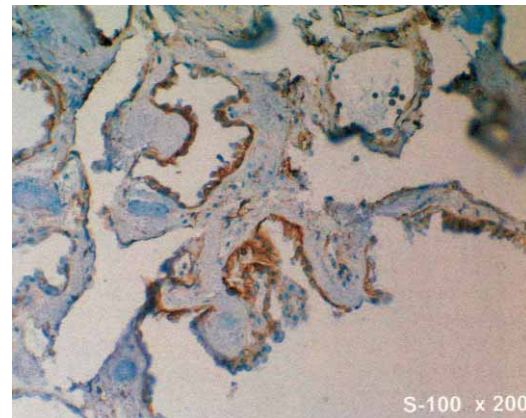


Fig. 3. Pathohistological finding of a choroid plexus cyst wall dyed using immunoreactive method S-100.

REFERENCES

1. PELEG D, YANKOWITZ J, J Med Genet, 35 (1998) 554. — 2. SHU-ANGSHOTI S, NETSKY MG, Am J Anat, 118 (1966) 283. — 3. GUARIGLIA L, ROSATI P, Prenat Diagn. 19(2) (1999) 128. — 4. CHITKARA U, Obstet Gynecol, 72 (1988) 185. — 5. BURROWS A, Aust N Z J Obstet Gynaecol, 33 (1993) 262. — 6. DIGIOVANNI LM, Obstet Gynecol, 90 (1997) 191. — 7. BOLMANN R, CHAOUI R, ZEINERT A, KORNER H, Zentral Gynaecol, 114 (1992) 171. — 8. YODER PR, Obstet Gynecol 93 (1999) 869. — 9. ACOG Obstet Gynecol, 97 (2001) suppl 1–12. — 10. KENNETH LJ, Smith's Recognizable Patterns of Human Malformations (Saunders Co, Philadelphia, 1997). — 11. JAARSMA AS, TAMMINGOOR, DE LANGEN ZJ, VAN DER LAAN T, NIKKELS PG, KIMPEN JL, Eur J Pediatric, 153 (1994) 276. — 12. TAMURA Z, USIZIMA H, TAKASHI M, SAKAI I, Gan. 1954 45(2-3) 333. — 13. CASENTINI L, RIGOBELLO L, GEROSA M, PARDDATSCHER K, ANDRIOLI GC, Zentralbl Neurochir, 40 (1979) 239. — 14. BOZIC B, KOGLER A, TALAN-HRANILOVIC J, BEROS V, SAJKO T, HAT J, Neurol Croat, 50 (2001) 75.

K. Houra

*Department of Neurosurgery, University Hospital »Sestre milosrdnice«, Vinogradska 29, 10000 Zagreb, Croatia
e-mail: khoura@kbsm.hr*

GIGANTSKA CISTA KOROIDNOG SPLETA KAO SLUČAJAN NALAZ U STARIJEG MUŠKARCA

S A Ž E T A K

Ciste korioidnog pleksusa kao morfološki entitet vežu se za kraj drugog trimestra graviditeta. Kao slučajan nalaz znaju se pronaći prilikom ultrazvučnog pregleda ploda kod trudnica. Tijekom sazrijevanja ploda najveći broj cisti korioidnog pleksusa spontano regredira. Ciste korioidnog pleksusa u osoba odmakle životne dobi, su izrazito rijedak patomorfološki entitet. U pravilu su asimptomatskog tijeka i nađu se kao rijedak patomorfološki supstrat pri snimanju mozga kompjuteriziranom tomografijom (CT) ili magnetnom rezonancom (MR). Najčešće su smještene u postraničnim moždanim kljetkama. Kod osoba starije životne dobi obično se kao usputni nalaz nađu na patološkim obdukcijama i veličine su 1.5 do 2 cm. Nalaz gigantske ciste korioidnog pleksusa u osoba starije živote dobi je raritetan nalaz. U našem se slučaju radilo o starijoj muškoj osobi u dobi od 75 godina. Osnovni i vodeći simptom bila je glavobolja refraktorna na konzervativno liječenje. Pacijent je operiran te je učinjena ablacija ciste i osteoplastična kraniotomija. Poteškoće u vidu glavobolja su poslije operacije u potpunosti regredirale. Pregledom novije medicinske literature nismo naišli na takav slučaj ni s obzirom na visoku bolesnikovu dob, ni s obzirom na veličinu ciste korioidnog pleksusa.