

## SUBFASCIAL ENDOSCOPIC PERFORATING VEIN SURGERY (SEPS): THE TECHNIQUE AND OUR VIEWS

Björn Dario Franjić, Ivo Lovričević, Tomislav Kuna, Zvonimir Puljiz, Narcis Hudorović, Drago De Syo, Aljoša Matejčić and Miroslav Bekavac-Bešlin

University Department of Surgery, Sestre milosrdnice University Hospital, Zagreb, Croatia

**SUMMARY** – Chronic venous insufficiency is a major health and socioeconomic issue throughout the world. Some 2%-5% of the adult population suffer from chronic venous insufficiency, while about 1% of the European population have chronic leg ulceration. The role of retrograde blood flow through incompetent perforating veins has an important role in the development of chronic venous insufficiency. Duplex ultrasound imaging is the preferred diagnostic tool, which is used to confirm the presence of bidirectional flow through the perforators adjacent to the areas of lipodermatosclerosis, healed ulcers and open ulcerations, i.e. in patients with chronic venous insufficiency CEAP class 4, 5 and 6. Subfascial endoscopic perforating vein surgery (SEPS) is a minimally invasive surgical procedure, which is the treatment of choice in these patients. The endoscope and surgical instruments are introduced through skin incisions that are distant from the areas of skin changes. The perforating veins are excellently visualized, while clipping and dividing the perforators interrupt retrograde blood flow. In patients with insufficiency of the superficial venous system, ligation and stripping of the superficial veins are usually performed at the same time. The lesser saphenous vein can be occluded with SEPS itself. The healing time with SEPS is substantially decreased when compared with conventional treatment and carries low complication and recurrence rates. However, SEPS should be offered to selected patients, i.e. to those with chronic venous insufficiency CEAP class 4, 5 and 6.

**Key words:** *Vascular surgical procedures, methods; Vascular surgical procedures, utilization; Peripheral vascular diseases, surgery; Croatia*

### Introduction

It is estimated that 2% to 5% of the adult population have chronic venous insufficiency. Chronic leg ulceration affects about 1% of the population in Europe at some point in their lives. Von Loder<sup>1</sup> was among the first who described the anatomy of communicating veins between the superficial and deep venous systems in 1803. Linton and Hardy<sup>2</sup> and Linton<sup>3</sup> advocated interruption of these veins to treat venous ulceration in the 1930s and 1940s. Cockett<sup>4</sup> contributed to better understanding of the physiology of varicose veins and ulcerations in the 1950s and devel-

oped a new surgical approach. Edwards<sup>5</sup> devised the phlebectomy and commenced blind disruption of perforating veins in 1975. The pioneer work of Hauer<sup>6</sup> from 1985 is crucial for the endoscopic approach to surgery of insufficient perforating veins.

The contribution of perforating veins to the varicose syndrome manifestations and especially to the development of chronic venous insufficiency is a matter of continuous study and at times arises controversy. The pathophysiology of chronic venous insufficiency emphasizes the role of retrograde blood flow through incompetent perforating veins in chronic congestion of venous blood and the consecutive manifestations in the form of chronic venous insufficiency. Recent ultrasonographic studies confirm the standpoints on the bidirectional flow, which is found in the perforating veins greater than 2 mm in diameter, adjacent to the areas of lipodermatosclerosis, healed ulcers and ulcerations.

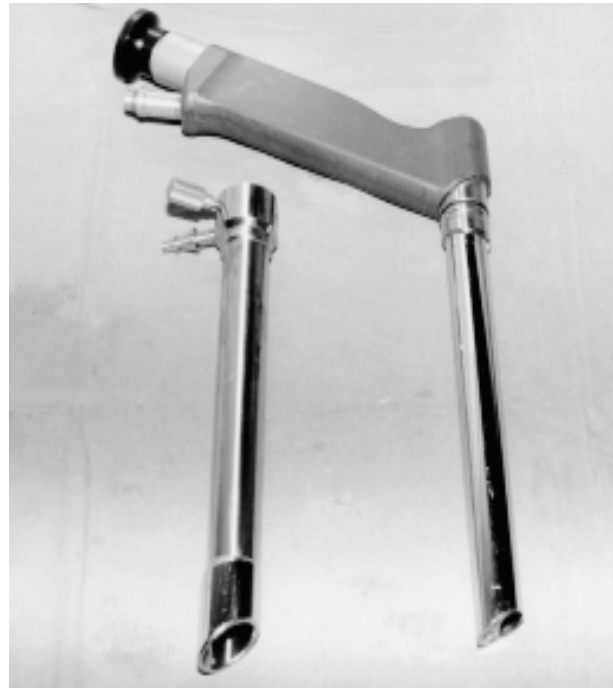Correspondence to: *Björn D. Franjić, M.D.*, University Department of Surgery, Sestre milosrdnice University Hospital, Vinogradska c. 29, HR-10000 Zagreb, Croatia  
E-mail: [bjorn.franjic@zg.htnet.hr](mailto:bjorn.franjic@zg.htnet.hr)

Received May 20, 2003, accepted in revised form October 17, 2003

Conventional surgery of perforating veins requires long skin incisions in order to ligate incompetent perforating veins. As the overlying skin is often atrophic, poorly nourished and frequently affected with skin necrosis, impaired wound healing and wound infection pose considerable problem. Edwards<sup>5</sup> introduced the phlebectome, which is essentially a device that is introduced under the fascia at a distant site, thus avoiding skin incisions in the areas of lipodermatosclerosis. The phlebectome shears off all perforating veins; the disadvantage of this method lies in the fact that it is performed blindly and painful subfascial hematomas may occur. The introduction of endoscopy solves this problem and permits direct visualization of perforating veins and their ligation.

### Patients and Methods

Two basic types of endoscopic techniques can be used in subfascial endoscopic perforating vein surgery (SEPS)<sup>7-9</sup>. One implies the use of open endoscope (Figs. 1 and 2) that is introduced subfascially immediately upon skin incision, and dissection of the subfascial plane is accomplished manually with endoscopic instruments; then the procedure is commenced. This endoscope contains an integrated port through which endoscopic instruments are introduced; therefore, a single incision is required. The other method of endoscopy includes the use of balloon dissector, which is introduced and insufflated to create a large working space in the subfascial plane. Following its removal, a 10-mm trocar is positioned and an insufflator is used to introduce carbon dioxide to maintain this working space at a pressure of 15 mm Hg. Finally, a 10-mm lap-



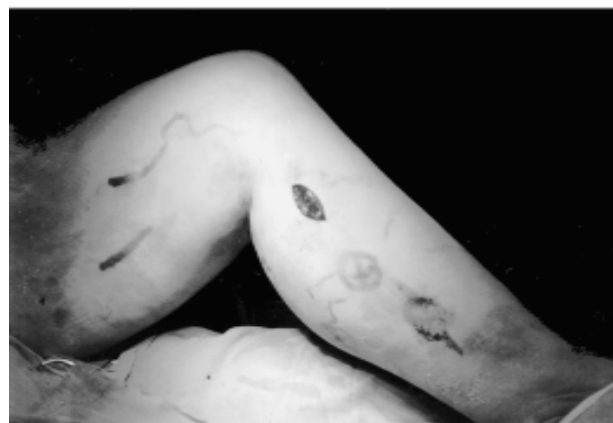*Fig. 2. The endoscope used for SEPS.*

aroscope is positioned. Another skin incision at 3-5 cm inferomedially to the first one is made and an endoinstrument is introduced under direct visual control through the endoscope. The instruments used for the latter method are in general the same as those used in standard laparoscopic cholecystectomy.

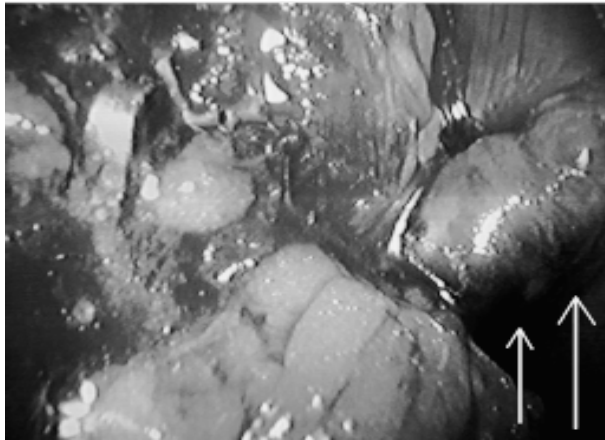
During the procedure, the patient is in supine and Trendelenburg position with the knee flexed and elevated. The whole extremity is circumferentially prepped. The



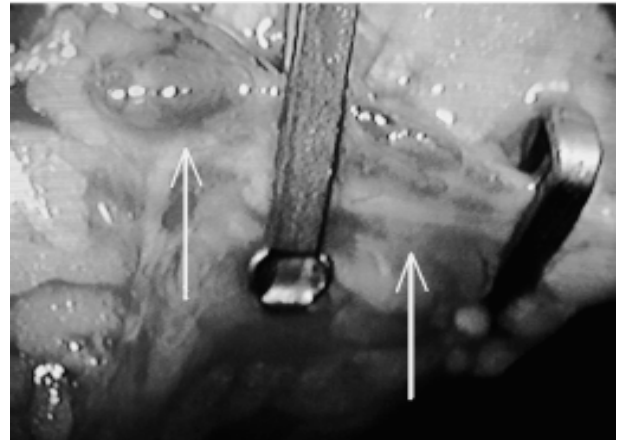
*Fig. 1. The endoscope used for SEPS at the University Department of Surgery, Sestre milosrdnice University Hospital, Zagreb.*



*Fig. 3. Incision in the medial portion of the leg where the endoscope is introduced.*



*Fig. 4. Visualization of a dilated and incompetent perforating vein during SEPS (white arrows).*



*Fig. 5. The perforating vein (arrows) is occluded with 2 clips.*

skin incision usually does not exceed 2-3 cm and is positioned about 10-12 cm below the popliteal crease, approximately 2-4 cm posteromedially to the tibia (Fig. 3).

The endoscope is introduced under the fascia. Usually, all visualized perforating veins are double clipped, hence their continuity is interrupted and it is not crucial to divide them (Figs. 4 and 5). However, division of the perforators may be performed to facilitate distal exposure.

In patients with insufficiency of the superficial venous system, ligation and stripping of the superficial veins is usually performed. The greater saphenous vein is removed retrogradely in order to avoid the areas of lipodermatosclerosis (Fig. 6). The lesser saphenous vein can be occluded by SEPS itself.

Upon completion of the perforating vein interruption, the instruments are removed and the skin incisions are



*Fig. 6. Incision in the left groin with dissected proximal end of the greater saphenous vein during its stripping.*

closed with interrupted mattress stitches using monofilament suture. The wounds are covered with dressings and the leg is wrapped with compression bandage from the forefoot to the thigh. Two hours later, the compression bandage is reapplied with a lower degree of tension.

The first SEPS procedure at the University Department of Surgery, Sestre milosrdnice University Hospital in Zagreb was performed in 1998. During the next 5-year period (1998-2002), 43 patients with chronic venous insufficiency underwent SEPS. Ten of these patients had active ulcers and the remaining 33 had lipodermatosclerosis. All procedures were performed following tourniquet application. Extirpation of the greater saphenous vein was performed in all our patients and ligation of the lesser saphenous vein in two patients. Careful preparation of the subfascial plane is recommended to avoid hemorrhage, which may impede further visualization and necessitate conversion to open procedure. This was the case in one patient.

The patients were generally discharged on the next day and the first follow up visit was scheduled one week after the surgery, when the sutures were removed. Elastic compression was applied for another 6-8 weeks during the day and removed overnight.

### *Patient evaluation and selection*

A prerequisite for surgery of the superficial and perforating venous systems is demonstration of the presence of a patent deep system and confirmation of the incompetence of the perforating veins and superficial veins. This may be achieved by either phlebography or color duplex

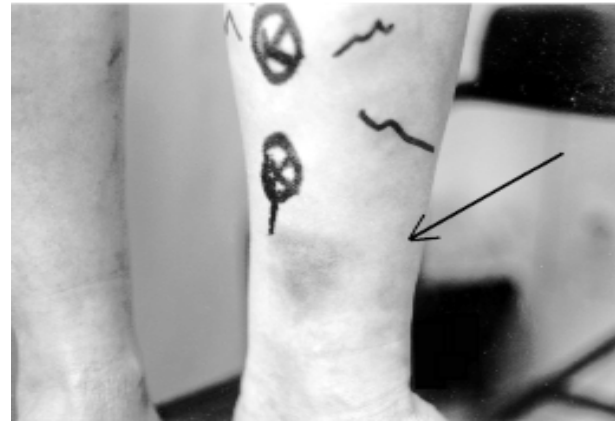
ultrasound imaging.

Phlebography is an invasive procedure that carries a potential risk of allergic reaction to the contrast medium administered into the dorsal foot veins. The contrast injection is often quite painful and sometimes it cannot be used due to the vein fragility in chronic venous insufficiency.

Ultrasonography, on the other hand, carries virtually no risk for the patient and may be more informative than phlebography<sup>10,11</sup>. Modern ultrasonography permits hemodynamic evaluation and 'road mapping' of the perforating veins and their blood flow. The majority of our patients are operated on on the basis of duplex scanning alone.

The question of patient selection remains somewhat controversial. We believe and most literature reports concur that SEPS should only be offered to selected patients who fall into class 4, 5 or 6 according to CEAP (Clinical status – Etiology – Anatomical distribution – Pathophysiology) classification of venous disease (Table 1). These patients have preulcerative changes of the skin, which include lipodermatosclerosis, pain and pigmentation (Fig. 7), or have active venous ulcers or healed ulcers.

SEPS is performed under general or spinal anesthesia, and all standard preoperative evaluations are required. The



*Fig. 7. Area of lipodermatosclerosis of the left leg (arrow). The position of Cockett's perforators (circles with crosses) and incompetent superficial veins (lines) are preoperatively marked on the skin.*

patient is usually admitted on the day of surgery and discharged on the next day. With the emergence of the one-day surgery principles, it might prove possible to discharge the patient on the very same day.

## Results and Discussion

Chronic venous insufficiency is a major health and socioeconomic issue throughout the world. It is estimated that about 2% of the entire health care expenditure in European countries are linked to chronic venous insufficiency.

It is believed that sustained venous hypertension arising from incompetence of the deep and superficial venous systems leads to skin changes and ulcerations found in chronic venous insufficiency. Incompetent perforating veins are found in patients with chronic venous insufficiency. The diameter of both competent and incompetent perforating veins as well as the number of incompetent perforating veins increase with the severity of chronic venous insufficiency<sup>11</sup>. Philips and Cheng<sup>12</sup> found most perforators of  $\geq 4$  mm in diameter and only one third of those with a diameter of  $< 4$  mm to be incompetent. Numerous data suggest that surgical repair of incompetent superficial and perforating veins is of clinical benefit in aiding ulcer healing and in preventing ulcer recurrence.

SEPS alone, without treating incompetent superficial or deep veins, seldom leads to ulcer healing. Furthermore, occlusion of perforating veins in the areas of lipodermatosclerosis and venous ulcers is often demonstrated<sup>13</sup>. SEPS enables occlusion of Cockett's perforators, gastrocnemius perforators and lesser saphenous vein orifice.

*Table 1. CEAP\* classification of chronic venous disease*

### Clinical class

- 0 No visible signs
- 1 Telangiectasias or reticular veins
- 2 Varicose veins
- 3 Edema
- 4 Pigmentation, venous eczema, lipodermatosclerosis
- 5 Skin changes with healed ulceration
- 6 Skin changes with active ulcer

### Etiology class

- C Congenital
- P Primary
- S Secondary

### Anatomic class

- S Superficial
- D Deep
- P Perforating

### Pathophysiologic class

- R Reflux
- O Obstruction
- RO Reflux & obstruction

\* Clinical status – Etiology – Anatomical distribution – Pathophysiology classification

According to literature data, the average healing time for active ulcerations following SEPS is 42 days and is accompanied by a low recurrence rate of only 3%<sup>14</sup>. Ulcers heal in some 88% of patients<sup>15</sup>, yielding a 4-fold reduction in healing time as compared with nonsurgical treatment.

The main advantages of SEPS include virtual elimination of morbidity from wound complications. By avoiding the areas of skin lesions overlying the incompetent perforating veins, the incisions are made in the normal skin, hence the low rates of impaired wound healing at the site of endoscope and instrument introduction<sup>8</sup>. Direct visualization of perforating veins in the subfascial plane permits a more thorough identification of perforating veins that were not detected on duplex imaging, which only contributes to the minimal recurrence rate. The process of clipping or dividing the perforators itself achieves the same hemodynamic results as in open surgery.

The possible complications that may occur with SEPS, although quite rare, include lesions of the tibial<sup>16</sup> and saphenous nerves, deep venous thrombosis, subfascial and wound hematomas, and wound infection. Subfascial hematomas were observed in 3%-6%, and delayed wound healing was recorded in 3% of patients<sup>17</sup>. The total rates of these complications reported in the literature are extremely low.

Minimal hospital stay is required following SEPS as compared with postoperative stay following Linton operation (median 2 vs 9 days) in patients with CEAP class 4, 5 and 6, and it may be performed on a one-day surgery basis<sup>18</sup>.

At some facilities, SEPS has been widely performed to treat patients falling into CEAP classes lower than 4. This arises some controversy about the real advantage of SEPS in treating patients without strict indications who may equally be treated by open surgery with comparable results and only minimally poorer cosmetic results from several incisions as opposed to one incision needed in SEPS. The number of skin incisions is equal if ligation and stripping of the superficial veins are performed in the same act, hence no real practical advantage is noted in these patients. Furthermore, the potential neural lesion that may occur during SEPS limits its use to strict indications, which does not include uncomplicated primary varicose veins.

In conclusion, it may be said that SEPS is a minimally invasive surgical procedure that provides excellent visualization of the anatomy of the subfascial plane. It enables introduction of the instruments through skin incisions that are distant from the site of skin changes and carries a low rate of complications. Hence, SEPS is the procedure of

choice in the treatment of patients with chronic venous insufficiency CEAP class 4, 5 and 6.

## References

1. Van LODER JC. Anatomische Tafeln. Text (2 Vol), Table 127. Weimar, 1803.
2. LINTON RR, HARDY IB. Post-thrombotic syndrome of the lower extremity: treatment by interruption of the superficial femoral vein and ligation and stripping of the long and short saphenous vein. *Surgery* 1948;24:452-68.
3. LINTON RR. The communicating veins of the lower leg and the operative technique for their ligation. *Ann Surg* 1938;107:582-93.
4. COCKETT FB. The pathology and treatment of varicose ulcers of the leg. *Br J Surg* 1955;43:260-78.
5. EDWARDS JM. Shearing operation for incompetent perforating veins. *Br J Surg* 1976;63:885-6.
6. HAUER G. Die endoskopische subfasciale Division der Perforansvenen – vorläufige Mitteilung. *Vasa* 1985;14:59-61.
7. PORTER JM, MONETA GL. Reporting standards in venous disease: an update. International Consensus Committee on Chronic Venous Disease. *J Vasc Surg* 1995;21:635-45.
8. PIERIK EG, van URK H, *et al.* Endoscopic versus open subfascial division of incompetent perforating veins in the treatment of venous leg ulceration: a randomized trial. *J Vasc Surg* 1997;26:1049-54.
9. TAWES RL, WETTER LA, HERMANN GD, FOGARTY TJ. Endoscopic technique for subfascial perforating vein surgery. *J Endovasc Surg* 1996;3:414-20.
10. PIERIK EG, TOONDER IM, *et al.* Validation of duplex ultrasonography in detecting competent and incompetent perforating veins in patients with venous ulceration of the lower leg. *J Vasc Surg* 1997;26:49-52.
11. LABROPOULUS N, MANSOUR MA, KANG SS, GLOVICZKI P, BAKER H. New insights into perforator vein incompetence. *Eur J Vasc Endovasc Surg* 1999;18:228-34.
12. PHILIPS GW, CHENG LS. The value of ultrasound in the assessment of incompetent perforating veins. *Australas Radiol* 1996;40:15-8.
13. LOVRIČEVIĆ I. Antirefluksni kirurški postupak u liječenju kronične venske insuficijencije. Doctoral dissertation. Zagreb: Zagreb University School of Medicine, 2001.
14. SCRIVEN JM, BIANCHI V, HARTSHORNE T, BELL PRF, NAYLOR AR, LONDON NJM. A clinical and haemodynamic investigation into the role of calf perforating vein surgery in patients with venous ulceration and deep venous incompetence. *Eur J Vasc Endovasc Surg* 1998;16:148-52.
15. GLOVICZKI P, BERGAN JJ, MENAWAT SS, *et al.* Safety, feasibility and early efficacy of endoscopic subfascial perforator surgery: a preliminary report from the North American Registry. *J Vasc Surg* 1997;25:94-105.
16. WHITLEY MS, SMITH JJ, GALLAND RB. Tibial nerve damage during subfascial endoscopic perforator vein surgery (SEPS). *Br J Surg* 1997;84:512.

17. WHITLEY MS, SMITH JJ, GALLAND RB. Subfascial endoscopic perforator vein surgery (SEPS): current practice among British surgeons. *Ann R Coll Surg Engl* 1998;80:104-7.
18. STUART WP, ADAM DJ, BRADBURY AW, RUCKLEY CV. Subfascial endoscopic perforator surgery is associated with significantly less morbidity and shorter hospital stay than open operation (Linton procedure). *Br J Surg* 1997;84:1364-5.

#### Sažetak

### SUBFASCIJALNA ENDOSKOPSKA KIRURGIJA PERFORANTNIH VENA (SEPS): TEHNIKA I NAŠA STAJALIŠTA

*B.D. Franjić, I. Lovričević, T. Kuna, Z. Puljiž, N. Hudorović, D. De Syo, A. Matejčić i M. Bekavac-Bešlin*

Kronična venska insuficijencija predstavlja značajan zdravstveni i socioekonomski problem u cijelom svijetu. Oko 2% do 5% odrasle populacije ima kroničnu vensku insuficijenciju, a oko 1% europske populacije ima kronične venske ulceracije. Za razvoj kronične venske insuficijencije važna je uloga retrogradnog protoka krvi kroz nekompetentne perforantne vene. Dupleks ultrazvučni prikaz je dijagnostičko sredstvo izbora kojim se potvrđuje prisutnost dvosmjernog protoka kroz perforatore koji se nalaze uz mjesta lipodermatoskleroze, zacijeljenih ili otvorenih ulceracija, tj. kod bolesnika s kroničnom venskom insuficijencijom 4., 5. i 6. CEAP razreda. Subfascijalna endoskopska kirurgija perforantnih vena (SEPS) je minimalno invazivni kirurški postupak koji predstavlja metodu izbora kod ovih bolesnika. Endoskop i kirurški instrument se uvode kroz rezove na koži, koji su udaljeni u odnosu na kožne promjene. Perforantne vene se odlično prikazuju, te se njihovim 'klipsanjem' i presijecanjem uklanja retrogradni protok krvi. Kod bolesnika s insuficijentnim površinskim venskim sustavom se u istom aktu učini i podvezivanje, kao i odstranjivanje površinskih vena. Vena saphena parva se može okludirati i samim SEPS-om. Vrijeme cijeljenja kod SEPS-a znatno je kraće u odnosu na klasično liječenje i praćeno je niskim stopama komplikacija i recidiva. Ipak, SEPS bi se trebao indicirati samo u određenih bolesnika, tj. onih s kroničnom venskom insuficijencijom 4., 5. i 6. CEAP razreda.

*Ključne riječi: Vaskularni kirurški zahvati, metode; Vaskularni kirurški zahvati, primjena; Periferne krvne žilne bolesti, kirurgija; Hrvatska*