

## OCULAR PSEUDOEXFOLIATION SYNDROME AND INTERNAL SYSTEMIC DISEASES

Jasenka Brajković, Ivana Kalauz-Surać, Ante Ercegović, Alenka Miletić-Jurić, Nikola Sušić and Željko Burić

Department of Ophthalmology, Šibenik General Hospital, Šibenik, Croatia

**SUMMARY** – The aim of the study was to assess the association between the presence of ocular pseudoexfoliation syndrome and internal systemic diseases, i.e. arterial hypertension, angina pectoris, myocardial infarction, heart arrhythmias, diabetes mellitus, stroke and transient ischemic attacks. This prospective study included 646 patients aged  $\geq 50$  examined at a general ophthalmology clinic in Knin. Ophthalmologic examination included visual acuity testing and refraction, slit lamp examination, fundus examination and applanation tonometry. The diagnosis of pseudoexfoliation syndrome was based on the presence of characteristic whitish, granular deposits on the anterior segment structures of the eye. Data on the presence of internal systemic disease were collected by interview with patients and from internist and neurological medical records. All data collected were statistically analyzed by use of  $\chi^2$ -test and ANOVA. In patients with pseudoexfoliation syndrome, the prevalence of arterial hypertension ( $p=0.468$ ), ischemic heart disease ( $p=0.372$ ), cerebrovascular disease ( $p=0.485$ ), diabetes mellitus ( $p=0.492$ ) was not statistically significantly higher in comparison with patients without pseudoexfoliation syndrome. However, the prevalence of heart arrhythmia was statistically significantly higher in patients with than in those without pseudoexfoliation syndrome ( $p=0.001$ ). Based on the results of this and other studies, the question of whether the presence of ocular pseudoexfoliation syndrome could be used as a marker in detecting individuals with heart arrhythmias or internal disease remains open.

**Key words:** *ocular pseudoexfoliation syndrome, internal systemic diseases*

### Introduction

Pseudoexfoliation syndrome (PEX) is a generalized disorder of the extracellular matrix. It is characterized by extensive production and accumulation of fibrillar material in all structures of the anterior segment of the eye (palpebral and bulbar conjunctiva, corneal endothelium, angle of the anterior chamber, iris, muscle dilator and blood vessels of the iris, epithelium of the ciliary body, zonules, anterior lens capsule and the anterior vitreous surface)<sup>1,2</sup>. Electron microscopy has confirmed the presence of PEX material in connective tissue of different visceral organs (skin, lung, gallbladder, liver,

myocardium, kidney, bladder, meninges and blood vessels)<sup>3,4</sup>.

PEX is manifested clinically by the presence of whitish, granular, dandruff-like deposits within the structures of the anterior segment of the eye, unilaterally or bilaterally. The iris sphincter atrophy is often present and a "moth-eaten" appearance of the iris is seen on transillumination. Dispersed pigment of the iris is accumulated in the trabecular meshwork along the Schwalbe line, thus forming a typical Sampaolesi line. Pharmacological dilatation of the pupil is reduced and the zonular apparatus weakened<sup>5</sup>.

The aim of the study was to assess the possible association between ocular PEX and internal systemic diseases such as arterial hypertension, ischemic heart disease (angina pectoris, myocardial infarction), heart arrhythmias, diabetes mellitus and cerebrovascular disease (stroke and transient ischemic attacks).

Correspondence to: *Jasenka Brajković, MD*, Department of Ophthalmology, Šibenik General Hospital, Stjepana Radića 83, HR-22000 Šibenik, Croatia

Received January 30, 2007, accepted March 26, 2007

### Patients and Methods

This prospective study included 646 patients aged =50 examined at a general ophthalmology clinic in Knin during the period between October 2005 and April 2006. Ophthalmologic examination included visual acuity testing and refraction, slit lamp examination, fundus examination and applanation tonometry using Goldmann's applanation tonometer. All examinations were performed by the same examiner. The diagnosis of PEX was based on the presence of characteristic whitish, granular deposits on the anterior segment structures of the eye.

Data on the presence of internal systemic disease were collected by interview with patients and from internist and neurological medical records. All data collected were statistically analyzed by use of  $\chi^2$ -test and ANOVA.

### Results

Out of 646 patients, 161 (25%) had PEX on one or both eyes. In the study series, there was an equal number of women (54%) and men (46%). The prevalence of PEX was not statistically significantly connected with sex ( $p=0.251$ ) (Fig. 1).

Study patients were divided into 4 age groups: 50-60 ( $n=126$ ), 61-70 ( $n=210$ ), 71-80 ( $n=248$ ) and  $\geq 81$  ( $n=62$ ). The prevalence of PEX patients was greater in older age groups. The highest number of PEX patients was recorded in the 71-80 age group. There was no statistically significant difference in the prevalence of arterial hypertension between patients with and without PEX ( $p=0.468$ ) (Fig. 2). The group of patients with ischemic heart disease included patients with angina pectoris and patients with a history of myocardial inf-

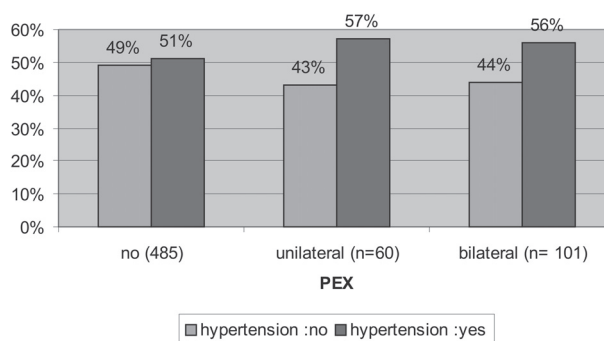


Fig. 2. Prevalence of arterial hypertension in patients without and with pseudoexfoliation syndrome.

arction. There was no statistically significant difference in the prevalence ischemic heart disease between patients with and without PEX ( $p=0.372$ ) (Fig. 3). Furthermore, there was no statistically significant difference in the prevalence of diabetes mellitus between patients with and without PEX ( $p=0.492$ ) (Fig. 4). The group of patients with cerebrovascular disease included patients who had sustained one or more transient ischemic attacks and patients with a history of stroke. There was no statistically significant difference in the prevalence of cerebrovascular disease between patients with and without PEX ( $p=0.485$ ) (Fig. 5). There were 106 (16%) patients with heart arrhythmias. This group included patients with any medicamentously or operatively (pacemaker) treated dysfunction of the heart rhythm (atrial fibrillation, A-V block, supraventricular rhythm dysfunction, ventricular extrasystole). The prevalence of heart arrhythmias was statistically significantly higher in patients with PEX in comparison with patients without PEX ( $p=0.001$ ) (Fig. 6).

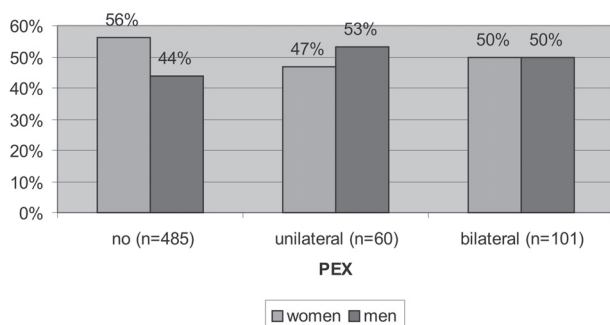


Fig. 1. Sex distribution of patients with pseudoexfoliation syndrome.

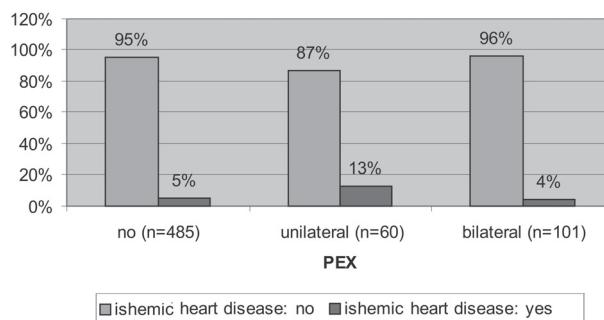


Fig. 3. Prevalence of ischemic heart diseases in patients without and with pseudoexfoliation syndrome.

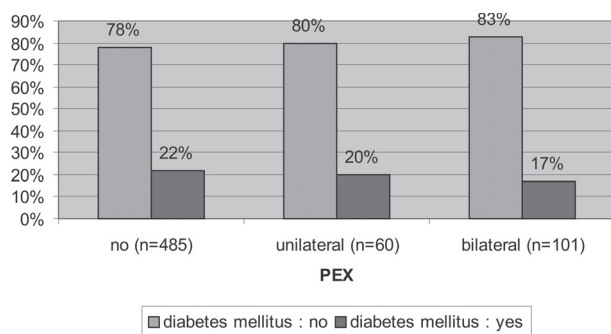


Fig. 4. Prevalence of diabetes mellitus in patients without and with pseudoexfoliation syndrome.

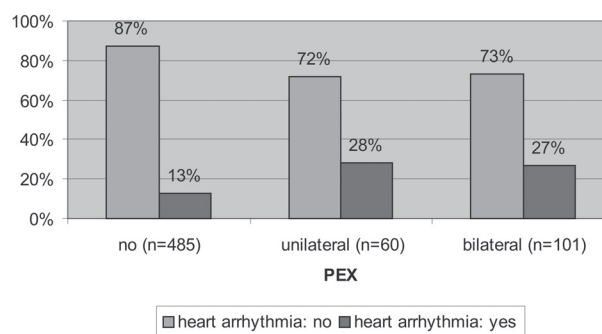


Fig. 6. Prevalence of heart arrhythmias in patients without and with pseudoexfoliation syndrome.

## Discussion and Conclusion

There are numerous studies of the association of ocular PEX syndrome and different internal diseases. However, the results are controversial. Mitchell *et al.* found PEX to be significantly associated with a history of angina or hypertension or combined history of angina pectoris, acute myocardial infarction or stroke. They attributed it to the effect of wide-spread elastosis in PEX on many tissues including vessel walls<sup>6</sup>. In his study, Sollosy recorded a high incidence of PEX syndrome in diabetic patients<sup>7</sup>. However, several studies report an even lower incidence of PEX in diabetic patients<sup>8</sup>. Sainz Gomez *et al.* also failed to demonstrate any association of PEX with hypertension and diabetes, but found a 3.5-fold prevalence of PEX in patients with heart failure<sup>9</sup>. A high prevalence of PEX was found in patients with transient ischemic attacks<sup>10</sup>. Moreover, acute cerebrovascular disease and chronic cerebral disease (senile dementia, cerebral atrophy and chronic cerebral ischemia) were more common in patients with exfoliative glaucoma than in patients with primary open-angle glaucoma<sup>11</sup>. How-

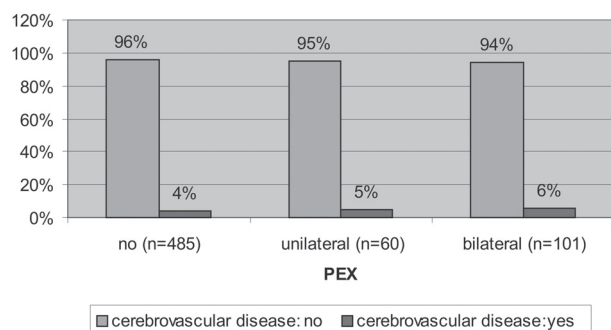


Fig. 5. Prevalence of cerebrovascular disease in patients without and with pseudoexfoliation syndrome.

ever, Shrum *et al.* found no significant association between PEX and cardiovascular or cerebrovascular mortality<sup>12</sup>. Recent studies have brought some new concepts on the complex association between PEX and internal diseases at genetic and molecular level. Eleven HLA antigens were isolated at a significantly higher rate in PEX patients than in general population, among them HLA-DR3 and HLA-B8, which are more frequent in diabetic patients<sup>13</sup>. Aqueous humor of PEX patients contained a raised level of the tissue inhibitor of matrix metalloproteinase-1 (TIMP-1) and a low level of matrix metalloproteinase-9 (TIMP-9), indicating lower degradation of extracellular matrix. The increased concentration of the connective tissue growth factor (CTGF) supports the proposed fibrotic pathology of PEX<sup>14</sup>. A higher level of plasma homocysteine was confirmed in patients with PEX than in those without PEX<sup>15-18</sup>. Hyperhomocysteinemia has been recognized as a risk factor for cardiovascular and cerebrovascular diseases, which can partly explain the higher risk of vascular incidents among PEX patients.

Our study did not prove a statistically significant difference in the prevalence of arterial hypertension, ischemic heart diseases, diabetes mellitus and cerebrovascular diseases between patients with and without PEX. The prevalence of heart arrhythmias was statistically significantly higher in patients with PEX than in those without PEX. However, the nature of this association is vague; is PEX syndrome an underlying cause of arrhythmia or PEX and arrhythmia coexist together as a consequence of the same genetically determined disorder or degenerative aging process?

Considering the results of this and other studies, the question of whether the presence of ocular PEX syndrome could be a marker in detecting individuals with

heart arrhythmias or those with internal disease remains open.

## References

- RITCH R, SCHLÖTZER-SCHREHARDT U, KONSTAS AP. Why is glaucoma associated with exfoliation syndrome? *Prog Retin Eye Res* 2003;22(Suppl 3):253-75.
- HAMMER T, SCHLÖTZER-SCHREHARDT U, NAUMANN GO. Unilateral or asymmetric pseudoexfoliation syndrome? An ultrastructural study. *Arch Ophthalmol* 2001;119(Suppl 7):1023-31.
- SCHLÖTZER-SCHREHARDT U, KOCA MR, NAUMANN GO, VOLKHOLZ H. Pseudoexfoliation syndrome: ocular manifestation of a systemic disorder? *Arch Ophthalmol* 1992;110:1752-6.
- STREETEN BW, LI ZY, WALLACE RN, EAGLE RC, KESHGEGIAN AA. Pseudoexfoliative fibrilopathy in visceral organs of a patient with pseudoexfoliation syndrome. *Arch Ophthalmol* 1992;110:1757-62.
- YANOFF M, DUKER JS. *Ophthalmology*. 2<sup>nd</sup> ed. St. Louis: Mosby Inc., 2004.
- MITCHELL P, WANG JJ, SMITH W. Association of pseudoexfoliation syndrome with increased vascular risk. *Am J Ophthalmol* 1997;124(Suppl 5):685-7.
- SOLLOSY M. Incidence of the uveal pseudoexfoliation syndrome in patients with diabetes mellitus. *Oftalmologia* 2004;48(Suppl 1):76-80.
- PSILAS KG, STEFANIOTOU MJ, ASPIOTIS MB. Pseudoexfoliation syndrome and diabetes mellitus. *Acta Ophthalmol (Copenh)* 1991;69(Suppl 5):664-6.
- SAINZ GOMEZ C, MORENO-MONTANES J, ESCUDERO BERASATEGUI JM, SADABA ECHARI LM, FERNANDEZ HORTELANO A, GARCIA LAYANA A. Prevalence and risk factors of pseudoexfoliation syndrome in institutionalized geriatric patients in Navarra. *Arch Soc Esp Ophthalmol* 2003;78(Suppl 7):383-8.
- REPO LP, SUHONEN MT, TERASVIRTA ME, KOIVISTO KJ. Colour doppler imaging of the ophthalmic artery blood flow spectra of patients who have had a transient ischaemic attack. *Ophthalmology* 1995;102:1199-205.
- RITLAND JS, EGGE K, LYDERSEN S, JUUL R, SEMB SO. Exfoliative glaucoma and primary open-angle glaucoma: associations with death causes and comorbidity. *Acta Ophthalmol Scand* 2004;82:401-4.
- SHRUM KR, HATTENHAUER MG, HODGE D. Cardiovascular and cerebrovascular mortality associated with ocular pseudoexfoliation. *Am J Ophthalmol* 2000;129:83-6.
- FITZSIMON JS, MULVIHILL A, KENNEDY S, FINCH A, COLLUM LMT, EUSTACE P. Association of HLA type with pseudoexfoliation of the lens capsule. *Br J Ophthalmol* 1996;80:402-4.
- HO SL, DOGAR GF, WANG J, CREAN J, WU QD, OLIVER N, WEITZ S, MURRAY A, CLEARY PE, O'BRIEN C. Elevated aqueous humour tissue inhibitor of matrix metalloproteinase-1 and connective tissue growth factor in pseudoexfoliation syndrome. *Br J Ophthalmol* 2005;89:169-73.
- VESSANI RM, RITCH R, LIEBMANN JM, JOFE M. Plasma homocysteine is elevated in patients with exfoliation syndrome. *Am J Ophthalmol* 2003;136(Suppl 1):41-6.
- ALTINTAS O, MARAL H, YUKSEL N, KARABAS VL, DILLIOGLUGIL MO, CAGLAR Y. Homocysteine and nitric oxide levels in plasma of patients with pseudoexfoliation syndrome, pseudoexfoliation glaucoma and primary open angle glaucoma. *Graefes Archive for Clinical & Experimental Ophthalmology* 2005;243(Suppl 7):677-83.
- PUUSTJARVI T, BLOMSTER H, KONTKANEN M, PUNNONEN K, TERASVIRTA M. Plasma and aqueous humour levels of homocysteine in exfoliation syndrome. *Graefes Archive for Clinical & Experimental Ophthalmology* 2004;242(Suppl 9):749-54.
- LEIBOVITCH I, KURTZ S, SHEMESH G, GOLDSTEIN M, SELA BA, LAZAR M, LOEWENSTEIN A. Hyperhomocysteinemia in pseudoexfoliation glaucoma. *J Glaucoma* 2003;12(Suppl 1):36-9.



## Sažetak

## OKULARNI PSEUDOEKSFOLIJATIVNI SINDROM I UNUTARNJE SISTEMSKE BOLESTI

*J. Brajković, I. Kalauz-Surać, A. Ercegović, A. Miletić-Jurić, N. Sušić i Ž. Burić*

Cilj studije bio je ispitati povezanost između okularnog pseudoeksfolijativnog sindroma i unutarnjih sistemskih bolesti arterijske hipertenzije, ishemične bolesti srca (angina pektoris i infarkt miokarda), srčanih aritmija, šećerne bolesti i cerebrovaskularnih bolesti (moždani udar i tranzitorne ishemične atake). Ova pro-spektivna studija uključila je 646 bolesnika u dobi od 50 ili više godina pregledanih u općoj oftalmološkoj ambulanti u Kninu. Oftalmološki pregled bolesnika uključio je ispitivanje vidne oštine i refrakcije, pregled na biomikroskopu, pregled očne pozadine i aplanacijsku tonometriju. Dijagnoza okularnog pseudoeksfolijativnog sindroma postavljena je na temelju prisutnosti znakovitih bjelkastih granularnih nakupina na strukturama prednjeg segmenta oka. Podaci o postojanju unutarnjih sistemskih bolesti prikupljeni su anamnestički i uvidom u internističku i neurološku medicinsku dokumentaciju. Svi prikupljeni podaci obrađeni su statistički pomoću  $\chi^2$ -testa i ANOVA. Nismo utvrdili statistički značajnu razliku u učestalosti arterijske hipertenzije ( $p=0,468$ ), ishemične bolesti srca ( $p=0,372$ ), cerebrovaskularnih bolesti ( $p=0,485$ ) i šećerne bolesti ( $p=0,492$ ) u bolesnika s pseudoeksfolijativnim sindromom u odnosu na učestalost tih bolesti u bolesnika bez pseudoeksfolijativnog sindroma. Učestalost srčanih aritmija bila je statistički značajno viša u pacijenata s pseudoeksfolijativnim sindromom u odnosu na učestalost srčanih aritmija u bolesnika bez pseudoeksfolijativnog sindroma ( $p=0,001$ ). S obzirom na rezultate ove i drugih studija ostaje otvoreno pitanje bi li okularni pseudoeksfolijativni sindrom mogao poslužiti kao biljeg u otkrivanju osoba s poremećajem srčanog ritma odnosno osoba s unutarnjim bolestima.

*Ključne riječi: okularni pseudoeksfolijativni sindrom, unutarnje bolesti*

