

HISTOPATHOLOGICAL ANALYSIS OF LIVER IN FISH (*BARBUS MERIDIONALIS PETENYI* HECKEL) IN RESERVOIR TREBENIŠTA

LIDIJA VELKOVA-JORDANOSKA & GOCE KOSTOSKI

PSI Hydrobiological Institute,
Naum Ohridski 50, 6000 Ohrid, R. Macedonia
(E-mail: lidvejo@yahoo.com)

Velkova-Jordanoska, L. & Kostoski, G.: Histopathological analysis of liver in fish (*Barbus meridionalis petenyi* Heckel) in reservoir Trebeništa. Nat. Croat., Vol. 14, No. 2., 147–153, 2005, Zagreb.

The *Barbus meridionalis petenyi* Heck. is a typical benthophagous fish, feeding on the zoobenthos and plant components and thanks to its sensitivity to the changes in surrounding medium is an ideal object for indication of the health of aquatic ecosystems. The Teleostei fish liver is susceptible to numerous, both toxic and metabolic, disturbances.

Liver pieces of 40 individuals collected from Trebeništa Reservoir in July 1999, were excised and processed for standard histopathological analysis. The obtained results revealed pathological changes in the liver tissue including parenchyme cell necrosis associated with hemorrhagia.

Key words: histopathology, liver, necrosis, hemorrhagia

Velkova-Jordanoska, L. & Kostoski, G.: Histopatološka analiza jetre riba (*Barbus meridionalis petenyi* Heckel) iz akumulacije Trebeništa. Nat. Croat., Vol. 14, No. 2., 147–153, 2005, Zagreb.

Barbus meridionalis petenyi Heck. tipična je bentofagna riba koja se hrani zoobentosom i dijelovima biljaka, a zbog svoje osjetljivosti na promjene u okolišu idealan je objekt za određivanje zdravlja vodenih ekosustava. Jetra riba koštunjača podložna je mnogobrojnim toksičnim i metaboličkim promjenama.

U srpnju 1999. prikupljeni su iz akumulacije Trebeništa uzorci jetre 40 riba koji su obrađeni standardnom histopatološkom analizom. Prikupljeni podaci otkrili su patološke promjene u tkivu jetre, uključujući nekrozu parenhimskih stanica povezanu s hemoragijom.

Ključne riječi: histopatologija, jetra, nekroza, hemoragija

INTRODUCTION

Histopathological biomarkers can be indicators of the effects on organisms of various anthropogenic pollutants and are a reflection of the overall health of the entire population in the ecosystem. The alterations in cells and tissues in vertebrate

fish are recurrently used biomarkers in many studies, but such changes occur in all vertebrates and invertebrates inhabiting aquatic basins. Histopathological biomarkers embody tissue lesions arising as a result of a previous or current exposure of the organism to one or more toxins. Well-documented lesions based on experimental data in liver, ovary, skeleton system and skin have been used as biomarkers to date (HINTON *et al.*, 1985).

Histopathological biomarkers are closely related to other biomarkers of stress since many pollutants have to undergo metabolic activation in order to be able to provoke cellular change in the affected organism. For example, the mechanism of action of several xenobiotics could initiate the formation of a specific enzyme that causes changes in metabolism, further leading to cellular intoxication and death, at a cellular level, whereas this manifests as necrosis, i. e. histopathological biomarker on a tissue level. As well as from chemical insult, histopathological lesions may arise from infectious diseases and parasites, provoking necrotic and degenerative alterations to which the organism responds with an inflammatory, defensive reaction (VELKOVA-JORDANOSKA, 2002; ROGANOVIC-ZAFIROVA *et al.*, 2003). An increased number of macrophagic aggregates can be found in the liver, kidney and spleen in fish exposed to chemical pollutants, bacteria, fungi or parasites (ROGANOVIC-ZAFIROVA & JORDANOVA, 1998).

The liver plays a key role in the metabolism and biochemical transformations of pollutants from the environment, which inevitably reflects on its integrity by creating lesions and other histopathological alterations of the liver parenchyma or the bile duct (ROBERTS, 1978).

Trebeništa is a small natural reservoir of the Livoiska River, part of the watershed of Lake Ohrid, with very small dimensions: length of 200 m, width 80 m and depth from 2 to 6 m (Fig. 1).

Lake Ohrid and its watershed have been under strong anthropogenic influence from the use of various fertilizers, herbicides and insecticides leading to gradual but crucial modifications not only of the coastline but also of the lake as a whole (CHADO, 1974). Another type of anthropogenic impact is manifested by pollution of the tributaries where there is an inflow of wastewater from household and industrial facilities. Fecal pollution, detergents and other chemical waste material, and fine alluvium from the Sateska River are undesirable in Lake Ohrid archaic lacustrine ecosystem (OCEVSKI *et al.*, 1977).

The ecological effects of pollutants in aquatic ecosystems and their bioavailability and toxicity are closely related to species distribution, both in the solid and the liquid phase of the aquatic ecosystem. Pollutants are transferred to the plankton, aquatic plants, mollusks and fish. A wide range of microscopic and macroscopic animals and plants live in and on bottom sediments of the aquatic ecosystems, and a great number of these organisms ingest organic matter from these sediments (MOSISCH & ARTHINGTON, 2000).

Young fish and larvae of *Barbus meridionalis petenyi* Heck. in Lake Ohrid hide in places close to the bottom and at a depth of about 10 cm. Chironomid larvae are found in their gut content, then copepods and harpacticids, as well as chlorophytes,

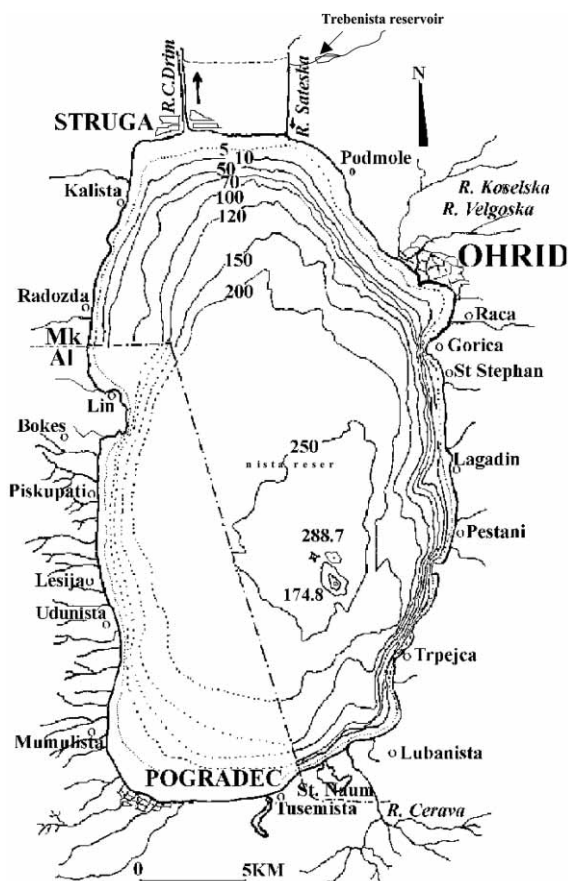


Fig. 1. Investigated locality – Trebeništa Reservoir.

many diatoms and cyanophytes of the plant species. According to this, their nutrition is of a mixed character, with numerous animal elements (TOCKO, 1987). The *Barbus* species is a typical benthophagous fish feeding on the zoobenthos and plant components in the course of the autumn. Every natural community of the bottom, mainly the larvae, is included in the *Barbus* nutrition (MORAVEC, 1997).

MATERIALS AND METHODS

In this study livers of 40 individuals of barbel (*Barbus meridionalis petenyi* Heck.) were examined. Fishes were collected during July 1999 from Trebeništa Reservoir. Each fish was dissected according to the following protocol: measurement of the fish length, dissection by opening the abdominal cavity, determination of the sex, dissection of the digestive tract and taking the liver in the end. Tissue specimens

with diameter of 3–5 mm were fixed in 10% formalin and processed according to a standard paraffin procedure. The 5 µm paraffin sections were stained with the Hemalaun & Eosin method and approximately 2–4 sections of each individual fish were analyzed by light microscope. The prevalence of registered histopathological changes was calculated as the percent of affected fishes.

Materials for zooplankton investigations were collected in July 1999, fixed in 4% formalin and counted under microscope.

The aim of these investigations was to perform a histological analysis of liver tissue in barbel in Trebeništa Reservoir, to represent a reliable indicator of the ecological condition of the aquatic ecosystem and the possible negative impact of the surrounding environment.

RESULTS AND DISCUSSION

Zooplankton investigations were scheduled in Trebeništa Reservoir, zooplankton constituting important components for monitoring water quality and the changes that occur in it. The following species were registered in the investigation period:

Phylum ROTIFERA

Polyarthra vulgaris

Trichocerca (D) *tigris*

Phylum, Subphylum CRUSTACEA

Class Branchiopoda

Order Cladocera

Daphnia sp.

Leidigia leidigi

Bosmina longirostris

Macrotrix laticornis

Chidorus sphaericus

Subclass Copepoda

Order Cyclopoida

Cyclops vicinus

Mesocyclops leuckarti

Investigations of the qualitative composition of zooplankton have revealed the sparse presence of the species in Trebeništa Reservoir, probably pointing to certain negative processes (SERAFIMOVA-HADZISCHE, 1957, 1975; KOSTOSKI, 1998).

The direct acute effect of exposure to insecticide is a rapid decrease in many species of zooplankton. The alteration in crustacean species composition was probably due to variation in susceptibility to the direct toxic effect of insecticide (WENDT-RASCH *et al.*, 2003). These results provided knowledge about the direct and indirect effect of pesticide stress on the ecosystem level. They also showed that there was a

variation in sensitivity between different species of zooplankton under natural conditions and thus exemplify the necessity of multispecies approaches in the risk assessment of pesticides (FRIBERG-JENSEN *et al.*, 2003).

In arid periods with a small quantity of rainwater and high evaporation in the summer months due to high temperatures, a rapid reduction of the water quantity in Trebenista Reservoir occurs. In some cases fish pestilence was evidenced, probably as a result of the increased water temperature, intensified eutrophication processes and hypoxic conditions in the aquatic environment. There were no dead individuals in the samples caught in this reservoir, which indicates their health was good in morphological terms. Nevertheless, the microscopic analysis of the histological preparations indicated presence of hemorrhaging in the hepatocellular parenchyma (Fig. 2a); moreover the pigment hemosiderin was evidenced, probably as a result of internal bleeding in the hepatic tissue of barbel (Fig. 2b). Apart from these changes, there was also the presence of parasites, most probably of the class Nematodes (Fig. 2c). Approximately 22.5 % of all barbels collected at Trebeništa Reservoir showed evidence of hemorrhagia, and 17.5 % showed the presence of the pigment hemosiderin in liver tissue. Prevalence of parasite infestation was only 10 %. Hemosiderin in the liver is not surprising as it represents a product of hemoglo-

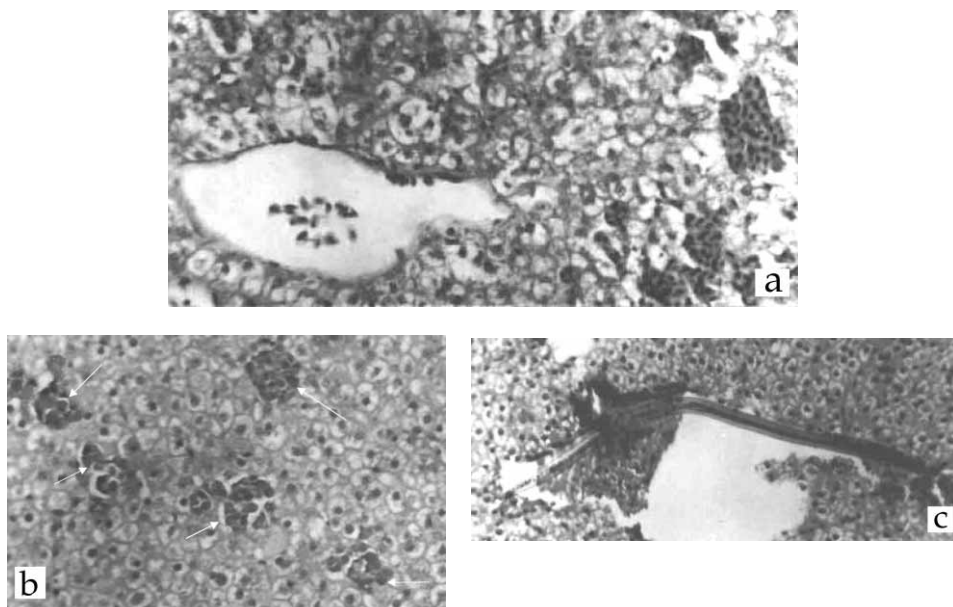


Fig. 2. Liver lesions in barbel (*Barbus meridionalis petenyi* Heck.) from Trebeništa Reservoir (H&E, $\times 100$). **a.** hemorrhagia in the liver tissue associated with parenchyma cell necrosis; **b.** the pigment hemosiderin in hepatocellular parenchyma (arrows); **c.** presence of parasite in hepatocellular parenchyma (probably Nematode).

bin degradation that has been filtered out by the lymphoid-macrophage system (KHAN *et al.*, 1994).

Recent evidence indicates that increases in oxidative stress and associated biochemical alterations could be a toxic mechanism in fish exposed to pulp mill effluent (OAKES & VAN DER KRAAK, 2003). Also, high amounts of ions (especially nitrogen and potassium) in mining wastewater have drastically changed the water chemistry in lakes, and affected species composition, the food chain structure and fish health. Despite high fish population densities, histology of liver and gills indicates unfavorable environmental conditions for individual fish in lakes receiving mining effluents (TKATCHEVA *et al.*, 2002).

All these findings imply that certain negative processes are taking place in Trebeništa Reservoir, not only for the fish population, but also most probably for the other vertebrate and invertebrate forms inhabiting it. These negative impacts especially accelerate in the droughty periods of arid and hot summers, when fish pestilence has been evidenced in the reservoir. Certain localities of Ohrid Lake and its watershed display loading with contaminants from the ground, especially in the course of the summer period (MITIC *et al.*, 2002). This implies the need for greater seriousness in terms of protection of the Lake and its watershed, and more efforts towards eliminating the constant sources of pollution.

Received April 23, 2004

REFERENCES

- CHADO, I., 1974: The antropogeny factor and some changes on Lake Ohrid. Simp. on the problems of the regulation of Lake Ohrid (October 20–23, 1971), pp. 357–362, MASA, Skopje, R. Macedonia (in Macedonian).
- FRIBERG-JENSEN, U., WENDT-RASCH, L., WOIN, P. & CHRISTOFFERSEN, K., 2003: Effects of the pyrethroid insecticide, cypermethrin, on a freshwater community studied under field conditions. I. Direct and indirect effects on abundance measures of organisms at different trophic levels. *Aquatic Toxicology*, **63**(4), 357–371.
- HINTON, D. E., BAUMAN, P. C., GARDNER, G. R., HAWKINS, W. E., HENDRICKS, J. D., MURCHELANO, R. A. & OIKIHIRO, M. S., 1985: Histopathological biomarkers. In: RAND, G. M. & PETROCELLI, S. R. (Eds.): *Fundamentals of aquatic toxicology. Methods and applications*, pp. 155–209. Hemisphere publishing corporation. Washington, New York.
- KHAN, R. A., BARKER, D. E., HOOPER, R., LEE, E. M., RYAN, K. & NAG, K., 1994: Histopathology in Winter Flounder (*Pleuronectes americanus*) living adjacent to a pulp and paper mill. *Arch. Environ. Contam. Toxicol.* **26**, 95–102.
- KOSTOSKI, G., 1998: A day-night and seasonal periodicity in the distribution of the zooplankton from Lake Ohrid. D. Sc. Thesis, Univ. St. Cyril and Methodius, Skopje, R. Macedonia (in Macedonian).
- MITIC, V., KOSTOSKI, G., GUSESKA, D. & PATCEVA, S., 2002: Lake Ohrid plankton. *Limnological investigations of Lake Ohrid*. Hydrobiological Institute, Vol. **1** & **2**, pp. 42–83.
- MORAVEC, F., 1997: Endohelminth fauna of barbel, *Barbus barbus* (L.), under ecological condition of the Danube basin in Central Europe. *Academia. Praha*.

- MOSISCH, T. D. & ARTHINGTON, A. H., 2001: Polycyclic aromatic hydrocarbon residues in the sediment of a dune lake as a result of power boating. *Lakes & Reservoirs: Research and Management* 2001, **6**, 21–32.
- OAKES, K. D. & VAN DER KRAAK, G. J., 2003: Utility of the TBARS assay in detecting oxidative stress in white sucker (*Catostomus commersoni*) populations exposed to pulp mill effluent. *Aquatic Toxicology*, **63**(4), 447–463.
- OCEVSKI, B., TOCKO, M. & SAPKAREV, J., 1977: Lake Ohrid and Anthropological factor. *Ecologija* **12**(1), 79–88.
- ROBERTS, R. J., 1978: The anatomy and physiology of teleosts. In: ROBERTS, R. J. (Ed.): *Fish pathology*, pp. 13–103. Bailliere Tindall, London.
- ROGANOVIC-ZAFIROVA, D. & JORDANOVA, M., 1998: Histopathological analysis of liver from Ohrid roach (*Rutilus rubilio ohridanus*) collected in Grasnica, a contaminated site of Lake Ohrid. *Special Issues of Macedonian Ecological Society*, 5(1–2), 530–544.
- ROGANOVIC-ZAFIROVA, D., JORDANOVA, M., PANOV, S. & VELKOVA-JORDANOSKA, L. 2003: Hepatic capillariasis in the Mediterranean barbell (*Barbus meridionalis petenyi* Heck.) from Lake Ohrid. *Folia Veterinaria*, **47**(1), 35–37.
- SERAFIMOVA-HADZISCHE, J., 1957: Le zooplancton du Lac D'Ohrid. *Edition speciales, Station Hydrobiologique, Ohrid*, Vol. **1**, 4–64.
- SERAFIMOVA-HADZISCHE, J., 1975: Seasonal variations of the reproductive rate of pelagic copepods of Lake Ohrid. *Verh. Inter.Ver. Limnol.*, **19**, 2546–2550.
- TOCKO, M., 1987: Development and nutrition of the young cyprinids of Lake Ohrid. *Special Editio Hydrobiological Institute, Ohrid*.
- TKATCHEVA, V., HOLOPAINEN, I. J. & HYVARIENEN, H., 2002: Effects of mining wastewaters on fish in lakes of NW Russia. *Verh. Internat. Verein. Limnol.*, **28**, 484–487.
- VELKOVA-JORDANOSKA, L., 2002: Histopatological and molecular-diagnostical study of the hepatic capillary in black barbel (*Barbus meridionalis petenyi* Heck.) in Lake Ohrid. MSc Thesis, Univ. St. Cyril and Methodius, Skopje, R. Macedonia (in Macedonian).
- WENDT-RASCH, L., FRIBERG-JENSEN, U., WOIN, P. & CHRISTOFFERSEN, K., 2003: Effects of the pyrethroid insecticide cypermethrin on a freshwater community studied under field conditions. II. Direct and indirect effects on the species composition. *Aquatic Toxicology*, **63**(4), 373–389.