

Therapeutic Efficacy of 5% NaCl Hypertonic Solution in Patients with Bullous Keratopathy

Igor Knezović¹, Iva Dekaris¹, Nikica Gabrić², Jasenka Cerovski¹, Ante Barišić¹, Damir Bosnar¹, Petar Raštegovac¹ and Anđelko Parać¹

¹ University Department of Ophthalmology, General Hospital »Sveti Duh«, Zagreb, Croatia

² Eye Clinic »Svjetlost«, Zagreb, Croatia

ABSTRACT

A clinical trial was undertaken to evaluate the efficacy of hypertonic solution (5% NaCl) in patients who have bullous keratopathy (BK). The aim of the study was to define the stage of the disease and the thickness of cornea in micrometers, which would be the threshold for therapeutic approach. This was a prospective study on 70 eyes of 55 patients. Patients were divided in two groups at the beginning of the study. The first group (n=33 eyes) included patients with initial stage of BK: only stromal component of corneal oedema was present. The second group (n=37 eyes) included patients with advanced stage of BK: the epithelial component of the disease with bullae on the corneal surface had already developed. Visual acuity, central and peripheral thickness of cornea and morphology of the disease was recorded before therapy, 7 days and 4 weeks after administration of hypertonic solution. Our results shown that the efficacy of hypertonic solution correlates with the severity of clinical picture in patients with BK. When 5% NaCl hypertonic solution was applied in the early stage of the disease, when only stromal component of corneal oedema was presented, visual acuity and pachymetry readings were significantly improved. The threshold pachymetry measurement of corneal thickness justifying the application of hypertonic solution was 613–694 μm (in the central corneal area), and 633–728 μm (at corneal periphery). It seems reasonable to apply hypertonic solution to the patients who have BK and whose pachymetric values are below mentioned range. In terminal stages of BK, when superficial bullae (epithelial component) had already developed, treatment with NaCl was not effective and patients had to be submitted to penetrating keratoplasty.

Key words: hypertonic solution, 5% NaCl, bullous keratopathy

Introduction

Opacification of the cornea which occurs in bullous keratopathy (BK) is often untreatable by conservative treatment and can only be treated by corneal transplantation^{1,2}. Transparency of the cornea mostly depends on the endothelial cells function, namely on their number per mm^2 and regularity of their shape and size. If the majority of endothelial cell layer is impaired due to inflammation, trauma, degenerative diseases, toxin or surgical procedure, residual cells are not able to prevent the entrance of aqueous humor in corneal stromal layer^{3,4}. As a result, a hyper-hydration of the cornea with consequent stromal edema and epithelial bullae develops. The loss of endothelial cells can also be genetically determined as in case of Fuch's endothelial dystrophy⁵⁻⁷. Loss of visual acuity due to decreased corneal transparency is one of the symptoms of BK. It is typical for patients with BK to have lower visual acuity in the morning than in

the evening, because the corneal hydration is increased during the night when eyelids are closed.

It is easy to assess increased corneal thickness, stromal edema and epithelial bullae by slit-lamp examination. The endothelial cell layer can be examined by specular microscope.

There are not many options for treatment of BK. Hyperosmolar solutions^{8,9} were reported as potentially beneficial in symptomatic treatment. The most commonly used topical treatments are hypertonic solutions of NaCl, and the most frequent of them are: Adsorbonac, SalineX, Ak-NaCl, Hyperton-5 and Muro-128. Recommended dose is 1–2 drops 4–6 times per day but the optimal dose is not yet established, especially with children.

Other therapeutic approaches that can be of benefit for patients with BK are antiglaucoma drops, application

of honey¹⁰ and therapeutic lens¹¹, transplantation of the amniotic membrane^{12,13} and finally corneal transplantation^{1,2}.

The aim of the study was to evaluate the efficacy of topical 5% NaCl in eyes with different stages of BK. We also aimed to determine the thickness of cornea which will be a threshold value for beneficial effect of mentioned treatment.

Patients and Methods

We performed a prospective study on 55 ambulatory patients (70 eyes) suffering from BK. The patients were divided in two groups. The first group included eyes with only stromal component of corneal oedema, without epithelial bullae. All patients underwent standard ophthalmological evaluation: check of visual acuity by Snellen's chart, slit-lamp examination, aplanation tonometry, examination of fundus, and ultrasound examination (B-scan). Pachymetry of central and peripheral cornea was performed with ultrasound pachymeter (Alcon, USA).

Patients in the second group had epithelial component of corneal oedema and significant bullae on their corneal surface. All patients underwent same ophthalmic evaluation as those in the first group, only difference was a decreased visualization of fundus due to advanced stage of disease and decreased transparency of optical media. Both groups were followed up for 4 weeks and were compared according to following parameters: visual acuity, central and peripheral corneal thickness, and morphological changes on day 7 and 4 weeks after the application of hypertonic NaCl. The obtained results were compared with the condition before treatment. Central and peripheral pachymetry were defined as mean value of four consecutive measurements: a.) for central pachymetry in central 5 mm² of cornea and b.) for peripheral pachymetry in four corneal quadrants (12, 3, 6 and 9 clock hours) at 1 millimeter distance from limbus.

Study drug was 5% solution of NaCl. It was prepared in aseptic conditions in our hospital pharmacy, only for the purpose of this study. Hypertonic NaCl was administered to both groups of patients: 2 drops were given 4 times a day in conjunctival sac.

The obtained results were statistically evaluated by ANOVA (analysis of variance) regarding to time as a factor inside of each group, followed by paired student t-test.

Results

In the first group of patients (24 patients with initial stage of the disease, 14 women and 10 men, n=33 eyes, age between 65 and 83 years, mean value of intraocular pressure 15,5±3 mm Hg) a statistically significant improvement (p<0.05) of visual acuity (V.A.=0.39±0.063) occurred one week after topical NaCl in comparison to the values before the treatment (V.A.=0.25±0.063, Figure 1). The example of clinical improvement of one patient is represented by Figure 2, Figure 3, and Figure 4. No further

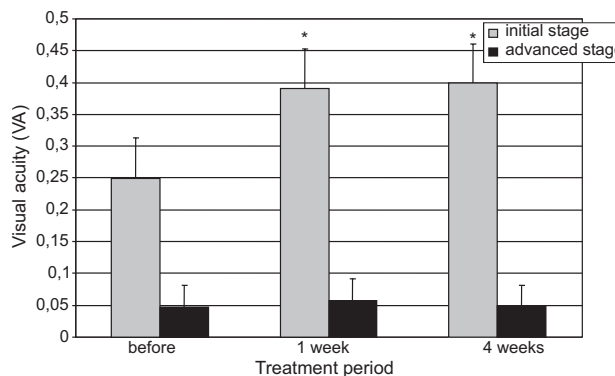


Fig. 1. Changes in visual acuity in patients with bullous keratopathy treated with 5% NaCl hypertonic solution during 4 weeks. A significant improvement of visual acuity (*p<0.05 in comparison with the value before treatment) was recorded in patients with initial stage of the disease (grey bars). No significant change in visual acuity was recorded in patients with advanced stage of bullous keratopathy (black bars).

improvement was recorded during following three weeks of NaCl application (V.A.=0.4±0.06, Figure 1). Central pachymetry values significantly decreased after the first week of hypertonic solution application (582±22 μm) in comparison with the baseline value (613±33 μm, p<0.05),

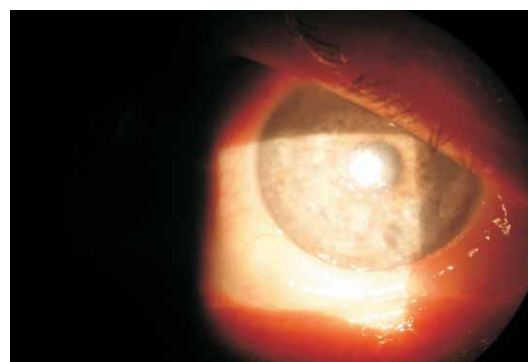


Fig. 2. Patient with bullous keratopathy before topical treatment with 5% NaCl hypertonic solution.

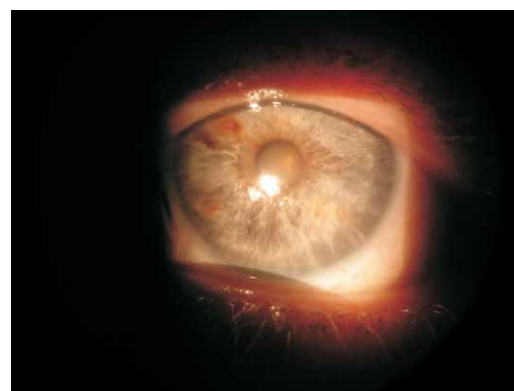


Fig. 3. Patient with bullous keratopathy 7 days after topical treatment with 5% NaCl hypertonic solution.

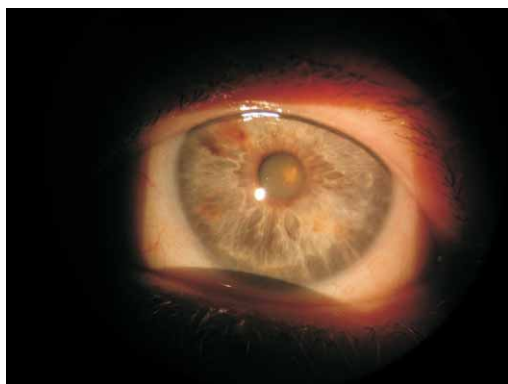


Fig. 4. Patient with bullous keratopathy four weeks after topical treatment with 5% NaCl hypertonic solution.

and remained the same during the next three weeks of treatment (Figure 5). Normal range of central corneal thickness is $548 \pm 21.2 \mu\text{m}^{14}$. Namely, after the first week of NaCl application, no further decrease of central corneal thickness was recorded ($578 \pm 27 \mu\text{m}$ at 4 weeks). Peripheral pachymetry values also decreased 1 ($602 \pm 26 \mu\text{m}$, $p < 0.05$) and 4 ($579 \pm 26 \mu\text{m}$, $p < 0.05$) weeks after the application of hypertonic solution in comparison with the baseline value ($633 \pm 54 \mu\text{m}$, Figure 6). Four weeks after application of hypertonic solution, no statistically significant change in corneal thickness was presented, in comparison with the values after 1 week.

In the second group of patients with the advanced stage of BK (31 patients, 14 women and 17 men, $n=37$ eyes, age between 63 and 86 years), there was no statistically significant change of visual acuity either one (V.A. = 0.057 ± 0.035 , $p > 0.05$) or four weeks (V.A. = 0.05 ± 0.032 , $p > 0.05$) after local application of 5% NaCl in comparison with the baseline value (V.A. = 0.047 ± 0.034 , Figure 1). Peripheral pachymetry was also unchanged after one ($716 \pm 83 \mu\text{m}$, $p > 0.05$) and four weeks ($714 \pm 95 \mu\text{m}$, $p > 0.05$) of treatment in comparison with the baseline value ($728 \pm 76 \mu\text{m}$, Figure 6).

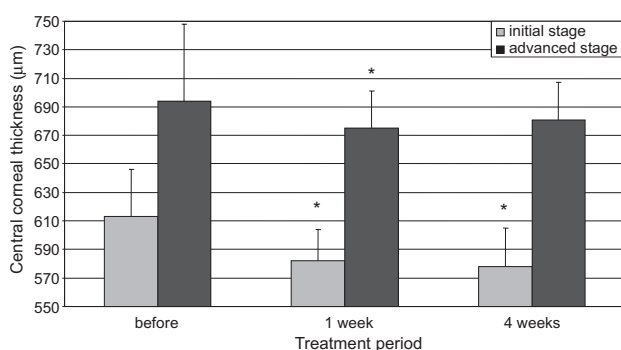


Fig. 5. Changes in central corneal pachymetry in patients with bullous keratopathy during four weeks of treatment with 5% NaCl hypertonic solution. A significant decrease in pachymetry value ($*p < 0.05$ in comparison with the value before treatment) was recorded in patients with initial stage of bullous keratopathy (grey bars) and in patients with advanced stage of bullous keratopathy (black bars).

However, there was a statistically significant decrease of central pachymetric values 1 week ($675 \pm 93 \mu\text{m}$, $p < 0.05$) after local application of 5% NaCl in comparison with the baseline value ($694 \pm 84 \mu\text{m}$). Four weeks after application of 5% NaCl central pachymetry values were unchanged ($681 \pm 99 \mu\text{m}$, $p > 0.05$) in comparison with both, baseline and values after 1 week (Figure 5).

Discussion

Takahashi and Leibowitz were the first who reported on visual improvement after the administration of hypertonic solution on patients with bullous keratopathy⁸. Assumed mechanism of 5% NaCl action was the evacuation of corneal edema due to hypertonic properties of this solution. However, it is still unclear at which stage of the disease patients with BK may benefit from hypertonic solution, and does the efficacy of 5% NaCl depend on the baseline corneal thickness. It would be of clinical importance to define maximal corneal pachymetric values at which administration of hypertonic solution can have therapeutic effect. The respective value could be the distinguishing threshold between indication for conservative treatment (hypertonic solution) or surgical approach - corneal transplantation.

It is well known from the literature that the application of the therapeutic lens without concomitant therapy (hypertonic solution) can not improve corneal edema¹¹. Surgical procedures, e.g. transplantation of the amniotic membrane (TAM), have shown beneficial effect regarding decrease of pain and discomfort in patients with bullous keratopathy. However, there is no precise data about influence of TAM on visual acuity and pachymetric values, and there are no studies comparing efficacy of TAM versus hypertonic solution^{12,13}.

It is important to emphasize that the treatment with hypertonic solution is only symptomatic and requires continuity since it does not influence the etiology of disease.

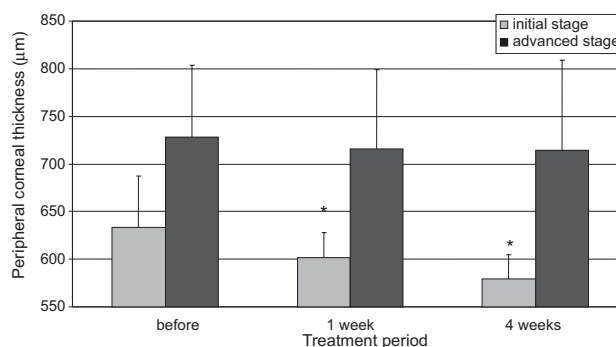


Fig. 6. Changes in peripheral corneal pachymetry in patients with bullous keratopathy during four weeks of treatment with 5% NaCl hypertonic solution. A significant decrease in pachymetry value ($*p < 0.05$ in comparison with the value before treatment) was recorded in patients with initial stage of bullous keratopathy (grey bars). No significant change in peripheral corneal pachymetry was recorded in patients with advanced stage of bullous keratopathy (black bars).

Therefore, accurate estimation (by pachymetry) which patient can benefit from NaCl treatment could be beneficial.

In our study we have shown that NaCl may indeed be beneficial for patients with BK, but only in a selected group of such patients. Namely, in the early stage of BK the administration of hypertonic solution led to significant improvement of visual acuity. Rationale for this improvement lays in significant dehydration of the corneal tissue, since both central and peripheral pachymetric values were significantly lower after the treatment. In the terminal stage of the disease, with developed stromal and epithelial component of corneal edema, local administration of hypertonic solution did not show any significant change in the progress of the disease. There was no statistical difference in visual acuity or peripheral pachymetry both, 1 and 4 weeks after local administration of 5% NaCl. However, there was a slight and transitory decrease in central pachymetric values 7 days after treat-

ment in comparison with the baseline value that remained stable up to 4 weeks.

Our results implicate that it is possible to predict the efficacy of NaCl treatment according to values of central and peripheral corneal pachymetry. It is reasonable to conclude that hypertonic solution of 5% NaCl may be beneficial for the patients with BK having central pachymetry values of 613–694 μm and peripheral pachymetry values between 633–728 μm .

These respective values are the range of threshold of corneal thickness, and in the advanced stage of BK, when both stromal and epithelial components of the disease have already developed, the pachymetric values will be above mentioned range and, therefore, hypertonic solution has no therapeutic effect. For these patients, corneal transplantation remains the only valuable treatment to improve their visual acuity and resolve painful symptoms of BK.

REFERENCES

1. LINDQUIST, T. D., J. S. MCGLOTHAN, W. M. ROTKIS, J. W. CHANDLER, Cornea, 10 (1991) 210. — 2. PRICE, F. W. JR., W. E. WHITSON, R. G. MARKS, Ophthalmology, 98 (1991) 322. — 3. OHGURO, N., M. MATSUDA, S. KINOSHITA, Am. J. Ophthalmol., 112 (1991) 424. — 4. OBATA, H., K. ISHIDA, M. MURAO, K. MIYATA, M. SAWA, Jpn. J. Ophthalmol., 35 (1991) 411. — 5. KANSKI, J. J.: Clinical Ophthalmology. (Butterworth-Heinemann, Oxford, 1999). — 6. BROOKS, A. M., G. GRANT, W. E. GILLIES, Aust. N. Z. J. Ophthalmol., 16 (1988) 93. — 7. BRAMSEN, T., N. EHLERS, Acta Ophthalmol. (Copenh.), 55 (1977) 665. — 8. TAKAHASHI, G. H., H. M. LEIBOWITZ, Arch. Ophthalmol., 86 (1971) 133. —
9. MARISI, A., J. V. AQUAVELLA, Ann. Ophthalmol., 7 (1975) 229. — 10. MANSOUR, A. M., W. ZEIN, R. HADDAD, J. KHOURY, Acta Ophthalmol. Scand., 82 (2004) 312. — 11. HODVING, G., Acta Ophthalmol. (Copenh.), 62 (1984) 566. — 12. SIENNICKA, A., H. PECOLD-STEPNJEWSKA, M. CZAJKA, Klin. Oczna., 105 (2003) 41. — 13. GABRIĆ, N., I. MRAVIČIĆ, I. DEKARIS, Z. KARAMAN, S. MITROVIC, Doc. Ophthalmology, 98 (1999) 273. — 14. WHITSON, J. T., C. LIANG, D. G. GODFREY, W. M. PETROLL, H. D. CAVANAGH, D. PATEL, R. L. FELLMAN, R. J. STARITA, Eye Contact Lens, 31 (2005) 221.

I. Knezović

University Department of Ophthalmology, General Hospital »Sveti Duh«, Sveti Duh 64, 10000 Zagreb, Croatia
e-mail: i_knezovic@yahoo.com

DJELOVANJE HIPERTONIČNE OTOPINE 5% NaCl NA EDEM ROŽNICE KOD BOLESNIKA S BULOZKOM KERATOPATIJOM

SAŽETAK

U bolesnika s buloznom keratopatijom učinjena je klinička studija radi evaluacije djelotvornosti hipertonične otopine 5% NaCl. Cilj studije bio je definirati stadij bolesti i debljinu rožnice (mm) koja bi trebala biti „prag“ za odluku o primjeni konzervativnog ili operativnog terapijskog pristupa. Ova prospektivna studija obuhvatila je 70 očiju u 55 bolesnika s različitim stadijem bulozne keratopatije. Bolesnici s buloznom keratopatijom podijeljeni su u dvije skupine. U prvoj skupini bili su bolesnici koji su imali razvijenu samo stromalnu komponentu rožničnog edema (inicijalni stadij) (n=33, 24 bolesnika), dok je druga skupina obuhvatila bolesnike (n=37, 31 bolesnik) s razvijenom epitelnom komponentom rožničnog edema i s vidljivim bulama po površini rožnice (uznapredovali stadij). Mjerenja vidne oštrine, debljine rožnice centralno i periferno (pahimetrija) te evaluacija morfoloških promjena, rađeni su prije početka terapije, 7 dana nakon početka terapije hipertoničnom otopinom 5% NaCl, te tijekom slijedeća 3 tjedna. Rezultati istraživanja pokazali su da je stupanj učinkovitosti djelovanja hipertonične otopine 5% NaCl na rožnični edem u korelaciji sa stadijem bolesti. Ukoliko se hipertonična otopina 5% NaCl primijeni u inicijalnom stadiju bulozne keratopatije, gore navedena terapija ima zadovoljavajući učinak. Vidljivo je da prag koji opravdava učinkovitu primjenu hipertonične otopine 5% NaCl, pri centralnoj pahimetriji ima raspon od 613 μm do 694 μm , a periferno od 633 μm do 728 μm . Zaključak je da dotični parametri predstavljaju raspon praga u pahimetrijskim vrijednostima ispod kojih ima smisla bolesnika podvrgnuti terapiji hipertoničnom otopinom 5% NaCl. Ako se radi o uznapredovalom stadiju bulozne keratopatije, za potpuno izlječenje bolesnika potrebno je napraviti transplantaciju rožnice.