

**Longitudinal changes in subcortical morphology in Huntington Disease and the  
relationship with clinical, motor and neurocognitive outcomes**

**Fiona Anne Wilkes**

**December 2020**

A thesis submitted for the degree of Doctor of Philosophy of

The Australian National University

ANU Medical School

College of Health and Medicine

The Australian National University

© Copyright Fiona Anne Wilkes 2020

All Rights Reserved

## **Candidate statement**

I certify that, to the best of my knowledge, the content of this thesis is my own work, unless otherwise specified, and that this thesis complies with The Australian National University Research Award Rules and has not been previously accepted for award of a degree or diploma to any other institution of higher learning. The research presented in this thesis was supported by an ANU University Research Scholarship.

**Word count: 42, 474**

**Signed:**

A handwritten signature in black ink, consisting of a series of connected, fluid strokes that are difficult to decipher as specific letters.

**Date:** 13/05/2021

## **Acknowledgements**

Dedicated with thanks to my primary supervisor Jeffrey Looi, whose unwavering support and encouragement meant that I continued even when I didn't think I could, who indulged my many sidesteps along the way, and who led me by example rather than coercion into a field I didn't think possible.

Thank you also to my co-supervisors Professors Mark Walterfang, Dennis Velakoulis and Nellie Georgiou-Karistianis, who have been unfailingly kind, generous and patient. Further thanks are due to my numerous co-authors and collaborators, listed in full in the various chapters and papers, but in particular to David Jakabek, Conor Owens-Walton and Lauren Turner.

To my entire extended network of friends and family and colleagues (clinical and research), who have given so much time and love and support.

To Justin, who loved.

To my grandfather, who died more than a decade ago but in whose name I started research into neurodegenerative disease and in whose life I take inspiration for kindness, intelligence and dignity.

Finally, thank you to the people living with Huntington disease who so generously gave their time to be involved in the IMAGE-HD study.

## **Funding**

The IMAGE-HD study was supported by the CHDI Foundation, Inc. (USA) (grant number A – 3433) and the National Health and Medical Research Council (NHMRC) (grant number 606650).

This thesis was supported by an ANU PhD scholarship, the RANZCP New Investigator Grant 2013, as well as the University of Melbourne for computer and software support.

## **Abstract**

Huntington disease (HD) is a devastating inherited neurodegenerative disease which causes progressive motor, psychiatric and cognitive disturbances as well as neurodegeneration.

Mapping the spatiotemporal progression of neuroanatomical change in HD is fundamental to developing biomeasures suitable for prognostication and to aid in development and testing of potential treatments. The neostriatum is central to HD and is known to start to degenerate more than a decade before observable motor onset. It is central to a number of frontostriatal re-entrant circuits which regulate motor control and other forms of behaviour. Changes in striatal morphology can consequently be correlated with observable clinical, motor and cognitive outcomes. However, the neostriatum is merely one part of the “hubs and spokes” of neural circuitry and neurodegeneration in HD also occurs in other areas of the brain. The hippocampus has been less fully studied in HD and has implications for neural plasticity, particularly given neurogenesis continues into adulthood in this region. Furthermore, thickness of the corpus callosum may be used as a proxy for cortical changes that are known to occur later in HD.

This thesis uses data from the IMAGE-HD study to characterise neuroanatomical changes in HD, with the aim to improve knowledge of HD-associated neurodegenerative pathways and to provide further insight to relate quantitative measures of morphology to function. A number of analytical techniques are used to investigate changes in size and shape of neuroanatomical structures and to correlate these with clinical, motor and neurocognitive outcomes.

This thesis demonstrates that shape changes in the neostriatum in HD and pre-symptomatic HD correlate with functional measures subserved by corticostriatal circuits, and identifies significant longitudinal differences in putaminal and caudate shape. Only the putamen has a significant group by time interaction, suggesting that it is a better marker for longitudinal change in pre-symptomatic HD and HD. While HD has its most marked effects on the neostriatum, it also has more subtle effects on other subcortical areas. This thesis shows surface contraction occurring in HD in the hippocampus compared to controls, although without correlations to functional measures or significant longitudinal change. Unlike these “hubs”, this thesis finds that the large “spoke” of the corpus callosum is not impacted early in the HD process but becomes affected after symptom onset, highlighting the spread of neurodegeneration in other structures.

This is the first time that such robust statistical analysis of longitudinal shape change in HD has been able to be performed and shows the neostriatum, particularly the putamen, as a potentially useful structural basis for the characterisation of an endophenotype of HD. This thesis provides a more comprehensive picture of neuroanatomical change in HD by using a “hubs and spokes” approach to analyse key areas, increasing knowledge about neurodegenerative pathways and functional outcomes.

## Table of Contents

<b>Candidate statement</b>	<b>2</b>
<b>Acknowledgements</b>	<b>3</b>
<b>Funding</b>	<b>4</b>
<b>Abstract</b>	<b>5</b>
<b>List of Manuscripts</b>	<b>11</b>
<b>List of Figures</b>	<b>12</b>
<b>List of Tables</b>	<b>14</b>
<b>List of Abbreviations</b>	<b>14</b>
<b>1. Introduction</b>	<b>17</b>
<i>1.1 Overview</i>	17
<i>1.2 Background/context</i>	18
<i>1.2.1 Huntington disease epidemiology and course</i>	18
<i>1.2.2 Pathogenesis of HD</i>	21
<i>1.2.3 Overview of neuroanatomical changes in HD</i>	24
<i>1.3 The subcortical connectome: role of the striatum and other subcortical areas involved in HD</i>	27
<i>1.3.1 The neostriatum</i>	27
<i>1.3.2 The hippocampus</i>	32
<i>1.3.3 Neurogenesis potential near striatum and hippocampus</i>	36
<i>1.3.4 Hippocampal/striatal circuits</i>	38
<i>1.3.5 The corpus callosum</i>	39
<i>1.4 The IMAGE-HD study</i>	41
<i>1.5 Rationale for thesis</i>	43
<i>1.6 Scope of thesis</i>	45
<i>1.6.1 Study One: Baseline analysis of the neostriatum in Huntington disease, pre-HD, and the relationship between striatal morphology and motor and neurocognitive outcomes</i>	46
<i>1.6.2 Study Two: Longitudinal analysis of shape change in the neostriatum in Huntington disease.</i>	47
<i>1.6.3 Study Three: Baseline analysis of the hippocampus in Huntington disease and relationship to antidepressant use, implications for neurogenesis.</i>	47
<i>1.6.4 Study Four: Analysis of the corpus callosum in Huntington disease as a proxy measure for cortical changes.</i>	48

<b>2. Methods</b>	<b>49</b>
2.1 <i>The IMAGE-HD Study</i>	49
2.1.1 <i>Subjects</i>	49
2.1.2 <i>Imaging</i>	51
2.1.3 <i>Motor, neurocognitive and neuropsychiatric assessments</i>	51
2.1.4 <i>Candidate's involvement in IMAGE-HD study</i>	52
2.2 <i>Structural neuroimaging: manual tracing</i>	52
2.2.1 <i>Manual tracing of the caudate</i>	53
2.2.2 <i>Manual tracing of the putamen</i>	53
2.2.3 <i>Manual tracing of the hippocampus</i>	56
2.3 <i>Structural neuroimaging: Shape analysis</i>	58
2.3.1 <i>Radial thickness and Jacobian measures</i>	60
2.3.2 <i>SPHARM-PDM longitudinal image processing</i>	62
2.4 <i>Measuring and analysing callosal thickness</i>	64
<b>3. Study One: Baseline striatal morphology in HD</b>	<b>67</b>
3.1 <i>Abstract</i>	69
3.2 <i>Introduction</i>	70
3.2.1 <i>The role of the striatum in Huntington Disease</i>	70
3.2.2 <i>Aims and hypotheses</i>	73
3.3 <i>Methods</i>	73
3.3.1 <i>Subjects and measures</i>	73
3.3.2 <i>Imaging</i>	75
3.3.3 <i>Volumetric analysis</i>	75
3.3.4 <i>Shape analysis</i>	78
3.4 <i>Results</i>	79
3.4.1 <i>Demographics and clinical details</i>	79
3.4.2 <i>Volume and shape</i>	81
3.4.3 <i>Correlations- shape</i>	82
3.5 <i>Discussion</i>	87
3.5.1 <i>CAG repeat length correlations with shape</i>	88
3.5.2 <i>Shape correlations with motor measures</i>	88
3.5.3 <i>Shape correlations with neurocognitive measures</i>	90
3.6 <i>Limitations</i>	92
3.7 <i>Conclusions/clinical implications</i>	92
<b>4. Study Two: Longitudinal striatal morphology in HD</b>	<b>93</b>



4.1 Abstract	95
4.2 Introduction	96
4.2.1 Striatal shape in HD	97
4.2.2 Mapping spatiotemporal progression of striatal atrophy in HD: the current state of play	98
4.2.3 A method to measure spatiotemporal progression	99
4.3 Methods	100
4.3.1 Subjects and measures	100
4.3.2 Shape analysis	101
4.4 Results	102
4.4.1 Group effects- shape	104
4.4.2 CAG repeats- shape	104
4.5 Discussion	109
4.5.1 Shape changes in relationship to frontostriatal circuits	110
4.5.2 Implications for pathophysiology	110
4.5.3 Towards an endophenotype of HD	111
4.6 Limitations	112
4.7 Conclusions/clinical implications	113
<b>5. Study Three: Hippocampal morphology and neurocognitive dysfunction in HD.</b>	<b>114</b>
5.1 Abstract	116
5.2 Introduction	117
5.2.1 The hippocampus	117
5.2.2 Volume and shape of the hippocampus in HD	121
5.2.3 Hypotheses	122
5.3 Method	122
5.3.1 Subjects	122
5.3.2 Measures	123
5.3.3 Manual tracing	123
5.3.4 Volumetric analysis	126
5.3.5 SPHARM shape analysis	126
5.4 Results	127
5.4.1 Baseline volumetric data	127
5.4.2 Baseline shape differences	128
5.5 Discussion	130
5.5.1 Volumetric differences in hippocampus	131
5.5.2 Clinical correlations	131
5.5.3 Hippocampal shape analysis	133

5.6	<i>Limitations</i>	134
5.7	<i>Conclusions</i>	135
<b>6.</b>	<b>Study Four: Callosal thickness in HD</b>	<b>136</b>
6.1	<i>Abstract</i>	138
6.2	<i>Introduction</i>	139
6.3	<i>Methods</i>	142
6.3.1	<i>Participants</i>	142
6.3.2	<i>Measures</i>	142
6.3.3	<i>Imaging</i>	143
6.3.4	<i>Mid-sagittal thickness profiles</i>	144
6.3.5	<i>Statistics</i>	144
6.4	<i>Results</i>	145
6.4.1	<i>Neurocognitive and motor testing</i>	145
6.4.2	<i>CC Thickness</i>	146
6.5	<i>Discussion</i>	151
6.5.1	<i>Changes in CC thickness as a marker of loss of connectivity</i>	151
6.5.2	<i>Bidirectional changes in the CC suggest ongoing plasticity</i>	152
6.6	<i>Limitations</i>	153
6.7	<i>Conclusion</i>	154
<b>7.</b>	<b>General discussion</b>	<b>155</b>
7.1	<i>Brief summary of findings</i>	156
7.2	<i>Insights into progression of neurodegeneration in HD and implications for treatment</i>	159
7.2.1	<i>Neuroanatomical changes in HD, network spread, and potential for neural and functional compensation.</i>	160
7.2.2	<i>Development of an endophenotype of HD, implications for treatment</i>	162
7.3.3	<i>Future directions</i>	164
7.4.	<i>Conclusion</i>	165
	<b>References</b>	<b>167</b>

## List of Manuscripts

The following manuscripts were published during my PhD candidature, derived from research project material presented in this thesis:

Study One: Wilkes F.A., Abaryan, Z., Ching, C.R.K., et al. (2019) Striatal morphology and neurocognitive dysfunction in Huntington disease: The IMAGE-HD study. *Psychiatry Research: Neuroimaging* 291, 1-8.

The following manuscripts were published during my PhD candidature, derived from research project material directly related to this thesis:

Turner, L., Jakabek, D., Wilkes, F.A., et al. (2016). Striatal morphology correlates with frontostriatal electrophysiological motor processing in Huntington's Disease: An IMAGE-HD study. *Brain and Behaviour*. 2016 Jul 27;6(12):e00511. doi: 10.1002/brb3.511

The following manuscripts were published during my PhD candidature, derived from research project material indirectly related to this thesis:

Owens-Walton C., Jakabek D., Li X., Wilkes F.A., et al. (2018) Striatal changes in Parkinson disease: An investigation of morphology, functional connectivity and their relationship to clinical symptoms. *Psychiatry Research: Neuroimaging* 275, 5-13

Power B.D., Jakabek D., Hunter-Dickson M., Wilkes F.A., et al. (2017) Morphometric analysis of thalamic volume in progressive supranuclear palsy: In vivo evidence of regionally specific bilateral thalamic atrophy. *Psychiatry Research: Neuroimaging* 265,65-71

Power, B.D., Wilkes, F.A., Hunter-Dickson, M., et al. (2015). Validation of a protocol for manual segmentation of the thalamus on magnetic resonance imaging scans. *Psychiatry Research: Neuroimaging* 232, 98-105

Macfarlane, M., Jakabek, D., Walterfang, M., et al. (2015). Striatal atrophy in the behavioural variant of frontotemporal dementia: correlation with diagnosis, negative symptoms and

disease severity. *PLOS One*, DOI:10.1371/journal.pone.0129692

Looi, J.C.L., Velakoulis, D., Walterfang, M., et al. (2014). AUSSIE – the Australian United States Scandinavian Imaging Exchange: an innovative virtual integrated health research network embedded in health care. *AustPsychiatry*, 22, 260-265

## List of Figures

<b>Figure</b>	<b>Page</b>
<b>Figure 1.1: Pathogenesis of HD</b>	22
<b>Figure 1.2: Gross neuroanatomical changes in HD</b>	25
<b>Figure 1.3: Central position of the striatum and schematic view of fronto-striatal re-entrant circuits</b>	29
<b>Figure 1.4: Topographic arrangement of the neostriatum</b>	30
<b>Figure 1.5: The human hippocampus</b>	33
<b>Figure 1.6: Representation of the hippocampus and its main connections</b>	34
<b>Figure 1.7: Areas of neurogenesis in the adult human brain</b>	37
<b>Figure 1.8: Corpus callosum anatomy and connectivity</b>	40
<b>Figure 2.1: Manual tracing of the caudate</b>	54
<b>Figure 2.2: Manual tracing of the putamen</b>	55
<b>Figure 2.3: Manual tracing of the hippocampus</b>	57
<b>Figure 2.4: Visual representation of radial thickness and Jacobian measures of morphological change</b>	61
<b>Figure 2.5: Schematic view of SPHARM-PDM pipeline</b>	63
<b>Figure 2.6: Measuring midsagittal callosal thickness</b>	65
<b>Figure 3.1: Frontostriatal re-entrant circuits</b>	71
<b>Figure 3.2: Manual tracing of the caudate</b>	76
<b>Figure 3.3: Manual tracing of the putamen</b>	77

<b>Figure 3.4: Visual representation of radial thickness and Jacobian measures of morphological change</b>	79
<b>Figure 3.5: Shape differences between groups</b>	83
<b>Figure 3.6: Correlations between neostriatal shape and measures of disease burden</b>	84
<b>Figure 3.7: Neostriatal shape correlations with motor and cognitive test scores</b>	86
<b>Figure 4.1: Schematic view of SPHARM-PDM pipeline</b>	101
<b>Figure 4.2: Main effect of group type, controlling for different time points</b>	105
<b>Figure 4.3: Group by time interaction</b>	106
<b>Figure 4.4: Main effect of CAG repeats on shape</b>	107
<b>Figure 4.5: Time by CAG interaction effect</b>	108
<b>Figure 5.1: The human hippocampus</b>	119
<b>Figure 5.2: Manual tracing of the hippocampus</b>	125
<b>Figure 5.3: Significant differences in baseline hippocampal shape in symp-HD compared to controls</b>	129
<b>Figure 6.1: Corpus callosum connectivity</b>	141
<b>Figure 6.2: Cross-sectional analysis of CC thickness, corrected for multiple comparisons and controlling for age and ICV</b>	147
<b>Figure 6.3: Ribbon plots showing mean change in callosal thickness</b>	148
<b>Figure 6.4: Longitudinal change in CC thickness in symp-HD after 30 months, corrected for multiple comparisons and controlling for age and ICV</b>	149
<b>Figure 6.5: Correlation between CC thickness in controls at Time 3 and scores on SDMT</b>	150

## List of Tables

<b>Table</b>	<b>Page</b>
<b>Table 1.1: Symptoms in HD and current treatment options</b>	19
<b>Table 1.2: Scope of thesis</b>	45
<b>Table 2.1: Selected demographic data from the IMAGE-HD study</b>	50
<b>Table 3.1: Study One</b>	67
<b>Table 3.2: Demographic and selected data across groups</b>	80
<b>Table 4.1: Study Two</b>	93
<b>Table 4.2: Demographic and volume data across groups</b>	103
<b>Table 5.1: Study Three</b>	114
<b>Table 5.2: Demographic and selected data across groups</b>	127
<b>Table 5.3: SSRI use and relationship with psychiatric symptoms, hippocampal volume, and motor incapacity in symp-HD</b>	129
<b>Table 6.1: Study Four</b>	136
<b>Table 6.2: Demographic, clinical, motor and baseline neurocognitive data</b>	145
<b>Table 7.1: Scope of thesis</b>	155

## List of Abbreviations

<b>Abbreviation</b>	<b>Full form/explanation</b>
<b>ACC</b>	Anterior cingulate cortex
<b>AC-PC plane</b>	Anterior commissure- posterior commissure plane
<b>BDI-II</b>	Beck Depression Inventory score, Version II
<b>BDNF</b>	Brain derived neurotrophic factor

<b>CA1-4</b>	Cornus ammonis subfields 1-4, cytoarchitecture of the hippocampus
<b>CAG (triplet) repeat</b>	Genetic change coding for polyglutamine repeat, in this document generally referring to the CAG triplet expansion within the <i>huntingtin</i> gene, although expansions also occur in other genes/disorders
<b>CAP score</b>	An index of degree of exposure to toxic polyglutamine repeats, based on CAG repeat length and age.
<b>CC</b>	Corpus callosum
<b>CSF</b>	Cerebrospinal fluid
<b>DBS</b>	Disease burden score, a marker of Huntington disease burden based off CAG repeat length and age
<b>DG</b>	Dentate gyrus
<b>DLPFC</b>	Dorsolateral prefrontal cortex
<b>DTI</b>	Diffusion tractography imaging
<b>EEG</b>	Electroencephalogram
<b>FA</b>	Fractional anisotropy
<b>FDR</b>	False discovery rate
<b>FEF</b>	Frontal eye fields
<b>FIRST</b>	FMRIB (Oxford Centre for Functional MRI of the Brain) Integrated Registration and Segmentation Tool
<b>fMRI</b>	Functional magnetic resonance imaging
<b>FrSBe</b>	Frontal Systems Behaviour Scale
<b>FSL</b>	FMRIB Software Library
<b>HADS A</b>	Hospital Anxiety and Depression Scale, Anxiety subscale
<b>HADS D</b>	Hospital Anxiety and Depression Scale, Depression subscale
<b>HD</b>	Huntington disease
<b>Htt</b>	Huntingtin protein
<b>ICC</b>	Intraclass correlation
<b>ICV</b>	Intracranial volume
<b>ITI</b>	Inter-tap interval, related to ITIPTAP and ITISTAP below
<b>ITIPTAP</b>	Variance in inter-trial interval in participant passed tapping,

	assess at two speeds, fast (3Hz) and slow (1.8Hz)
<b>ITISTAP</b>	Variance in inter-trial interval in speeded tapping
<b>IQ</b>	Intelligence quotient, in this thesis estimated from the National Adult Reading test
<b>JD</b>	Jacobian determinant
<b>LDDMM</b>	Large Deformation Diffeomorphic Metric Mapping
<b>MANCOVA</b>	Multivariate analysis of covariance
<b>MC</b>	Motor cortex
<b>MD</b>	Mean diffusivity
<b>mHtt</b>	Mutant huntingtin protein
<b>MRI</b>	Magnetic resonance imaging
<b>MSNs</b>	Medium spiny neurons
<b>OCD</b>	Obsessive compulsive disorder
<b>OFC</b>	Orbitofrontal cortex
<b>PPC</b>	Posterior parietal cortex
<b>pre-HD</b>	Presymptomatic Huntington disease
<b>SCOPI</b>	Schedule of Compulsions Obsessions and Pathological Impulses
<b>SD</b>	Standard deviation
<b>SDMT</b>	Symbol Digit Modalities Test
<b>SGZ</b>	Subgranular zone
<b>SMA</b>	Supplementary motor area
<b>SPHARM-PDM</b>	Spherical Harmonic Description- Point Distribution Models
<b>SSC</b>	Somatosensory cortex
<b>SSRI</b>	Selective serotonin reuptake inhibitor
<b>symp-HD</b>	Symptomatic Huntington disease
<b>SVZ</b>	Subventricular zone
<b>UHDRS</b>	Unified Huntington Disease Rating Scale
<b>UPSIT</b>	University of Pennsylvania Smell Identification Test



*When once it begins it clings to the bitter end.*

George Huntington

## **1. Introduction**

### **1.1 Overview**

Huntington disease (HD) is a devastating neurodegenerative disease, famously described by George Huntington, an American physician who wrote an account of the hereditary movement disorder in 1872 (Wexler, et al. 2016). It causes a clinical triad of progressive motor, cognitive and psychiatric symptoms, as well as observable in vivo imaging and post-mortem neurodegeneration. While the causative gene was eventually characterised in 1993 (The Huntington's Disease Collaborative Research Group 1993), unfortunately disease modifying treatments remain elusive. There is a concerted international effort to develop treatments for HD and to develop a clinical biomarker to aid in monitoring treatments and preventative measures.

Endophenotypes are “biological measures that correlate with, or predict, clinical features of brain dysfunction” (Looi, et al. 2014b). The concept was popularised in psychiatry due to the complexity of small changes in multiple genes and varying outcomes in psychiatric disorders, related to the interplay between environment and propensity, nurture and nature (Looi, et al. 2014b). This thesis uses a “hubs and spokes” neuroanatomical approach (Looi, et al. 2014b) to investigate key structures within the brain in HD with the view to developing an endophenotype and relate changes within the brain to observable clinical, motor and neurocognitive outcomes. Here, the neostriatum and hippocampus are investigated as “hubs” within the brain, followed by the major “spoke” of the corpus callosum, to develop a better understanding of the progression of neuroanatomical and related changes in HD.

Morphological analysis of these structures may provide insight into the pathophysiology and progression of HD and help with staging and monitoring progression, measuring treatment response, and targeting novel treatments.

### **1.2 Background/context**

#### *1.2.1 Huntington disease epidemiology and course*

HD is a lethal autosomal dominant, fully penetrant neurodegenerative disease caused by an expansion of the CAG triplet (polyglutamine) repeat in the gene *huntingtin* (The Huntington's Disease Collaborative Research Group 1993). It affects approximately 6 people per 100,000 population in Australia, with prevalence in the rest of the world ranging from 0.4 per 100,000 in Asia to 7 per 100,000 in North America (Rawlins, et al. 2016). HD is characterised by progressive motor, cognitive and psychiatric disturbances, as well as considerable brain atrophy, particularly of the neostriatum (Vonsattel, et al. 1985). The adult-onset subtype of HD is most common (>90% of cases (Koutsis, et al. 2013)), where onset usually occurs in midlife and death occurs 12 to 15 years later (Vonsattel and DiFiglia 1998), most frequently by aspiration pneumonia due to motor impairment (Heemskerk and Roos 2012; Sørensen and Fenger 1992). Throughout this thesis, “HD” refers to the adult-onset form of HD.

When HD becomes clinically manifest, it frequently causes a motor disorder in the form of a chorea, dance-like movements which are uncontrolled and cause spasmodic jerking, as well as other deficits with motor coordination (Young, et al. 1986). Prior to this motor manifestation more subtle changes can be seen in cognition and motor control (Biglan, et al. 2009; Paulsen, et al. 2017; Walker 2007). As motor processes degenerate, chorea can become less

pronounced and rigidity and dyskinesia develop, eventually leading to a loss of fine and gross motor skills. There is also a decline in cognitive capacity, particularly in executive function (Walker 2007; Young, et al. 1986). Neuropsychiatric symptoms are common throughout the course of HD, including dysphoria, irritability, agitation, apathy and anxiety (Paulsen, et al. 2001), with a higher rate of depression and suicide in both premanifest and symptomatic HD (Kachian, et al. 2019) (Table 1.1). There are no disease-modifying treatments, only symptomatic treatments such as antidepressants and antipsychotics for psychiatric and behavioural symptoms and dopamine-modulating agents to attenuate chorea (Table 1.1) (Bachoud-Levi, et al. 2019; Loi, et al. 2018; Ross and Tabrizi 2011).

**Table 1.1: Symptoms in HD and current treatment options** (Bachoud-Levi, et al. 2019; Ross and Tabrizi 2011).

Symptoms	Treatments	Notes
<b>Motor</b>		
- <b>Chorea</b>	Dopamine depleting agents	Important to optimise medications due to side effects.
- <b>Myoclonus</b>	(or dopamine agents,	
- <b>Dystonia, rigidity</b>	depending on symptoms),	Occupational therapy and physiotherapy extremely important.
- <b>Akathisia</b>	anticonvulsants,	
- <b>Akathisia (frequently iatrogenic)</b>	benzodiazepines, muscle relaxants	
- <b>Gait and balance disorders</b>	Cease medication if thought to be causing side effects.	Advanced swallowing disorders may require consideration of percutaneous endoscopic gastrostomy tube.
- <b>Swallowing disorders</b>		

---

**Cognitive**

- |   |  |  |
|---|--|--|
| - <b>Reduced executive function</b>                   | No pharmacological treatment is currently  | Rehabilitation strategies are key.   |
| - <b>Slowed information processing</b>                | recommended for cognitive symptoms.  | Treatment of psychiatric conditions such as depression may improve cognitive symptoms. |
| - <b>Language and communication disorders</b>         | Some medications used to treat motor and psychiatric symptoms can negatively affect cognition. |  |
| - <b>Social cognition impairments</b>                 |  |  |
| - <b>Memory disorders</b>                             |  |  |
| - <b>Disorientation</b>                               |  |  |
| - <b>Visuospatial and visual perceptual disorders</b> |  |  |

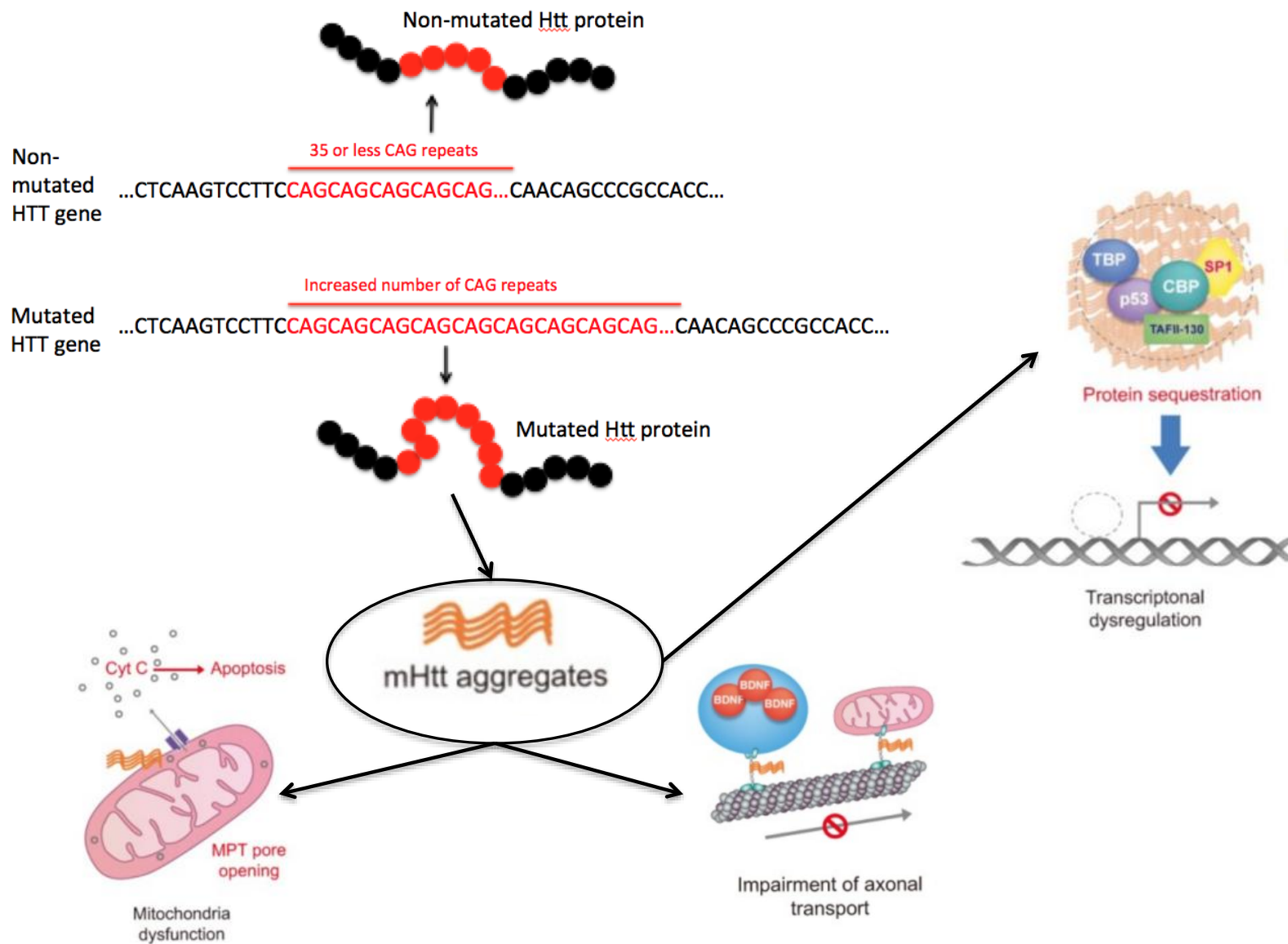
**Psychiatric**

- |   |  |                          |
|---|--|--------------------------|
| - <b>Depression</b>                     | Antidepressants,                             | Prevention of suicide    |
| - <b>Anxiety</b>                        | antipsychotics (also affect                  | includes treating risk   |
| - <b>Obsessive compulsive behaviour</b> | dopamine), anticonvulsants, mood stabilisers | underlying risk factors. |
| - <b>Irritability</b>                   |  |                          |
| - <b>Apathy</b>                         |  |                          |
| - <b>Psychosis</b>                      |  |                          |
| - <b>Mania</b>                          |  |                          |
| - <b>Impulsivity</b>                    |  |                          |
| - <b>Suicidal ideation and attempts</b> |  |                          |

### *1.2.2 Pathogenesis of HD*

CAG (polyglutamine) repeats exist in normal copies of the *huntingtin* gene, but more than 35 copies confer a risk for the development of HD, and more than 40 copies are generally associated with disease onset before the age of 65 (Chaganti, et al. 2017; Langbehn, et al. 2004; Rubinsztein, et al. 1996). Of note, although 27-35 CAG repeats are in the normal range, they are considered intermediate or unstable alleles and may expand or contract during reproduction (Sun, et al. 2017). However, while the genetic alteration accounts for approximately 50-70% of the age of motor onset, it has less to do with the later progression. A large proportion of age of onset and progression is likely related to environmental factors and other modifier genes conferring risk or protection (Rosenblatt, et al. 2006; Wexler, et al. 2004). As the gene is passed down the generations there is not infrequently an expansion of the unstable polyglutamine repeat, leading to a more severe form of the disease and an earlier age of onset. This phenomenon is known as anticipation and also occurs in other genetic diseases with similar triplet repeats, such as Fragile X syndrome and myotonic dystrophy (Teisberg 1995).

Theories as to the cause of neurodegeneration include a direct toxic effect of the mutant huntingtin protein (mHtt), as well as loss of its normal function in healthy neuronal tissue (Figure 1.1) (Morigaki and Goto 2017; Saudou and Humbert 2016). Wild-type huntingtin (Htt) is important as a major protein interaction hub and an orchestrator of converging intracellular trafficking and signalling pathways (Ratovitski, et al. 2012), has anti-apoptotic properties (Rigamonti, et al. 2000; Rigamonti, et al. 2001) and is essential for normal embryonic development (Nasir, et al. 1995)



**Figure 1.1: Pathogenesis of HD.** Adapted from (Kim and Kim 2014). Huntingtin gene (HTT), huntingtin protein (Htt), Mutant huntingtin (mHtt), cAMP response element binding protein (CREB) binding protein (CBP), TATA-binding protein (TBP), specificity protein 1 (SP1) and TBP-associated factor, 135 kDa (TAFII-130), brain-derived neurotrophic factor (BDNF), mitochondrial permeability transition (MPT), Cytochrome c (Cyt c).

An expanded polyglutamine sequence causes the normal huntingtin protein to misfold. These misfolded proteins build up in the cell nucleus as aggregates, which may cause altered cellular metabolism, neurotransmitter dysfunction, oxidative stress, microglial activation, and reactive astrogliosis (Andre, et al. 2016; Bates 2003; DiFiglia, et al. 1997; Lee, et al. 2007; McColgan and Tabrizi 2018; Tabrizi, et al. 2000). mHtt also causes alterations in transcription and epigenetic pathways (Ament, et al. 2018; Hervas-Corpion, et al. 2018; Seredenina and Luthi-Carter 2012). Although proteosomal degradation of mHtt prevents cytotoxicity early in life, this function is decreased with ageing and is at least partially responsible for the manifestation of disease later in life (Li and Li 2011).

Medium spiny neurons (MSN) are the striatal cell population predominantly affected in HD (Ferrante, et al. 1987a; Ferrante, et al. 1987b), despite the fact that *huntingtin* is expressed in almost all tissues (Sassone, et al. 2009). MSN have a number of characteristics which may make them more susceptible to the toxic effects of Htt (Morigaki and Goto 2017), including requiring high amounts of energy to maintain hyperpolarised states (Wilson and Kawaguchi 1996), containing lower levels of superoxide free radical scavengers (Medina, et al. 1996), and having alterations in glutamate transmission and response (Calabresi, et al. 1999; Calabresi, et al. 1998; Rossi, et al. 2006). While expression of mHtt itself is not increased in the striatum, there is increased expression of Rhes, a guanine nucleotide-binding protein that binds to mHtt and increases its toxicity (Subramaniam, et al. 2009). Striatal projection

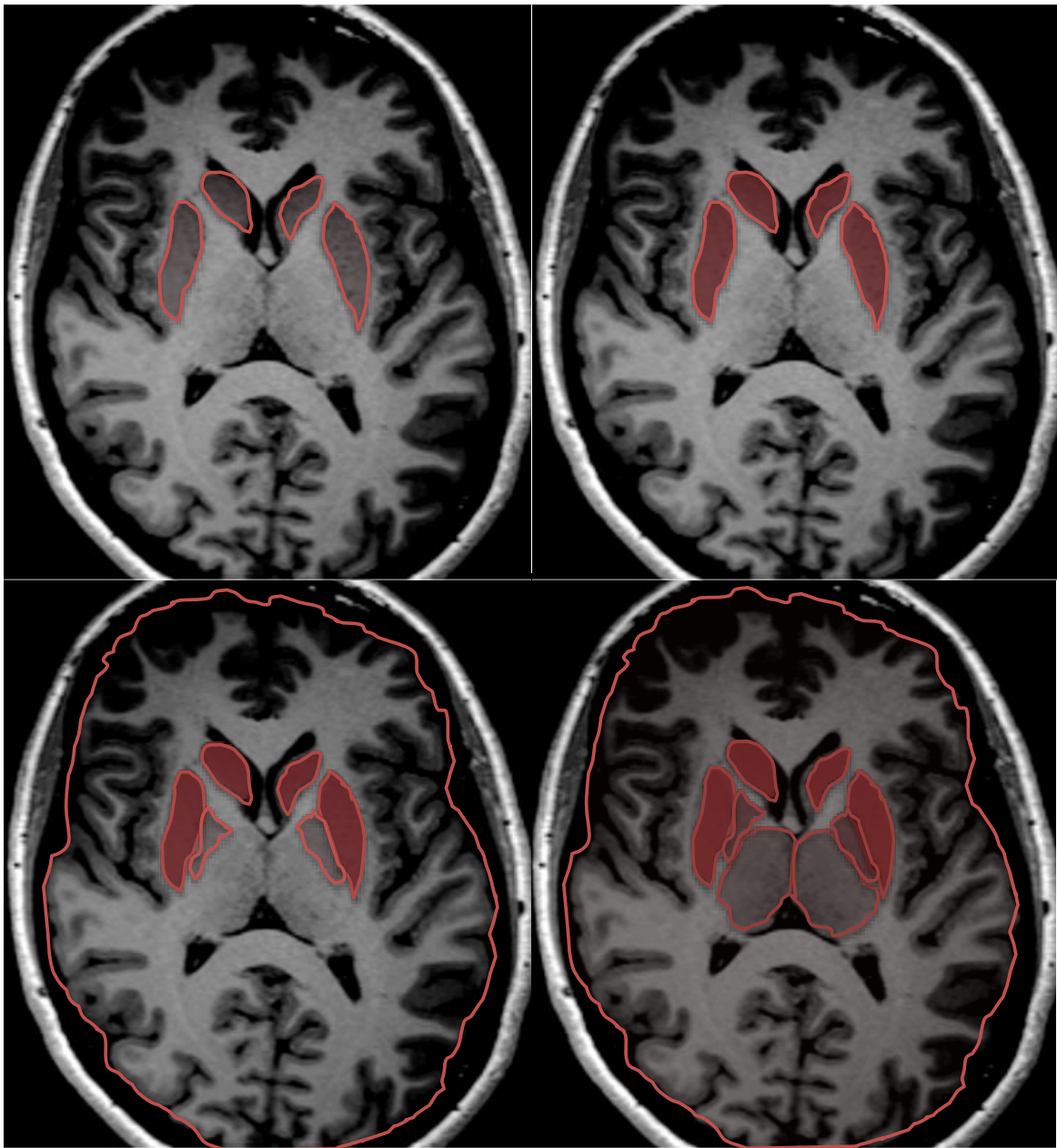
neurons require Htt for synaptic plasticity and survival (Burrus, et al. 2020), as well as brain derived neurotrophic factor (BDNF) (Canals, et al. 2004; Li, et al. 2012; Zuccato, et al. 2008), which depends on Htt for its production and transport to the striatum (Gauthier, et al. 2004; Zuccato and Cattaneo 2007; Zuccato, et al. 2001; Zuccato, et al. 2003). Growing evidence such as this points to HD as causing neurodevelopmental disruption as well as neurodegeneration (Lee, et al. 2012; Mangin, et al. 2020; Nopoulos, et al. 2011; Zuccato, et al. 2008).

### *1.2.3 Overview of neuroanatomical changes in HD*

Changes in the striatum in HD have been observed since the late 19<sup>th</sup> century and were further characterised by Vonsattel in the 1980s into five neuropathological grades of disease which correlated with reported clinical disease severity (Figure 1.2) (Vonsattel, et al. 1985). This study was based on post-mortem brain specimens of 163 clinically diagnosed cases of HD, and divided changes into grade 0, where there was a clinical diagnosis of HD but no discernible brain changes (note this occurred in 5 people only), through microscopic changes only (grade 1- 50% of neurons lost in the caudate) to gross changes in the caudate and putamen. The earliest changes were seen in the medial paraventricular portions of the caudate, in the caudate tail, and in the dorsal part of the putamen. In grades 3 and 4 changes were seen in other brain regions including the thalamus, sub-thalamic nucleus, white matter and cerebellum. By grade 4, 95% of neurons were lost in the caudate (Vonsattel, et al. 1985).

Extending this work, neuroimaging studies have shown neostriatal (caudate and putamen) volume is reduced in individuals with premanifest HD more than a decade before predicted disease onset (van den Bogaard, et al. 2011a), while more pronounced atrophy is apparent in patients the closer they are to onset (van den Bogaard, et al. 2011b). Caudate atrophy rates





**Figure 1.2: Gross neuroanatomical changes in HD.** Progression of HD via Vonsattel grades, from grades 1-4 (top left to bottom right) (Vonsattel and DiFiglia 1998). Affected areas represented in red, overlaid on an axial MRI slice of a normal brain from our study. Top images show changes in the caudate and putamen alone, while bottom images progress to include cortex and pallidum (bottom left and right), then thalamus (bottom right).

have been found to be 1-4% per year (Aylward, et al. 2011b; Aylward, et al. 2003; Hobbs, et al. 2009; Kipps, et al. 2005; Tabrizi, et al. 2011), while putaminal atrophy rates are as high as 3-7% (Tabrizi, et al. 2011) and may be the better predictor in whether an individual will develop the motor symptoms of HD in the next one to four years (Aylward, et al. 2012). Neurodegeneration in later stages of HD spreads out from the striatum, locally into other areas of the basal ganglia but also distally into cortex, particularly sensorimotor, insular and opercular cortices as well as frontal, cingulate, and visual cortex (Poudel, et al. 2019; Reiner and Deng 2018; Wijeratne, et al. 2018). White matter changes also occur, largely but not exclusively in corticostriatal white matter pathways (for overview see (Poudel, et al. 2019; Poudel, et al. 2014b)).

When investigating morphology using neuroimaging techniques, the striatum shows the earliest and largest amount of shape change in pre-symptomatic HD (pre-HD) and symptomatic HD (symp-HD) (Faria, et al. 2016; Kim, et al. 2017; Tang, et al. 2019; van den Bogaard, et al. 2011b; Wijeratne, et al. 2018; Younes, et al. 2012). Changes are also described in other areas in pre-HD closer to disease onset, including in the nucleus accumbens, globus pallidus, thalamus, hippocampus and amygdala, although results are less consistent (Faria, et al. 2016; Tang, et al. 2019; Younes, et al. 2012). Small areas of striatal shape displacement are seen in people with premanifest HD more than a decade from predicted disease onset, with more pronounced changes occurring in the medial caudate nucleus and putamen in those closer to predicted onset (van den Bogaard, et al. 2011b). Using an index of degree of exposure to the toxic polyglutamine repeats (a so-called “CAP-score”, based on CAG repeat length and age [CAG-Age Product]), significant shape differences are seen in caudate and putamen in people with high CAP scores, and in left putamen in the mid CAP scores group

(Younes, et al. 2012). These changes spare the dorsal caudate and show no clear gradient in putamen, although the most rostral portion of putamen is spared (Younes, et al. 2012).

### **1.3 The subcortical connectome: role of the striatum and other subcortical areas involved in HD**

The neostriatum, the hippocampus, and the corpus callosum are the structures of interest in this thesis, investigated together as part of the subcortical connectome, with the view towards using this as an endophenotype of HD. By quantitative mapping of neuroanatomical changes in HD, specifically with respect to subcortical structures, we relate the topography of these maps to the contours of the circuits affected by disease, and according to symptomatic dysfunction (Looi, et al. 2014b).

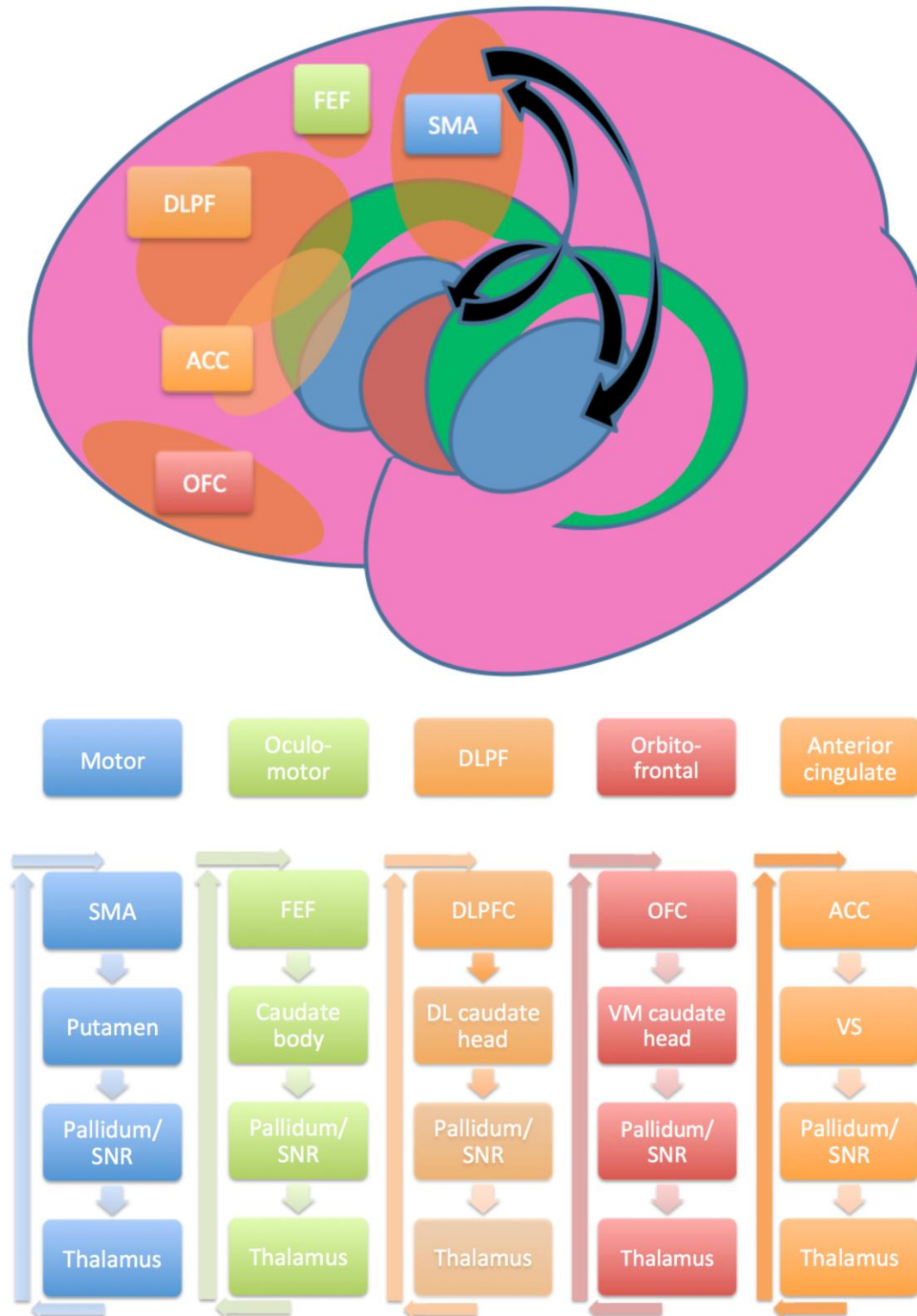
#### *1.3.1 The neostriatum*

The neostriatum, composed of the caudate nucleus and putamen, is a critical relay in frontostriatal re-entrant circuits involved with cognitive, emotional, behavioural and motor functions (Draganski, et al. 2008) (Figure 1.3). In general, these originate in the relevant area of cortex, then travel through, and are modified in, the neostriatum, globus pallidus, thalamus, and back to originating cortex. Structural changes in the striatum may disrupt these frontostriatal pathways and, as well as the obvious motor sequelae, also lead to measurable changes in related cognitive and neuropsychiatric outcomes (Looi and Walterfang 2012). In both Parkinson's disease and HD, abnormalities, particularly, but not exclusively in movement, are related to damage to this circuitry: in Parkinson's disease because of a lack of the neurotransmitter dopamine, while in HD this is related to neuronal loss (eg (Reiner and Deng 2018)).

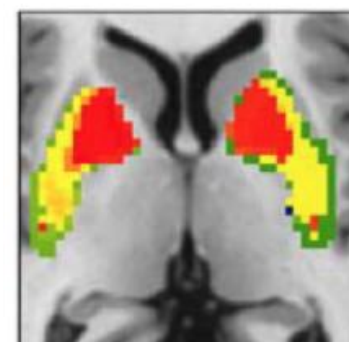
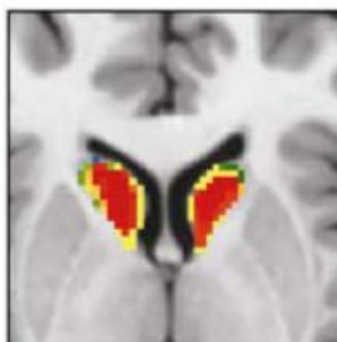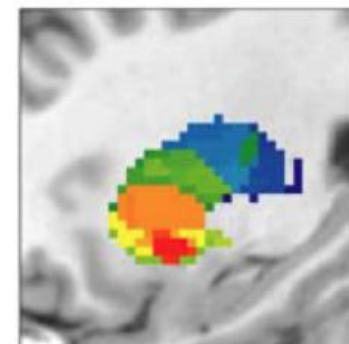
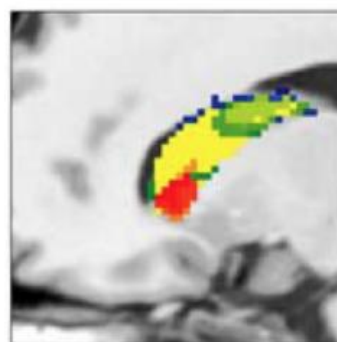
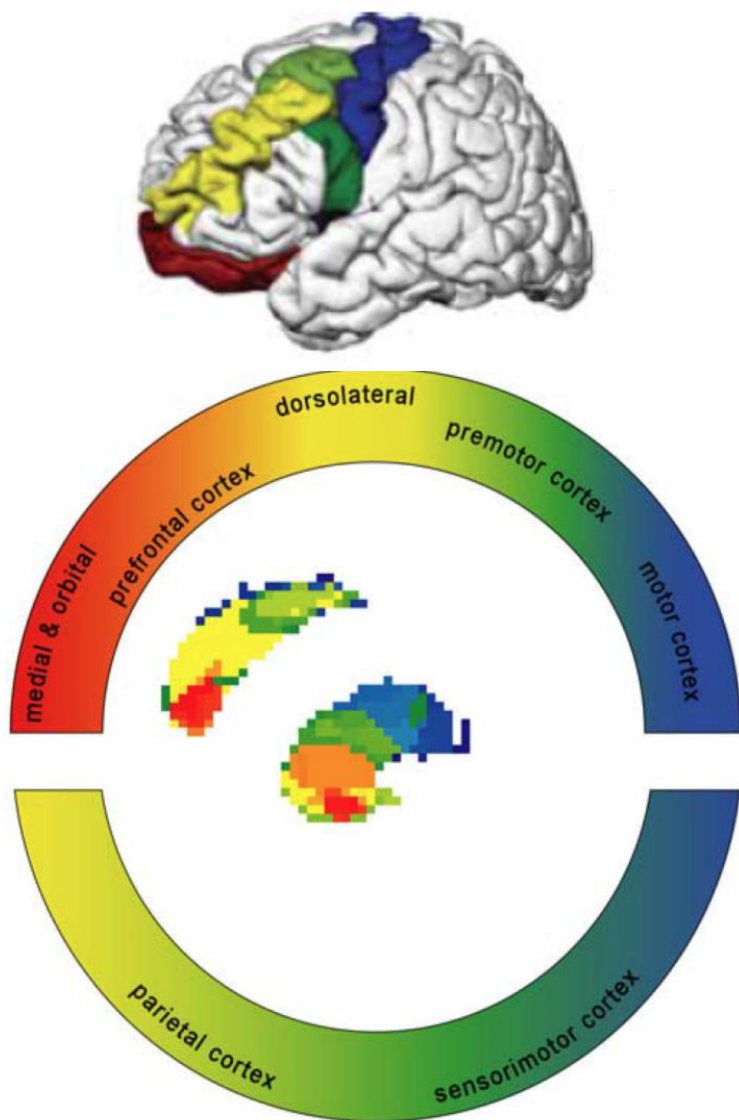
There are five frontostriatal re-entrant circuits which are generally described (Figure 1.3).

Two of these are frontostriatal motor circuits: the first is the well-known motor circuit originating in the supplementary motor area (SMA) and central to many movement disorders, including Parkinson's disease and HD (Alexander, et al. 1986; Cummings 1993). The other frontostriatal motor circuit originates in the frontal eye fields (FEF) and regulates visual attention and eye movements. HD patients have deficits in the voluntary control of saccadic eye movements, which is attributed to damage to this fronto-striatal loop (Peltsch, et al. 2008; Winograd-Gurvich, et al. 2003). There are three "cognitive loops", named for the area of cortex in which they originate: the dorsolateral prefrontal circuit is required for executive function such as problem solving, the orbitofrontal circuit mediates inhibition and impulse control, and the anterior cingulate circuit mediates motivation and initiation of behaviour (Alexander, et al. 1986; Cummings 1993). The striatum is structurally and functionally organised in a topographic pattern with more anterior portions receiving connections from more anterior parts of the cortex and more posterior parts from more posterior cortex (Bohanna, et al. 2011a).

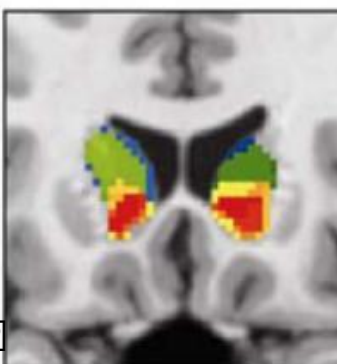
The striatum is highly topographically organised (Figure 1.4), with the caudate head and body receiving connections on the lateral aspect from dorsolateral prefrontal cortex (DLPFC), inferior orbitofrontal cortex (OFC) and posterior parietal cortex (PPC) and on the medial aspect from the anterior cingulate cortex (ACC). The caudate tail meanwhile receives input from the FEF. The putamen receives more motor input, receiving on its medial aspect connections from the motor cortex (MC) and somatosensory cortex (SSC), and on the lateral from the FEF. The putamen receives more motor input, receiving on its medial aspect connections from the motor cortex (MC) and somatosensory cortex (SSC), and on the lateral



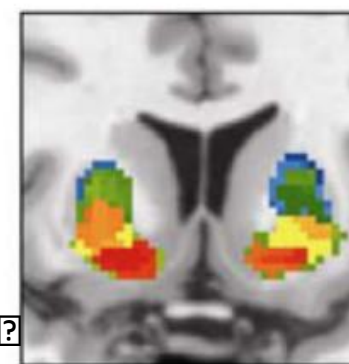
**Figure 1.3: Central position of the striatum and schematic view of fronto-striatal re-entrant circuits.** Based on Alexander, 1986 (Alexander, et al. 1986). SMA, supplementary motor area; SNR, substantia nigra pars reticulata; FEF, frontal eye fields; DLPF/C, dorsolateral prefrontal/cortex; DL, dorsolateral; OFC, orbitofrontal cortex; VM, ventromedial; ACC, anterior cingulate cortex; VS, ventral striatum.



a) ?



b) ?



**Figure 1.4: Topographic arrangement of the neostriatum.** “Rostrocaudal gradient” of frontal cortical connectivity in caudate and putamen. a) Caudate connectivity to different areas of cortex, represented in primary colours, visualised in sagittal, axial and coronal planes. b) Putamen connectivity to same, also visualised in sagittal, axial and coronal planes. Adapted from (Draganski, et al. 2008), after (Haber 2003).

aspect connections from the SMA. On its ventral aspect the putamen also receives input from the DLPFC, while both caudate and putamen are also linked directly through fibres traversing the internal capsule (Alexander, et al. 1986; Draganski, et al. 2008; Haber 2003; Haber, et al. 2000). In general, both caudate and putamen are topographically organised along an anterior-posterior axis such that more anterior parts of the striatum receive input from more anterior parts of the cortex (Bohanna, et al. 2011a).

Neostriatal shape changes are seen in a number of neurodegenerative and neuropsychiatric disorders which have links to frontostriatal circuits and behavioural disruption. For example, people with bipolar affective disorder show reductions in caudate regions which connect to DLPFC (Ong, et al. 2012), important for executive control. People with frontotemporal dementia exhibit deficits in oculomotor function, which can be related to alterations in the FEF circuit and the marked posterior atrophy of the caudate in this disorder (Looi, et al. 2011). Shape changes are also seen in chorea-acanthocytosis, which affects the neostriatum and produces choreo-athetoid movements which can be indistinguishable from those seen in HD. Chorea-acanthocytosis patients display major executive function deficits, particularly a greatly increased incidence of obsessive compulsive disorder (OCD), and shape changes are seen in areas of the striatum connected not only to motor circuits but also to all three frontostriatal circuits involved in behaviour (Walterfang, et al. 2011). Similarly, in OCD there are outward shape deformities in the superior, anterior parts of bilateral caudate nucleus,

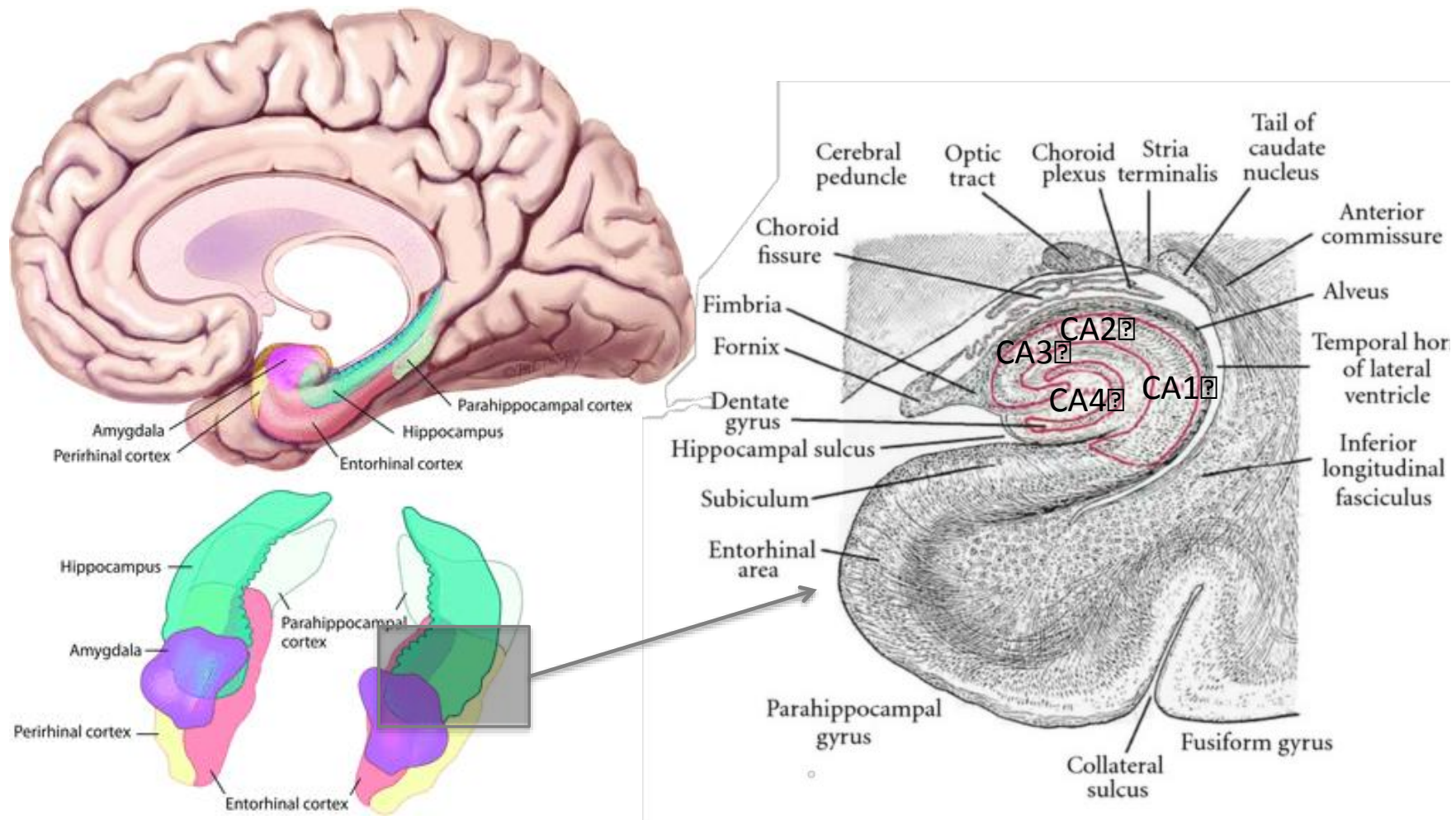
connected to DLPFC, and in the inferior, lateral portion of the left putamen, connected to limbic areas (Choi, et al. 2007). The eating disorders anorexia nervosa, binge eating disorder and bulimia nervosa, are also all known to have changes in the striatum (Molina-Ruiz, et al. 2020). This collective data suggests that disorders of repetitive thought and movements have significant striatal shape alterations.

Knowledge of the anatomy of this circuitry, and in particular of the topographical nature of striatal organisation, can help to guide treatments. An example is deep brain stimulation, which has widespread utility in Parkinson's disease but is also being used worldwide for psychiatric conditions including Gilles de la Tourette syndrome and OCD. In all three of these disorders the striatum is a major target of deep brain stimulation, and an electrode is placed surgically into this area where targeted currents of electricity modulate the abnormal circuitry and can lead to symptomatic relief (for a recent review see (Horn and Fox 2020)). While deep brain stimulation is a useful treatment for many diseases, it has so far had limited utility in HD, possibly due to the aggressive nature of neurodegeneration (Gonzalez, et al. 2014).

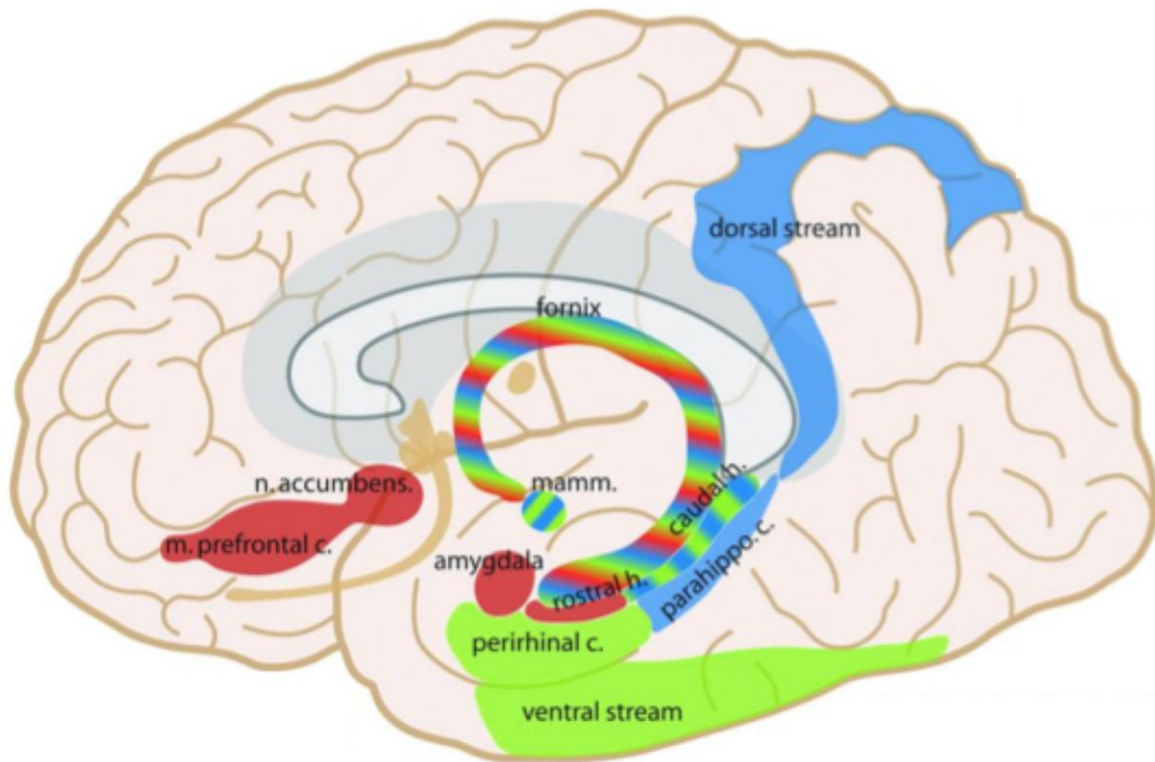
### *1.3.2 The hippocampus*

The hippocampus lies within the medial temporal lobe, bulging in the floor of the inferior horn of the lateral ventricle (Figure 1.5). In gross anatomical terms it can be divided into the hippocampal head, which is the most anterior part, the hippocampal body, and the tail. Based on its cytoarchitecture it is divided into the cornu ammonis subfields CA1-4, the dentate gyrus, and the subiculum (Figure 1.5b). Its main input arrives at the entorhinal cortex from association cortex in the frontal, parieto-occipital, and temporal lobes. These inputs are then processed further in the medial temporal lobe and sent back via subiculum to entorhinal





**Figure 1.5: The human hippocampus.** Schematic view on the sagittal plane (top left) and showing 3-dimensional hippocampi looking from an anterosuperior viewpoint adapted from (Purves 2012) (bottom left), with further emphasis on cytoarchitecture (right), shown in the coronal plane and adapted from (Kiernan 2012)



**Figure 1.6: Representation of the hippocampus and its main connections** (Purves 2012).

Anterior (rostral) hippocampus is connected to red areas of the brain above, caudal hippocampus to blue and green areas. The fornix is the major relay of outputs from the hippocampus. n. accumbens, nucleus accumbens; m. prefrontal c., medial prefrontal cortex; mamm., mammillary bodies; perirhinal c., perirhinal cortex; rostral h., rostral hippocampus; caudal h., caudal hippocampus; parahippo. c., parahippocampal cortex.

cortex to association cortices for memory storage (Figure 1.6) (Blumenfeld 2010).

There are two major projection pathways from the entorhinal cortex into the hippocampal formation- the perforant pathway and the alvear pathway. The perforant pathway reaches through the subiculum and across the hippocampal sulcus to the granule cell layer of the dentate gyrus. The granule cells then synapse directly on to CA3 pyramidal cells, and via Schaffer collaterals onto CA1 pyramidal cells, both of which then leave the hippocampus via

the fornix. CA1 cells relay through the subiculum to the fornix, as well as back into deeper layers of entorhinal cortex. The alvear pathway projects directly to CA1 and CA3, with outputs similar to the perforant pathway. The fornix carries output to the mammillary bodies of the hypothalamus, the lateral septal nucleus, and the anterior thalamic nucleus. Some inputs reach the hippocampus from the contralateral hippocampus via the hippocampal commissure, and further modulatory inputs arise via the fornix from cholinergic neurons in the medial septal nucleus and the nucleus of the diagonal band (Blumenfeld 2010).

Like the striatum, the hippocampus is also topographically organised. The posterior hippocampus is implicated in memory and spatial navigation whereas anterior hippocampus mediates anxiety related behaviour and learning through its connections to amygdala and hypothalamus (Figure 1.6) (Fanselow and Dong 2010; Moser and Moser 1998; Strange, et al. 2014). The hippocampus receives projections from the cingulate cortex along its long axis. Cingulate areas involved in emotional regulation project to more ventral regions, and cingulate areas involved in spatial processing project to more dorsal regions. Reciprocating projections are similarly organised. There is a gradient of output to the lateral septum and hypothalamus, coming largely from the anterior hippocampus. The hippocampus is connected with the nucleus accumbens and amygdala, with progressively more anterior hippocampal portions projecting to progressively more medial parts of both of these structures. There are different patterns of gene expression in different areas, and in general, neurotransmitter receptor expression varies across the long axis for the majority of transmitter systems (Strange, et al. 2014).

Shape and volume analysis have been applied to the hippocampus in a number of neurodevelopmental and degenerative disorders (Lindberg, et al. 2012; Solowij, et al. 2013;

Wood, et al. 2010). There is considerable interest in hippocampal plasticity, as cognitive training has been shown to increase left hippocampal activation in mild cognitive impairment (Rosen, et al. 2011) and aerobic exercise training has been shown to increase anterior hippocampal size and improve spatial memory (Erickson, et al. 2011). This increase in volume is associated with greater serum levels of BDNF (Erickson, et al. 2011). Limited attention however has been paid to the hippocampus in HD. In those few studies directly addressing hippocampal volume or shape in HD (Majid, et al. 2011; van den Bogaard, et al. 2011b; Younes, et al. 2012), the hippocampus in pre-HD tends to be spared (Majid, et al. 2011; Younes, et al. 2012), although both shape and volume changes do occur later on in disease progression (van den Bogaard, et al. 2011b). Despite known hippocampal plasticity and neurogenesis, no studies have examined longitudinal changes in HD.

### *1.3.3 Neurogenesis potential near striatum and hippocampus*

There are two areas of the adult brain where neurogenesis can occur: the subgranular zone of the dentate gyrus in the hippocampal complex (SGZ), and the subventricular zone (SVZ), which lies just above the caudate (Figure 1.7) (Barani, et al. 2007). Progenitor cells in the SGZ can migrate to the granule cell layer and differentiate into granular neurons which are functionally integrated into the hippocampal circuitry.

Newly generated cells in the SVZ can migrate to affected striatum in a model of HD (Jin, et al. 2005) and in ischaemia, and differentiate into medium spiny neurons (Yamashita, et al. 2006). In HD, increased cell proliferation and neurogenesis have been observed in the SVZ of

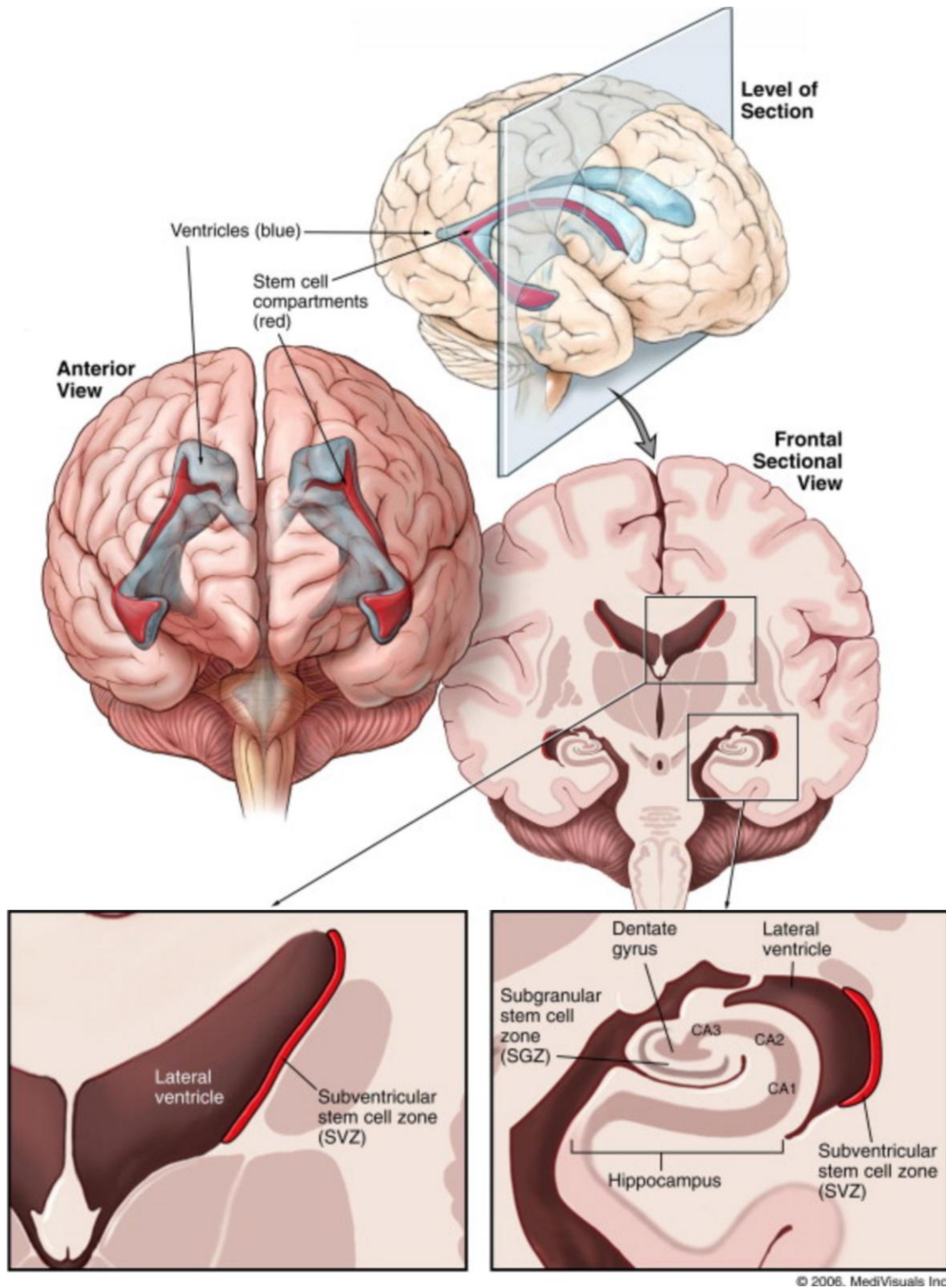


Figure 1.7: Areas of neurogenesis in the adult human brain (Barani, et al. 2007).

the adult human brain (Curtis, et al. 2003), while in the hippocampus *impaired* neurogenesis is observed in humans as well as in murine models (for review see (Curtis, et al. 2012; Gil-Mohapel, et al. 2011; Ransome, et al. 2012)).

Interestingly, treatment with selective serotonin reuptake inhibitors (SSRIs) in transgenic mouse models of HD increases both BDNF levels and neurogenesis in SGZ and SVZ, attenuating the progression of brain atrophy and behavioural abnormalities and increasing survival (Duan, et al. 2008; Grote, et al. 2005; Peng, et al. 2008). Despite this work in animal models and the common use of antidepressants, particularly SSRIs, in HD (Rowe, et al. 2012) there has been surprisingly limited research into the effect of SSRIs on the natural history of human HD progression.

### *1.3.4 Hippocampal/striatal circuits*

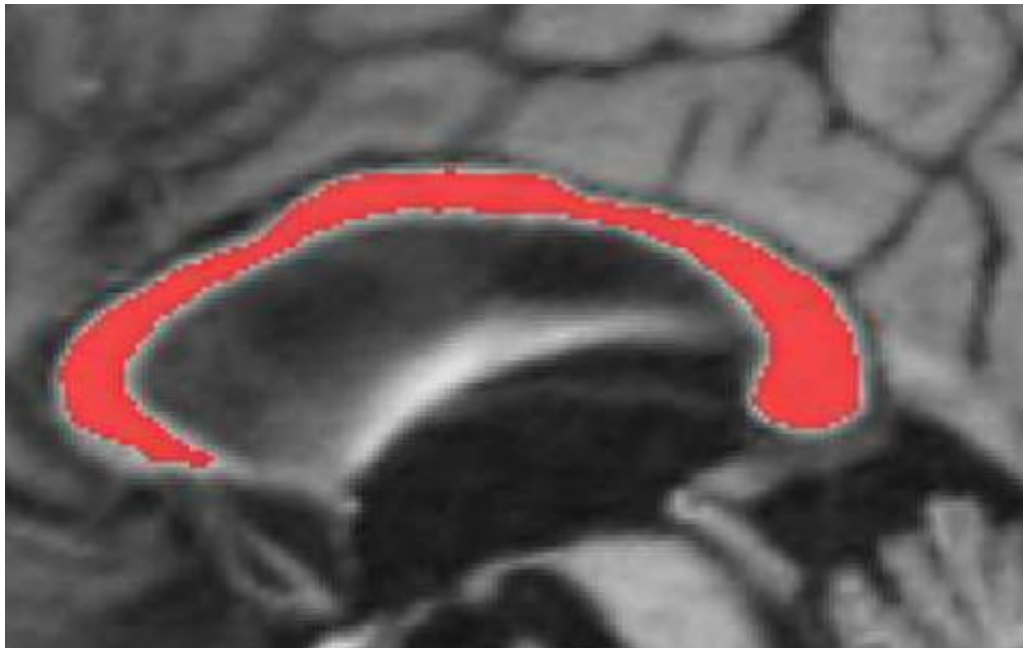
The hippocampus and the striatum are involved in parallel memory systems that interact (McDonald and White 1994; White 2009; White and McDonald 2002). Animal studies suggest that the dorsolateral parts of the neostriatum are central to the processing and consolidation of memory for reinforced stimulus-response associations, while the more medial and anterior areas are part of a circuit that includes the hippocampus and mediates relational information and certain forms of working memory (White 2009). Connections between the hippocampus and the ventral striatum, in particular the nucleus accumbens, modulate reward or goal directed behaviour (Fouquet, et al. 2013; Strange, et al. 2014). The caudate is thought to play a critical role in egocentric navigation as opposed to the hippocampus' role in allocentric navigation (McDonald and White 1994; White 2009; White and McDonald 2002), although in some cases in HD the hippocampus can compensate for caudate dysfunction in this memory pathway (Possin, et al. 2017; Voermans, et al. 2004). The

hippocampus and the striatum also interact cooperatively to support episodic memory formation (Sadeh, et al. 2011). Functional MRI (fMRI) studies show that successful memory is associated with greater activity in both the hippocampus and the putamen, with the strength of the correlation predicting memory success (Sadeh, et al. 2011).

### *1.3.5 The corpus callosum*

Further extending our study of subcortical structures in HD, we wished to look at the corpus callosum (CC), as a “spoke” in neural circuitry in addition to the “hubs” discussed above. The CC is the brain’s largest white matter bundle and contains most of the commissural fibres connecting the cortices of the two hemispheres (Figure 1.8). The trunk of the callosum is the compact part of the commissure in and near the midline. It is considerably shorter than the hemispheres, which accounts for the enlargements at the ends; these are the genu anteriorly and the splenium posteriorly. The genu tapers into the rostrum of the CC, which is continuous with the lamina terminalis forming the anterior wall of the third ventricle. The ventral surface of the CC forms the roof of the lateral ventricles (Kiernan 2005).

The CC may be used as a proxy for cortical changes and a marker of interhemispheric interconnections and changes in HD. Callosal thickness has previously been shown to be related to thickness in the cortical areas it connects (Hampel, et al. 1998; Teipel, et al. 2002), with connections occurring largely topographically and between hemispheres, but also within certain areas in the same hemisphere (Chao, et al. 2009; Phillips, et al. 2013). This is in contradistinction to the connections which occur through frontostriatal and hippocampal circuitry which do not go through the CC, and thus provides a more comprehensive picture of subcortical changes in HD.



**Figure 1.8: Corpus callosum anatomy and connectivity.** Reproduced and modified with permission from (Adamson, et al. 2014) (superior image) and (Phillips, et al. 2013) (inferior image). Images are in the sagittal plane, with anterior to the left and posterior to the right. The superior image shows gross anatomy of mid-sagittal corpus callosum, while the inferior image shows tracts within the corpus callosum connecting frontal (yellow), orbitofrontal (orange), superior frontal (blue), superior parietal (purple), posterior parietal (pink), temporal (brown), and occipital (light pink) regions.



In addition to subcortical structures, degeneration of the cerebral cortex is also known to occur in HD (Nopoulos, et al. 2010). Simplifying the analysis of overarching cortical changes, CC morphology has been purported to reflect cortical changes in HD and other neurodegenerative diseases (Rosas, et al. 2010). The CC has specific functional subregions based on connectivity to different parts of the cortex, and changes in these subregions are thought to be the morphological mirror of neuropsychological effects in degenerative disease (Rosas, et al. 2010): changes here may map cortico-cortical circuit abnormalities that underpin neuropsychological change. Diffusion tensor imaging in particular has shown changes in connectivity within the corpus callosum in HD (Bohanna, et al. 2011b; Della Nave, et al. 2010; Dumas, et al. 2012; Rosas, et al. 2006) and certain studies have gone further to show correlations between these changes and motor, oculomotor and cognitive function (Bohanna, et al. 2011b; Dumas, et al. 2012; Rosas, et al. 2006). While diffusivity changes have been seen in the CC as much as a decade prior to disease onset (Rosas, et al. 2010), and have even been correlated with probability of onset within 2-5 years (Dumas, et al. 2012), the picture with callosal shape changes is less clear, and no studies have looked at longitudinal changes.

### **1.4 The IMAGE-HD study**

The IMAGE-HD study is a Melbourne based study which followed a cohort of 36 people with pre-HD, 37 people with symp-HD, and 36 controls, with measures including motor, psychiatric and cognitive tests, 3T MRI brain scans, and other modalities outside the scope of this thesis (diffusion tractography imaging (DTI); fMRI). Participants were recruited in 2008 and 2009 through the HD Predictive Testing Program (Genetic Health Services, Victoria). Healthy controls were matched for age, sex and IQ to the pre-HD individuals. All participants

were right-handed and were free from brain injury, neurological and/or severe diagnosed psychiatric conditions other than HD. The study followed these people over time and took a number of different tests at the start of the study, at 18 months, and at 30 months.

Tests outside of imaging included Unified Huntington Disease Rating Scale (UHDRS) motor assessment (Huntington Study Group 1996); visuo-motor speed and attention (Symbol Digit Modalities Test, SDMT (Smith 1982)), speeded reading (Stroop Word Test, (Stroop 1935)), odour recognition (University of Pennsylvania Smell Identification Test, UPSIT (Doty, et al. 1984)) and motor performance (speeded tapping and self-paced tapping tasks (Stout, et al. 2011)), executive function (Frontal Systems Behaviour Scale, FrSBe (Stout, et al. 2003)) and psychiatric disturbances (Schedule of Compulsions Obsessions and Pathological Impulses, SCOPI (Watson and Wu 2005), Hospital Anxiety and Depression Scale, HADS A and HADS D (Zigmond and Snaith 1983), Beck Depression Inventory score Version II, BDI II (Beck 1996)). All were chosen because of their proven potential in differentiating symp-HD and possibly pre-HD (Stout, et al. 2011; Tabrizi, et al. 2009).

Previous work in the IMAGE-HD study has investigated various different imaging modalities including DTI (Bohanna, et al. 2011a; Dominguez, et al. 2013; Dominguez, et al. 2016; Georgiou-Karistianis, et al. 2013a; Poudel, et al. 2015b; Poudel, et al. 2014b), fMRI (Domínguez, et al. 2017; Georgiou-Karistianis, et al. 2013b; Georgiou-Karistianis, et al. 2014; Gray, et al. 2013; Poudel, et al. 2015a; Poudel, et al. 2014a; Soloveva, et al. 2020), iron studies (Domínguez, et al. 2016), and investigations of other areas including cortex (Shishegar, et al. 2019), thalamus (Furlong, et al. 2020), hypothalamus (Gabery, et al. 2015), and amygdala (Ahveninen, et al. 2018; Alexander, et al. 2020).

My primary PhD supervisor Associate Professor Jeffrey Looi and I (Looi, et al. 2014a) became involved with the IMAGE-HD study after the initial data collection, in order to further investigate morphological change in elements of the subcortical connectome, for reasons described above. I manually traced caudate, putamen and hippocampus and then worked with other collaborators to coordinate and analyse this data in the light of the other clinical information obtained. The CC has a reliable method of analysis which does not require manual tracing and so I coordinated sending this to a further collaborator for computational analysis, before further analysing and interpreting results. Further details of the methods used in the various studies can be found in subsequent sections of this thesis.

Study One of this thesis has been published in the scientific literature (Wilkes, et al. 2019), and will be appended in full to the end of the thesis as well as discussed further within the thesis proper. Work done on this thesis also contributed to another paper published in the literature (Turner, et al. 2016), which found alterations in electroencephalogram (EEG) activity during a motor task in pre-HD even though performance at that stage was not impaired, and correlated changes in EEG with shape abnormalities in the striatum.

### **1.5 Rationale for thesis**

This thesis presents an investigation into subcortical changes in HD and their relationship with clinical, motor, neurocognitive and neuropsychiatric outcomes, with the intention of advancing a biomarker for HD. Investigation focuses on specific “hubs and spokes” within the brain, providing a more comprehensive picture of HD as a whole and the interrelationship between neuroanatomical changes and functional outcomes. Further characterisation of changes in HD increases knowledge of neurodegenerative pathways and the relationship

between quantitative measures of morphology (morphometry) and function *in vivo*, constituting endophenotypes, and aims towards developing biomarkers for prognostication and use in HD treatment trials.

Statistical shape analysis of subcortical structures is emerging as a method to measure highly localised changes in neurodegenerative disease which may be missed by gross volumetric measurement (van den Bogaard, et al. 2011b). In this manner, shape analysis can help to extend knowledge of affected neural pathways (Looi and Walterfang 2012; van den Bogaard, et al. 2011b), as much is known about the topographical organisation of the striatum, hippocampus, and corpus callosum. The topographical organisation of the structures examined in this study lend themselves to shape analysis as they act as homunculi for changes in other parts of the brain, being a more constrained structure to analyse for broader brain patterns.

One particularly interesting question which may be answered by longitudinal shape analysis is whether neurodegeneration in HD occurs by spreading out from the striatum along corticostriatal pathways, or, as has more recently been proposed, whether the picture is more complicated and involves multiple points of co-occurring degeneration, as well as altered neurodevelopment (Younes, et al. 2012). If localised and spreading, there is potential for effective treatment or prevention of HD with a targeted approach, for example injected factors to enhance neuronal survival in the striatum. However if HD is more complex and multifaceted, as seems likely, then more systemic approaches will be needed (Younes, et al. 2012).

Consequently, we have considered the following, namely that: 1) morphological and neuropsychiatric change in HD will provide further knowledge of the link between structure, circuits and function; 2) increased knowledge of structural change in HD will allow biomeasures to be developed towards biomarkers for surrogate endpoints in treatment trials (Georgiou-Karistianis, et al. 2013c); and 3) development of disease-modifying treatments may eventually be informed by an understanding of the progression of subcortical neurodegeneration and how the trajectory of this may be modified by these treatments.

The central questions of this thesis are:

- Is there a difference between subcortical morphology in symp-HD, pre-HD, and controls?
- Do these change over time and progress in a determined pattern?
- Is there a relationship between shape change and motor and neurocognitive outcomes?
- Do these follow the expected relationships with known subcortical circuits in a topographical pattern?
- Can the picture of the above give a better understanding of the pathogenesis of HD and help with the development of a biomarker and endophenotype of HD?

### 1.6 Scope of thesis

**Table 1.2: Scope of thesis.** Investigation of the subcortical connectome in HD, with view to development of an endophenotype.

Study	Investigation	Rationale	Endophenotype components
<b>Study One</b>	Baseline analysis of neostriatum and	Key structure in HD and hub in frontostriatal circuitry	Genetics Morphology

	relationship with functional outcomes		Function
<b>Study Two</b>	Longitudinal analysis of neostriatal change	Morphological change over time, investigating potential biomarkers	Genetics Morphology Spatiotemporal signature
<b>Study Three</b>	Baseline analysis of hippocampus and relationship with functional outcomes	Further extension of subcortical connectome in a different but related hub, potential for compensation	Genetics Morphology Function
<b>Study Four</b>	Baseline and longitudinal analysis of the corpus callosum	Major spoke within the connectome, complementary information regarding degeneration	Genetics Morphology Spatiotemporal signature

*1.6.1 Study One: Baseline analysis of the neostriatum in Huntington disease, pre-HD, and the relationship between striatal morphology and motor and neurocognitive outcomes*

The first chapter of this thesis concerns a baseline shape analysis of the neostriatum in HD and the relationship between striatal morphology and motor and neurocognitive outcomes.

The outcomes tested were chosen based on their statistically significant differences between groups. Shape analysis consisted of two separate forms of computational analysis, one the Jacobian shape determinant and one the radial distance between the median line (called thickness for simplicity). Jacobian shape determinant is a more subtle analysis of shape changes from the outer curve, versus the simplicity of looking at distance from a median line, and so analysis differs slightly between these two computational forms.

We hypothesised that quantified measures of neostriatal morphology would significantly differ between controls and individuals with pre-HD and symp-HD. We also hypothesised that neostriatal morphological changes would be associated with cognitive, neuropsychiatric and motor outcomes according to known functional connections.

Chapter 1 has been published in *Psychiatry Research: Neuroimaging* (Wilkes, et al. 2019).

### *1.6.2 Study Two: Longitudinal analysis of shape change in the neostriatum in Huntington disease.*

We extended the findings from the study in Chapter 1 to look at longitudinal changes in shape in HD. Longitudinal shape analysis in this paper was based on the SPHARM method and manual tracing of the neostriatum, using alterations to manage statistical difficulties in longitudinal analysis and addressing limitations in the current literature. Mixed multiple analysis of variance was used to determine the effect of a number of important areas of interest, namely group membership, versus genetic burden via number of CAG repeats. We hypothesised that we would find similar results to those seen in pathological studies and in the preliminary longitudinal imaging studies, but that we would be able to see these changes in more detail using our advanced method and statistical analysis.

### *1.6.3 Study Three: Baseline analysis of the hippocampus in Huntington disease and relationship to antidepressant use, implications for neurogenesis.*

We extended study of subcortical shape analysis in HD to look at the hippocampus at baseline (via manual tracing and the SPHARM method). We also planned to analyse how any changes

were related to neurocognitive and neuropsychiatric outcomes, in particular whether there was any relationship between size/shape and hippocampal volume. Based on previous work we hypothesised that there would be subtle differences in hippocampal shape between pre-HD and controls, and between symp-HD and controls, but not between pre-HD and symp-HD. We also hypothesised that there would be a relationship between shape and depressive symptoms and that these changes would be attenuated by antidepressant, particularly SSRI use.

### *1.6.4 Study Four: Analysis of the corpus callosum in Huntington disease as a proxy measure for cortical changes.*

Finally, we chose to look at corpus callosum thickness in HD and any longitudinal changes and relationship with motor and neurocognitive outcomes. This analysis used an automated model to determine average callosal thickness based on the mid-sagittal slice, with difference from average thickness determined at all of 100 points along the line of the corpus callosum. This method was developed and implemented by a collaborator in Melbourne and provided a solution to the previous problem of analysing thickness around the genu and the splenium of the callosum. We hypothesised that this more sensitive method of investigation would allow subtle changes to be documented in pre-HD and symp-HD over time, thus revealing more insights about the pattern of neurodegeneration in HD and relationships with clinical and neurocognitive outcomes.

We will begin this thesis by presenting background to the main methods used in all four studies.



## **2. Methods**

This thesis uses data from the IMAGE-HD study to better understand subcortical changes in HD and how they relate to clinical and neurocognitive outcomes. This chapter first explains the IMAGE-HD study, and then provides an overview of the methods used in this thesis.

### **2.1 The IMAGE-HD Study**

#### *2.1.1 Subjects*

As part of the IMAGE-HD project (Georgiou-Karistianis, et al. 2013a), in 2008-2009 T1-weighted MRI scans were taken of 36 individuals with pre-HD, 37 with early symp-HD, and 36 healthy matched controls. A range of genetic and neurocognitive assessments were also performed by the IMAGE-HD group. Participants were followed up at 18 and 30 months for further testing. Healthy controls were matched for age, sex and IQ to the pre-HD individuals. All participants were right-handed and were free from brain injury, neurological and/or severe diagnosed psychiatric conditions other than HD.

7 controls, 3 pre-HD and 5 symp-HD dropped out of the study at 18 months, and a further 3 controls, 3 pre-HD and 3 symp-HD dropped out at 30 months, leaving 26 controls, 30 pre-HD, and 29 symp-HD at the end of the study. There are only two missing data points due to MRI scans which were unusable; these are from one control participant and one pre-HD participant at 30 months.

Pre-HD and symp-HD participants underwent gene testing prior to enrolment in the study and had CAG repeat lengths ranging from 39 to 50 (Table 2.1). All were clinically assessed using UHDRS motor subscale (Kiebertz, et al. 1996). HD participants were categorised as pre-HD if they had a UHDRS score of 5 or less (Tabrizi, et al. 2009). Years to onset of diagnostic motor symptoms were estimated via Langbehn's parametric survival model, based on the participant's age and number of CAG repeats (Langbehn, et al. 2004).

**Table 2.1: Selected demographic data from IMAGE-HD study**

	Mean $\pm$ SD		
	Controls (n=36)	Pre-HD (n=36)	Symp-HD (n=37)
Sex (M:F)	12:24	14:22	21:16
Age (years)	42.4 $\pm$ 13.4	41.7 $\pm$ 9.9	52.1 $\pm$ 9.3
CAG repeat number (range)		42 $\pm$ 2 (39-46)	43 $\pm$ 2 (40-50)
Years to onset (Langbehn method)		15.5 $\pm$ 7.0	
Years since diagnosis			2.0 $\pm$ 1.6
UHDRS motor score (range)		1 (0-4)	19 (6-60)

The study was approved by the Monash University and Melbourne Health Human Research Ethics Committees and informed written consent was obtained from each participant prior to testing in accord with the Helsinki Declaration. All testing was undertaken at the Royal Children's Hospital, Parkville, Melbourne, Australia.

### *2.1.2 Imaging*

Imaging was performed on a Siemens Magnetom Trio Tim System 3 Tesla scanner with a 32-channel head coil (Siemens AG, Erlangen, Germany) at the Murdoch Children's Research Institute (Royal Children's Hospital, Victoria, Australia). High-resolution T1-weighted images were acquired (192 slices, slice thickness of 0.9 mm, 0.8 mm 0.8 mm in-plane resolution 320 320 field of view, TI=900 ms, TE=2.59 ms, TR=1900 ms, flip angle=9°).

### *2.1.3 Motor, neurocognitive and neuropsychiatric assessments*

All participants underwent a battery of comprehensive neurocognitive and neuropsychiatric assessments, selected based on their sensitivity in previous large multi-site studies (Stout, et al. 2011; Tabrizi, et al. 2009). This included assessment of premorbid IQ, estimated from the National Adult Reading Test (Nelson and Willison 1991), cognitive function including visuo-motor speed and attention (SDMT (Smith 1982)), speeded reading (Stroop Word Test, (Stroop 1935)), and odour recognition (UPSIT (Doty, et al. 1984)). Participants completed behavioural questionnaires which included executive function (FrSBe (Stout, et al. 2003)) and psychiatric disturbances (SCOPI (Watson and Wu 2005), HADS A and HADS D (Zigmond and Snaith 1983), BDI II (Beck 1996)).

Motor speed and timing were assessed using speeded tapping and paced tapping tasks (Stout, et al. 2011). Variance in inter-trial interval in speeded tapping, ITISTAP, reflected 1/inter-tap interval (ITI) when participants tapped a finger as rapidly as possible during repeated 10 s intervals. Inter-trial interval in participant paced tapping (ITIPTAP) was assessed at two speeds, fast (3Hz) and slow (1.8Hz), where participants were asked to tap along to a paced tone and then to continue tapping after the tone disappeared.

### *2.1.4 Candidate's involvement in IMAGE-HD study*

The candidate planned, designed, coordinated and performed analysis of clinical and neuroimaging data derived from the IMAGE-HD study, specifically:

- 1) Morphometric structural neuroimaging analysis of caudate, putamen and hippocampus
- 2) Automated structural neuroimaging analysis of the corpus callosum.

### **2.2 Structural neuroimaging: manual tracing**

This thesis investigates the morphology of key parts of the subcortical connectome using volume, surface-based shape analysis, and thickness measures. A manual segmentation approach was used in this thesis to quantify neuroanatomical changes as this is considered the gold standard in the field, although automated methods are increasingly used in larger datasets due to manual segmentation's labour-intensive nature (Morey, et al. 2009; Power and Looi 2015). Manual segmentation produces volume metrics and binary images that can then be processed further using surface-based shape analysis techniques to give information on subtle localised morphological changes that may not be apparent using volume alone. For the corpus callosum however mid-sagittal thickness is analysed using a semiautomated segmentation technique.

Using the MRI scans above from IMAGE-HD, caudates, putamina, and hippocampi were traced according to previously established protocols described in detail below. For all, ANALYZE 11.0 (Mayo Foundation, Rochester, MI, USA) software is used to create 3D object maps of the structures that can be analysed for changes in volume and surface shape. The caudate and putamen were traced in the axial plane, while the hippocampus was traced

along the coronal plane. All brain MRI scans were analysed by one experienced tracer (FW), blinded to clinical information. Reliability of image analysis was assessed by intraclass correlation (ICC), which was evaluated by repeating right and left sided structural (caudate, putamen, hippocampus) measurements on 10 randomly selected scans (20 comparisons). Intra-rater intra-class correlations were 0.88-0.98.

### *2.2.1. Manual tracing of the caudate*

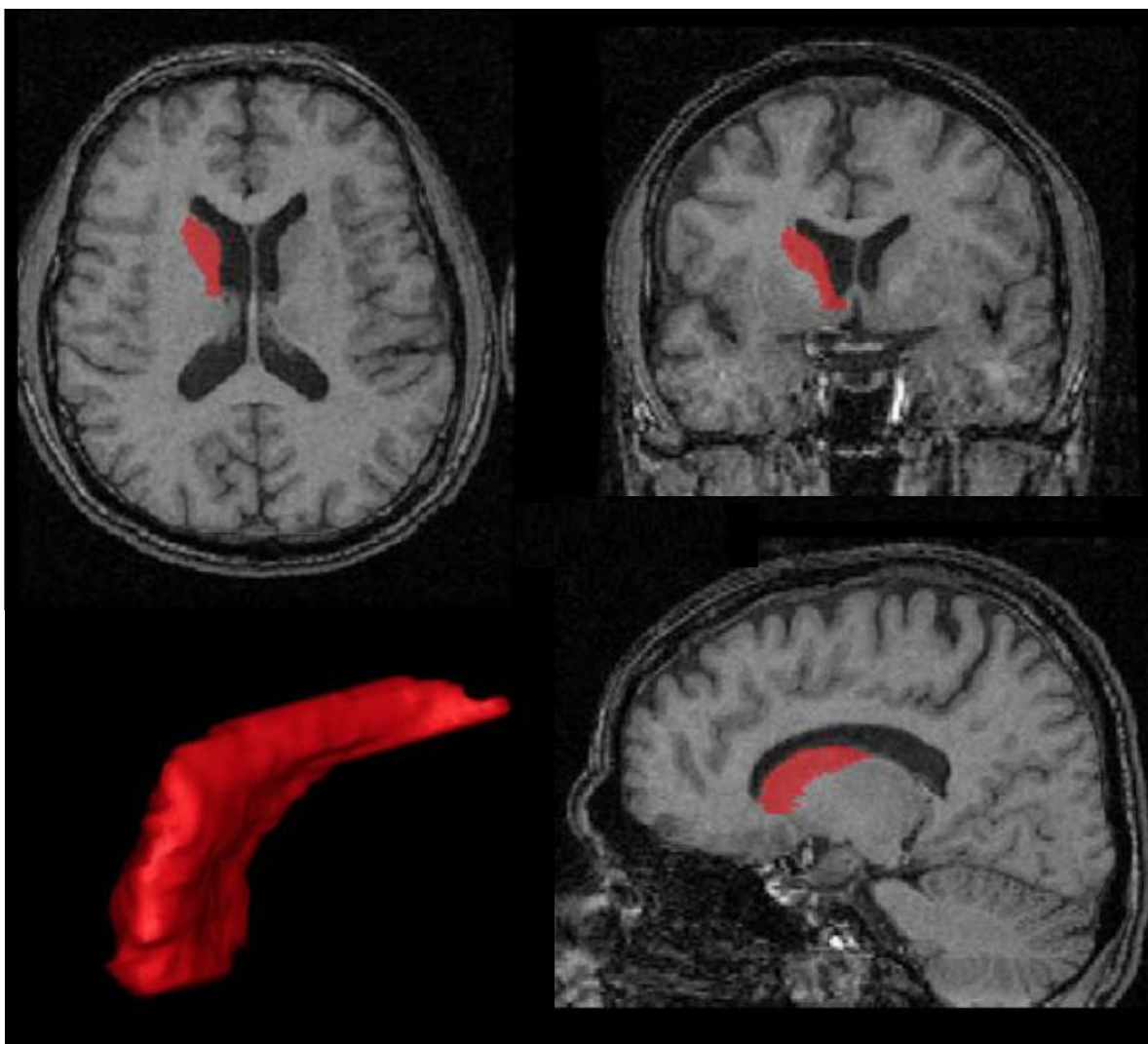
Manual tracing of the caudate is based on a previously published protocol (Figure 2.1) (Looi, et al. 2008). Tracing occurs in the axial plane and begins at the most inferior slice where the anterior commissure becomes visible as a solid line. At this point the caudate head is distinguishable from the putamen, separated by the internal capsule. The caudate is traced in successive slices moving superiorly. The medial border is the wall of the lateral ventricle and the lateral border is the internal capsule, and tracing continues superiorly until the caudate becomes a thin sliver along the lateral ventricle which then disappears.

### *2.2.2 Manual tracing of the putamen*

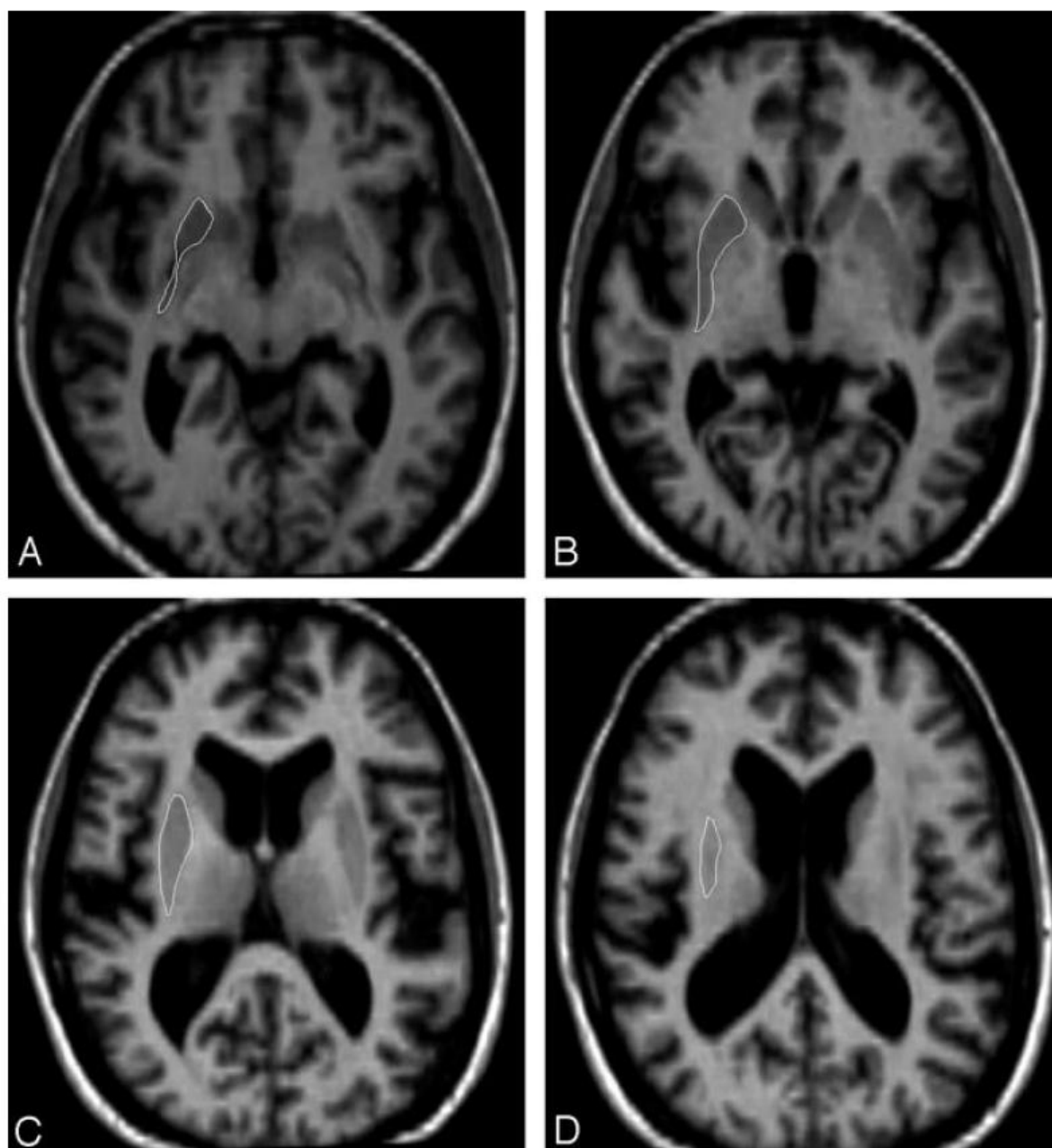
Manual tracing of the putamen is based on a previously published protocol (Looi, et al. 2009). Tracing begins on the same axial slice as the caudate, where the anterior commissure is first visible as a solid line and the caudate and putamen are separated by the anterior limb of the internal capsule. The putamen is traced in successive superior slices until it can no longer be seen. For inferior segments of the putamen the medial edge is the lamina separating putamen and globus pallidus, the lateral edge is the external capsule, and the anterior edge is the anterior limb of the internal capsule. As slices progress superiorly the globus pallidus

disappears and the putamen is bordered on its medial side by the anterior and inferior limbs of the internal capsule and on its lateral side by the external capsule.

Images for caudate and putamen are checked in the sagittal plane after tracing is complete in the axial plane and any errors are corrected, then saved for further shape processing described below.



**Figure 2.1: Manual tracing of the caudate.** Image reproduced and modified from (Looi, et al. 2008) with permission. Caudate shaded in red, with views from all planes, as well as the 3-dimensional image of the same.



**Figure 2.2: Manual tracing of the putamen.** Image reproduced and modified from (Looi, et al. 2009) with permission. Putamen outlined in white in the axial plane, from inferior (A) to superior borders (D).




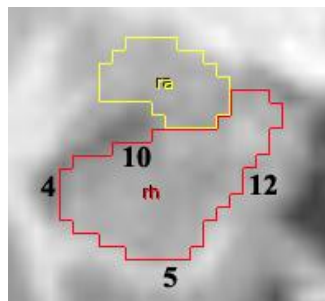
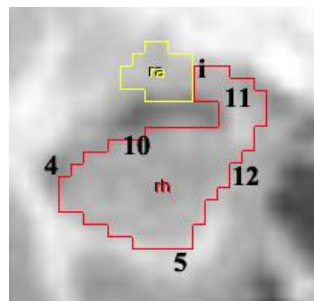
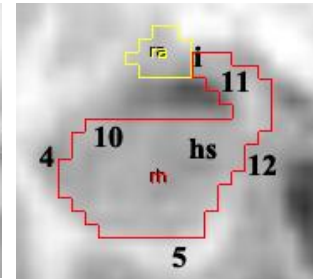
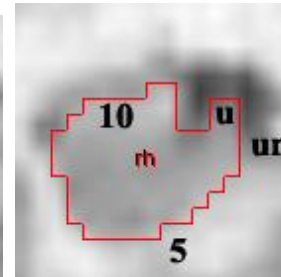

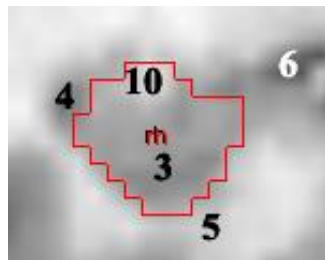
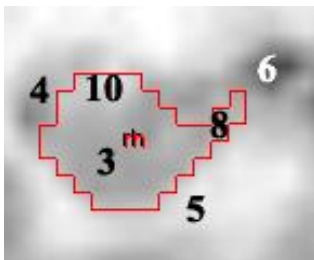

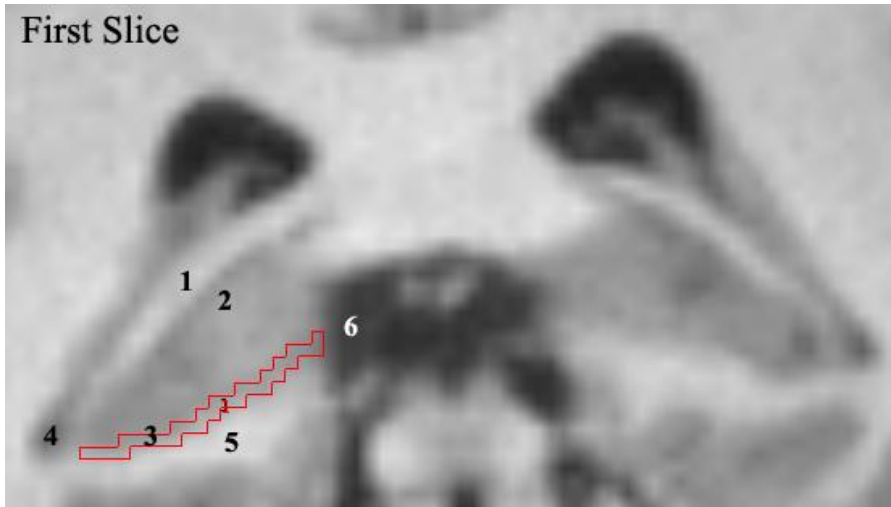
### *2.2.3 Manual tracing of the hippocampus*

Manual tracing of the hippocampus is done according to the Melbourne Brain Centre protocol for extracting hippocampal volume from 3D T1-weighted MRI volumes using the ANALYZE and FSL softwares; this protocol is similarly based on previously published results (Velakoulis, et al. 1999; Watson, et al. 1992). Unlike the caudate and putamen, the hippocampus is traced in the coronal plane from posterior to anterior, starting one slice before the crus of the fornix merges into the thalamus. Slices are then traced anteriorly until the hippocampus disappears and the amygdala appears. To align the images before tracing, all MRI images were aligned along the anterior commissure- posterior commissure (AC-PC) plane in FSL. Tracing was then performed using Analyze software.

Tracing of the hippocampus begins posteriorly just before the crux of the fornix becomes indistinctly separated from the thalamus (Figure 2.3). The inferior border of the hippocampus is the interface between the hippocampal grey matter and the parahippocampal gyrus white matter. The lateral border is the temporal/inferior horn of the lateral ventricle. The superior border includes any white matter superior to the hippocampal grey matter- more posteriorly this is the fornix until it becomes the fimbria and alveus more anteriorly. For the inferior to medial border initially the tracing includes a one-voxel thick line just superior to the white matter of the parahippocampal gyrus, connecting the hippocampal grey matter to the cerebrospinal fluid (CSF) of the quadrigeminal cistern. This line is not included once the CSF of the ambient cistern moves laterally to reach the medial aspect of the fimbria/alveus, as happens more anteriorly in the tracing.

Note that the subiculum is not included in this protocol. The uncus is traced once it appears more anteriorly, as is the hippocampal tail. Once the uncus appears, the medial border of the





**Figure 2.3: Manual tracing of the hippocampus.** MRI images from the Melbourne Brain Centre Protocol (Velakoulis, et al. 1999; Watson, et al. 1992). Manual tracing of the hippocampus in the coronal plane, from posterior (top left) to anterior (bottom right). 1. Crus of the fornix; 2. Thalamus; 3. Hippocampal grey matter; 4. Temporal horn of lateral ventricle; 5. Parahippocampal gyrus; 6. Quadrigeminal cistern; 7. CSF in the subarachnoid space of the transverse cerebral fissures/choroidal fissure; 8. One voxel thick tracing of inferior to medial border of hippocampus, from superior to parahippocampal gyrus until reaching the quadrigeminal cistern (not included once quadrigeminal cistern moves laterally to reach the fimbria/alveus); 9. Fornix; 10. Fimbria/alveus; 11. “Seahorse head” of the hippocampus; 12. Inferior/medial border of the hippocampus; i. Isthmus; ra. Amygdala; rh. Hippocampus; u. Uncus; un. Uncal notch

hippocampus becomes the uncal notch. As the amygdala appears anteriorly the hippocampus gains its characteristic “seahorse shape” and starts to shrink while the amygdala increases in size. They are initially connected by an isthmus, then more anteriorly are separated in tracing by a thin strip of white matter between the two structures. When this is not discernible, a straight diagonal line is drawn from the most superior tip of the temporal horn of the lateral ventricle to the semiannular sulcus. The hippocampus is traced until the temporal horn of the lateral ventricle is not visible, or when the temporal horn moves from a lateral to a completely inferior position.

### **2.3 Structural neuroimaging: Shape analysis**

Methods which assess three-dimensional shape of structures, including those described below, allow analysis of systematic effects and structural-functional correlations of subcortical structures in neurodegenerative disease. They can measure the surface of a

structure precisely, calculate average shapes within groups, and determine differences between groups and correlate with clinically relevant measures (Looi and Walterfang 2012). This forms a clinically useful step between large-scale network studies, which are challenging for multiple reasons (conceptually, computationally and practically), and simple volumetric studies, which yield little detail. They also provide finer anatomical detail than functional studies.

There are a number of potential ways to analyse and compare shapes of structures (Wang, et al. 2011): for simple structures this can be done by computing an intermediate mapping to a canonical space such as a sphere (spherical harmonic point distribution models, SPHARM-PDM, discussed in further detail below) (Styner, et al. 2006), while for more complicated structures large deformation diffeomorphic metric mapping (LDDMM) generates models based on template shapes (Qiu, et al. 2010), and surface tensor-based morphometry uses a tensor based morphometric framework (Chung, et al. 2008). Subcortical surfaces can also be registered to parametric meshes that are imposed on manually traced or automatically segmented boundaries, yielding shape statistics such as radial distance and local area differences (discussed in further detail below) (Gutman, et al. 2015; Gutman, et al. 2012).

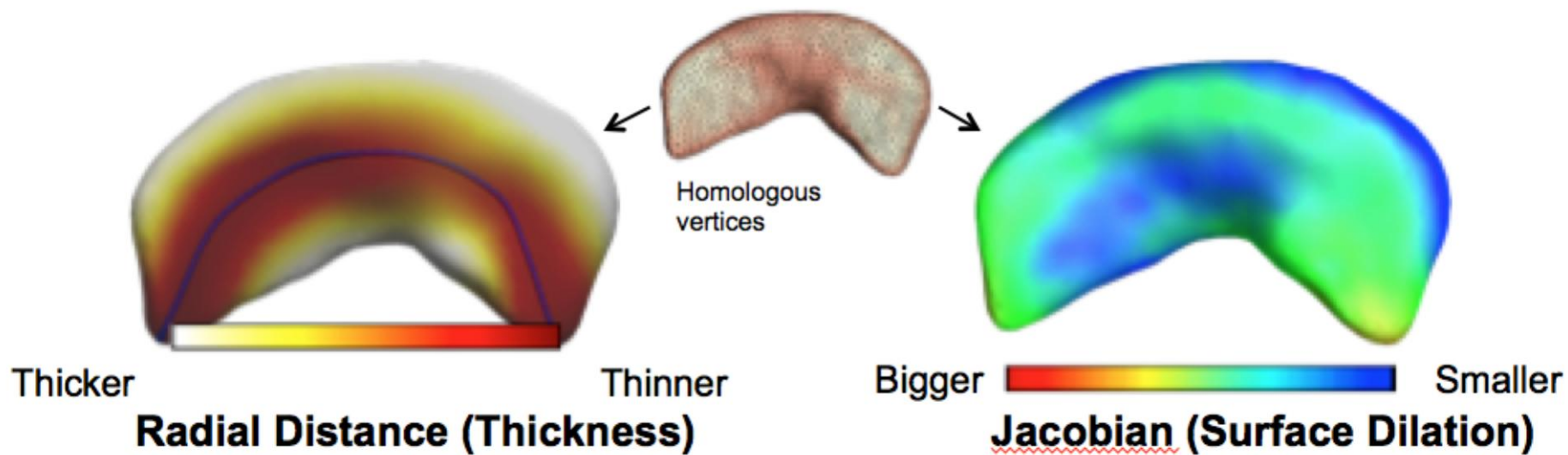
Methods discussed below focus on individual structures within the subcortical connectome, with emphasis on the strategic vulnerability of these structures, to develop a map of the connectome in HD and work towards development of an endophenotype (Looi, et al. 2014b). As these methods are specialised and technical, analyses were planned, designed and coordinated with the relevant specialists by the author, with specialist contributions discussed throughout the subsequent studies.

### *2.3.1 Radial thickness and Jacobian measures*

This method uses the manual tracings above to create shape models of the caudate and putamen. A surface-based parametric mapping protocol is used to derive two pointwise shape measures: thickness (radial distance) and the Jacobian determinant (JD- surface dilation ratio) are derived across thousands of points on the surface of the left and right caudate and putamen (Figure 2.4). The protocol is freely available at <http://enigma.ini.usc.edu/protocols/imaging-protocols/> and has been published elsewhere (Gutman, et al. 2015; Gutman, et al. 2012).

Thickness, or radial distance, is the local distance measure from medial curve to surface. This directly corresponds to localised volume, where thicker equals more local volume and vice versa. JD is the surface dilation ratio to template structure or local surface area (based on a template structure made from all shapes combined). JD is more reliable as it is made into a smoother measure, whereas Thickness is reportedly easier to interpret. Similarly, JD can capture the stretching/shrinking along the main axis of a region, whereas Thickness only examines radial expansion/contraction. The two measures together therefore provide complementary information that gives more detail than either measure alone (Gutman, et al. 2015; Gutman, et al. 2012). For further discussion, see for example (Tate, et al. 2016; Thompson, et al. 2004; Wang, et al. 2011).

Only shape models that pass visual inspection and that conform to T1-weighted MRI neuroanatomical boundaries using the ENIGMA Shape Analysis Quality Assessment Protocol are used in the analysis. Using the R package *lm* version 3.0.2, a multiple linear regression is fit at each thickness and Jacobian point to test for group differences and associations with clinical features. All analyses are adjusted for age, sex, and intracranial volume. A standard



**Figure 2.4: Visual representation of radial thickness and Jacobian measures of morphological change.** Shape models are created based on manual tracing of caudate and putamen, with two pointwise shape measures (radial thickness and Jacobian surface dilation) derived across thousands of points on the surface.

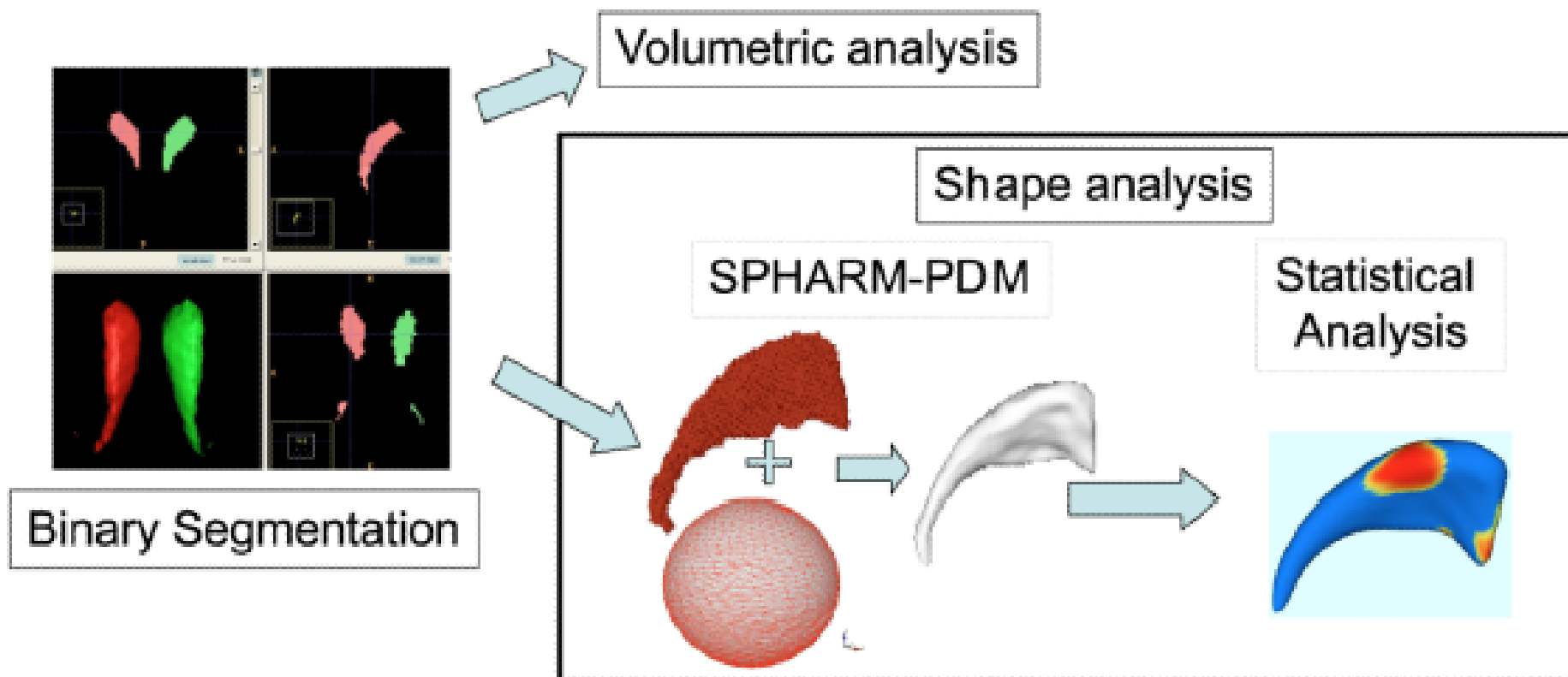
false discovery rate (FDR) correction is applied at the accepted level of 5% ( $q=0.05$ ) and implemented in the R function *p.adjusted*.

### *2.3.2 SPHARM-PDM longitudinal image processing*

As there is currently no available method of longitudinal shape analysis using JD or Thickness protocols, the SPHARM-PDM method was modified so as to be able to look at morphological change over time. The SPHARM-PDM approach uses spherical harmonics to map a sphere mesh onto the target segmentation (Figure 2.5). This produces one-to-one mapping of surface vertices and makes possible a comparison of object average surfaces between groups.

Traced structures are processed for shape analysis using the SPHARM-PDM analysis software (<https://www.nitrc.org/projects/spharm-pdm/>) (Styner, et al. 2006). Segmented 3D binaries are smoothed with a 1mm Gaussian kernel and spherical harmonics are used to generate 1002 corresponding surface points (Levitt, et al. 2009; Styner, et al. 2006). An average shape is created using the control participants at the baseline time, and all structures are aligned to this mean shape using Procrustes alignment. For each participant at each time point, the signed magnitude of displacement along the surface normal from the mean shape is calculated. This displacement vector is used in subsequent shape analysis.

Displacement vector values are used as the dependent variables in all analyses, and thus all analyses are conducted across the 1002 corresponding points for each structure. Linear mixed models are utilised with a random intercept to account for repeated time effects. Predominant interest is in group and time differences. For between group comparisons, effects of group,



**Figure 2.5: Schematic view of SPHARM-PDM pipeline** (Styner, et al. 2006). Bilateral caudates are shown, from binary segmentation (red and green), through to SPHARM-PDM and statistical analysis.

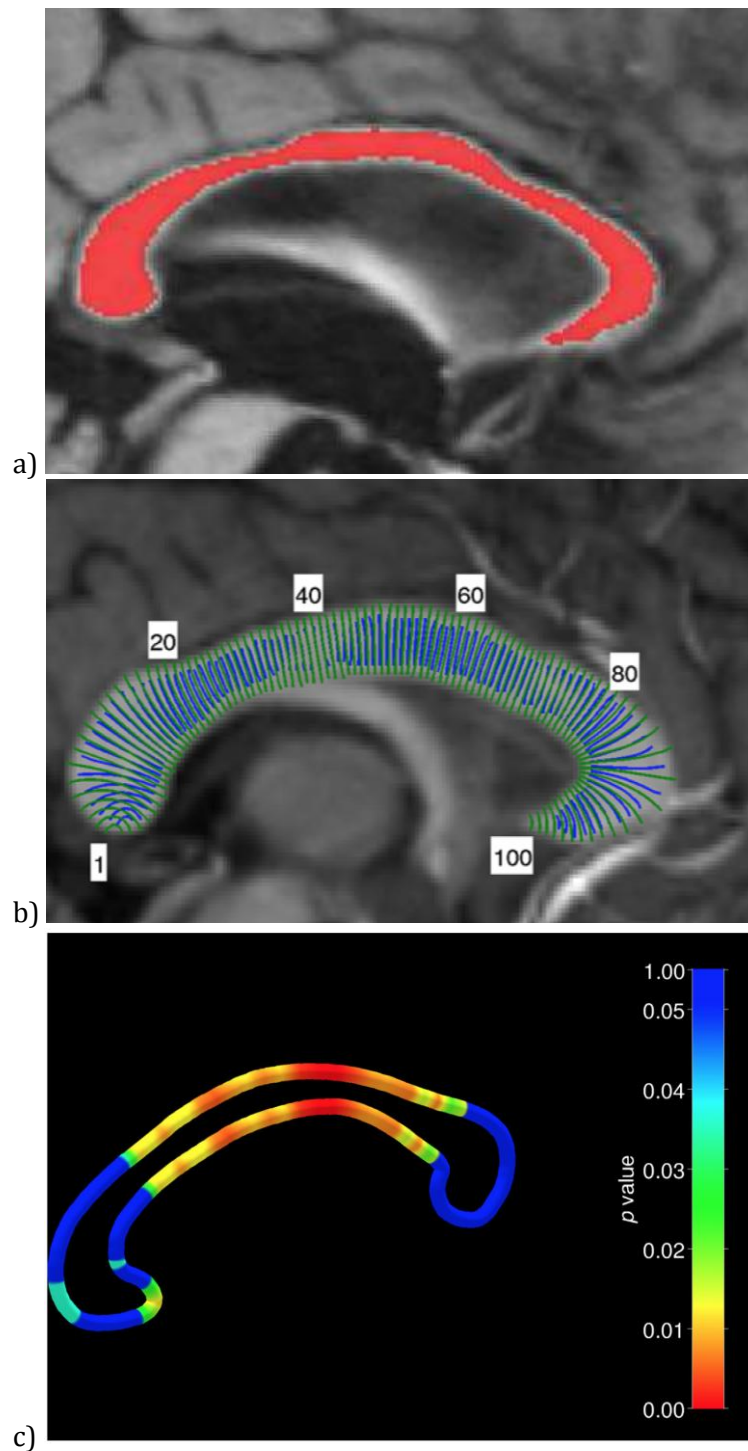
time, and the interaction between the two are examined. For covariate analyses (CAG repeats), group by covariate interaction, time by covariate interaction, and three-way group, time and covariate interactions are examined. In all analyses age at baseline scan, sex and ICV at time of scan are used as covariates. P-values across each shape are corrected using FDR with  $q < 0.05$ .

### **2.4 Measuring and analysing callosal thickness**

Thickness profiles for each midsagittal corpus callosum (CC) were generated from the 3D T1-weighted images using a fully automated pipeline (Adamson, et al. 2014). The thickness of corpus callosum (thickness profile) is determined by segmenting the midsagittal corpus callosum, then computing mid-points running from anterior to posterior so that streamlines can be generated to determine thickness profiles (Adamson, et al. 2014; Adamson, et al. 2011) (Figure 2.6).

Midsagittal plane extraction is performed using alignment to a template. The CC segmentation method consisted of template-based initialisation followed by refinement using a cascade of mathematical morphology operations, then manual editing is performed to correct errors. 100 streamlines are next generated at evenly spaced intervals, running orthogonally along the anterior-posterior trajectory through mid-line from superior to inferior CC. These are non-overlapping nominally parallel lines, the angle of which, running from the superior to inferior borders of the CC, is determined by Laplace's equation (Adamson, et al. 2011). Laplacian methods, previously used to robustly measure cortical thickness in highly curved areas such as sulci and gyri, generate streamlines that do not cross each other and are more representative of true thickness in these structures (Adamson, et al. 2011). From these





**Figure 2.6: Measuring midsagittal callosal thickness.** Method and pictures from (Adamson, et al. 2014). a) The corpus callosum is first semi-automatically segmented in the midsagittal plane. b) Thickness streamlines are drawn at 100 nodes along the corpus callosum, using Laplace’s equation to determine the angle of the lines. c) Statistical results are displayed on a 3D tube surface that follows an “ideal” CC boundary. Here, example p-values are displayed along the surface.

100 streamlines along the CC, the distances to superior and inferior borders are measured and can be used as markers of regional and overall thickness and compared amongst groups.

Thickness profiles are compared utilising two-sample Welch's T-test, with age and ICV accounted for via regression. As sex differences in CC volume are largely due to variation in brain size, this was controlled for using ICV (Luders, et al. 2014). Multiple comparisons are corrected for via correction for the FDR. Correlations are performed between thickness profiles at each of the nodes with clinical and neurocognitive outcomes, utilising FDR to correct for multiple comparisons. The pipeline for this is available at [www.nitrc.org/projects/ccsegthickness](http://www.nitrc.org/projects/ccsegthickness).

### 3. Study One: Baseline striatal morphology in HD

The first study in this thesis investigates the morphology of the striatum in HD and the relationship between morphology and motor and neurocognitive outcomes which are known to be subserved by frontostriatal circuits.

**Table 3.1: Study One.** Beginning the investigation of the subcortical connectome in HD through a baseline analysis of the neostriatum and its relationship with functional outcomes.

<b>Study</b>	<b>Investigation</b>	<b>Rationale</b>	<b>Endophenotype components</b>
<b>Study One</b>	<i>Baseline analysis of neostriatum and relationship with functional outcomes</i>	<i>Key structure in HD and hub in frontostriatal circuitry</i>	<i>Genetics Morphology Function</i>
<b>Study Two</b>	Longitudinal analysis of neostriatal change	Morphological change over time, investigating potential biomarkers	Genetics Morphology Spatiotemporal signature
<b>Study Three</b>	Baseline analysis of hippocampus and relationship with functional outcomes	Further extension of subcortical connectome in a different but related hub, potential for compensation	Genetics Morphology Function
<b>Study Four</b>	Baseline and longitudinal analysis of the corpus callosum	Major spoke within the connectome, complementary information regarding degeneration	Genetics Morphology Spatiotemporal signature

The following chapter has been published previously. It appears here with small amendments in format to match the overall structure of this thesis, as well as some minor alterations to help with clarity and with fitting in to the broader context of the thesis proper. Publications details are: Striatal morphology and neurocognitive dysfunction in Huntington disease: The IMAGE-HD study. *Psychiatry Research: Neuroimaging*, 291, 1-8

<https://doi.org/10.1016/j.psychresns.2019.07.003>, with the full paper also attached as an

Appendix to this thesis.

**Title:**

**Striatal morphology and neurocognitive dysfunction in Huntington disease: The IMAGE-HD study.**

**Authors:**

Fiona A. Wilkes<sup>1</sup>, Zvart Abaryan<sup>2</sup>, Chris R.K. Ching<sup>2</sup>, Boris A. Gutman<sup>2,3</sup>, Sarah K. Madsen<sup>2</sup>, Mark Walterfang<sup>4,5,6</sup>, Dennis Velakoulis<sup>4,5</sup>, Julie C. Stout<sup>7</sup>, Phyllis Chua<sup>8</sup>, Gary F. Egan<sup>7,9</sup>, Paul M. Thompson<sup>2,10</sup>, Jeffrey C.L. Looi<sup>1,4</sup>, Nellie Georgiou-Karistianis<sup>7</sup>

**Affiliations:**

<sup>1</sup> Academic Unit of Psychiatry and Addiction Medicine, the Australian National University Medical School, Canberra Hospital, Yamba Drive, Garran, ACT 2605, Australia

<sup>2</sup> Imaging Genetics Center, Department of Neurology, Stevens Institute for Neuroimaging & Informatics, Keck School of Medicine, University of Southern California, 4676 Admiralty Way, Ste. 200, Health Sciences Campus, Marina del Rey, CA, USA

<sup>3</sup> Department of Biomedical Engineering, Illinois Institute of Technology, 3255 South Dearborn St., Wishnick Hall, Suite 314, Chicago, IL 60616, USA

<sup>4</sup> Melbourne Neuropsychiatry Centre, Royal Melbourne Hospital and University of Melbourne, Level 3 Alan Gilbert Building, 161 Barry St., Calton, VIC 3053, Australia

<sup>5</sup> Neuropsychiatry Unit, Level 2, John Cade Building, Royal Melbourne Hospital, VIC 3050, Australia

<sup>6</sup> Florey Institute of Neuroscience and Mental Health, 30 Royal Parade, Parkville, VIC 3052, Australia

<sup>7</sup> School of Psychological Sciences and Monash Institute of Cognitive and Clinical Neurosciences, 18 Innovation Walk, Clayton Campus, Wellington Road, Monash University, VIC 3800, Australia

<sup>8</sup> Department of Psychiatry, School of Clinical Sciences, Monash University, Monash Medical Centre, Block P, Level 3 246 Clayton Road, Clayton, VIC 3168, Australia

<sup>9</sup> Monash Biomedical Imaging, 770 Blackburn Road, Building 220, Monash University, Clayton, VIC 3800, Australia

<sup>10</sup> Departments of Neurology, Psychiatry, Radiology, Engineering, Pediatrics and Ophthalmology, University of Southern California, CA, USA

#### **Author contributions:**

F.A. Wilkes performed the manual segmentation of the neostriatum, coordinated and directed the imaging analysis and wrote the bulk of the manuscript (>80% of total work). Z. Abaryan, C.R.K. Ching and B.A. Gutman performed the imaging analysis under the supervision of P.M. Thompson. J.C. Stout, P.Chua, G.F. Egan, and N. Georgiou-Karistianis were integral to the development and implementation of the overall IMAGE-HD project, of which this study is a sub-project. N. Georgiou-Karistianis is the primary investigator of the IMAGE-HD project and along with M. Walterfang and D. Velakoulis contributed to project design and is a PhD co-supervisor of F.A. Wilkes; J.C.L. Looi contributed to project design and coordination and is F.A. Wilkes' main PhD supervisor. All authors had significant intellectual and practical input into the final manuscript.

#### **3.1 Abstract**

We aimed to investigate the relationship between striatal morphology in Huntington disease (HD) and measures of motor and cognitive dysfunction. MRI scans, from the IMAGE-HD study, were obtained from 36 individuals with pre-HD, 37 with early symp-HD, and 36 healthy matched controls. The neostriatum was manually segmented and a surface-based parametric mapping protocol derived two pointwise shape measures: thickness and surface dilation ratio. Significant shape differences were detected between all groups. Negative

associations were detected between lower thickness and surface area shape measure and CAG repeats, disease burden score, and UHDRS total motor score. In symp-HD, UPSIT scores were correlated with higher thickness in left caudate tail and surface dilation ratio in left posterior putamen; Stroop scores were positively correlated with the thickness of left putamen head and body. Self-paced tapping (slow) was correlated with higher thickness and surface dilation ratio in the right caudate in symp-HD and with bilateral putamen in pre-HD. Self-paced tapping (fast) was correlated with higher surface dilation ratio in the right anterior putamen in symp-HD. Shape changes correlated with functional measures subserved by corticostriatal circuits, suggesting that the neostriatum is a potentially useful structural basis for characterisation of endophenotypes of HD.

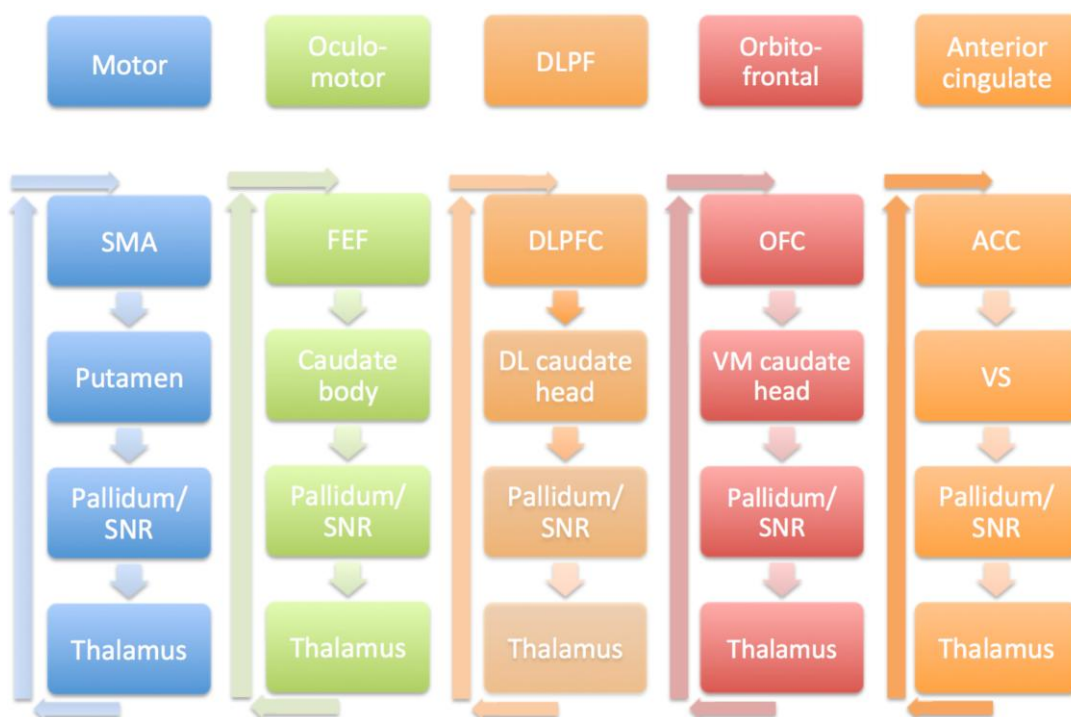
## **3.2 Introduction**

### *3.2.1 The role of the striatum in Huntington Disease*

Huntington Disease (HD) is caused by a genetic mutation in the *huntingtin* gene, and leads to progressive and currently irreversible motor, psychiatric and cognitive decline (Vonsattel, et al. 1985). Multiple studies are utilising clinical, cognitive, neuropsychiatric, and imaging data to better understand the progression of HD, and to identify biomarkers for use as endpoints in clinical trials (Georgiou-Karistianis, et al. 2013a; Georgiou-Karistianis, et al. 2013c; Paulsen, et al. 2008; Tabrizi, et al. 2009). Atrophy of the neostriatum (caudate nucleus and putamen) has been well established in pre-HD more than a decade prior to disease onset (see (Georgiou-Karistianis, et al. 2013a; Paulsen, et al. 2008; Tabrizi, et al. 2009; van den Bogaard, et al. 2011a)), and becomes more pronounced as individuals approaches clinical diagnosis

(Dominguez, et al. 2013; Dominguez, et al. 2016; Georgiou-Karistianis, et al. 2013a; van den Bogaard, et al. 2011b).

The neostriatum is a crucial hub in corticostriatocortical re-entrant circuits that regulate cognition, emotion, behaviour and motor functions (Figure 3.1) (Draganski, et al. 2008). Structural changes in the striatum may disrupt these corticostriatal pathways (Looi and Walterfang 2012) leading to changes in motor function and related cognitive and neuropsychiatric outcomes in HD (van Duijn, et al. 2007). These circuits are structurally and functionally organised in the striatum in a topographic pattern (Bohanna, et al. 2011a; Haber 2003).



**Figure 3.1: Frontostriatal re-entrant circuits.** Based on Alexander, 1986 (Alexander, et al. 1986). SMA, supplementary motor area; SNR, substantia nigra pars reticulata; FEF, frontal eye fields; DLPF/C, dorsolateral prefrontal/cortex; DL, dorsolateral; OFC, orbitofrontal cortex; VM, ventromedial; ACC, anterior cingulate cortex; VS, ventral striatum.

HD studies that relate genetic and neuroanatomical measures to clinical outcomes may offer insight into disease mechanisms (Gottesman and Gould 2003). In part, motor dysfunction arises from structural alteration to, or atrophy in, corticostriatal circuit components, including the striatum. Structural atrophy may also be related to the severity of genetic loading as characterised by polyglutamine (CAG) repeat length in the *huntingtin* gene, which has been used in the literature to compute a disease burden score [DBS (CAG length – 35.5) × age] (Georgiou-Karistianis, et al. 2013c). CAG repeat length has long been known to be related to age of onset of disease, with longer repeat length related to earlier onset of motor symptoms of disease (Andrew, et al. 1993; Langbehn, et al. 2004). However, this is thought to account for only around 40-70% of the variance in age of disease onset, with other genes and environmental factors also presumed to play an important role (Ross and Tabrizi 2011; Wexler, et al. 2004).

Changes in striatal morphology have long been observed both in neuropathological and imaging studies of HD (Looi, et al. 2012; Tang, et al. 2019; van den Bogaard, et al. 2011b; Vonsattel, et al. 1985; Younes, et al. 2012). However, to our knowledge, very few studies have investigated the relationship between striatal shape or subregional specific volume changes and measures of dysfunction (Bohanna, et al. 2011a; Kim, et al. 2017; Turner, et al. 2016). Shape analysis is emerging as a potential endophenotype for multiple psychiatric and neurodegenerative diseases, allowing a more nuanced view of the interplay between structure and function (for review, see (Looi, et al. 2014b)). It has the advantage over pure volumetric analysis as it can elucidate subregional structural changes, in multiple disorders, which may not be apparent when looking at volume alone (Berner, et al. 2019; Tang, et al. 2019; Tate, et al. 2019). Further characterisation of these changes will improve knowledge of HD-associated neurodegenerative pathways and provide further insight to relate quantitative measures of



morphology (morphometry) to function. Measures of structural change in HD may also serve as biomarkers or surrogate endpoints for treatment trials (Georgiou-Karistianis, et al. 2013c), and importantly, development of future disease-modifying treatments may be further informed by an understanding of the progression of subcortical neurodegeneration.

#### *3.2.2 Aims and hypotheses*

In this investigation we aimed to characterise neostriatal changes in individuals with pre-HD and symp-HD compared to healthy controls, and to correlate changes with measures of clinical, motor, cognitive, and neuropsychiatric function. We hypothesised that quantified measures of neostriatal morphology would significantly differ between controls and individuals with pre-HD and symp-HD. We also hypothesised that neostriatal morphological changes would be associated with cognitive, neuropsychiatric and motor outcomes according to known functional connections.

### **3.3 Methods**

#### *3.3.1 Subjects and measures*

Participants for this study, and all measurements, were acquired as part of the IMAGE-HD study (Georgiou-Karistianis, et al. 2013a). Participants included 36 individuals with pre-HD, 37 with early symp-HD, and 36 healthy matched controls. Healthy controls were matched for age, sex, and IQ (Nelson and Willison 1991) to the pre-HD individuals. All participants were right-handed and were free from brain injury, neurological and/or severe diagnosed psychiatric conditions (e.g. bipolar disorder, psychosis) other than HD. All pre-HD and symp-

HD participants underwent a UHDRS motor assessment (Huntington Study Group 1996); inclusion in the pre-HD group required a UHDRS total motor score of  $\leq 5$ . Estimated years to clinical onset was based on the participant's age and the number of CAG repeats on the expanded allele (Langbehn, et al. 2004).

A battery of neurocognitive tests were administered on the day of scanning that were selected based on their sensitivity in detecting differences between groups from previous large scale multi-site studies (Stout, et al. 2011; Tabrizi, et al. 2009). The tests assessed visuo-motor speed and attention (SDMT (Smith 1982)), speeded reading (Stroop Word Test, (Stroop 1935)), odour recognition (UPSIT (Doty, et al. 1984)) and motor performance (speeded tapping and self-paced tapping tasks (Stout, et al. 2011) - inter-trial interval in speeded tapping, ITISTAP; inter-trial interval in participant passed tapping, slow 1.8 Hz, ITIPTAP slow average; and inter-trial interval in participant passed tapping, fast 3 Hz, ITIPTAP fast average). Participants completed behavioural questionnaires which included assessments of behaviours associated with frontal-striatal brain dysfunction, including executive function (FrSBe (Stout, et al. 2003)) and psychiatric disturbances (SCOPI (Watson and Wu 2005), HADS A and HADS D (Zigmond and Snaith 1983), BDI II (Beck 1996)).

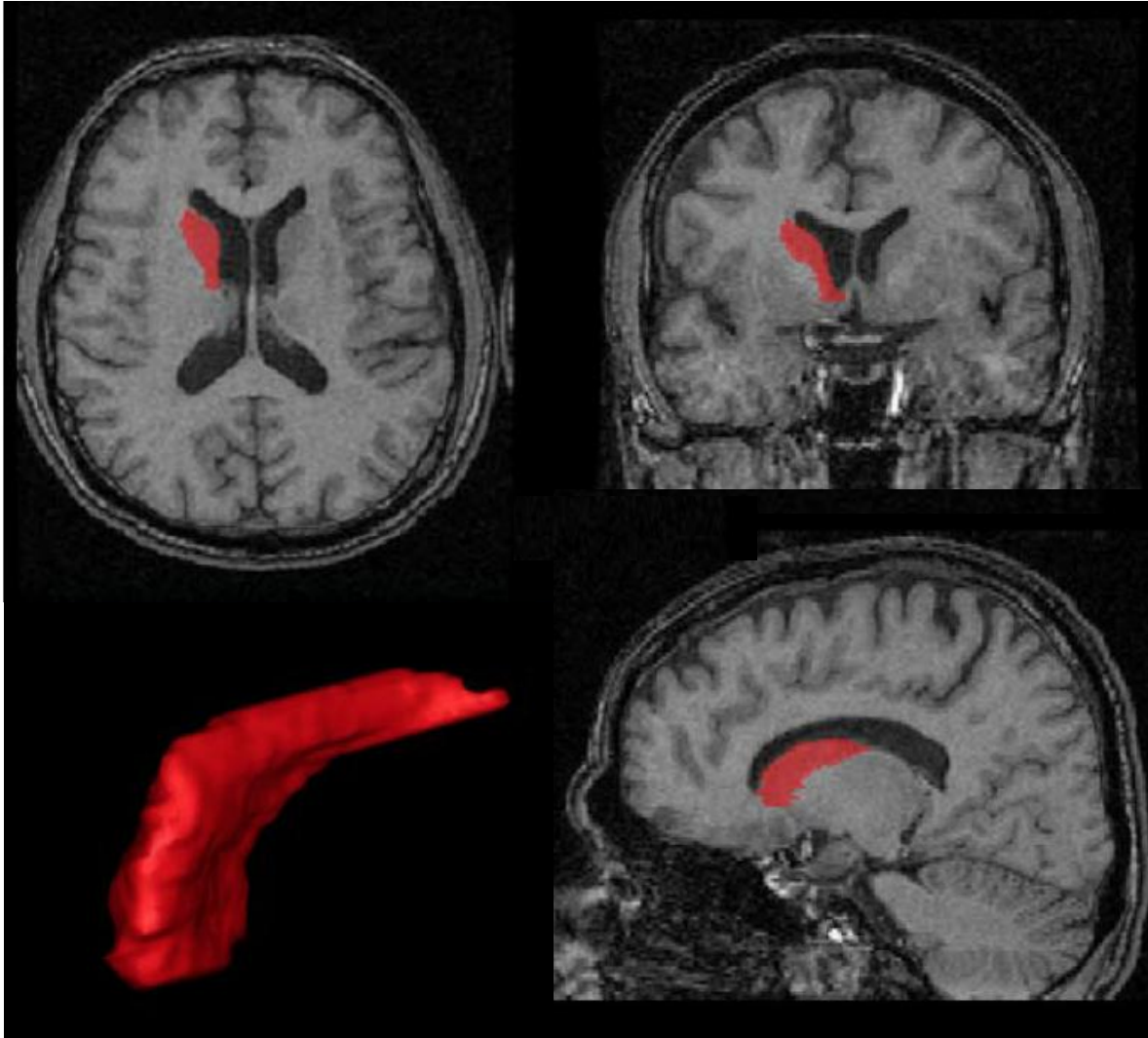
The IMAGE-HD study was approved by the Monash University and Melbourne Health Human Research Ethics Committees; informed written consent was obtained from each participant prior to testing in accord with the Helsinki Declaration. All testing was undertaken at the Royal Children's Hospital, Parkville, Melbourne, Australia. Ethics approval for this sub-project was obtained from Monash University and the Australian National University.

#### *3.3.2 Imaging*

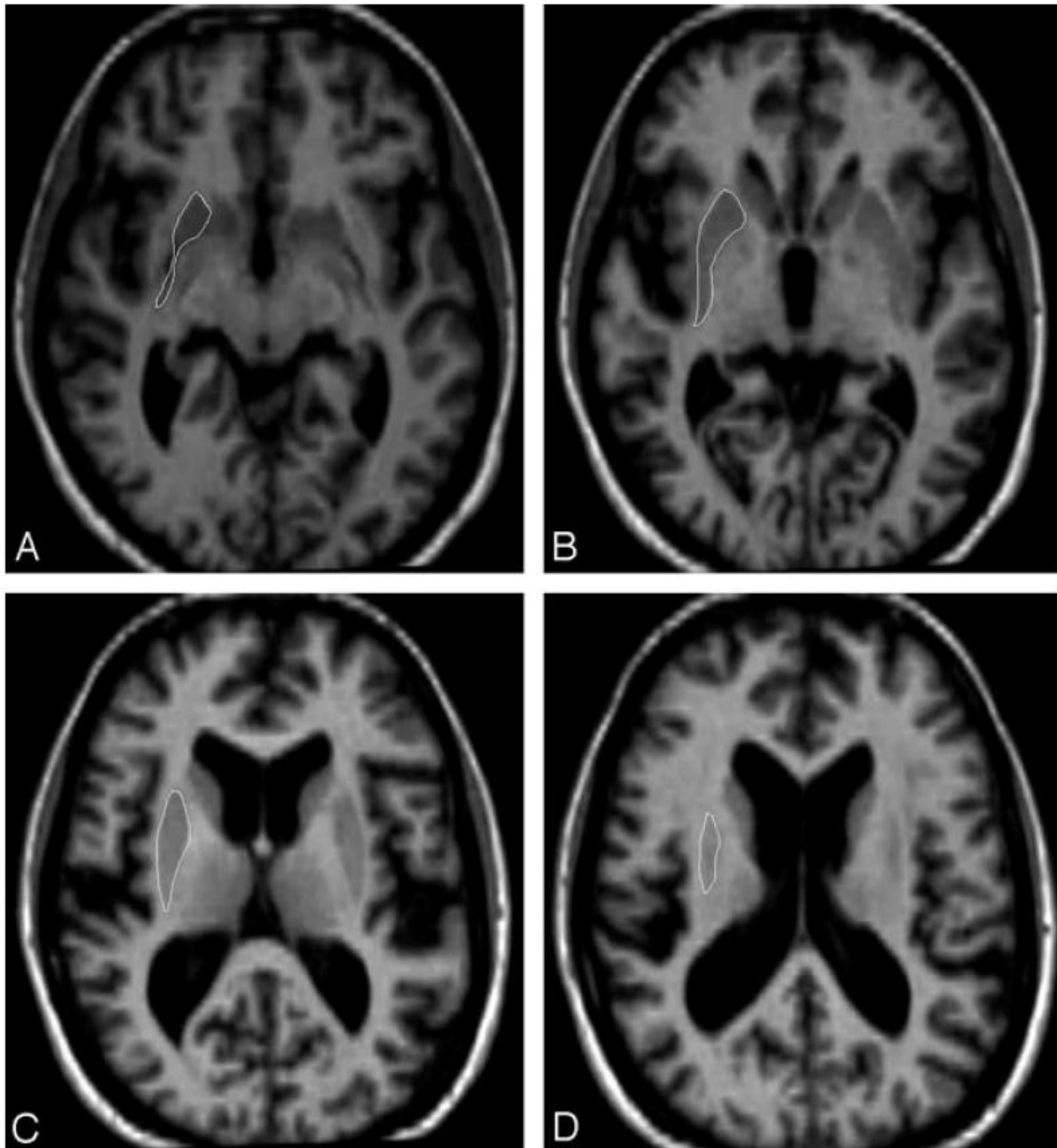
Imaging was performed on a Siemens Magnetom Trio Tim System 3 Tesla scanner with a 32-channel head coil (Siemens AG, Erlangen, Germany) at the Murdoch Children's Research Institute (Royal Children's Hospital, Victoria, Australia). High-resolution T1-weighted images were acquired (192 slices, slice thickness of 0.9 mm, 0.8 mm x 0.8 mm in-plane resolution, 320 x 320 mm field of view, TI=900 ms, TE=2.59 ms, TR=1900 ms, flip angle=9°). No participants were excluded on the basis of poor quality scans or missing data.

#### *3.3.3 Volumetric analysis*

Neostriatal volumes for each scan were measured by a single trained researcher (FW) using manual segmentation according to a validated protocol (intra-rater intraclass correlation 0.88-0.98) (Looi, et al. 2008; Looi, et al. 2009) and ANALYZE 11.0 (Mayo Foundation, Rochester, MI, USA) software. Details of the protocol have been published previously (Looi, et al. 2008; Looi, et al. 2009)- briefly, these are performed in native space and trace both the caudate and putamen separately in the axial plane from a starting point at the level of the anterior commissure, then every slice superiorly until their upper boundaries (Figure 3.2, 3.3). This method misses the nucleus accumbens/more limbic areas, and traces only the neostriatum proper.



**Figure 3.1: Manual tracing of the caudate.** Image reproduced and modified from (Looi, et al. 2008) with permission. Caudate shaded in red, with views from all planes, as well as the 3-dimensional image of the same.



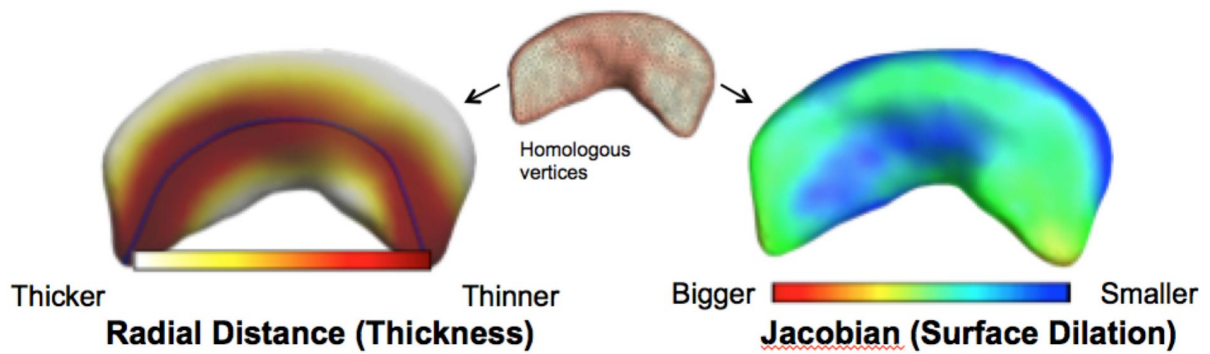
**Figure 3.3: Manual tracing of the putamen.** Image reproduced and modified from (Looi, et al. 2009) with permission. Putamen outlined in white in the axial plane, from inferior to superior borders.

Statistical analysis of volume and other baseline data was performed using SPSS 20.0 (Chicago, Ill., USA) and significance was set at  $P < 0.05$ . Multivariate analysis of covariance (MANCOVA) was used to test statistical significance between the subject groups with age, sex and intracranial volume (ICV) as covariates (Table 3.2). ICV was calculated from outputs from FMRIB's Software Library FSL 4.1.6 1, for more details see (Georgiou-Karistianis, et al. 2013a). Preliminary checks were conducted to ensure there was no violation of assumptions of normality, homogeneity of variances, and reliable measurement of the covariate.

#### *3.3.4 Shape analysis*

A surface-based parametric mapping protocol derived two pointwise shape measures from the manual tracing above: thickness (radial distance) and the Jacobian determinant (surface dilation ratio) were derived across 2502 points on the surface of each of the left and right caudate and putamen. The protocol is freely available at <http://enigma.ini.usc.edu/protocols/imaging-protocols/> (Figure 3.4) (Gutman, et al. 2015; Gutman, et al. 2012).

Striatal shape atlases were created from the manual segmentations first, and then the ENIGMA shape pipeline was modified to use these instead of free-surfer based atlases. Briefly, thickness, or radial distance, is a local distance measure from the medial curve to the surface. The Jacobian determinant is the surface dilation ratio relative to template structure, or a measure of the local surface area (relative to a template structure made from all manually traced shapes combined). For clarity in results/discussion, radial distance will be referred to as “thickness” and the Jacobian determinant will be referred to as surface expansion/contraction.



**Figure 3.4: Visual representation of radial thickness and Jacobian measures of morphological change.** Shape models are created based on manual tracing of caudate and putamen, with two pointwise shape measures (radial thickness and Jacobian surface dilation) derived across thousands of points on the surface.

Only shape models that passed visual inspection and that conformed to T1-weighted MRI neuroanatomical boundaries using the ENIGMA Shape Analysis Quality Assessment Protocol were used (<http://enigma.ini.usc.edu/protocols/imaging-protocols/>). Using the R package *lm* version 3.0.2, a multiple linear regression was fit at each thickness and Jacobian point to test for group differences and associations with clinical features. All analyses were adjusted for age, sex, and intracranial volume. A standard FDR correction was applied at the accepted level of 5% ( $q=0.05$ ), as implemented in the R function *p.adjusted*.

### 3.4 Results

#### 3.4.1 Demographics and clinical details

Group differences were assessed with non-parametric tests (Table 3.2). There were significant differences between groups in measures of self-paced tapping (1.8 Hz and 3 Hz), SDMT,

speeded tapping, UPSIT and Stroop ( $p < 0.001$ ) and BDI-II ( $p < 0.05$ ), but not in ICV, verbal IQ, SCOPI total OCD, FRSBE, or HADS anxiety or depression. Mann-Whitney U tests revealed significant differences between all three groups in all motor tests and in SDMT ( $p \leq 0.017$ ). There were also significant differences between symp-HD and both controls and pre-HD in UPSIT and in Stroop ( $p \leq 0.017$ ), and a significant difference between symp-HD and controls on the BDI-II ( $p \leq 0.017$ ).

**Table 3.2: Demographic and selected data across groups.**<sup>†</sup>

	Mean $\pm$ SD		
	Controls (n=36)	Pre-HD (n=36)	Symp-HD (n=37)
<u>Covariates and clinical information:</u>			
Sex (M:F)	12:24	14:22	21:16
Age (years)	42.4 $\pm$ 13.4	41.7 $\pm$ 9.9	52.1 $\pm$ 9.3
ICV (cm <sup>3</sup> )	1456.4 $\pm$ 143.5	1414.7 $\pm$ 156.8	1400.8 $\pm$ 155.7
CAG repeat number		42 $\pm$ 2 (range 39-46)	43 $\pm$ 2 (range 40-50)
Disease Burden Score (DBS)		269.4 $\pm$ 52.7	378.5 $\pm$ 67.8
Years to onset		15.5 $\pm$ 7.0	
Years since diagnosis			2.0 $\pm$ 1.6
UHDRS motor score (range)		1 (0-4)	19 (6-60)
<u>Significant differences: All 3 groups<sup>a</sup></u>			
Putaminal volume	5969 $\pm$ 797	5065 $\pm$ 1089	3449 $\pm$ 775
Caudate volume	7385 $\pm$ 1162	6052 $\pm$ 1574	4392 $\pm$ 981



### 3. Study One: Baseline striatum

Speeded tapping (ms)	219.9±38.1	243.7±45.0	364.5±162.2
Self-paced tapping (1/SD ITI) 333ms	29.1±8.3	23.8±8.7	11.4±5.7
Self-paced tapping (1/SD ITI) 550ms	23.8±7.7	19.6±7.4	10.5±4.1
SDMT	56.3±10.1	51.5±8.6	36.0±11.7
<u>Two comparisons<sup>b</sup></u>			
UPSIT	34.0±3.1	32.7±5.0	26.2±7.1
Stroop	109.8±16.6	104.4±17.5	82.5±22.0

ICV: Intracranial volume; DBS: (CAG-35.5)\*age; YtO: approximate years to onset, modified Langbehn method (Langbehn, et al. 2004); YSD: Years since diagnosis; ITI: Inter-tap interval; SDMT: Symbol Digit Modalities Test; Age, sex and ICV were used as covariates in all analyses.

†For a full list see (Georgiou-Karistianis, et al. 2013a), although note that more subjects have been included in the symp-HD group since this initial publication.

*a* Symp-HD versus pre-HD, symp-HD versus controls, and pre-HD versus controls all  $p \leq 0.017$

*b* Symp-HD versus pre-HD and symp-HD versus controls,  $p \leq 0.017$

#### 3.4.2 Volume and shape

There were significant differences in striatal volume between all three groups with control volumes larger than pre-HD, which were significantly larger than symp-HD (Table 3.2).


Significant striatal shape differences were also detected between all groups (Figure 3.5), with controls showing larger shape metrics (increased thickness and surface expansion) than pre-HD, and pre-HD larger than symp-HD. These shape differences mapped across large areas of the striatum, with more extensive differences detected using the Jacobian shape metric (local

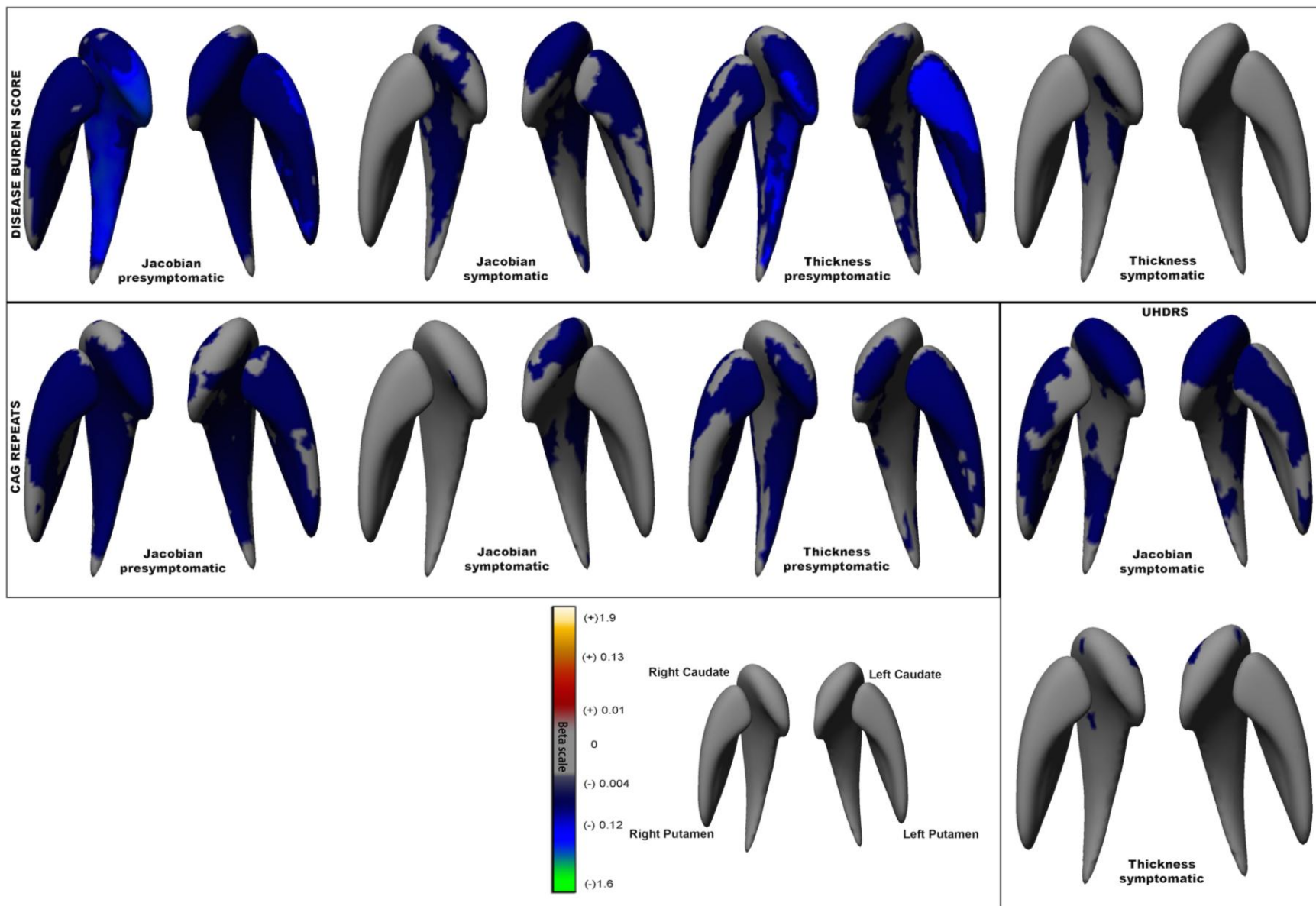
surface area expansion/contraction). The greatest shape differences were between controls and symp-HD, but there were also widespread shape differences between pre-HD and symp-HD and between pre-HD and controls. The greatest differences were in surface contraction and decreased thickness in the right putamen in pre-HD compared to controls and left putamen in symp-HD compared to pre-HD.

#### *3.4.3 Correlations- shape*

Significant negative associations were detected between striatal thickness and surface expansion/contraction measure and the number of CAG repeats, DBS, and UHDRS total motor score in pre-HD, symp-HD, or both (Figure 3.6). Again, greater areas of association were seen with the Jacobian surface contraction/expansion measures than with the thickness metric. In pre-HD, there were widespread significant negative associations between lower thickness and surface contraction in caudate and putamen and both CAG repeat number and DBS. These associations were detected to a much lesser extent in symp-HD, with only small areas of association between lower surface area shape measures and increasing DBS in patches of bilateral caudate, as well as left anterior putamen. Increasing CAG repeat number was only associated with lower surface area shape measures in left caudate head and anterior tail in symp-HD. Changes were similar but much less extensive when measuring thickness.

**Figure 3.5: Shape differences between groups** (next page). Top panel: Significant differences based on Jacobian determinant, indicating surface dilation due to subregional volume change. Bottom panel: Significant differences based on radial distance (“thickness”), or distance of the vertex from the medial curve of the structure. Beta value = regression coefficient, or “slope”.





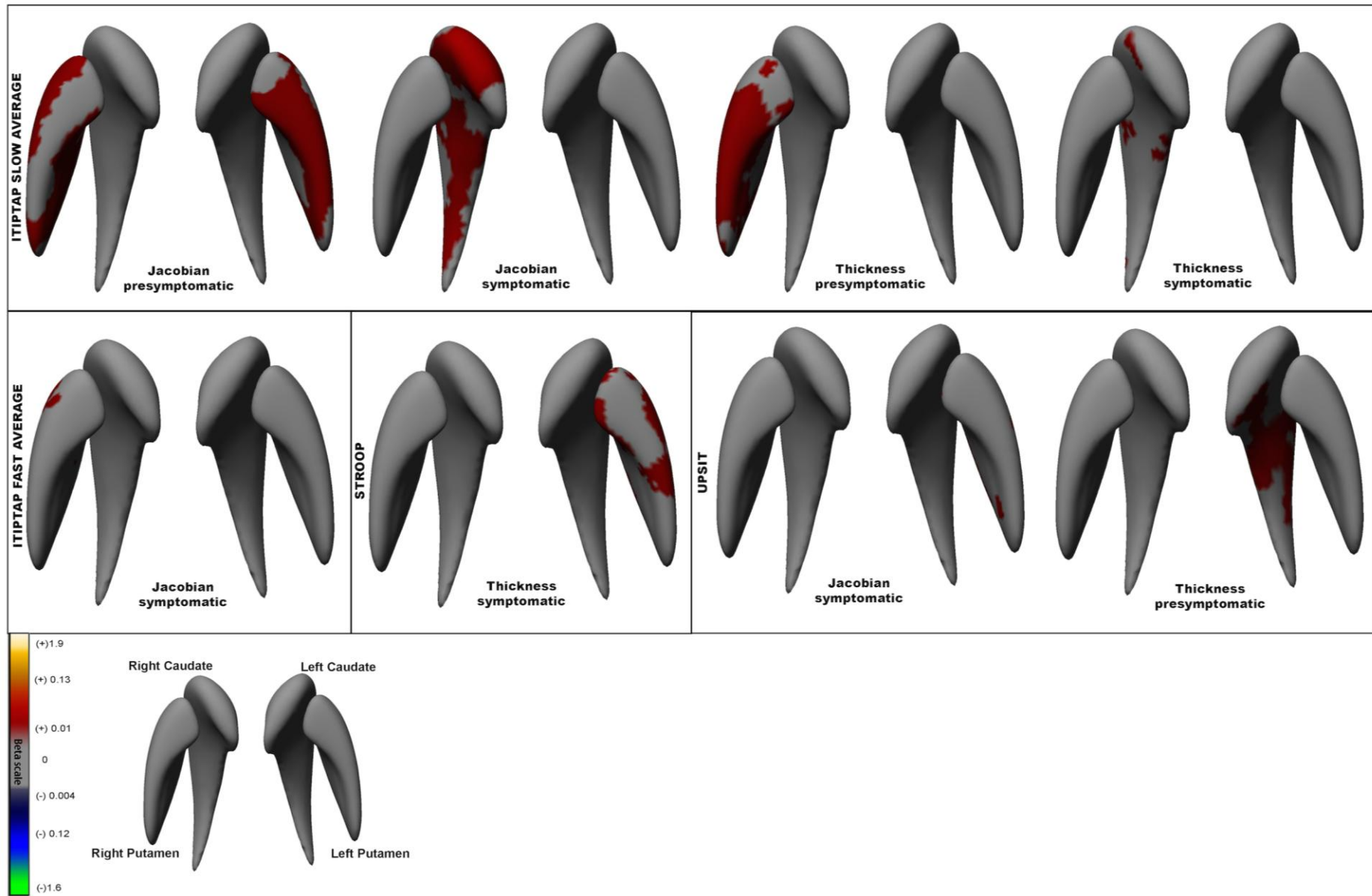
#### **Figure 3.6: Correlations between neostriatal shape and measures of disease burden.**

Panels indicate all significant correlations within each measure of disease burden: DBS, CAG repeats, and UHDRS motor scores. Jacobian = correlation based on surface dilation due to subregional volume change. Thickness = correlation based on radial distance, or distance of the vertex from the medial curve of the structure. Beta value = regression coefficient, or “slope”.

Of the other motor and neurocognitive measures tested against shape changes in neostriatum, only UPSIT, Stroop, and self-paced tapping (slow and fast) showed significant correlations (Figure 3.7). There were significant associations between surface contraction in bilateral caudate and putamen in symp-HD and increasing UHDRS (motor) scores. These were limited to only patches of bilateral caudate head when thickness was tested.

In symp-HD, UPSIT scores were correlated with thickness of left caudate body and surface expansion in left posterior putamen, both in very limited regions. Stroop scores were positively correlated with the thickness of left putamen head and body. The regions of volume change are also very limited in these associations.

Self-paced tapping (slow) was correlated with surface expansion of the right caudate in symp-HD and with bilateral putamen in pre-HD, although when thickness was tested these correlations were confined to only anterior right caudate in symp-HD and right putamen in pre-HD. Self-paced tapping (fast) was correlated with right anterior putaminal higher surface expansion in symp-HD only.



**Figure 3.7: Neostriatal shape correlations with motor and cognitive test scores.** Panels indicate all significant correlations within each measure with significant results: ITIPTAP slow average (inter-trial interval in participant passed tapping, slow 1.8Hz), ITIPTAP fast average (inter-trial interval in participant passed tapping, fast 3Hz), Stroop, and UPSIT. Jacobian = correlation based on surface dilation due to subregional volume change. Thickness = correlation based on radial distance, or distance of the vertex from the medial curve of the structure. Beta value = regression coefficient, or “slope”.

### **3.5 Discussion**

This study has confirmed significant differences between controls, pre-HD and symp-HD in neostriatal volume and shape metrics that quantify morphologic structural brain change. The regions of change in this area, while using different methods and investigating both pre-HD and symp-HD, confirm similar patterns of striatal atrophy (Faria, et al. 2016; Kim, et al. 2017; Tang, et al. 2019; van den Bogaard, et al. 2011b; Younes, et al. 2012). It extends current research by finding that these morphologic changes correlate with CAG repeat number and DBS and that morphologic changes in specific areas in pre-HD and symp-HD are associated with motor and cognitive differences, which may provide insight into how subcortical morphometric changes relate to disease pathogenesis.

Interestingly, of the two measures used to identify shape changes, the Jacobian measurement of shape change showed more extensive and stronger correlations than the radial thickness measure. As the Jacobian measurement incorporates more dimensions of the data than the simple scalar value of thickness, it may be better suited to discriminate relevant shape changes (Gutman, et al. 2015; Gutman, et al. 2012). However, both measures remain useful in subcortical shape analysis (Tate, et al. 2019): radial thickness directly corresponds to localised volume, whereas the Jacobian determinant can capture the stretching/shrinking along the main axis of a region, making them different but complementary measures.

#### *3.5.1 CAG repeat length correlations with shape*

Increasing number of CAG repeats correlated with surface contraction and decreased thickness throughout the neostriatum in pre-HD. In contrast, in symp-HD, the number of CAG repeats was only associated with surface contraction in left anterior caudate. This may be a statistical artefact due to the destructive nature of HD - by the time of clinical diagnosis, there is already marked neurodegeneration, particularly in the striatum, whereas there is much more variation in size of the striatum in pre-HD. However, there is also evidence that the factors that determine age of disease onset in pre-HD (largely but not exclusively CAG) do not explain all of the disease progression once it has become manifest (Aziz, et al. 2018). In this study, reduced areas of shape correlation with CAG repeat length in symp-HD, but widespread correlations between shape and UHDRS throughout caudate and putamen, may also provide indirect evidence for the idea that CAG repeat length has less of an influence on disease progression. Similarly, there were also significant negative associations between neostriatal surface area shape measures and DBS. These correlations were greatest in pre-HD and less apparent in symp-HD.

#### *3.5.2 Shape correlations with motor measures*

Overall neostriatal volumes have been correlated with motor and cognitive outcomes in a number of studies in HD (Aylward, et al. 2012; Bechtel, et al. 2010; Delmaire, et al. 2012; Misiura, et al. 2017) but to our knowledge only two studies have examined striatal subregional morphology and motor outcomes in HD (Bohanna, et al. 2011a; Turner, et al. 2016). Both studies investigated the IMAGE-HD cohort or a subset.



Bohanna and colleagues have previously found the greatest differences in volume and diffusion tensor imaging measures in dorsal areas of the striatum that have connections to primary motor and somatosensory cortices; subregion-specific volume was also strongly correlated with the UHDRS motor score (Bohanna, et al. 2011a).

Using a subset of the IMAGE-HD cohort, Turner and colleagues (Turner, et al. 2016) measured EEG components of sensorimotor integration in 12 individuals with pre-HD and 7 with symp-HD and correlated these with shape changes in the striatum. All results occurred in the context of abnormal processing but normal task execution. Unregulated premotor activation was correlated with shape deflation of the dorsal putamen bilaterally, as well as deflation in anterior inferior putamen (left > right). This was thought to reflect the ability to recruit compensatory network from frontal motor projection areas. In contrast, delayed timing of neural premotor activation was significantly correlated with shape deflation in the right caudate (anterolateral and dorsomedial areas only). Here, caudate shape deflation was thought to impair motor planning and execution (Turner, et al. 2016).

Self-paced finger tapping has been previously shown to be impaired in both pre-HD and symp-HD individuals (Bechtel, et al. 2010; Georgiou-Karistianis, et al. 2013a; Stout, et al. 2011). This task requires participants to listen to a tone presented at a certain rate (1.8 or 3.0 Hz), to tap along with this tone, and then to continue tapping at the same rate after cessation of the tone (Stout, et al. 2011). “ITIPTAP slow average” measures the variance in self-paced tapping to a slow beat. In pre-HD, worsening accuracy in this measure was correlated with shape contraction throughout bilateral putamen (and reduced thickness in right putamen). Interestingly, in symp-HD this correlation was lost and instead worsening accuracy in self-paced tapping scores were correlated with right caudate shape contraction, throughout the

entire caudate. This is consistent with the results found by Turner and colleagues above (Turner, et al. 2016), suggesting that initially the bilateral putamen is able to recruit compensatory networks to help in motor tasks, but eventually this fails and consequently, right caudate atrophy impairs motor planning and execution, leading to worsening outcomes without any remaining compensatory measures. The regions of shape and volume change in these associations implicate the surface mapping of afferents from a wide range of circuits, including but not limited to the rostral premotor (to a lesser degree) and caudal motor corticostriatal circuits that converge on the striatum (Draganski, et al. 2008; Haber 2003). Fast self-paced tapping is thought to be more difficult, requiring greater involvement of the frontal cortex rather than the striatum (Delmaire, et al. 2012), which may explain why there are fewer significant correlations seen between self-paced tapping (fast) and striatal shape in our study, apart from in the anterior right putamen in a region that has connections to frontal cortex.

#### *3.5.3 Shape correlations with neurocognitive measures*

Of the neurocognitive measures tested, UPSIT and Stroop, but not SDMT, showed correlations with striatal shape metrics in symp-HD. There were no significant correlations detected between neostriatal shape and any cognitive measures in pre-HD or in controls. To our knowledge only one previous study has investigated the correlation between neostriatal shape change and neurocognitive measures; Kim and colleagues manually segmented the caudates of individuals with pre-HD and correlated shape changes here with composite measures of executive function and working memory. They found that scores in these domains mapped to anteromedial caudate (Kim, et al. 2017).

The UPSIT is a complex task involving integration from a number of areas. Scores in UPSIT have been associated with diffusion tensor MRI mean diffusivity in the parietal lobe, medial temporal lobes, cingulum and insula, as well as caudate nucleus and anterior putamen (Delmaire, et al. 2012). Here, we have found that in symp-HD, better scores in UPSIT are related to increased thickness of left mid-caudate and surface expansion in left posterior putamen. The regions of both shape and volume difference are very limited in these associations, and implicate the surface mapping of afferents from the orbitofrontal and dorsolateral-prefrontal corticostriatal circuits that converge on the left caudate, as well as known areas of connections with temporal lobe in left putamen (Draganski, et al. 2008; Haber 2003).

Similarly, the Stroop Word Test requires executive control (MacLeod and MacDonald 2000). In this study Stroop scores were positively correlated with left anterior putaminal thickness in symp-HD, in regions mapping to orbitofrontal and dorsolateral-prefrontal corticostriatal circuits (Draganski, et al. 2008; Haber 2003). Of note, correlations with both Stroop and UPSIT were in the left neostriatum only- the dominant hemisphere for all subjects.

Integrity of tracts between the putamen and prefrontal areas are thought to be critical for executive function (Liston, et al. 2006). Damage to these tracts and others, as reflected in the shape abnormalities here, can affect not only the more obvious motor symptoms of HD but also subtler circuitry controlling executive function. The small regions of associations here compared to the larger areas of association in Kim et al.'s study (Kim, et al. 2017) likely reflect the composite nature of their measures. Our study however remains an important addition to the current body of work because it adds precise anatomical detail to this knowledge of circuitry, and extends into further measures of caudate and putamen, as well as motor, cognitive and clinical measures.

#### **3.6 Limitations**

We focused on the morphology of the striatum as a sentinel measure of structural change within corticostriatal circuits, which we believe is more easily quantified than the entirety of the corticostriatal pathways. Inferences regarding the effect of shape differences on known underlying subfields are limited by our shape analysis technique. Some inferences may be made based on neuroanatomical sources (Draganski, et al. 2008; Haber 2003), but ongoing work involves the challenging task of mapping known neuroanatomical subfields to the surface of our subcortical shape models. Future studies may provide additional insights into the underlying subfield effects detected by this powerful shape analysis technique.

#### **3.7 Conclusions/clinical implications**

We have replicated and extended on previous work showing that quantified measures of neostriatal morphology differ significantly across controls, pre-HD and symp-HD. We found the thickness and surface expansion/dilation measures correspond to the surface mapping of afferents from corticostriatal circuits in HD. Furthermore, neostriatal shape correlated with motor, neurocognitive and clinical measures subserved by such circuits, suggesting that the neostriatum is a potentially useful structural basis for characterisation of endophenotypes of HD. Future work in HD should investigate the spatiotemporal progression of striatal atrophy and its genetic and clinical correlates: to assess the usefulness of such quantifiable endophenotypes (striatal structure and frontostriatal function) to understand the pathophysiology of the disorder, monitor disease progression and ultimately, assess response to clinical interventions (Looi and Santillo 2017).

## 7. General discussion

This thesis presents an investigation into subcortical changes in HD in specific neuroanatomical “hubs and spokes”, i.e. the caudate, putamen, hippocampus, and corpus callosum, and their relationship with clinical, motor, neurocognitive and neuropsychiatric outcomes. The central questions were:

- Is there a difference between subcortical morphology in symp-HD, pre-HD, and controls?
- Do these change over time and progress in a determined pattern?
- Is there a relationship between shape change and motor and neurocognitive outcomes?
- Do these follow the expected relationships with known subcortical circuits in a topographical pattern?
- Can the picture of the above give a better understanding of the pathogenesis of HD and help with the development of a biomarker and endophenotype of HD?

**Table 7.1: Scope of thesis.** Investigation of the subcortical connectome in HD, with view to development of an endophenotype.

<b>Study</b>	<b>Investigation</b>	<b>Rationale</b>	<b>Endophenotype components</b>
<b>Study One</b>	Baseline analysis of neostriatum and relationship with functional outcomes	Key structure in HD and hub in frontostriatal circuitry	Genetics Morphology Function
<b>Study Two</b>	Longitudinal analysis of neostriatal change	Morphological change over time, investigating potential biomarkers	Genetics Morphology Spatiotemporal signature

<b>Study Three</b>	Baseline analysis of hippocampus and relationship with functional outcomes	Further extension of subcortical connectome in a different but related hub, potential for compensation	Genetics Morphology Function
<b>Study Four</b>	Baseline and longitudinal analysis of the corpus callosum	Major spoke within the connectome, complementary information regarding degeneration	Genetics Morphology Spatiotemporal signature

Investigation in this thesis focused on specific “hubs and spokes” within the brain, providing a more comprehensive picture of HD as a whole and the interrelationship between neuroanatomical changes and functional outcomes. This thesis found changes in subcortical morphology in pre-HD and symp-HD, which progressed in a determined pattern and related to genetic changes. This thesis also found correlations between shape changes in the striatum and motor and neurocognitive outcomes, in areas related to the appropriate frontostriatal circuitry. Further characterisation of changes in HD increases knowledge of neurodegenerative pathways and the relationship between quantitative measures of morphology (morphometry) and function *in vivo*, constituting endophenotypes, and aims towards developing biomarkers for prognostication and use in HD treatment trials.

### 7.1 Brief summary of findings

**Study One** investigated the baseline morphology of the neostriatum in pre-HD and symp-HD, and how this related to functional outcomes. Study One hypothesised that neostriatal morphology would differ significantly between controls and individuals with pre-HD and symp-HD, and that changes would be associated with cognitive, neuropsychiatric and motor

outcomes according to known functional connections. Significant shape differences were detected between all groups, with caudate and putamen being largest in controls, then in pre-HD, and then in symp-HD. Higher CAG repeats, DBS, and UHDRS total motor score were associated with striatal shape deflation and decreasing striatal thickness. In pre-HD, there were widespread correlations between decreasing striatal thickness and surface contraction in caudate and putamen and greater CAG repeat number and DBS. These associations were detected to a much lesser extent in symp-HD, with only small areas of association between lower surface area shape measures and increasing DBS in patches of bilateral caudate, as well as left anterior putamen. Increasing CAG repeat number was only associated with lower surface area shape measures in left caudate head and anterior tail in symp-HD. In symp-HD, UPSIT scores were correlated with greater thickness in left caudate tail and surface dilation ratio in left posterior putamen; Stroop scores were positively correlated with the thickness of left putamen head and body. Better scores in self-paced tapping (slow) were correlated with greater thickness and surface dilation in bilateral putamen in pre-HD and in right caudate in symp-HD, reflecting some element of network compensation. Self-paced tapping (fast) was correlated with higher surface dilation ratio in the right anterior putamen in symp-HD. Shape changes correlated with functional measures subserved by corticostriatal circuits, and were also correlated with genetic changes in HD, providing evidence towards the striatum as an endophenotype of HD.

**Study Two** aimed to extend the literature on morphological change in HD using a new method of longitudinal shape analysis. Study Two hypothesised that there would be longitudinal shape changes in the caudate and putamen, visualised in greater detail than previously due to the new method of analysis, and that this would help towards development of a biomarker for HD. Study Two found significant differences in shape of the striatum between groups.

Significant group-by-time interaction was observed for the putamen bilaterally, but not for caudate, with a differential rate of shape change between groups over time and deflation more pronounced in the symp-HD group. The main effect of CAG repeats on shape in pre-HD and symp-HD occurred for the entire bilateral striatum and there was no significant group-by-CAG-repeat interaction effect. In contrast to the lack of group-by-CAG-repeat interaction effect, there was a significant time-by-CAG-repeat interaction effect: later time points in pre-HD and symp-HD demonstrated an association between increased CAG repeats and increased deflation in the caudate.

*Study Three* extended the investigation of HD from the neostriatum to the hippocampus, another key neuronal hub which also has a relationship with clinical symptoms seen in HD, but which has been less extensively studied in this field. Study Three hypothesised that there would be subtle shape changes in the hippocampus in pre-HD and symp-HD, and that these would be related to psychiatric and cognitive scores related to the hippocampus, as well as to SSRI use as this alters hippocampal neurogenesis. No differences were found in baseline hippocampal volume between groups after controlling for age and intracranial volume. There was also no relationship between hippocampal volume and scores on UPSIT, BDI-II, HADS-A or HADS-D, all of which have links to the hippocampus. Unexpectedly, a significant difference in both right and left hippocampal volume was found in SSRI users, despite there being no significant changes between anxiety or depressive symptoms or motor incapacity. Significant shape contraction was seen in the right hippocampal head in symp-HD in a pattern consistent with later spread of neurodegeneration from the striatum. No longitudinal changes in shape were found in any group.



*Study Four* extended the hubs and spokes model of neuronal circuitry further to examine the largest “spoke” in the brain, the corpus callosum, which provides a unique opportunity to investigate a proxy marker of widespread neurodegeneration in HD. Study Four investigated mid-sagittal callosal thickness and aimed to correlate changes with functional outcomes. Study Four hypothesised that subtle changes would be seen in pre-HD and symp-HD over time, reflecting spread of neurodegeneration. Participants with symp-HD showed significant reductions in callosal thickness and significant decreases were seen in callosal thickness over time. There were no significant correlations between regional callosal thickness and clinical or neurocognitive outcomes in either pre-HD or symp-HD. While CC thickness was not impacted early in the disease process, it became affected after symptom onset, reflecting the spread of neurodegeneration to other structures.

## **7.2 Insights into progression of neurodegeneration in HD and implications for treatment**

This thesis investigated structural changes to brain “hubs and spokes” and how these changes were related to motor, neurocognitive and psychiatric outcomes in HD. Using structural MRI and shape analysis techniques, this thesis demonstrated that changes to brain “hubs”, particularly the neostriatum, occur in early disease stages, followed later by changes in the major “spoke” of the corpus callosum. “Hub” changes in the neostriatum were also reflected in correlations with functional outcomes related to underlying frontostriatal circuitry. In addition, changes reflected areas of both functional and structural compensation for neurodegeneration in HD. Neuroanatomical changes, compensation, and the implications for development of an endophenotype of HD are discussed below.

*7.2.1 Neuroanatomical changes in HD, network spread, and potential for neural and functional compensation.*

HD has its most marked effects on the neostriatum, but also has more subtle effects on other subcortical areas. This thesis also showed areas of surface contraction in symp-HD in the hippocampus compared to controls. Areas of change within the hippocampus were in regions which are topographically related to striatum and which receive inputs from other areas of the brain (rather than internal circuitry or output regions). Unlike these “hubs”, this thesis found that the large “spoke” of the corpus callosum was not impacted early in the HD process but became affected after symptom onset. These converging lines of evidence highlight the spread of neurodegeneration from striatum to other structures (Poudel, et al. 2019), rather than supporting the competing hypothesis of multiple foci of cell autonomous degeneration (Tang, et al. 2019).

The two areas of potential neurogenesis in the adult human brain are within the hippocampus (SGZ) and next to the caudate (SVZ). New neurons from the SVZ can integrate into the striatum in adult humans: this is depleted in HD and postnatally generated neurons are absent in advanced stages of the disease (Ernst, et al. 2014), even though some early studies showed increased cell proliferation in the SVZ in HD and potential compensation (Curtis, et al. 2003). Similarly, a large subpopulation of hippocampal neurons are subject to turnover in the adult human brain, with neurogenesis continuing throughout the lifespan (Spalding, et al. 2013). Cell proliferation in the hippocampus is reduced in mouse models of HD but reportedly not in humans with advanced HD, although there are limited human histopathological studies (Low, et al. 2011). Well-defined maps of shape change in the neostriatum and hippocampus in HD are crucial towards recognising and tracking where potential compensation and neurogenesis can occur with treatment.

Recent studies investigating children and adolescents with pre-HD many years before motor onset have found a number of interesting changes in neurodevelopment. The recent Kids-HD study (Tereshchenko, et al. 2020; van der Plas, et al. 2019) investigated a cohort of young people age 6-18 with a parent or grandparent with symp-HD, and so therefore potentially at risk of later developing symp-HD themselves. The study excluded children with juvenile onset HD, and on average the estimated time to onset of symp-HD was 35 years. Given the ethical considerations with testing for genetic changes indicative of HD, genetic results were blinded to all participants and to everyone who was involved in working directly with participants. Abnormal neurodevelopment was found in the striatum in children who had pre-HD, with early hypertrophy (van der Plas, et al. 2019). In HD gene non-expanded individuals, the striatum grows in size until approximately age 14, followed by a decline in striatal volume (Herting, et al. 2018; van der Plas, et al. 2019). In pre-HD however, there is initial hypertrophy of the striatum prior to the age of 10, followed by a steady early decrease in volume. From age 14, volume loss occurs in a similar pattern in both pre-HD and gene non-expanded individuals. Children with CAG repeat lengths greater than 50 had both greater initial hypertrophy and faster rates of subsequent volume decline.

Resting-state fMRI was also used in this cohort to investigate possible compensation from the cerebellum for abnormal striatal neurodevelopment (Tereshchenko, et al. 2020). The cerebellum is integrated into the indirect pathway of the basal ganglia through outputs from the dorsocaudal putamen, globus pallidus externa, subthalamic nucleus, and pontine nuclei, and reciprocal inputs come from the dentate nucleus of the cerebellum to the ventrolateral thalamus and dorsocaudal putamen (Milardi, et al. 2016; Tereshchenko, et al. 2020). By calculating seed-to-seed correlations among these regions, significantly different trajectories of connectivity were found between all regions except the dorsocaudal putamen. In children

with pre-HD, hyperconnectivity is seen in early years (while hypertrophy of the striatum is occurring), with later linear decline. This hyperconnectivity is thought to be a compensatory measure for abnormal neurodevelopment in the striatum (Tereshchenko, et al. 2020), and cerebellar compensation has also been proposed during later striatal degeneration (Franklin, et al. 2020; Gaura, et al. 2017). This is in line with a number of other functional imaging studies which have shown compensatory increases in other pathways for motor and cognitive tasks in pre-HD and symp-HD (Georgiou-Karistianis, et al. 2013b; Georgiou-Karistianis, et al. 2014; Gregory, et al. 2018; Kloppel, et al. 2009; Klöppel, et al. 2015; Poudel, et al. 2015c).

### *7.2.2 Development of an endophenotype of HD, implications for treatment*

Researchers continue to search for improved ways to monitor progression of disease in HD, as there are no current disease-modifying treatments and an ongoing need for a biomarker to help with testing potential treatments. CAG repeat number in HD accounts for only 50-70% of age at onset, and has less of a role in disease progression once the motor symptoms become apparent, although this role may be somewhat masked by the process of ageing itself (Rosenblatt, et al. 2012; Rosenblatt, et al. 2006; Wexler, et al. 2004). Indeed, in Study One there were reduced areas of striatal shape correlation with CAG repeat length in symp-HD (controlling for age, sex and ICV), occurring only in the left caudate, compared to widespread correlations between shape and UHDRS. Extending this, Study Two demonstrated that while there was a significant correlation between increasing CAG repeat number and shape deflation in caudate and putamen, a significant effect of time on this effect was only found in the caudate and stronger in the left hemisphere. Group by time interactions, however, revealed correlations only with putamen, and not caudate, shape: change in putamen shape over time in

symp-HD appears to be somewhat independent of CAG repeat length. These results point specifically to the putamen as the better biomarker for progression in pre-HD and symp-HD.

As research moves towards searching in younger cohorts for potential biomarkers in HD, one recent study looking at young adults in their 20s found a few potential biomarkers at very early stages of pre-HD, with an average of 24 years to diagnosis (Scahill, et al. 2020). One of these was putamen volume, although volume was not correlated with CAG repeat numbers. The others were two CSF markers and one serum marker, with CSF neurofilament light protein being the most sensitive measure and correlated with CAG repeat number (Scahill, et al. 2020). From a practical standpoint however, regular lumbar punctures to siphon CSF has a number of disadvantages, as it is a painful procedure and carries significant risks. Importantly, this young adult study looked at putaminal volumes only and not shape. Results in this thesis would suggest that adding shape to the measure of putaminal changes could also increase sensitivity for a biomarker at early stages.

Establishment of an endophenotype, a “biological measure that correlates with, or predicts, clinical features of brain dysfunction” (Looi, et al. 2014b), is especially important in complex conditions like HD, given the issues described above. Research in this thesis confirms the neostriatum as a perfect candidate for an endophenotype in HD, as it sits central to the motor changes but also to other neurocognitive changes and is related to the known genetic changes in HD (Looi and Walterfang 2012). Knowledge of the anatomy of this circuitry, of its topographical nature, as well as the overall changes within the “hubs and spokes” of the brain in HD can help to guide potential treatments, whether these be targeting with surgery or novel molecular mechanisms.

### *7.3.3 Future directions*

Studies in HD and in neuroscience more generally are moving towards pooling data with international collaborations, increasing power to find biomarkers, endophenotypes, and mechanisms of disease (Thompson, et al. 2020). This is particularly useful for rare diseases such as HD, which requires multicentre data even for Phase 1 trials (Wijeratne, et al. 2020). Amongst other benefits, larger data sets and international collaboration also facilitate the investigation of intriguing findings from smaller studies, such as the SSRI findings in this study.

Automated shape analysis is likely to take over from manual methods as automated methods improve, with longitudinal shape analysis also becoming increasingly available and detailed. The subcortical connectome should continue to be targeted by these methods as composite endpoints increase power further to investigate changes in HD (Wijeratne, et al. 2020), and morphological investigation of the subcortical connectome provides a clinically and practically useful intermediary step between mapping complicated large-scale networks and studying individual structures (Looi, et al. 2014b).

Given recent findings of early compensation by the cerebellum for abnormal striatal development (Tereshchenko, et al. 2020), the cerebellum should receive more research input, particularly from a morphological perspective due to the advantages of structural analysis discussed throughout this thesis. This could target the dentate gyrus in particular, as another hub in the connectome. As studies are looking towards younger cohorts, morphological analysis also has strong potential to provide a useful biomarker and endophenotype here, and has not yet been investigated in this group.

Psychiatric conditions in HD are increasingly receiving more research interest and recognition as an integral and disabling part of the condition (Goh, et al. 2018; Ho, et al. 2009; Sellers, et al. 2020). A recent study examined gene expression profiles from peripheral blood samples in pre-HD and symp-HD and found differential gene expression between depressed and non-depressed people with HD (Colpo, et al. 2020). While examining only a small number of people, as an exploratory study it reveals a number of interesting changes. 19 genes were differentially expressed between people with HD with and without depression, with 6 upregulated and 13 downregulated. Of note, several of the top differentially expressed genes were involved in nervous system development. Unfortunately however, there is no mention in this study of whether any of the participants were taking psychiatric or other medications. This has implications both from the findings in this thesis of altered hippocampal volumes with SSRIs, as well as the known epigenetic changes from a number of medications, including the mood stabiliser sodium valproate, which is sometimes used in HD (Bachoud-Levi, et al. 2019; de Campos Vidal and Mello 2020). Of great interest in this thesis is the never before noted association between SSRI use and decreased hippocampal volume in HD. Given the high proportion of people with HD with depression and on SSRIs, this warrants further investigation and may yield more information about abnormal molecular pathways and neurogenesis in HD.

### **7.4. Conclusion**

This thesis demonstrates morphological change in several subcortical regions in pre-HD and symp-HD and correlates these with functional outcomes. It reveals neuronal degeneration in HD occurring largely in a pattern of spread from the neostriatum. Correlations between

striatal shape changes and functional outcomes occur in areas linked to subserving (frontostriatal) circuitry, adding to the growing weight of evidence pointing towards the neostriatum as an endophenotype of HD.

Spatiotemporal signatures developed from shape analysis of neuronal structures assist in understanding pathophysiology of disease, with the view to developing biomarkers for prognostication and analysis of potential disease-modifying treatments. This is the first time that such robust statistical analysis of longitudinal shape change in HD has been able to be performed and shows the neostriatum, particularly the putamen, as a potentially useful structural basis for the characterisation of an endophenotype of HD. This thesis provides a more comprehensive picture of neuroanatomical change in HD by using a “hubs and spokes” approach to analyse key areas, increasing knowledge about the pathogenesis of HD and network changes in neurodegenerative disease.



## References

- Adamson C, Beare R, Ball G, Walterfang M, Seal M. 2018. Callosal thickness profiles for prognosticating conversion from mild cognitive impairment to Alzheimer's disease: A classification approach. *Brain Behav* 8(12):e01142.
- Adamson C, Beare R, Walterfang M, Seal M. 2014. Software pipeline for midsagittal corpus callosum thickness profile processing : automated segmentation, manual editor, thickness profile generator, group-wise statistical comparison and results display. *Neuroinformatics* 12(4):595-614.
- Adamson CL, Wood AG, Chen J, Barton S, Reutens DC, Pantelis C, Velakoulis D, Walterfang M. 2011. Thickness profile generation for the corpus callosum using Laplace's equation. *Human Brain Mapping* 32:2131-40.
- Ahveninen LM, Stout JC, Georgiou-Karistianis N, Lorenzetti V, Glikmann-Johnston Y. 2018. Reduced amygdala volumes are related to motor and cognitive signs in Huntington's disease: The IMAGE-HD study. *Neuroimage Clin* 18:881-887.
- Alexander B, Georgiou-Karistianis N, Beare R, Ahveninen LM, Lorenzetti V, Stout JC, Glikmann-Johnston Y. 2020. Accuracy of automated amygdala MRI segmentation approaches in Huntington's disease in the IMAGE-HD cohort. *Hum Brain Mapp* 41(7):1875-1888.
- Alexander GE, Delong MR, Strick PL. 1986. Parallel organization of functionally segregated circuits linking basal ganglia and cortex. *Annual Review of Neuroscience* 9:357-381.
- Ament SA, Pearl JR, Cantle JP, Bragg RM, Skene PJ, Coffey SR, Bergey DE, Wheeler VC, MacDonald ME, Baliga NS and others. 2018. Transcriptional regulatory networks underlying gene expression changes in Huntington's disease. *Mol Syst Biol* 14(3):e7435.
- Andre R, Carty L, Tabrizi SJ. 2016. Disruption of immune cell function by mutant huntingtin in Huntington's disease pathogenesis. *Curr Opin Pharmacol* 26:33-8.
- Andrew SE, Goldberg YP, Kremer B, Telenius H, Theilmann J, Adam S, Starr E, Squitieri F, Lin B, Kalchman MA and others. 1993. The relationship between trinucleotide (CAG) repeat length and clinical features of Huntington's disease. *Nat. Genet.* 4(4):398-403.
- Aylward E, Mills J, Liu D, Nopoulos P, Ross CA, Pierson R, Paulsen JS. 2011a. Association between Age and Striatal Volume Stratified by CAG Repeat Length in Prodromal Huntington Disease. *PLoS Currents* 3:RRN1235.
- Aylward EH, Harrington DL, Mills JA, Nopoulos PC, Ross CA, Long JD, Liu D, Westervelt HK, Paulsen JS. 2013. Regional atrophy associated with cognitive and motor function in prodromal Huntington disease. *J Huntingtons Dis* 2(4):477-89.
- Aylward EH, Liu DW, Nopoulos PC, Ross CA, Pierson RK, Mills JA, Long JD, Paulsen JS, Huntington Study Group. 2012. Striatal volume contributes to the prediction of onset of Huntington Disease in incident cases. *Biol. Psychiatry* 71(9):822-828.
- Aylward EH, Nopoulos PC, Ross CA, Langbehn DR, Pierson RK, Mills JA, Johnson HJ, Magnotta VA, Juhl AR, Paulsen JS and others. 2011b. Longitudinal change in regional brain volumes in prodromal Huntington disease. *Journal of Neurology Neurosurgery and Psychiatry* 82(4):405-410.
- Aylward EH, Rosenblatt A, Field K, Yallapragada V, Kieburtz K, McDermott M, Raymond LA, Almqvist EW, Hayden M, Ross CA. 2003. Caudate volume as an outcome measure in clinical trials for Huntington's disease: a pilot study. *Brain Research Bulletin* 62(2):137-141.

- Aziz NA, van der Burg JMM, Tabrizi SJ, Landwehrmeyer GB. 2018. Overlap between age-at-onset and disease-progression determinants in Huntington disease. *Neurol.* 90(24):e2099-e2106.
- Bachoud-Levi AC, Ferreira J, Massart R, Youssov K, Rosser A, Busse M, Craufurd D, Reilmann R, De Michele G, Rae D and others. 2019. International Guidelines for the Treatment of Huntington's Disease. *Front Neurol* 10:710.
- Barani IJ, Benedict SH, Lin P-S. 2007. Neural stem cells: Implications for the conventional radiotherapy of central nervous system malignancies. *International Journal of Radiation Oncology Biology Physics* 68(2):324-333.
- Bates G. 2003. Huntingtin aggregation and toxicity in Huntington's disease. *Lancet* 361(9369):1642-4.
- Bechtel N, Scahill RI, Rosas HD, Acharya T, van den Bogaard SJA, Jauffret C, Say MJ, Sturrock A, Johnson H, Onorato CE and others. 2010. Tapping linked to function and structure in premanifest and symptomatic Huntington disease. *Neurol.* 75(24):2150-2160.
- Beck AT, Steer, R.A., Brown, G. K. 1996. Manual for the Beck Depression Inventory - II. San Antonio: Psychol. Corp.
- Begeti F, Schwab LC, Mason SL, Barker RA. 2016. Hippocampal dysfunction defines disease onset in Huntington's disease. *J Neurol Neurosurg Psychiatry* 87(9):975-81.
- Berner LA, Wang Z, Stefan M, Lee S, Huo Z, Cyr M, Marsh R. 2019. Subcortical shape abnormalities in Bulimia Nervosa. *Biol. Psychiatry Cogn. Neurosci. Neuroimaging.*
- Biglan KM, Ross CA, Langbehn DR, Aylward EH, Stout JC, Queller S, Carlozzi NE, Duff K, Beglinger LJ, Paulsen JS and others. 2009. Motor Abnormalities in Premanifest Persons with Huntington's Disease: The PREDICT-HD Study. *Movement Disorders* 24(12):1763-1772.
- Blumenfeld H. 2010. *Neuroanatomy Through Clinical Cases*. Sunderland, Mass.: Sinauer Associates.
- Bohanna I, Georgiou-Karistianis N, Egan GF. 2011a. Connectivity-based segmentation of the striatum in Huntington's disease: Vulnerability of motor pathways. *Neurobiol. Dis.* 42(3):475-481.
- Bohanna I, Georgiou-Karistianis N, Hannan AJ, Egan GF. 2008. Magnetic resonance imaging as an approach towards identifying neuropathological biomarkers for Huntington's disease. *Brain Research Reviews* 58(1):209-225.
- Bohanna I, Georgiou-Karistianis N, Sritharan A, Asadi H, Johnston L, Churchyard A, Egan G. 2011b. Diffusion Tensor Imaging in Huntington's disease reveals distinct patterns of white matter degeneration associated with motor and cognitive deficits. *Brain Imaging and Behavior* 5(3):171-180.
- Boldrini M, Underwood MD, Hen R, Rosoklija GB, Dwork AJ, John Mann J, Arango V. 2009. Antidepressants increase neural progenitor cells in the human hippocampus. *Neuropsychopharmacology* 34(11):2376-89.
- Burrus CJ, McKinstry SU, Kim N, Ozlu MI, Santoki AV, Fang FY, Ma A, Karadeniz YB, Worthington AK, Dragatsis I and others. 2020. Striatal Projection Neurons Require Huntingtin for Synaptic Connectivity and Survival. *Cell Rep* 30(3):642-657.e6.
- Calabresi P, Centonze D, Pisani A, Bernardi G. 1999. Metabotropic glutamate receptors and cell-type-specific vulnerability in the striatum: implication for ischemia and Huntington's disease. *Exp Neurol* 158(1):97-108.
- Calabresi P, Centonze D, Pisani A, Sancesario G, Gubellini P, Marfia GA, Bernardi G. 1998. Striatal spiny neurons and cholinergic interneurons express differential ionotropic glutamatergic responses and vulnerability: implications for ischemia and Huntington's disease. *Ann Neurol* 43(5):586-97.

- Canals JM, Pineda JR, Torres-Peraza JF, Bosch M, Martin-Ibanez R, Munoz MT, Mengod G, Ernfors P, Alberch J. 2004. Brain-derived neurotrophic factor regulates the onset and severity of motor dysfunction associated with enkephalinergic neuronal degeneration in Huntington's disease. *Journal of Neuroscience* 24(35):7727-7739.
- Chaganti SS, McCusker EA, Loy CT. 2017. What do we know about Late Onset Huntington's Disease? *J Huntingtons Dis* 6(2):95-103.
- Chao YP, Cho KH, Yeh CH, Chou KH, Chen JH, Lin CP. 2009. Probabilistic topography of human corpus callosum using cytoarchitectural parcellation and high angular resolution diffusion imaging tractography. *Hum Brain Mapp* 30(10):3172-87.
- Choi JS, Kim SH, Yoo SY, Kang DH, Kim CW, Lee JM, Kim IY, Kim SI, Kim YY, Kwon JS. 2007. Shape deformity of the corpus striatum in obsessive-compulsive disorder. *Psychiatry Res* 155(3):257-64.
- Chung MK, Dalton KM, Davidson RJ. 2008. Tensor-based cortical surface morphometry via weighted spherical harmonic representation. *IEEE Trans Med Imaging* 27(8):1143-51.
- Ciarochi JA, Calhoun VD, Lourens S, Long JD, Johnson HJ, Bockholt HJ, Liu J, Plis SM, Paulsen JS, Turner JA. 2016. Patterns of Co-Occurring Gray Matter Concentration Loss across the Huntington Disease Prodrome. *Front Neurol* 7:147.
- Colpo GD, Rocha NP, Furr Stimming E, Teixeira AL. 2020. Gene Expression Profiling in Huntington's Disease: Does Comorbidity with Depressive Symptoms Matter? *Int J Mol Sci* 21(22).
- Coppen EM, Jacobs M, van den Berg-Huysmans AA, van der Grond J, Roos RAC. 2018. Grey matter volume loss is associated with specific clinical motor signs in Huntington's disease. *Parkinsonism Relat Disord* 46:56-61.
- Crawford HE, Hobbs NZ, Keogh R, Langbehn DR, Frost C, Johnson H, Landwehrmeyer B, Reilmann R, Craufurd D, Stout JC and others. 2013. Corpus callosal atrophy in premanifest and early Huntington's disease. *J Huntingtons Dis* 2(4):517-26.
- Cummings JL. 1993. Frontal-subcortical circuits and human-behavior. *Archives of Neurology* 50(8):873-880.
- Curtis MA, Low VF, Faull RLM. 2012. Neurogenesis and progenitor cells in the adult human brain: A comparison between hippocampal and subventricular progenitor proliferation. *Developmental Neurobiology* 72(7):990-1005.
- Curtis MA, Penney EB, Pearson AG, van Roon-Mom WMC, Butterworth NJ, Dragunow M, Connor B, Faull RLM. 2003. Increased cell proliferation and neurogenesis in the adult human Huntington's disease brain. *Proceedings of the National Academy of Sciences of the United States of America* 100(15):9023-9027.
- de Campos Vidal B, Mello MLS. 2020. Sodium valproate (VPA) interactions with DNA and histones. *Int J Biol Macromol* 163:219-231.
- Della Nave R, Ginestroni A, Tessa C, Giannelli M, Piacentini S, Filippi M, Mascalchi M. 2010. Regional distribution and clinical correlates of white matter structural damage in Huntington Disease: A tract-based spatial statistics study. *American Journal of Neuroradiology* 31:1675-81.
- Delmaire C, Dumas E, Sharman M, van den Bogaard S, Valabregue R, Jauffret C, Justo D, Reilmann R, Stout J, Craufurd D and others. 2012. The structural correlates of functional deficits in early Huntington's disease. *Hum. Brain Mapp.* 34(9):2141-2153.
- Di Paola M, Luders E, Cherubini A, Sanchez-Castaneda C, Thompson PM, Toga AW, Caltagirone C, Orobello S, Elifani F, Squitieri F and others. 2012. Multimodal MRI analysis of the corpus callosum reveals white matter differences in presymptomatic and early Huntington's disease. *Cereb Cortex* 22(12):2858-66.

- DiFiglia M, Sapp E, Chase KO, Davies SW, Bates GP, Vonsattel JP, Aronin N. 1997. Aggregation of huntingtin in neuronal intranuclear inclusions and dystrophic neurites in brain. *Science* 277(5334):1990-3.
- Dominguez DJ, Egan GF, Gray MA, Poudel GR, Churchyard A, Chua P, Stout JC, Georgiou-Karistianis N. 2013. Multi-modal neuroimaging in premanifest and early Huntington's disease: 18 month longitudinal data from the IMAGE-HD study. *PLOS ONE* 8(9).
- Domínguez DJ, Poudel G, Stout JC, Gray M, Chua P, Borowsky B, Egan GF, Georgiou-Karistianis N. 2017. Longitudinal changes in the fronto-striatal network are associated with executive dysfunction and behavioral dysregulation in Huntington's disease: 30 months IMAGE-HD data. *Cortex* 92:139-149.
- Domínguez JF, Ng AC, Poudel G, Stout JC, Churchyard A, Chua P, Egan GF, Georgiou-Karistianis N. 2016. Iron accumulation in the basal ganglia in Huntington's disease: cross-sectional data from the IMAGE-HD study. *J Neurol Neurosurg Psychiatry* 87(5):545-9.
- Dominguez JF, Stout JC, Poudel G, Churchyard A, Chua P, Egan GF, Georgiou-Karistianis N. 2016. Multimodal imaging biomarkers in premanifest and early Huntington's disease: 30-month IMAGE-HD data. *Br. J. Psychiatry* 208(6):571-8.
- Doty RL, Shaman P, Kimmelman CP, Dann MS. 1984. University of Pennsylvania Smell Identification Test: a rapid quantitative olfactory function test for the clinic. *Laryngoscope* 94(2 Pt 1):176-8.
- Douaud G, Gaura V, Ribeiro MJ, Lethimonnier F, Maroy R, Verny C, Krystkowiak P, Damier P, Bachoud-Levi AC, Hantraye P and others. 2006. Distribution of grey matter atrophy in Huntington's disease patients: A combined ROI-based and voxel-based morphometric study. *Neuroimage* 32(4):1562-1575.
- Draganski B, Kherif F, Kloeppel S, Cook PA, Alexander DC, Parker GJM, Deichmann R, Ashburner J, Frackowiak RSJ. 2008. Evidence for segregated and integrative connectivity patterns in the human basal ganglia. *J. Neurosci.* 28(28):7143-7152.
- Duan WZ, Peng Q, Masuda N, Ford E, Tryggestad E, Ladenheim B, Zhao M, Cadet JL, Wong J, Ross CA. 2008. Sertraline slows disease progression and increases neurogenesis in N171-82Q mouse model of Huntington's disease. *Neurobiology of Disease* 30(3):312-322.
- Dumas EM, van den Bogaard SJA, Ruber ME, Reilman RR, Stout JC, Craufurd D, Hicks SL, Kennard C, Tabrizi SJ, van Buchem MA and others. 2012. Early changes in white matter pathways of the sensorimotor cortex in premanifest Huntington's disease. *Human Brain Mapping* 33(1):203-212.
- Erickson KI, Voss MW, Prakash RS, Basak C, Szabo A, Chaddock L, Kim JS, Heo S, Alves H, White SM and others. 2011. Exercise training increases size of hippocampus and improves memory. *Proceedings of the National Academy of Sciences of the United States of America* 108(7):3017-3022.
- Ernst A, Alkass K, Bernard S, Salehpour M, Perl S, Tisdale J, Possnert G, Druid H, Frisén J. 2014. Neurogenesis in the striatum of the adult human brain. *Cell* 156(5):1072-83.
- Fanselow MS, Dong HW. 2010. Are the dorsal and ventral hippocampus functionally distinct structures? *Neuron* 65(1):7-19.
- Faria AV, Ratnanather JT, Tward DJ, Lee DS, van den Noort F, Wu D, Brown T, Johnson H, Paulsen JS, Ross CA and others. 2016. Linking white matter and deep gray matter alterations in premanifest Huntington disease. *Neuroimage Clin.* 11:450-460.
- Ferrante RJ, Beal MF, Kowall NW, Richardson EP, Jr., Martin JB. 1987a. Sparing of acetylcholinesterase-containing striatal neurons in Huntington's disease. *Brain Res* 411(1):162-6.

- Ferrante RJ, Kowall NW, Beal MF, Martin JB, Bird ED, Richardson EP, Jr. 1987b. Morphologic and histochemical characteristics of a spared subset of striatal neurons in Huntington's disease. *J Neuropathol Exp Neurol* 46(1):12-27.
- Fouquet C, Babayan BM, Watilliaux A, Bontempi B, Tobin C, Rondi-Reig L. 2013. Complementary Roles of the Hippocampus and the Dorsomedial Striatum during Spatial and Sequence-Based Navigation Behavior. *Plos One* 8(6).
- Franklin GL, Camargo CHF, Meira AT, Lima NSC, Teive HAG. 2020. The Role of the Cerebellum in Huntington's Disease: a Systematic Review. *Cerebellum*.
- Fung YL, Ng KET, Vogrin SJ, Meade C, Ngo M, Collins SJ, Bowden SC. 2019. Comparative Utility of Manual versus Automated Segmentation of Hippocampus and Entorhinal Cortex Volumes in a Memory Clinic Sample. *J Alzheimers Dis* 68(1):159-171.
- Furlong LS, Jakabek D, Power BD, Owens-Walton C, Wilkes FA, Walterfang M, Velakoulis D, Egan G, Looi JC, Georgiou-Karistianis N. 2020. Morphometric in vivo evidence of thalamic atrophy correlated with cognitive and motor dysfunction in Huntington's disease: The IMAGE-HD study. *Psychiatry Res Neuroimaging* 298:111048.
- Gabery S, Georgiou-Karistianis N, Lundh SH, Cheong RY, Churchyard A, Chua P, Stout JC, Egan GF, Kirik D, Petersén Å. 2015. Volumetric analysis of the hypothalamus in Huntington Disease using 3T MRI: the IMAGE-HD Study. *PLoS One* 10(2):e0117593.
- Gaura V, Lavisse S, Payoux P, Goldman S, Verny C, Krystkowiak P, Damier P, Supiot F, Bachoud-Levi AC, Remy P. 2017. Association Between Motor Symptoms and Brain Metabolism in Early Huntington Disease. *JAMA Neurol* 74(9):1088-1096.
- Gauthier LR, Charrin BC, Borrell-Pages M, Dompierre JP, Rangone H, Cordelieres FP, De Mey J, MacDonald ME, Lessmann V, Humbert S and others. 2004. Huntingtin controls neurotrophic support and survival of neurons by enhancing BDNF vesicular transport along microtubules. *Cell* 118(1):127-138.
- Georgiou-Karistianis N, Gray MA, Dominguez JF, Dymowski AR, Bohanna I, Johnston LA, Churchyard A, Chua P, Stout JC, Egan GF. 2013a. Automated differentiation of pre-diagnosis Huntington's disease from healthy control individuals based on quadratic discriminant analysis of the basal ganglia: The IMAGE-HD study. *Neurobiol. Dis.* 51:82-92.
- Georgiou-Karistianis N, Poudel GR, Domínguez DJ, Langmaid R, Gray MA, Churchyard A, Chua P, Borowsky B, Egan GF, Stout JC. 2013b. Functional and connectivity changes during working memory in Huntington's disease: 18 month longitudinal data from the IMAGE-HD study. *Brain Cogn* 83(1):80-91.
- Georgiou-Karistianis N, Scahill R, Tabrizi SJ, Squitieri F, Aylward E. 2013c. Structural MRI in Huntington's disease and recommendations for its potential use in clinical trials. *Neurosci. and Biobehav. Rev.* 37(3):480-490.
- Georgiou-Karistianis N, Stout JC, Domínguez DJ, Carron SP, Ando A, Churchyard A, Chua P, Bohanna I, Dymowski AR, Poudel G and others. 2014. Functional magnetic resonance imaging of working memory in Huntington's disease: cross-sectional data from the IMAGE-HD study. *Hum Brain Mapp* 35(5):1847-64.
- Gerig G, Fishbaugh J, Sadeghi N. 2016. Longitudinal modeling of appearance and shape and its potential for clinical use. *Medical Image Analysis* 33:114-121.
- Germeyan SC, Kalikhman D, Jones L, Theodore WH. 2014. Automated versus manual hippocampal segmentation in preoperative and postoperative patients with epilepsy. *Epilepsia* 55(9):1374-9.
- Gil-Mohapel J, Simpson JM, Ghilan M, Christie BR. 2011. Neurogenesis in Huntington's disease: Can studying adult neurogenesis lead to the development of new therapeutic strategies? *Brain Research* 1406:84-105.

- Goh AM, Wibawa P, Loi SM, Walterfang M, Velakoulis D, Looi JC. 2018. Huntington's disease: Neuropsychiatric manifestations of Huntington's disease. *Australas Psychiatry* 26(4):366-375.
- Gonzalez V, Cif L, Biolsi B, Garcia-Ptacek S, Seychelles A, Sanrey E, Descours I, Coubes C, de Moura AM, Corlobe A and others. 2014. Deep brain stimulation for Huntington's disease: long-term results of a prospective open-label study. *J Neurosurg* 121(1):114-22.
- Gottesman II, Gould TD. 2003. The endophenotype concept in psychiatry: etymology and strategic intentions. *Am. J. Psychiatry* 160(4):636-45.
- Granberg T, Bergendal G, Shams S, Aspelin P, Kristoffersen-Wiberg M, Fredrikson S, Martola J. 2015. MRI-Defined Corpus Callosal Atrophy in Multiple Sclerosis: A Comparison of Volumetric Measurements, Corpus Callosum Area and Index. *J Neuroimaging* 25(6):996-1001.
- Gray MA, Egan GF, Ando A, Churchyard A, Chua P, Stout JC, Georgiou-Karistianis N. 2013. Prefrontal activity in Huntington's disease reflects cognitive and neuropsychiatric disturbances: the IMAGE-HD study. *Exp Neurol* 239:218-28.
- Gregory S, Long JD, Klöppel S, Razi A, Scheller E, Minkova L, Johnson EB, Durr A, Roos RAC, Leavitt BR and others. 2018. Testing a longitudinal compensation model in premanifest Huntington's disease. *Brain* 141(7):2156-2166.
- Gregory S, Scahill RI, Seunarine KK, Stopford C, Zhang H, Zhang J, Orth M, Durr A, Roos RA, Langbehn DR and others. 2015. Neuropsychiatry and White Matter Microstructure in Huntington's Disease. *J Huntingtons Dis* 4(3):239-49.
- Grote HE, Bull ND, Howard ML, van Dellen A, Blakemore C, Bartlett PF, Hannan AJ. 2005. Cognitive disorders and neurogenesis deficits in Huntington's disease mice are rescued by fluoxetine. *European Journal of Neuroscience* 22(8):2081-2088.
- Gusella JF, MacDonald ME, Lee JM. 2014. Genetic modifiers of Huntington's disease. *Mov Disord* 29(11):1359-65.
- Gutman BA, Jahanshad N, Ching CR, Wang Y, Kochunov PV, Nichols TE, Thompson PM. 2015. Medial Demons Registration localizes the degree of genetic influence over subcortical shape variability: An N= 1480 Meta-Analysis. *Proc. I.E.E.E. Int. Symp. Biomed. Imaging* 2015:1402-1406.
- Gutman BA, Wang Y, Rajagopalan P, Toga AW, Thompson PM. Shape matching with medial curves and 1-D group-wise registration; 2012 2-5 May 2012. p 716-719.
- Haber SN. 2003. The primate basal ganglia: parallel and integrative networks. *J Chem. Neuroanat.* 26(4):317-30.
- Haber SN, Fudge JL, McFarland NR. 2000. Striatonigrostriatal pathways in primates form an ascending spiral from the shell to the dorsolateral striatum. *J Neurosci* 20(6):2369-82.
- Hampel H, Teipel SJ, Alexander GE, Horwitz B, Teichberg D, Schapiro MB, Rapoport SI. 1998. Corpus callosum atrophy is a possible indicator of region- and cell type-specific neuronal degeneration in Alzheimer disease: a magnetic resonance imaging analysis. *Arch Neurol* 55(2):193-8.
- Heemskerk A, Roos R. 2012. Aspiration pneumonia and death in Huntington's disease. *PLOS Currents Huntington Disease*.
- Herting MM, Johnson C, Mills KL, Vijayakumar N, Dennison M, Liu C, Goddings AL, Dahl RE, Sowell ER, Whittle S and others. 2018. Development of subcortical volumes across adolescence in males and females: A multisample study of longitudinal changes. *Neuroimage* 172:194-205.
- Hervas-Corpcion I, Guiretti D, Alcaraz-Iborra M, Olivares R, Campos-Caro A, Barco A, Valor LM. 2018. Early alteration of epigenetic-related transcription in Huntington's disease mouse models. *Sci Rep* 8(1):9925.

- Ho AK, Gilbert AS, Mason SL, Goodman AO, Barker RA. 2009. Health-related quality of life in Huntington's disease: Which factors matter most? *Mov Disord* 24(4):574-8.
- Hobbs NZ, Barnes J, Frost C, Henley SM, Wild EJ, Macdonald K, Barker RA, Scahill RI, Fox NC, Tabrizi SJ. 2010. Onset and progression of pathologic atrophy in Huntington disease: a longitudinal MR imaging study. *AJNR Am J Neuroradiol* 31(6):1036-41.
- Hobbs NZ, Cole JH, Farmer RE, Rees EM, Crawford HE, Malone IB, Roos RA, Sprengelmeyer R, Durr A, Landwehrmeyer B and others. 2012. Evaluation of multi-modal, multi-site neuroimaging measures in Huntington's disease: Baseline results from the PADDINGTON study. *Neuroimage Clin* 2:204-11.
- Hobbs NZ, Henley SMD, Wild EJ, Leung KK, Frost C, Barker RA, Scahill RI, Barnes J, Tabrizi SJ, Fox NC. 2009. Automated quantification of caudate atrophy by local registration of serial MRI: Evaluation and application in Huntington's disease. *Neuroimage* 47(4):1659-1665.
- Hofer S, Frahm J. 2006. Topography of the human corpus callosum revisited--comprehensive fiber tractography using diffusion tensor magnetic resonance imaging. *Neuroimage* 32(3):989-94.
- Hong S, Fishbaugh J, Rezanejad M, Siddiqi K, Johnson H, Paulsen J, Kim EY, Gerig G. 2017. Subject-Specific Longitudinal Shape Analysis by Coupling Spatiotemporal Shape Modeling with Medial Analysis. *Proc SPIE Int Soc Opt Eng* 10133.
- Hong Y, O'Donnell LJ, Savadjiev P, Zhang F, Wassermann D, Pasternak O, Johnson H, Paulsen J, Vonsattel JP, Makris N and others. 2018. Genetic load determines atrophy in hand cortico-striatal pathways in presymptomatic Huntington's disease. *Hum Brain Mapp* 39(10):3871-3883.
- Horn A, Fox MD. 2020. Opportunities of connectomic neuromodulation. *Neuroimage* 221:117180.
- Huntington Study Group. 1996. Unified Huntington's Disease Rating Scale: reliability and consistency. *Mov. Disord.* 11(2):136-42.
- Jin KL, LaFevre-Bernt M, Sun YJ, Chen S, Gafni J, Crippen D, Logvinova A, Ross CA, Greenberg DA, Ellerby LM. 2005. FGF-2 promotes neurogenesis and neuroprotection and prolongs survival in a transgenic mouse model of Huntington's disease. *Proceedings of the National Academy of Sciences of the United States of America* 102(50):18189-18194.
- Julien CL, Thompson JC, Wild S, Yardumian P, Snowden JS, Turner G, Craufurd D. 2007. Psychiatric disorders in preclinical Huntington's disease. *J Neurol Neurosurg Psychiatry* 78(9):939-43.
- Kachian ZR, Cohen-Zimmerman S, Bega D, Gordon B, Grafman J. 2019. Suicidal ideation and behavior in Huntington's disease: Systematic review and recommendations. *J Affect Disord* 250:319-329.
- Kassubek J, Juengling FD, Kioschies T, Henkel K, Karitzky J, Kramer B, Ecker D, Andrich J, Saft C, Kraus P and others. 2004. Topography of cerebral atrophy in early Huntington's disease: a voxel based morphometric MRI study. *Journal of Neurology Neurosurgery and Psychiatry* 75(2):213-220.
- Kiebertz K, Penney JB, Como P, Ranen N, Shoulson I, Feigin A, Abwender D, Greenamyre JT, Higgins D, Marshall FJ and others. 1996. Unified Huntington's disease rating scale: Reliability and consistency. *Movement Disorders* 11(2):136-142.
- Kiernan JA. 2005. *Barr's The human nervous system: an anatomical viewpoint*: Lippincott Williams and Wilkins.
- Kiernan JA. 2012. Anatomy of the temporal lobe. *Epilepsy Res Treat* 2012:176157.

- Kim H, Kim JH, Possin KL, Winer J, Geschwind MD, Xu D, Hess CP. 2017. Surface-based morphometry reveals caudate subnuclear structural damage in patients with premotor Huntington disease. *Brain Imaging Behav.* 11(5):1365-1372.
- Kim S, Kim KT. 2014. Therapeutic Approaches for Inhibition of Protein Aggregation in Huntington's Disease. *Exp Neurobiol* 23(1):36-44.
- Kipps CM, Duggins AJ, Mahant N, Gomes L, Ashburner J, McCusker EA. 2005. Progression of structural neuropathology in preclinical Huntington's disease: a tensor based morphometry study. *Journal of Neurology Neurosurgery and Psychiatry* 76(5):650-655.
- Kirkwood S, Su J, Conneally P, Foroud T. 2001. Progression of symptoms in the early and middle stages of Huntington Disease. *Archives of Neurology* 58:273-278.
- Kloppel S, Draganski B, Golding CV, Chu C, Nagy Z, Cook PA, Hicks SL, Kennard C, Alexander DC, Parker GJ and others. 2008. White matter connections reflect changes in voluntary-guided saccades in pre-symptomatic Huntington's disease. *Brain* 131(Pt 1):196-204.
- Kloppel S, Draganski B, Siebner HR, Tabrizi SJ, Weiller C, Frackowiak RS. 2009. Functional compensation of motor function in pre-symptomatic Huntington's disease. *Brain* 132(Pt 6):1624-32.
- Klöppel S, Gregory S, Scheller E, Minkova L, Razi A, Durr A, Roos RA, Leavitt BR, Papoutsis M, Landwehrmeyer GB and others. 2015. Compensation in Preclinical Huntington's Disease: Evidence From the Track-On HD Study. *EBioMedicine* 2(10):1420-9.
- Knierim JJ, Neunuebel JP, Deshmukh SS. 2014. Functional correlates of the lateral and medial entorhinal cortex: objects, path integration and local-global reference frames. *Philos Trans R Soc Lond B Biol Sci* 369(1635):20130369.
- Koutsis G, Karadima G, Kladi A, Panas M. 2013. The challenge of juvenile Huntington disease: to test or not to test. *Neurology* 80(11):990-6.
- Langbehn DR, Brinkman RR, Falush D, Paulsen JS, Hayden MR, International Huntingtons Disease Collaborative Group. 2004. A new model for prediction of the age of onset and penetrance for Huntington's disease based on CAG length. *Clin. Gen.* 65(4):267-277.
- Langbehn DR, Stout JC, Gregory S, Mills JA, Durr A, Leavitt BR, Roos RAC, Long JD, Owen G, Johnson HJ and others. 2019. Association of CAG Repeats With Long-term Progression in Huntington Disease. *JAMA Neurol.*
- Lee JK, Mathews K, Schlaggar B, Perlmutter J, Paulsen JS, Epping E, Burmeister L, Nopoulos P. 2012. Measures of growth in children at risk for Huntington disease. *Neurology* 79(7):668-674.
- Lee JM, Ivanova EV, Seong IS, Cashorali T, Kohane I, Gusella JF, MacDonald ME. 2007. Unbiased gene expression analysis implicates the huntingtin polyglutamine tract in extra-mitochondrial energy metabolism. *PLoS Genet* 3(8):e135.
- Levitt JJ, Styner M, Niethammer M, Bouix S, Koo MS, Voglmaier MM, Dickey CC, Niznikiewicz MA, Kikinis R, McCarley RW and others. 2009. Shape abnormalities of caudate nucleus in schizotypal personality disorder. *Schizophrenia Research* 110(1-3):127-139.
- Li XJ, Li S. 2011. Proteasomal dysfunction in aging and Huntington disease. *Neurobiol Dis* 43(1):4-8.
- Li Y, Yui DS, Luikart BW, McKay RM, Li YJ, Rubenstein JL, Parada LF. 2012. Conditional ablation of brain-derived neurotrophic factor-TrkB signaling impairs striatal neuron development. *Proceedings of the National Academy of Sciences of the United States of America* 109(38):15491-15496.



- Lindberg O, Walterfang M, Looi JCL, Malykhin N, Ostberg P, Zandbelt B, Styner M, Paniagua B, Velakoulis D, Orndahl E and others. 2012. Hippocampal Shape Analysis in Alzheimer's Disease and Frontotemporal Lobar Degeneration Subtypes. *Journal of Alzheimers Disease* 30(2):355-365.
- Liston C, Watts R, Tottenham N, Davidson MC, Niogi S, Ulug AM, Casey BJ. 2006. Frontostriatal microstructure modulates efficient recruitment of cognitive control. *Cereb. Cortex* 16(4):553-60.
- Loi SM, Walterfang M, Velakoulis D, Looi JC. 2018. Huntington's disease: Managing neuropsychiatric symptoms in Huntington's disease. *Australas Psychiatry* 26(4):376-380.
- Looi JC, Velakoulis D, Walterfang M, Georgiou-Karistianis N, Macfarlane MD, Power BD, Nilsson C, Styner M, Thompson PM, Van Westen D and others. 2014a. The Australian, US, Scandinavian Imaging Exchange (AUSSIE): an innovative, virtually-integrated health research network embedded in health care. *Australas Psychiatry* 22(3):260-265.
- Looi JC, Walterfang M, Styner M, Niethammer M, Svensson LA, Lindberg O, Ostberg P, Botes L, Orndahl E, Chua P and others. 2011. Shape analysis of the neostriatum in subtypes of frontotemporal lobar degeneration: neuroanatomically significant regional morphologic change. *Psychiatry Res* 191(2):98-111.
- Looi JCL, Lindberg O, Liberg B, Tatham V, Kumar R, Maller J, Millard E, Sachdev P, Hogberg G, Pagani M and others. 2008. Volumetrics of the caudate nucleus: Reliability and validity of a new manual tracing protocol. *Psychiatry Res.: Neuroimaging* 163(3):279-288.
- Looi JCL, Rajagopalan P, Walterfang M, Madsen SK, Thompson PM, Macfarlane MD, Ching C, Chua P, Velakoulis D. 2012. Differential putaminal morphology in Huntington's disease, frontotemporal dementia and Alzheimer's disease. *Aust. N.Z. J. Psychiatry*.
- Looi JCL, Santillo AF. 2017. Time and relative dimensions in syndromology: Towards endophenotypes in neurology, psychiatry and in-between. *Aust. N. Z. J. Psychiatry* 51(11):1079-1081.
- Looi JCL, Svensson L, Lindberg O, Zandbelt BB, Ostberg P, Orndahl E, Wahlund LO. 2009. Putaminal volume in frontotemporal lobar degeneration and Alzheimer disease: differential volumes in dementia subtypes and controls. *Am. J. Neuroradiology* 30(8):1552-1560.
- Looi JCL, Walterfang M. 2012. Striatal morphology as a biomarker in neurodegenerative disease. *Mol. Psychiatry* 18(4):417-424.
- Looi JCL, Walterfang M, Nilsson C, Power BD, van Westen D, Velakoulis D, Wahlund LO, Thompson PM. 2014b. The subcortical connectome: hubs, spokes and the space between - a vision for further research in neurodegenerative disease. *Aust. N. Z. J. Psychiatry* 48(4):306-9.
- Low VF, Dragunow M, Tippett LJ, Faull RL, Curtis MA. 2011. No change in progenitor cell proliferation in the hippocampus in Huntington's disease. *Neuroscience* 199:577-88.
- Luders E, Toga AW, Thompson PM. 2014. Why size matters: differences in brain volume account for apparent sex differences in callosal anatomy: the sexual dimorphism of the corpus callosum. *Neuroimage* 84:820-4.
- Mackay-Sim A, Doty, R.L. 2001. The University of Pennsylvania Smell Identification Test: Normative adjustment for Australian subjects. *Australian Journal of Oto-Laryngology* 4:174-177.

- MacLeod CM, MacDonald PA. 2000. Interdimensional interference in the Stroop effect: uncovering the cognitive and neural anatomy of attention. *Trends Cogn. Sci.* 4(10):383-391.
- Maguire EA, Gadian DG, Johnsrude IS, Good CD, Ashburner J, Frackowiak RS, Frith CD. 2000. Navigation-related structural change in the hippocampi of taxi drivers. *Proc Natl Acad Sci U S A* 97(8):4398-403.
- Majid DSA, Aron AR, Thompson W, Sheldon S, Hamza S, Stoffers D, Holland D, Goldstein J, Corey-Bloom J, Dale AM. 2011. Basal ganglia atrophy in prodromal Huntington's disease is detectable over one year using automated segmentation. *Movement Disorders* 26(14):2544-2551.
- Mangalore S, Mukku SSR, Vankayalapati S, Sivakumar PT, Varghese M. 2021. Shape Profile of Corpus Callosum As a Signature to Phenotype Different Dementia. *J Neurosci Rural Pract* 12(1):185-192.
- Mangin JF, Rivière D, Duchesnay E, Cointepas Y, Gaura V, Verny C, Damier P, Krystkowiak P, Bachoud-Lévi AC, Hantraye P and others. 2020. Neocortical morphometry in Huntington's disease: Indication of the coexistence of abnormal neurodevelopmental and neurodegenerative processes. *Neuroimage Clin* 26:102211.
- Marrakchi-Kacem L, Delmaire C, Guevara P, Poupon F, Lecomte S, Tucholka A, Roca P, Yelnik J, Durr A, Mangin JF and others. 2013. Mapping cortico-striatal connectivity onto the cortical surface: a new tractography-based approach to study Huntington disease. *PLoS One* 8(2):e53135.
- McColgan P, Gregory S, Seunarine KK, Razi A, Papoutsis M, Johnson E, Durr A, Roos RAC, Leavitt BR, Holmans P and others. 2018. Brain Regions Showing White Matter Loss in Huntington's Disease Are Enriched for Synaptic and Metabolic Genes. *Biol Psychiatry* 83(5):456-465.
- McColgan P, Tabrizi SJ. 2018. Huntington's disease: a clinical review. *Eur J Neurol* 25(1):24-34.
- McDonald RJ, White NM. 1994. Parallel information processing in the water maze: evidence for independent memory systems involving dorsal striatum and hippocampus. *Behav Neural Biol* 61(3):260-70.
- McKinnon MC, Yucel K, Nazarov A, MacQueen GM. 2009. A meta-analysis examining clinical predictors of hippocampal volume in patients with major depressive disorder. *J Psychiatry Neurosci* 34(1):41-54.
- Medina L, Figueredo-Cardenas G, Reiner A. 1996. Differential abundance of superoxide dismutase in interneurons versus projection neurons and in matrix versus striosome neurons in monkey striatum. *Brain Res* 708(1-2):59-70.
- Milardi D, Arrigo A, Anastasi G, Cacciola A, Marino S, Mormina E, Calamuneri A, Bruschetta D, Cutroneo G, Trimarchi F and others. 2016. Extensive Direct Subcortical Cerebellum-Basal Ganglia Connections in Human Brain as Revealed by Constrained Spherical Deconvolution Tractography. *Front Neuroanat* 10:29.
- Misiura MB, Lourens S, Calhoun VD, Long J, Bockholt J, Johnson H, Zhang Y, Paulsen JS, Turner JA, Liu J and others. 2017. Cognitive control, learning, and clinical motor ratings are most highly associated with basal ganglia brain volumes in the premanifest Huntington's Disease phenotype. *J. Int. Neuropsychol. Soc.* 23(2):159-170.
- Molina-Ruiz RM, Looi JCL, Walterfang M, García-Saiz T, Wilkes FA, Liu LL, Velakoulis D, Perera JLC, Diaz-Marsa M. 2020. Striatal volumes as potential biomarkers in Eating Disorders: A pilot study. *Rev Psiquiatr Salud Ment.*
- Morey RA, Petty CM, Xu Y, Hayes JP, Wagner HR, 2nd, Lewis DV, LaBar KS, Styner M, McCarthy G. 2009. A comparison of automated segmentation and manual tracing for quantifying hippocampal and amygdala volumes. *Neuroimage* 45(3):855-66.

- Morigaki R, Goto S. 2017. Striatal Vulnerability in Huntington's Disease: Neuroprotection Versus Neurotoxicity. *Brain Sci* 7(6).
- Moser MB, Moser EI. 1998. Functional differentiation in the hippocampus. *Hippocampus* 8(6):608-19.
- Muirhead N, Benjamin E, Saleh H. 2013. Is the University of Pennsylvania Smell Identification Test (UPSIT) valid for the UK population? *The Otorhinolaryngologist* 6(2):99-103.
- Muralidharan P, Fishbaugh J, Johnson HJ, Durrleman S, Paulsen JS, Gerig G, Fletcher PT. 2014. Diffeomorphic shape trajectories for improved longitudinal segmentation and statistics. *Med Image Comput Comput Assist Interv* 17(Pt 3):49-56.
- Muralidharan P, Fishbaugh J, Kim EY, Johnson HJ, Paulsen JS, Gerig G, Fletcher PT. 2016. Bayesian Covariate Selection in Mixed-Effects Models For Longitudinal Shape Analysis. *Proc IEEE Int Symp Biomed Imaging* 2016:656-659.
- Nasir J, Floresco SB, O'Kusky JR, Diewert VM, Richman JM, Zeisler J, Borowski A, Marth JD, Phillips AG, Hayden MR. 1995. Targeted disruption of the Huntington's disease gene results in embryonic lethality and behavioral and morphological changes in heterozygotes. *Cell* 81(5):811-23.
- Nelson HE, Willison J. 1991. National adult reading test, 2nd Edition. Windsor: NFER-Nelson.
- Nogovitsyn N, Muller M, Souza R, Hassel S, Arnott SR, Davis AD, Hall GB, Harris JK, Zamyadi M, Metzrak PD and others. 2020. Hippocampal tail volume as a predictive biomarker of antidepressant treatment outcomes in patients with major depressive disorder: a CAN-BIND report. *Neuropsychopharmacology* 45(2):283-291.
- Nolan M, Roman E, Nasa A, Levins KJ, O'Hanlon E, O'Keane V, Willian Roddy D. 2020. Hippocampal and Amygdalar Volume Changes in Major Depressive Disorder: A Targeted Review and Focus on Stress. *Chronic Stress (Thousand Oaks)* 4:2470547020944553.
- Nopoulos PC, Aylward EH, Ross CA, Johnson HJ, Magnotta VA, Juhl AR, Pierson RK, Mills J, Langbehn DR, Paulsen JS and others. 2010. Cerebral cortex structure in prodromal Huntington disease. *Neurobiology of Disease* 40(3):544-554.
- Nopoulos PC, Aylward EH, Ross CA, Mills JA, Langbehn DR, Johnson HJ, Magnotta VA, Pierson RK, Beglinger LJ, Nance MA and others. 2011. Smaller intracranial volume in prodromal Huntington's disease: evidence for abnormal neurodevelopment. *Brain* 134:137-142.
- Ong D, Walterfang M, Malhi GS, Styner M, Velakoulis D, Pantelis C. 2012. Size and shape of the caudate nucleus in individuals with bipolar affective disorder. *Aust N Z J Psychiatry* 46(4):340-51.
- Paulsen JS, Langbehn DR, Stout JC, Aylward E, Ross CA, Nance M, Guttman M, Johnson S, MacDonald M, Beglinger LJ and others. 2008. Detection of Huntington's disease decades before diagnosis: the Predict-HD study. *J. Neurol. Neurosurg. Psychiatry* 79(8):874-880.
- Paulsen JS, Miller AC, Hayes T, Shaw E. 2017. Cognitive and behavioral changes in Huntington disease before diagnosis. *Handb Clin Neurol* 144:69-91.
- Paulsen JS, Ready RE, Hamilton JM, Mega MS, Cummings JL. 2001. Neuropsychiatric aspects of Huntington's disease. *J Neurol Neurosurg Psychiatry* 71(3):310-4.
- Peltsch A, Hoffman A, Armstrong I, Pari G, Munoz DP. 2008. Saccadic impairments in Huntington's disease. *Exp Brain Res* 186(3):457-69.
- Peng Q, Masuda N, Jiang M, Li Q, Zhao M, Ross CA, Duan W. 2008. The antidepressant sertraline improves the phenotype, promotes neurogenesis and increases BDNF levels

- in the R6/2 Huntington's disease mouse model. *Experimental Neurology* 210(1):154-163.
- Phillips JL, Batten LA, Tremblay P, Aldosary F, Blier P. 2015. A Prospective, Longitudinal Study of the Effect of Remission on Cortical Thickness and Hippocampal Volume in Patients with Treatment-Resistant Depression. *Int J Neuropsychopharmacol* 18(8).
- Phillips O, Sanchez-Castaneda C, Elifani F, Maglione V, Di Pardo A, Caltagirone C, Squitieri F, Sabatini U, Di Paola M. 2013. Tractography of the corpus callosum in Huntington's disease. *Plos One* 8(9).
- Possin KL, Kim H, Geschwind MD, Moskowitz T, Johnson ET, Sha SJ, Apple A, Xu D, Miller BL, Finkbeiner S and others. 2017. Egocentric and allocentric visuospatial working memory in premotor Huntington's disease: A double dissociation with caudate and hippocampal volumes. *Neuropsychologia* 101:57-64.
- Poudel GR, Driscoll S, Domínguez DJ, Stout JC, Churchyard A, Chua P, Egan GF, Georgiou-Karistianis N. 2015a. Functional Brain Correlates of Neuropsychiatric Symptoms in Presymptomatic Huntington's Disease: The IMAGE-HD Study. *J Huntingtons Dis* 4(4):325-32.
- Poudel GR, Egan GF, Churchyard A, Chua P, Stout JC, Georgiou-Karistianis N. 2014a. Abnormal synchrony of resting state networks in premanifest and symptomatic Huntington disease: the IMAGE-HD study. *J Psychiatry Neurosci* 39(2):87-96.
- Poudel GR, Harding IH, Egan GF, Georgiou-Karistianis N. 2019. Network spread determines severity of degeneration and disconnection in Huntington's disease. *Hum Brain Mapp* 40(14):4192-4201.
- Poudel GR, Stout JC, Domínguez DJ, Churchyard A, Chua P, Egan GF, Georgiou-Karistianis N. 2015b. Longitudinal change in white matter microstructure in Huntington's disease: The IMAGE-HD study. *Neurobiol Dis* 74:406-12.
- Poudel GR, Stout JC, Domínguez DJ, Gray MA, Salmon L, Churchyard A, Chua P, Borowsky B, Egan GF, Georgiou-Karistianis N. 2015c. Functional changes during working memory in Huntington's disease: 30-month longitudinal data from the IMAGE-HD study. *Brain Struct Funct* 220(1):501-12.
- Poudel GR, Stout JC, Dominguez DJ, Salmon L, Churchyard A, Chua P, Georgiou-Karistianis N, Egan GF. 2014b. White matter connectivity reflects clinical and cognitive status in Huntington's disease. *Neurobiol Dis* 65:180-7.
- Power BD, Looi JC. 2015. The thalamus as a putative biomarker in neurodegenerative disorders. *Aust N Z J Psychiatry* 49(6):502-18.
- Purves P, Cabeza R., Huettel, S., LaBar, K., Platt, M., Woldorff, M. 2012. *Principles of Cognitive Neuroscience*. Sunderland, MA.: Sinauer Associates, Inc. .
- Qiu A, Brown T, Fischl B, Ma J, Miller MI. 2010. Atlas generation for subcortical and ventricular structures with its applications in shape analysis. *IEEE Trans Image Process* 19(6):1539-47.
- Ramirez-Garcia G, Galvez V, Diaz R, Bayliss L, Fernandez-Ruiz J, Campos-Romo A. 2020. Longitudinal atrophy characterization of cortical and subcortical gray matter in Huntington's disease patients. *Eur J Neurosci* 51(8):1827-1843.
- Ransome MI, Renoir T, Hannan AJ. 2012. Hippocampal Neurogenesis, Cognitive Deficits and Affective Disorder in Huntington's Disease. *Neural Plasticity*.
- Ratovitski T, Chighladze E, Arbez N, Boronina T, Herbrich S, Cole RN, Ross CA. 2012. Huntingtin protein interactions altered by polyglutamine expansion as determined by quantitative proteomic analysis. *Cell Cycle* 11(10):2006-21.
- Rawlins MD, Wexler NS, Wexler AR, Tabrizi SJ, Douglas I, Evans SJ, Smeeth L. 2016. The Prevalence of Huntington's Disease. *Neuroepidemiology* 46(2):144-53.

- Reiner A, Deng YP. 2018. Disrupted striatal neuron inputs and outputs in Huntington's disease. *CNS Neurosci Ther* 24(4):250-280.
- Rigamonti D, Bauer JH, De-Fraja C, Conti L, Sipione S, Sciorati C, Clementi E, Hackam A, Hayden MR, Li Y and others. 2000. Wild-type huntingtin protects from apoptosis upstream of caspase-3. *J Neurosci* 20(10):3705-13.
- Rigamonti D, Sipione S, Goffredo D, Zuccato C, Fossale E, Cattaneo E. 2001. Huntingtin's neuroprotective activity occurs via inhibition of procaspase-9 processing. *J Biol Chem* 276(18):14545-8.
- Roos R, Pruyt J, de Vries J, Bots G. 1985. Neuronal distribution in the putamen in Huntington's disease. *Journal of Neurology, Neurosurgery and Psychiatry* 48(5):422-5.
- Rosas HD, Lee SY, Bender AC, Zaleta AK, Vangel M, Yu P, Fischl B, Pappu V, Onorato C, Cha JH and others. 2010. Altered white matter microstructure in the corpus callosum in Huntington's disease: Implications for cortical "disconnection". *Neuroimage* 49(4):2995-3004.
- Rosas HD, Reuter M, Doros G, Lee SY, Triggs T, Malarick K, Fischl B, Salat DH, Hersch SM. 2011. A Tale of Two Factors: What Determines the Rate of Progression in Huntington's Disease? A Longitudinal MRI Study. *Movement Disorders* 26(9):1691-1697.
- Rosas HD, Salat DH, Lee SY, Zaleta AK, Pappu V, Fischl B, Greve D, Hevelone N, Hersch SM. 2008. Cerebral cortex and the clinical expression of Huntington's disease: complexity and heterogeneity. *Brain* 131:1057-1068.
- Rosas HD, Tuch DS, Hevelone ND, Zaleta AK, Vangel M, Hersch SM, Salat DH. 2006. Diffusion tensor imaging in presymptomatic and early Huntington's disease: Selective white matter pathology and its relationship to clinical measures. *Movement Disorders* 21(9):1317-1325.
- Rosen AC, Sugiura L, Kramer JH, Whitfield-Gabrieli S, Gabrieli JD. 2011. Cognitive Training Changes Hippocampal Function in Mild Cognitive Impairment: A Pilot Study. *Journal of Alzheimers Disease* 26:349-357.
- Rosenblatt A, Kumar BV, Mo A, Welsh CS, Margolis RL, Ross CA. 2012. Age, CAG repeat length, and clinical progression in Huntington's disease. *Movement Disorders* 27(2):272-276.
- Rosenblatt A, Liang KY, Zhou H, Abbott MH, Gourley LM, Margolis RL, Brandt J, Ross CA. 2006. The association of CAG repeat length with clinical progression in Huntington disease. *Neurology* 66(7):1016-1020.
- Ross CA, Tabrizi SJ. 2011. Huntington's disease: from molecular pathogenesis to clinical treatment. *Lancet Neurol.* 10(1):83-98.
- Rossi S, Prosperetti C, Picconi B, De Chiara V, Mataluni G, Bernardi G, Calabresi P, Centonze D. 2006. Deficits of glutamate transmission in the striatum of toxic and genetic models of Huntington's disease. *Neurosci Lett* 410(1):6-10.
- Rowe KC, Paulsen JS, Langbehn DR, Wang C, Mills J, Beglinger LJ, Smith MM, Epping EA, Fiedorowicz JG, Duff K and others. 2012. Patterns of serotonergic antidepressant usage in prodromal Huntington disease. *Psychiatry Research* 196(2-3):309-314.
- Rubinsztein DC, Leggo J, Coles R, Almqvist E, Biancalana V, Cassiman JJ, Chotai K, Connarty M, Craufurd D, Curtis A and others. 1996. Phenotypic characterization of individuals with 30-40 CAG repeats in the Huntington disease (HD) gene reveals HD cases with 36 repeats and apparently normal elderly individuals with 36-39 repeats. *American Journal of Human Genetics* 59(1):16-22.
- Ruocco HH, Bonilha L, Li LM, Lopes-Cendes I, Cendes F. 2008. Longitudinal analysis of regional grey matter loss in Huntington disease: effects of the length of the expanded CAG repeat. *J Neurol Neurosurg Psychiatry* 79(2):130-5.

- Sadeh T, Shohamy D, Levy DR, Reggev N, Maril A. 2011. Cooperation between the hippocampus and the striatum during episodic encoding. *J Cogn Neurosci* 23(7):1597-608.
- Sassone J, Colciago C, Cislachi G, Silani V, Ciammola A. 2009. Huntington's disease: the current state of research with peripheral tissues. *Exp Neurol* 219(2):385-97.
- Saudou F, Humbert S. 2016. The Biology of Huntingtin. *Neuron* 89(5):910-26.
- Scahill RI, Hobbs NZ, Say MJ, Bechtel N, Henley SM, Hyare H, Langbehn DR, Jones R, Leavitt BR, Roos RA and others. 2013. Clinical impairment in premanifest and early Huntington's disease is associated with regionally specific atrophy. *Hum Brain Mapp* 34(3):519-29.
- Scahill RI, Zeun P, Osborne-Crowley K, Johnson EB, Gregory S, Parker C, Lowe J, Nair A, O'Callaghan C, Langley C and others. 2020. Biological and clinical characteristics of gene carriers far from predicted onset in the Huntington's disease Young Adult Study (HD-YAS): a cross-sectional analysis. *Lancet Neurol* 19(6):502-512.
- Sellers J, Ridner SH, Claassen DO. 2020. A Systematic Review of Neuropsychiatric Symptoms and Functional Capacity in Huntington's Disease. *J Neuropsychiatry Clin Neurosci* 32(2):109-124.
- Seredenina T, Luthi-Carter R. 2012. What have we learned from gene expression profiles in Huntington's disease? *Neurobiol Dis* 45(1):83-98.
- Shishegar R, Rajapakse S, Georgiou-Karistianis N. 2019. Altered Cortical Morphometry in Pre-manifest Huntington's Disease: Cross-sectional Data from the IMAGE-HD Study. *Conf Proc IEEE Eng Med Biol Soc* 2019:2844-2847.
- Smarr KL, Keefer AL. 2011. Measures of depression and depressive symptoms: Beck Depression Inventory-II (BDI-II), Center for Epidemiologic Studies Depression Scale (CES-D), Geriatric Depression Scale (GDS), Hospital Anxiety and Depression Scale (HADS), and Patient Health Questionnaire-9 (PHQ-9). *Arthritis Care Res (Hoboken)* 63 Suppl 11:S454-66.
- Smith A. 1982. Symbol Digit Modality Test (SDMT): Manual (Revised). Los Angeles: Psychological Services.
- Soloveva MV, Jamadar SD, Velakoulis D, Poudel G, Georgiou-Karistianis N. 2020. Brain compensation during visuospatial working memory in premanifest Huntington's disease. *Neuropsychologia* 136:107262.
- Solowij N, Walterfang M, Lubman DI, Whittle S, Lorenzetti V, Styner M, Velakoulis D, Pantelis C, Yuecel M. 2013. Alteration to hippocampal shape in cannabis users with and without schizophrenia. *Schizophrenia Research* 143(1):179-184.
- Sørensen S, Fenger K. 1992. Causes of death in patients with Huntington's disease and in unaffected first degree relatives. *Journal of Medical Genetics* 29(12):911-14.
- Spalding KL, Bergmann O, Alkass K, Bernard S, Salehpour M, Huttner HB, Boström E, Westerlund I, Vial C, Buchholz BA and others. 2013. Dynamics of hippocampal neurogenesis in adult humans. *Cell* 153(6):1219-1227.
- Sritharan A, Egan GF, Johnston L, Horne M, Bradshaw JL, Bohanna I, Asadi H, Cunningham R, Churchyard AJ, Chua P and others. 2010. A longitudinal diffusion tensor imaging study in symptomatic Huntington's disease. *Journal of Neurology Neurosurgery and Psychiatry* 81(3):257-262.
- Stahl CM, Feigin A. 2020. Medical, Surgical, and Genetic Treatment of Huntington Disease. *Neurol Clin* 38(2):367-378.
- Stout JC, Paulsen JS, Queller S, Solomon AC, Whitlock KB, Campbell JC, Carlozzi N, Duff K, Beglinger LJ, Langbehn DR and others. 2011. Neurocognitive signs in prodromal Huntington Disease. *Neuropsychol.* 25(1):1-14.

- Stout JC, Ready RE, Grace J, Malloy PF, Paulsen JS. 2003. Factor analysis of the frontal systems behavior scale (FrSBe). *Assessment* 10(1):79-85.
- Strange BA, Witter MP, Lein ES, Moser EI. 2014. Functional organization of the hippocampal longitudinal axis. *Nat Rev Neurosci* 15(10):655-69.
- Stroop JR. 1935. Studies of interference in serial verbal reactions. *J. Exp. Psychol.* 18(6):643-662.
- Styner M, Oguz I, Xu S, Brechbühler C, Pantazis D, Levitt J, Shenton M, Gerig G. 2006. Framework for the statistical shape analysis of brain structures using SPHARM-PDM. *Insight Journal* 1071:242-50.
- Subramaniam S, Sixt KM, Barrow R, Snyder SH. 2009. Rhes, a striatal specific protein, mediates mutant-huntingtin cytotoxicity. *Science* 324(5932):1327-30.
- Sun YM, Zhang YB, Wu ZY. 2017. Huntington's Disease: Relationship Between Phenotype and Genotype. *Mol Neurobiol* 54(1):342-348.
- Tabrizi SJ, Langbehn DR, Leavitt BR, Roos RAC, Durr A, Craufurd D, Kennard C, Hicks SL, Fox NC, Scahill RI and others. 2009. Biological and clinical manifestations of Huntington's disease in the longitudinal TRACK-HD study: cross-sectional analysis of baseline data. *Lancet Neurol.* 8(9):791-801.
- Tabrizi SJ, Scahill RI, Durr A, Roos RAC, Leavitt BR, Jones R, Landwehrmeyer GB, Fox NC, Johnson H, Hicks SL and others. 2011. Biological and clinical changes in premanifest and early stage Huntington's disease in the TRACK-HD study: the 12-month longitudinal analysis. *Lancet Neurology* 10(1):31-42.
- Tabrizi SJ, Workman J, Hart PE, Mangiarini L, Mahal A, Bates G, Cooper JM, Schapira AH. 2000. Mitochondrial dysfunction and free radical damage in the Huntington R6/2 transgenic mouse. *Ann Neurol* 47(1):80-6.
- Tang X, Ross CA, Johnson H, Paulsen JS, Younes L, Albin RL, Ratnanather JT, Miller MI. 2019. Regional subcortical shape analysis in premanifest Huntington's disease. *Hum. Brain Mapp.* 40(5):1419-1433.
- Tate DF, Wade BS, Velez CS, Drennon AM, Bolzenius J, Gutman BA, Thompson PM, Lewis JD, Wilde EA, Bigler ED and others. 2016. Volumetric and shape analyses of subcortical structures in United States service members with mild traumatic brain injury. *J Neurol* 263(10):2065-79.
- Tate DF, Wade BSC, Velez CS, Drennon AM, Bolzenius JD, Cooper DB, Kennedy JE, Reid MW, Bowles AO, Thompson PM and others. 2019. Subcortical shape and neuropsychological function among U.S. service members with mild traumatic brain injury. *Brain Imaging Behav.* 13(2):377-388.
- Teipel SJ, Bayer W, Alexander GE, Bokde AL, Zebuhr Y, Teichberg D, Müller-Spahn F, Schapiro MB, Möller HJ, Rapoport SI and others. 2003. Regional pattern of hippocampus and corpus callosum atrophy in Alzheimer's disease in relation to dementia severity: evidence for early neocortical degeneration. *Neurobiol Aging* 24(1):85-94.
- Teipel SJ, Bayer W, Alexander GE, Zebuhr Y, Teichberg D, Kulic L, Schapiro MB, Möller HJ, Rapoport SI, Hampel H. 2002. Progression of corpus callosum atrophy in Alzheimer disease. *Arch Neurol* 59(2):243-8.
- Teisberg P. 1995. The genetic background of anticipation. *J R Soc Med* 88(4):185-7.
- Tereshchenko AV, Schultz JL, Bruss JE, Magnotta VA, Epping EA, Nopoulos PC. 2020. Abnormal development of cerebellar-striatal circuitry in Huntington disease. *Neurology* 94(18):e1908-e1915.
- The Huntington's Disease Research Group. 1993. A novel gene containing a trinucleotide repeat that is expanded and unstable on Huntington's disease chromosomes. *Cell* 72(6):971-83.

- Thompson JC, Harris J, Sollom AC, Stopford CL, Howard E, Snowden JS, Craufurd D. 2012. Longitudinal evaluation of neuropsychiatric symptoms in Huntington's disease. *J Neuropsychiatry Clin Neurosci* 24(1):53-60.
- Thompson PM, Hayashi KM, De Zubicaray GI, Janke AL, Rose SE, Semple J, Hong MS, Herman DH, Gravano D, Doddrell DM and others. 2004. Mapping hippocampal and ventricular change in Alzheimer disease. *Neuroimage* 22(4):1754-66.
- Thompson PM, Jahanshad N, Ching CRK, Salminen LE, Thomopoulos SI, Bright J, Baune BT, Bertolín S, Bralten J, Bruin WB and others. 2020. ENIGMA and global neuroscience: A decade of large-scale studies of the brain in health and disease across more than 40 countries. *Transl Psychiatry* 10(1):100.
- Tulving E. 2002. Episodic memory: from mind to brain. *Annu Rev Psychol* 53:1-25.
- Turner LM, Jakabek D, Wilkes FA, Croft RJ, Churchyard A, Walterfang M, Velakoulis D, Looi JC, Georgiou-Karistianis N, Apthorp D. 2016. Striatal morphology correlates with frontostriatal electrophysiological motor processing in Huntington's disease: an IMAGE-HD study. *Brain Behav.* 6(12):e00511.
- van den Bogaard SJA, Dumas EM, Acharya TP, Johnson H, Langbehn DR, Scahill RI, Tabrizi SJ, van Buchem MA, van der Grond J, Roos RAC and others. 2011a. Early atrophy of pallidum and accumbens nucleus in Huntington's disease. *J. Neurol.* 258(3):412-420.
- van den Bogaard SJA, Dumas EM, Ferrarini L, Milles J, van Buchem MA, van der Grond J, Roos RAC. 2011b. Shape analysis of subcortical nuclei in Huntington's disease, global versus local atrophy - Results from the TRACK-HD study. *J. Neurol. Sci.* 307(1-2):60-68.
- van der Plas E, Langbehn DR, Conrad AL, Kosciuk TR, Tereshchenko A, Epping EA, Magnotta VA, Nopoulos PC. 2019. Abnormal brain development in child and adolescent carriers of mutant huntingtin. *Neurology* 93(10):e1021-e1030.
- van Duijn E, Craufurd D, Hubers AA, Giltay EJ, Bonelli R, Rickards H, Anderson KE, van Walsem MR, van der Mast RC, Orth M and others. 2014. Neuropsychiatric symptoms in a European Huntington's disease cohort (REGISTRY). *J Neurol Neurosurg Psychiatry* 85(12):1411-8.
- van Duijn E, Kingma EM, van der Mast RC. 2007. Psychopathology in verified Huntington's disease gene carriers. *J. Neuropsychiatry Clin. Neurosci.* 19(4):441-448.
- Velakoulis D, Pantelis C, McGorry PD, Dudgeon P, Brewer W, Cook M, Desmond P, Bridle N, Tierney P, Murrie V and others. 1999. Hippocampal volume in first-episode psychoses and chronic schizophrenia - A high-resolution magnetic resonance imaging study. *Archives of General Psychiatry* 56(2):133-141.
- Voermans NC, Petersson KM, Daudey L, Weber B, van Spaendonck KP, Kremer HPH, Fernandez G. 2004. Interaction between the human hippocampus and the caudate nucleus during route recognition. *Neuron* 43(3):427-435.
- Vonsattel JP, Myers RH, Stevens TJ, Ferrante RJ, Bird ED, Richardson EP, Jr. 1985. Neuropathological classification of Huntington's disease. *J Neuropathol Exp Neurol* 44(6):559-77.
- Vonsattel JPG, DiFiglia M. 1998. Huntington disease. *Journal of Neuropathology and Experimental Neurology* 57(5):369-384.
- Wachinger C, Salat DH, Weiner M, Reuter M. 2016. Whole-brain analysis reveals increased neuroanatomical asymmetries in dementia for hippocampus and amygdala. *Brain* 139(12):3253-3266.
- Walker FO. 2007. Huntington's disease. *Lancet* 369(9557):218-28.



- Walterfang M, Looi JC, Styner M, Walker RH, Danek A, Niethammer M, Evans A, Kotschet K, Rodrigues GR, Hughes A and others. 2011. Shape alterations in the striatum in chorea-acanthocytosis. *Psychiatry Res* 192(1):29-36.
- Walterfang M, Luders E, Looi JC, Rajagopalan P, Velakoulis D, Thompson PM, Lindberg O, Ostberg P, Nordin LE, Svensson L and others. 2014. Shape analysis of the corpus callosum in Alzheimer's disease and frontotemporal lobar degeneration subtypes. *J Alzheimers Dis* 40(4):897-906.
- Walterfang M, Wood AG, Barton S, Velakoulis D, Chen J, Reutens DC, Kempton MJ, Haldane M, Pantelis C, Frangou S. 2009a. Corpus callosum size and shape alterations in individuals with bipolar disorder and their first-degree relatives. *Prog Neuropsychopharmacol Biol Psychiatry* 33(6):1050-7.
- Walterfang M, Wood AG, Reutens DC, Wood SJ, Chen J, Velakoulis D, McGorry PD, Pantelis C. 2008. Morphology of the corpus callosum at different stages of schizophrenia: cross-sectional study in first-episode and chronic illness. *British Journal of Psychiatry* 192(6):429-434.
- Walterfang M, Yucel M, Barton S, Reutens DC, Wood AG, Chen J, Lorenzetti V, Velakoulis D, Pantelis C, Allen NB. 2009b. Corpus callosum size and shape in individuals with current and past depression. *J Affect Disord* 115(3):411-20.
- Wang Y, Song Y, Rajagopalan P, An T, Liu K, Chou YY, Gutman B, Toga AW, Thompson PM. 2011. Surface-based TBM boosts power to detect disease effects on the brain: an N=804 ADNI study. *Neuroimage* 56(4):1993-2010.
- Watson C, Andermann F, Gloor P, Jones-Gotman M, Peters T, Evans A, Olivier A, Melanson D, Leroux G. 1992. Anatomic basis of amygdaloid and hippocampal volume measurement by magnetic resonance imaging. *Neurology* 42(9):1743-50.
- Watson D, Wu KD. 2005. Development and validation of the Schedule of Compulsions, Obsessions, and Pathological Impulses (SCOPI). *Assessment* 12(1):50-65.
- Weaver KE, Richards TL, Liang O, Laurino MY, Samii A, Aylward EH. 2009. Longitudinal diffusion tensor imaging in Huntington's Disease. *Exp Neurol* 216(2):525-9.
- Wexler A, Wild EJ, Tabrizi SJ. 2016. George Huntington: a legacy of inquiry, empathy and hope. *Brain* 139(Pt 8):2326-33.
- Wexler NS, Lorimer J, Porter J, Gomez F, Moskowitz C, Shackell E, Marder K, Penchaszadeh G, Roberts SA, Gayan J and others. 2004. Venezuelan kindreds reveal that genetic and environmental factors modulate Huntington's disease age of onset. *Proc Natl Acad Sci U S A* 101(10):3498-503.
- White NM. 2009. Some highlights of research on the effects of caudate nucleus lesions over the past 200 years. *Behav Brain Res* 199(1):3-23.
- White NM, McDonald RJ. 2002. Multiple parallel memory systems in the brain of the rat. *Neurobiol Learn Mem* 77(2):125-84.
- Wijeratne PA, Johnson EB, Eshaghi A, Aksman L, Gregory S, Johnson HJ, Poudel GR, Mohan A, Sampaio C, Georgiou-Karistianis N and others. 2020. Robust Markers and Sample Sizes for Multicenter Trials of Huntington Disease. *Ann Neurol* 87(5):751-762.
- Wijeratne PA, Young AL, Oxtoby NP, Marinescu RV, Firth NC, Johnson EB, Mohan A, Sampaio C, Scahill RI, Tabrizi SJ and others. 2018. An image-based model of brain volume biomarker changes in Huntington's disease. *Ann Clin Transl Neurol* 5(5):570-582.
- Wilkes FA, Abaryan Z, Ching CRK, Gutman BA, Madsen SK, Walterfang M, Velakoulis D, Stout JC, Chua P, Egan GF and others. 2019. Striatal morphology and neurocognitive dysfunction in Huntington disease: The IMAGE-HD study. *Psychiatry Res Neuroimaging* 291:1-8.

- Wilson CJ, Kawaguchi Y. 1996. The origins of two-state spontaneous membrane potential fluctuations of neostriatal spiny neurons. *J Neurosci* 16(7):2397-410.
- Winograd-Gurvich CT, Georgiou-Karistianis N, Evans A, Millist L, Bradshaw JL, Churchyard A, Chiu E, White OB. 2003. Hypometric primary saccades and increased variability in visually-guided saccades in Huntington's disease. *Neuropsychologia* 41(12):1683-1692.
- Wood SJ, Kennedy D, Phillips LJ, Seal ML, Yucel M, Nelson B, Yung AR, Jackson G, McGorry PD, Velakoulis D and others. 2010. Hippocampal pathology in individuals at ultra-high risk for psychosis: A multi-modal magnetic resonance study. *Neuroimage* 52(1):62-68.
- Yamashita T, Ninomiya M, Acosta PH, Garcia-Verdugo JM, Sunabori T, Sakaguchi M, Adachi K, Kojima T, Hirota Y, Kawase T and others. 2006. Subventricular zone-derived neuroblasts migrate and differentiate into mature neurons in the post-stroke adult striatum. *Journal of Neuroscience* 26(24):6627-6636.
- Younes L, Ratnanather T, Brown T, Aylward E, Nopoulos P, Johnson H, Magnotta VA, Paulsen JS, Margolis RL, Albin RL and others. 2012. Regionally selective atrophy of subcortical structures in prodromal HD as revealed by statistical shape analysis. *Hum. Brain Mapp.*
- Young AB, Shoulson I, Penney JB, Starosta-Rubinstein S, Gomez F, Travers H, Ramos-Arroyo MA, Snodgrass SR, Bonilla E, Moreno H and others. 1986. Huntington's disease in Venezuela: neurologic features and functional decline. *Neurology* 36(2):244-9.
- Zeng HM, Han HB, Zhang QF, Bai H. 2021. Application of modern neuroimaging technology in the diagnosis and study of Alzheimer's disease. *Neural Regen Res* 16(1):73-79.
- Zigmond AS, Snaith RP. 1983. The hospital anxiety and depression scale. *Acta Psychiatr. Scand.* 67(6):361-70.
- Zuccato C, Cattaneo E. 2007. Role of brain-derived neurotrophic factor in Huntington's disease. *Progress in Neurobiology* 81(5-6):294-330.
- Zuccato C, Ciammola A, Rigamonti D, Leavitt BR, Goffredo D, Conti L, MacDonald ME, Friedlander RM, Silani V, Hayden MR and others. 2001. Loss of huntingtin-mediated BDNF gene transcription in Huntington's disease. *Science* 293(5529):493-498.
- Zuccato C, Marullo M, Conforti P, MacDonald ME, Tartari M, Cattaneo E. 2008. Systematic assessment of BDNF and its receptor levels in human cortices affected by Huntington's disease. *Brain Pathology* 18(2):225-238.
- Zuccato C, Tartari M, Crotti A, Goffredo D, Valenza M, Conti L, Cataudella T, Leavitt BR, Hayden MR, Timmusk T and others. 2003. Huntingtin interacts with REST/NRSF to modulate the transcription of NRSE-controlled neuronal genes. *Nature Genetics* 35(1):76-83.