

First record of chewing lice *Brueelia pyrrhularum* Eichler, 1954 (Ischnocera: Philopteridae) on an Eurasian bullfinch, *Pyrrhula pyrrhula* L in Kushiro, Hokkaido, Japan

Tomoo Yoshino^{1,2} and Mitsuhiro Asakawa^{2*}

¹Kushiro Zoo, Kushiro, Hokkaido 085-0201, Japan

²School of Veterinary Medicine, Rakuno Gakuen University, Ebetsu, Hokkaido 069-8501, Japan

Abstract: A deceased male adult Eurasian bullfinch, *Pyrrhula pyrrhula*, was collected in March 2017 from Kushiro Natural Red-crowned Crane Reserve, Kushiro, Hokkaido, Japan. In the post-mortem examination, three adult chewing lice were obtained from the body surface. The present specimens were identified as *Brueelia pyrrhularum* Eichler, 1954 by morphological measurements and characteristics. This is the first record of *B. pyrrhularum* from Japan.

Key words: first geographical record in Japan, chewing lice, *Pyrrhula pyrrhula*

The Eurasian bullfinch *Pyrrhula pyrrhula* (Linnaeus, 1758) (Passeriformes: Fringillidae) is widely distributed throughout the Palearctic region from western Europe to Kamchatka in the north to southern Japan. Although this species is resident in Hokkaido, they breeding in coniferous and mixed forests of mountainous regions and carry out short distance seasonal movements that wintering at lower elevations in warmer areas (Brazil 2009; Fujimaki, 1996). The Eurasian bullfinch is common, but there is little biological data available on the species in Japan (Takagawa et al. 2010). Information on disease-causing agents, such as viruses, bacteria, and parasites, is important for the conservation of birds (Asakawa et al. 2002). Therefore, we investigated the cause of death of an adult male Eurasian bullfinch and the parasites present in the bird.

The carcass of an adult male Eurasian bullfinch was found in the Kushiro Natural Red-crowned Crane Reserve in Kushiro, Hokkaido, Japan, in March 2017. On post-mortem examination performed at Kushiro Zoo, three chewing lice specimens (♂1, ♀2) were obtained from the body surface. The lice specimens were fixed in 70% ethanol and taken to the Wild Animal Medical Center of Rakuno Gakuen University (WAMC) for taxonomical examination. The lice were mounted in Hoyer's medium for microscopic observation, and the morphological and biometric data were recorded using a Lucida camera (OLYMPUS DP20). The stuffed body of the Eurasian bullfinch and parasite specimens are preserved in Kushiro Zoo.

According to a rapid screening test (Espline A Influenza; Fuji Rebio Inc.), the bird was not infected with Avian Flu.

The bullfinch's measurements were recorded as the following: body weight, 27.8 g; total length, 155 mm; wingspan, 256 mm; unflattened wing length, 83 mm; maximum wing length, 83 mm; wing width, 63 mm; tail length, 66 mm; exposed culmen size, 8.88 mm; total culmen size, 11.58 mm; height of bill, 8.14 mm; width of bill, 9.45 mm; total head length, 27.75 mm; and tarsus length, 17.53 mm. The bird had a sufficient store of subcutaneous fat, and the pectoral muscle did not contract; therefore, the nutritional status appeared good. Hemoptysis was observed, but no fracture was apparent. Post-mortem findings included stasis of the jugular vein, pulmonary contusion, bleeding associated with the third thoracic vertebral fracture, and brain contusion, but no other abnormalities. The above findings are commonly seen in some collision accidents, and the bird was collected from just under a glass door. Therefore, the bird had apparently collided with the glass door and died from a vertebral fracture, organ contusion, and circulation failure. In Hokkaido, it is known that wild birds are injured and die from collisions and traffic accidents in the spring and autumn migration seasons (Yanagawa and Shibuya 1996, Yoshino et al. 2014). The Eurasian bullfinch is known to make a seasonal trip from their over-wintering areas to breeding areas in spring (Brazil 2009). Because sufficient subcutaneous fat was found, it was thought that the bird was involved in an accident during its migration. Moreover, no helminths were found within the visceral organs.

The lice specimens discovered on the body belonged to the family Philopteridae of the suborder Ischnocera, which was confirmed via the following features: the snout did not extend from the head, there were two claws on each leg, and the antennae, which were elongated, were filiform, had five

*Corresponding author: askam@rakuno.ac.jp

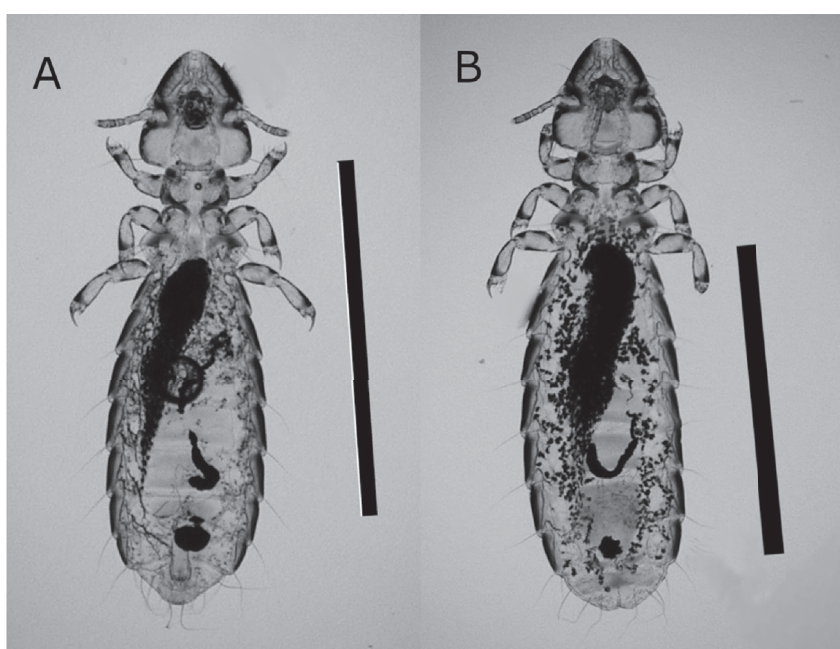


Fig. 1. *Brueelia pyrrhularum* from an Eurasian bullfinch, *Pyrrhula pyrrhula* L in Kushiro, Hokkaido, Japan. A. male, B. female (bar = 1 mm)

Table 1. Body parameters of the present specimens of *Brueelia pyrrhularum*, comparing with Balát(1955)

Body parameters*	Male		Female	
	present specimen (n=1)	Balát 1955 (n=5)	present specimen (n=2)	Balát 1955 (n=8)
Head length	343	342 - 360	384, 388	369 - 391
Head width	322	315 - 337	360, 369	337 - 378
Thorax length	314	297 - 306	336, 346	319 - 351
Prothorax width	204	198 - 207	219, 226	198 - 229
Metathorax width	310	301 - 319	352, 354	324 - 364
Abdomen length	1011	893 - 1000	1180, 1252	1060 - 1227
Abdomen width	469	408 - 453	541, 549	453 - 544
Total length	1596	1500 - 1636	1873, 1908	1742 - 1924

* in μm

sections, and reached the corner roots. In addition, the head was not elongated and was 1.05-1.10 times longer than wide; there were mandibulate mouthparts on the ventral part of the head, and the anterior head margin was flattened. The head was strong, the spank horns were angled, and the dark edges of the hem fell to the sides and around the base of the turrets. It was identified as belonging to the genus *Brueelia* according to Price et al. (2003). The lice were identified as *Brueelia pyrrhularum* Eichler, 1954 (Fig. 1) on the basis of measurements (Table 1) and characterized by the rather narrow head, almost flat posterior edge of the prothorax, noticeably convex posterior edge of metathorax, and male paramere (Eichler 1954, Balát 1955).

The genus *Brueelia* mainly parasitizes birds of the order Passeriformes and, globally, about 150 species are known (Gustafsson & Bush 2017, Price et al. 2003). Although *B. mol-*

lii Ansari, 1957 from *Corvus macrorhynchos* Wagler, 1827 and *B. rotundata* (Osborn, 1896) from *C. corone* Linnaeus, 1758, were known to inhabit Japan (Kano 2000, Mizuno 1984), these two species were transferred to the genus *Corvonirmus* Eichler, 1944 and their current names are *C. mollii* (Ansari, 1957) and *C. rotundatus* (Osborn, 1896) (Gustafsson & Bush, 2017). *B. pyrrhularum* is widely distributed in the Palearctic region, and the genus *Pyrrhula* is a specific host species (Palma & Jensen 2016, Price et al. 2003). The present findings represent the first record of the genus *Brueelia* and *B. pyrrhularum* from Japan.

Chewing lice are known to sometimes have adverse effects on host birds, such as feather wear, increased energy consumption, and decreased reproductive performance (Booth et al., 1993; Clayton, 1991). However, in the present case, there were no remarkable findings such as feather wear or skin

abnormalities, and the nutritional status was good. Thus, this Eurasian bullfinch was not apparently affected by parasitism of *B. pyrrhularum*.

Acknowledgment

This study was partly supported by the Strategic Research Foundation at Private Universities (2013–2017) and by a Grant-in-Aid for Scientific Research (C-23570120, C-26460513) from the Ministry of Education, Culture, Sports, Science and Technology of Japan. We also thank Mr. H. Fukuyama and Mrs. K. Kimura for the donation on sampling. We thank Suzanne Leech, Ph.D., from Edanz Group (<https://en-author-services.edanzgroup.com/ac>) for editing a draft of this manuscript.

References

- Asakawa, M., Nakamura, S. & Brazil, M. A. 2002. An overview of infectious and parasitic diseases in relation to the conservation biology of the Japanese avifauna. *J. Yamashina Inst. Ornithol.* **34**: 200–221.
- Balát, F., 1955. Príspevek k poznání vsenek rodu *Brueelia* I. *Práce Brněnské Zak. Českos. Akad. Ved.*, **27**: 499–524 (in Czech).
- Booth, D. T., Clayton, D. H. & Lock, B. A. 1993. Experimental demonstration of the energetic cost of parasitism in free-ranging host. *Proc. R. Soc. Lond. Ser. B*, **253**: 125–129.
- Brazil, M. A., 2009. Birds of East Asia. Princeton Publishing, England.
- Clayton, D. H. 1991. Coevolution of avian grooming and ectoparasite avoidance. In: Loye, J. E. & Zuk, M. (Eds). *Bird–parasite interactions: ecology, evolution and behaviour*. Oxford: Oxford University Press. pp. 258–289.
- Eichler, W., 1954. Deutsche Federlinge. I. Genus *Brueelia*. *Naturwiss. Mus. Nach. Aschaffenburg, Germany.*, **42**: 59–66 (in German).
- Fujimaki, Y., 1996. Distribution of Bullfinch *Pyrrhula pyrrhula* in south-eastern Hokkaido. *J. Jpn. Wildl. Res.*, **32**: 24–28 (in Japanese with English summary).
- Gustafsson, D. R. & Bush, S. E. 2017. Morphological revision of the hyperdiverse *Brueelia*-complex (Insecta: Phthiraptera: Ischnocera: Philopteridae) with new taxa, checklists and generic key. *Zootaxa*, **4313**: 1–443.
- Kano, R., 2000. Report of hippoboscids collected in the Institute for Nature Study, National Science Museum. *Rep. Inst. Nat. Stu.*, **31**: 9–11 (in Japanese).
- Mizuno, F., 1984. Studies on the parasite fauna of the eastern carrion crow, *Corvus corone orientalis* Eversman, and the Japanese jungle crow, *Corvus macrorhynchos japonensis* Bonaparte. *Jpn. J. Vet. Res.*, **32**: 105.
- Palma, R. L., & Jensen, J. K., 2016. Additional records of lice (Insecta, Phthiraptera) from the Faroe Islands. *Norwegian J. Entomol.* **63**: 50–57.
- Price, R. D., Hellenthal, R. A., Palma, R. L., Johnson, K. P. & Clayton, D. H., 2003. *The Chewing Lice world checklist and Biological Overview*. Illinois Natural History Survey Special Publication, Illinois
- Takagawa, S., Ueta, M., Amano, T., Okahisa, Y., Kamioki, M., Takagi, K., Takahashi, M., Hayama, M., Hirano, T., Mikami, O., Mori, S., Morimoto, G. & Yamaura, Y., 2011. JAVIAN database: a species-level database of life history, ecology and morphology of bird species in Japan. *Bird Res.* **7**: R9–R12 (in Japanese with English summary).
- Yanagawa, H. & Shibuya, T., 1996. Causes of wild bird mortality in eastern Hokkaido. Part II. *Res. Bull. Obihiro Univ.* **19**: 251–253 (in Japanese with English summary).
- Yoshino, T., Uemura, J., Watanabe, H., Aizawa, K., Endoh, D., Osa, Y. & Asakawa, M. 2014. Records of wildlife rescue in the Wild Animal Medical Center of Rakuno Gakuen University between 2003 and 2010. *J. Hokkaido Vet. Med. Assoc.* **58**: 123–129 (in Japanese).

(Received November 30, 2020; Accepted March 10, 2021)