

**Case Report / Olgu Sunumu**

## An Unusual Foreign Body in Stomach: Dining Fork

*Midede Sıradışı Bir Yabancı Cisim: Yemek Çatalı*

Cemil KAVALCI,<sup>1</sup> Atakan SEZER,<sup>2</sup> İrfan ÇOŞKUNOĞLU<sup>2</sup>

Departments of <sup>1</sup>Emergency Medicine and <sup>2</sup>General Surgery, Medical Faculty of Trakya University, Edirne

**Submitted / Başvuru tarihi:** 10.02.2009 **Accepted / Kabul tarihi:** 21.04.2009

An 18-year-old male patient applied to the emergency department with complaint of fork swallowing. Abdominal film of the patient showed meal fork in the stomach. Laboratory signs of the patient were normal. The fork in the stomach of the patient was removed surgically.

**Key words:** Emergency; fork; foreign body.

18 yaşında erkek hasta acil servisimize çatal yutma şikayeti ile başvurdu. Çekilen karın grafisinde midede çatal olduğu görüldü. Hastanın laboratuvar bulguları normal değerlerdeydi. Hastanın midesindeki çatal cerrahi olarak çıkarıldı.

**Anahtar sözcükler:** Acil; çatal; yabancı cisim.

Some foreign bodies (FBs) result in immediately apparent complications, whereas others remain asymptomatic and undetected. Malpractice lawsuits against emergency physicians regarding failure to diagnose or treat retained FBs result in the fifth highest amount of indemnity awards paid to patients.<sup>[1]</sup>

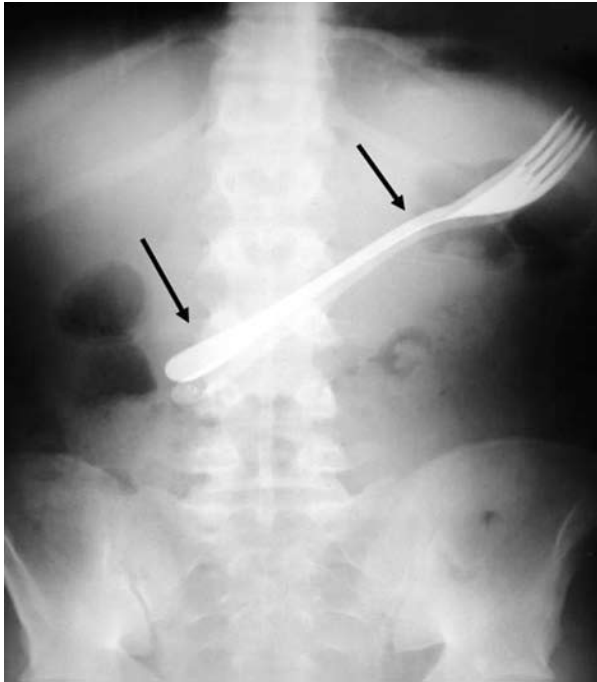
### CASE REPORT

An 18-year-old male patient applied to the emergency department with complaint of fork swallowing. During anamnesis, it was learnt that he had eaten yoghurt together with fish for lunch, then he had been worried about poisoning and while trying to vomit with fork, he had swallowed the fork. Epigastric tender-

ness was observed during physical examination. Abdominal film of the patient showed meal fork in the stomach (Fig. 1). Laboratory signs of the patient were normal. The fork in the stomach of the patient was removed surgically and the patient was discharged two days later.

### DISCUSSION

Literature scanning shows that FBs, such as coin, battery, needle, bottle, glass, etc. are frequently encountered inside the gastrointestinal system.<sup>[2-5]</sup> However, no fork aspiration was encountered so far. Possibly, this is the first case in the literature. Treatment depends on the swallowed object. While sharp objects



*Fig. 1. Fork in the stomach on abdominal X-ray.*

and batteries are surgically removed, blunt objects like coins are expected to be discarded

with defecation.<sup>[6]</sup> This article aims to remind the need that general public must be informed that myths such as eating fish together with yoghurt causes poisoning are not real as well as to present atypical foreign body in the stomach.

## REFERENCES

1. Ozsarac M, Demircan A, Sener S. Glass foreign body in soft tissue: possibility of high morbidity due to delayed migration. *J Emerg Med* 2008 [Epub ahead of print]
2. Ramos R, Duarte P, Vicente C, Casteleiro C. Upper gastrointestinal bleeding triggered by foreign body ingestion. *Rev Esp Enferm Dig* 2008;100:238-9. [Abstract]
3. Zippi M, Febbraro I, De Felici I, Mattei E, Pica R, Traversa G, et al. Foreign bodies in the upper gastrointestinal tract. Personal experience. *Clin Ter* 2007;158:291-5. [Abstract]
4. Smith MT, Wong RKH. Foreign bodies. *Gastrointest Endosc Clin N Am* 2007;17:361-82.
5. Lee TH, Kang YW, Kim HJ, Kim SM, Im EH, Huh KC, et al. Foreign objects in Korean prisoners. *Korean J Intern Med* 2007;22:275-8.
6. Telford JJ. Management of ingested foreign bodies. *Can J Gastroenterol* 2005;19:599-601.