

SHORT COMMUNICATION

Novel adenovirus associated with necrotizing bronchiolitis in a captive reindeer (*Rangifer tarandus*)

Akbar Dastjerdi¹  | Sonja Jeckel² | Hannah Davies^{1,3}  | Jennifer Irving² |
Camille Longue⁴ | Charlotte Plummer⁵ | Márton Z. Vidovszky⁶  | Balázs Harrach⁶  |
Julian Chantrey⁷ | Henny Martineau² | Jonathan Williams²

¹ Virology Department, Animal and Plant Health Agency (APHA)-Weybridge, Addlestone, Surrey, UK

² Pathobiology and Population Sciences, Royal Veterinary College, Hatfield, Hertfordshire, UK

³ School of Veterinary Medicine, University of Surrey, Guildford, UK

⁴ Idexx Laboratories Ltd., Wetherby, Yorkshire, UK

⁵ NorCal Veterinary Services, Thame, UK

⁶ Veterinary Medical Research Institute, Budapest, Hungary

⁷ Veterinary Pathology and Preclinical Sciences, University of Liverpool Veterinary School, Neston, UK

Correspondence

Akbar Dastjerdi, Virology Department, Animal and Plant Health Agency (APHA)-Weybridge, Addlestone, Surrey, KT15 3NB, UK.
Email: akbar.dastjerdi@apha.gov.uk

Funding information

Department of Environment, Food and Rural Affairs, Grant/Award Numbers: ED1500, ED1000; National Research, Development and Innovation Office – NKFIH, Grant/Award Number: NN140356

Abstract

Adenoviruses cause a range of major diseases across many diverse animal species including ruminants. They are classified into six genera in the family *Adenoviridae*. In deer species, two adenoviruses are currently recognized: deer adenovirus 1 in the *Atadenovirus* genus, and deer adenovirus 2 in the *Mastadenovirus* genus. Deer adenovirus 1 causes adenovirus haemorrhagic disease with high fatality in black-tailed and mule deer in North America. Conversely, deer adenovirus 2 was incidentally detected from a healthy white-tailed deer fawn, but experimentally it has been shown to cause pyrexia, cough and moderate to severe haemorrhage. Here, we detected a novel adenovirus, reindeer adenovirus 1, from lung lesions of a 5-year-old male reindeer (*Rangifer tarandus*). This animal presented with aspiration pneumonia and necrotizing bronchiolitis following a period of clinical weakness, nasal discharge and wasting. Histopathological examination of the lung revealed large intranuclear basophilic inclusions associated with the areas of necrotizing bronchiolitis. Next generation sequencing of the lung tissue identified a novel mastadenovirus with close similarity to deer adenovirus 2 and bovine adenovirus 3. To our knowledge, this is the first report of a deer mastadenovirus associated with necrotizing bronchiolitis in captive reindeer.

KEYWORDS

adenovirus, cervid, mastadenovirus, pneumonia, rangifer tarandus, reindeer

1 | INTRODUCTION

Adenoviruses cause a range of important diseases across many diverse animal species, and are classified into six genera based on phylogeny, host species and genome organization; *Mastadenovirus* (infecting mammals), *Atadenovirus* (infects squamate reptiles, ruminants, birds, marsupials and tortoises), *Aviadenovirus* (infects birds), *Ichtadenovirus* (affects

fish), *Siadenovirus* (infects birds, frog and tortoises) and *Testadenovirus* (infects turtles) (Harrach & Benkó, 2021; Harrach et al., 2011; Harrach et al., 2019; <https://sites.google.com/site/adenoseq/>).

In deer, adenovirus haemorrhagic disease (AHD) is caused by odocoileus adenovirus 1 (OdAdV-1, syn. deer AdV-1), species *Deer atadenovirus A* which is a member of the genus *Atadenovirus*. The virus can cause systemic vasculitis with high mortality and the potential of

high fatality (Lehmkuhl et al., 2001; Woods et al., 1999; Zakhartchouk et al., 2002). Since discovery of mule deer (*Odocoileus hemionus*) AHD in California in 1994 (Woods et al., 1996), outbreaks have also been reported in black-tailed deer (*Odocoileus hemionus columbianus*) (Boyce et al., 2000). Retrospective investigations also found OdAdV-1 responsible for mass HD mortality in mule deer species as far back as 1981 (Woods et al., 2018). AHD has also been reported in Canadian moose (*Alces alces*) (Shilton et al., 2002), but never in Europe or in European species of deer. A novel mastadenovirus (deer AdV-2 syn. OdAdV-2, *Deer mastadenovirus B*) has also been isolated incidentally from captive white-tailed deer (*Odocoileus virginianus*). Infection of white-tailed deer fawns at 3 months of age with this virus, however, caused biphasic pyrexia in 80% and cough in 40% of the fawns (Ridpath et al., 2017).

Reindeer, also known as caribou (*Rangifer tarandus*), are the most abundant herbivore across the Arctic, playing a key role in supporting predator populations and indigenous peoples (Mallory & Boyce, 2018). The submitted 5-year-old male reindeer in this report was kept with a group of 13 other unaffected reindeer at a free-range egg farm in the United Kingdom, open to the public where pigs and goats were also kept. The reindeer had been 'working' (hired for public Christmas events) until about 1 month prior to post-mortem examination. It is unknown whether this animal may have also come into contact with other free roaming deer native to the United Kingdom. This reindeer initially presented with clinical signs of sudden onset respiratory distress and weakness that began 2 weeks prior to death, which progressed to nasal discharge, uncoordinated gait and marked condition loss. Response to multiple antibiotic treatments was poor and the reindeer was subsequently found dead. Endoscopy suspected pneumonia.

Here, we describe detection of a novel adenovirus, reindeer adenovirus 1 (ReAdV-1) from lung tissue of this animal along with its complete genome sequence, genomic organization and phylogenetic analysis and provide evidence that the virus may represent a new species within the *Mastadenovirus* genus.

2 | MATERIALS AND METHODS

Post-mortem examination was carried out at the Royal Veterinary College, Farm Animal Pathology and Diagnostic Services. Samples of lung tissue were stored freshly frozen and separately fixed in 10% neutral buffered formalin and embedded in paraffin wax for histopathological examination. Sections (3–5 μm) of paraffin embedded formalin-fixed lung tissue were either stained with haematoxylin and eosin (H&E) or subjected to immunohistochemistry. Immunohistochemistry utilizing a primary antibody (polyclonal goat anti adenovirus; [Bio-Rad; product number 0151-9004] which binds numerous adenovirus proteins including hexon protein, and reacts with adenovirus types 1–6, 7a, 8, 31, 40 and 41 was performed as described previously, Verin et al., 2019). Slides were imaged with a Zeiss Axioscan Z1 digital slide scanner.

For next generation sequencing (NGS), approximately 25 mg of retained frozen lung tissue was processed for nucleic acid extraction as described by Dastjerdi et al. (2014). This extract (10 μl) was also

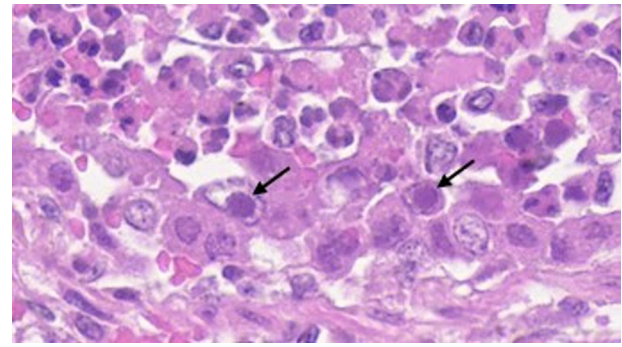


FIGURE 1 Bronchioles contained neutrophils and necrotic cell debris with lining bronchiolar epithelial cell degeneration and necrosis (necrotizing bronchiolitis), frequently with large, up to 6 μm intensely basophilic intranuclear inclusion bodies. Arrows indicate numerous intranuclear basophilic inclusion bodies that peripheralize the chromatin. Haematoxylin and eosin stain

subjected to whole genome amplification using REPLI-g® Cell WGA & WTA kit (Qiagen) as per the manufacturer's instructions. The nucleic acids were then sequenced through NGS (Dastjerdi et al., 2015) and analyzed by reference-guided, initially viral reference sequences and then deer AdV-2 and bovine AdV-3 sequences from the GenBank, and de novo assembly applications. Ambiguities in the SeqMan NGen 17 assembled sequence were verified by conventional PCRs and sequencing.

Genome annotation was carried out as described previously (Vidovszky et al., 2019) and MegAlign software (DNASTAR) was used to align the polymerase sequences and draw sequence similarity. Phylogenetic analysis was conducted in MEGA X (Kumar et al., 2018) and the evolutionary history was inferred using the Maximum Likelihood method, Le_Gascuel_2008 model (Le & Gascuel, 2008) and bootstrap estimation method by 500 samplings (Felsenstein, 1985).

3 | RESULTS

At postmortem examination, the lungs were heavy, dark red and very firm with an enhanced lobular pattern. On cut sections, the tissue bulged and contained multiple foci of thick, pink-beige fluid (pus), with a dark-red rim (abscesses). Within some of these abscesses was tan, fibrous material (forage). The bronchial lymph nodes were moderately to markedly enlarged and dark red. Lung and liver bacteriology showed variable growth of mixed flora with no predominance of pathogenic bacteria.

Histopathological examination of the lungs revealed an acute necrotizing bronchiolitis and subacute aspiration pneumonia. The bronchiolitis was characterized by degeneration and necrosis of the bronchiolar epithelium with intraluminal neutrophils admixed with necrotic cell debris. Remaining epithelial cells frequently contained large, up to 6 μm , intensely basophilic intranuclear inclusion bodies indicating probable adenovirus infection (Figure 1). Elsewhere, bronchioles were occluded by large fragments of cellulose material, and bronchioles and

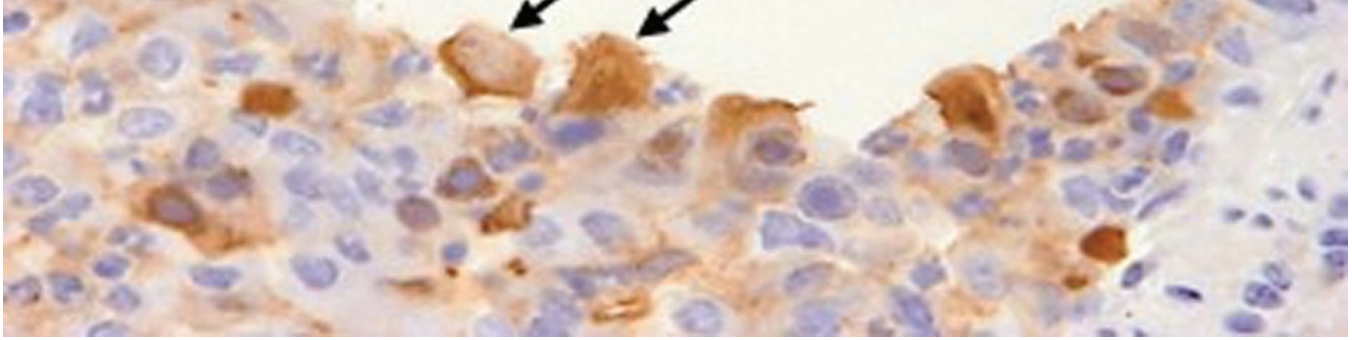


FIGURE 2 Bronchioles contained numerous degenerate bronchiolar epithelial cells that labelled positively of both cell membrane and cytoplasmically, indicated by the brown labelling (arrow) in immunohistochemistry for adenovirus antigen

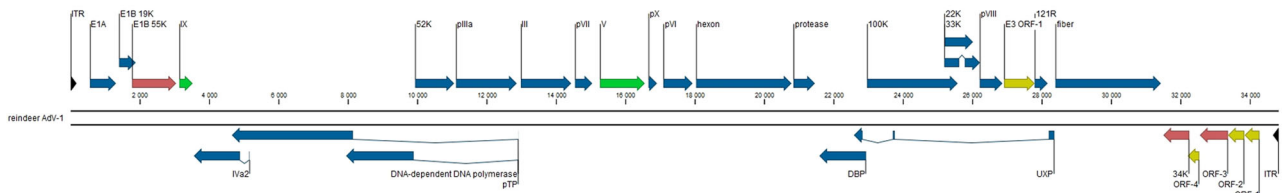


FIGURE 3 Genomic organization of reindeer adenovirus 1 (ReAdV-1). Different colours are used to indicate genes that have homologs in other adenoviruses. Blue, genes are present in all adenoviruses (AdVs); red, genes occurring in both mastadenoviruses and atadenoviruses; green, genes specific to mastadenoviruses; yellow, genes with homologues only in deer AdV-2, bovine AdV-3 and ovine AdV-8. ITRs are labelled with black

alveoli were filled with viable and degenerate neutrophils, fibrin aggregates, foamy macrophages, amorphous eosinophilic and karyorrhectic (necrotic) debris and colonies of Gram-positive cocci. Within these areas, alveolar septa were multifocally lost or fragmented (necrosis) and necrotic debris often mineralized. Multifocally in areas not obviously affected by aspiration, bronchioles contained neutrophils and necrotic cell debris with evidence of degeneration and necrosis of the lining bronchiolar epithelium (necrotizing bronchiolitis). Epithelial cells frequently contained large, up to 6 μm , intensely basophilic intranuclear inclusion bodies indicating probable adenovirus infection (Figure 1) although other viruses capable of causing intranuclear inclusions were considered (such as herpesviruses). Immunohistochemistry for adenovirus antigen demonstrated numerous intralesional positively labelled degenerate bronchiolar epithelial cells (Figure 2).

NGS has resulted in a total of 89,949,670 sequence reads for the amplified and non-amplified templates. A total of 889,278 sequence reads with average length of 95 bases generated a near complete ReAdV-1 genome with a median coverage of 3107. This assembled sequence was verified against 1827 sequence contigs. These contigs were generated through depletion of reindeer genome sequence (accession number GCA_004026565.1) from the NGS raw sequence data and de novo assembly of unassembled sequence reads. The right end inverted terminal repeat (ITR) sequence was completed by inference based on the assumption of it being of identical sequence to the left end ITR. No other known viruses were detected through reference-guided assembly or BLAST search of the de novo assembled contigs.

The ReAdV-1 genome, accession number MZ507556, was found to be 34,822 base pairs with ITRs of 166 bp and a relatively high G+C content of 61.25%. ReAdV-1 displayed a typical mastadenovirus genome organization with the genus-specific genes encoding proteins V and

IX and the E1, E3 and E4 regions (Figure 3). The ReAdV-1 genome is predicted to clone for 30 proteins, each showing clear homology to their orthologues in mastadenoviruses. The expected splicing sites were identified in the genes for Iva2, polymerase, pTP and 33K. Interestingly, the gene E1A seemed not to be spliced, while in most mastadenoviruses, it is coded by two exons (Reddy et al., 1998; Zhao et al., 2014). The gene for the whole U exon protein (UXP) was also identified by predicting splicing sites for three exons. The E3 region of mastadenoviruses usually contains several ORFs, and in the E3 region of ReAdV-1, we predict two genes. One of these (E3 ORF-1) is rather unique, with homologues only in deer AdV-2, bovine adenovirus 3 (BAdV-3), and ovine adenovirus 8 (OAdV-8) (Reddy et al., 1998; Ridpath et al., 2017; Vidovszky et al., 2019). Nevertheless, a second protein is also encoded in the E3 region, originally named 121R in BAdV-3 but actually being a homologue of E3 14.7K, found in several mastadenovirus genomes. Neither ReAdV-1 nor deer AdV-2, BAdV-3 or OAdV-8 contained the E3 12.5K gene, which is present in almost every mastadenovirus (Davison et al., 2003; Ursu et al., 2004). This short E3 region is more typical of some rodent and bat AdVs than other mammalian AdVs, whilst primate AdVs have especially complex E3 region (Hemmi et al., 2011; Kohl et al., 2012; Podgorski et al., 2016). The E4 region contains a 34K homologue. This gene (called ORF6 in human AdVs) is preserved both in mastadenoviruses and in the atadenoviruses. The coded protein, in association with E1B 55K, target cellular proteins for degradation (Gilson et al., 2016). The less-conserved part of E4 region contains four ORFs, each showing 46%–86% amino acid sequence identity with the corresponding E4 proteins of deer AdV-2, BAdV-3 and OAdV-8. E4 ORF-1, –2 and –4 showed sequence homology only to the corresponding ORFs of deer AdV-2, BAdV-3 and OAdV-8 while E4 ORF-3 shows up to 36% identity also with the 34K protein of these and many other mastadenoviruses; reflecting homology between these two proteins.

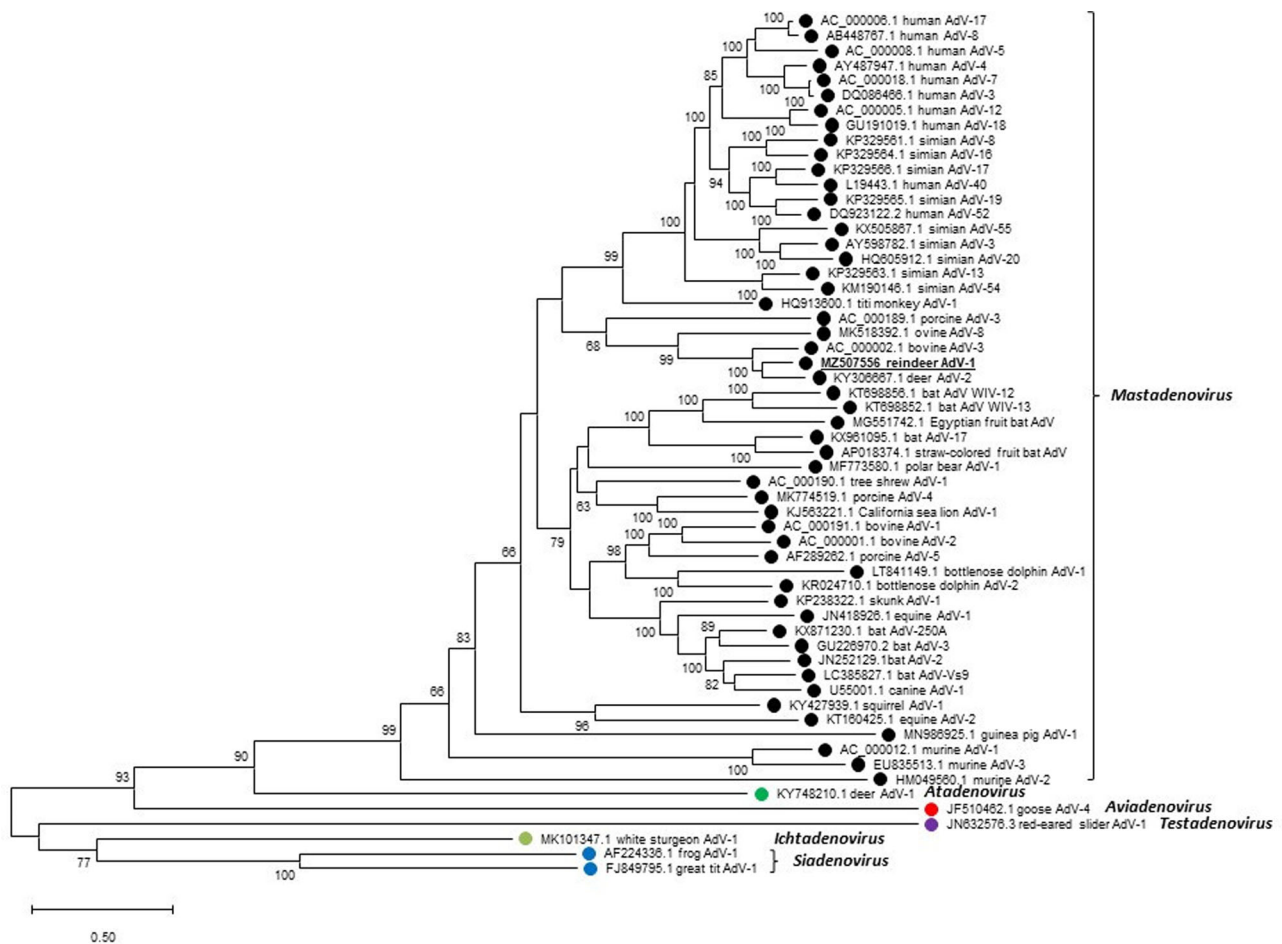


FIGURE 4 Maximum-likelihood phylogenetic analysis of reindeer adenovirus 1 (ReAdV-1) DNA polymerase and those of representative adenoviruses from the six adenovirus genera. The tree with the highest log likelihood (-75708.09) is shown. Initial tree for the heuristic search was obtained automatically by applying Neighbour-Join and BioNJ algorithms to a matrix of pairwise distances estimated using the JTT model, and then selecting the topology with superior log likelihood value. A discrete Gamma distribution was used to model evolutionary rate differences among sites (five categories [+G, parameter = 0.7913]). The tree is drawn to scale, with branch lengths measured in the number of substitutions per site. The percentage of trees in which the associated taxa clustered together in the bootstrap analysis is shown next to the branches. Bootstrap values less than 50% were omitted

The virus demonstrated closest amino acid sequence identity with those of deer AdV-2 (85.8%) and bovine AdV-3 (81.5%) for their polymerase as shown in GenBank (i.e., the non-spliced version of deer AdV-2 and the spliced version of BAdV-3 polymerase). Phylogenetic analysis accordingly clustered the virus in the *Mastadenovirus* genus and close to these two viruses, but in distinct branches (Figure 4). The virus was only distantly related to other adenovirus genera in the *Adenoviridae* family including deer AdV-1 (45.8% identity for the polymerase; genus *Atadenovirus*).

4 | DISCUSSION

Here we present discovery and characterization of a novel adenovirus seemingly capable of causing necrotizing bronchiolitis in reindeer. The only mastadenovirus previously detected naturally in a deer species was from a healthy captive white-tailed deer fawn. In experimental set-

tings, however, this virus has been shown to cause biphasic pyrexia and cough in fawns infected in vivo (Ridpath et al., 2017). There is, therefore, uncertainty surrounding the likely pathogenicity of mastadenoviruses in adult deer species. In this case, the presence of intraepithelial intranuclear adenoviral inclusions and epithelial cytopathic effects supports the notion that ReAdV-1 is capable of directly causing necrotizing bronchiolitis in reindeer. What is unclear is how this animal was initially infected and whether this animal had already been immunocompromised to predispose to adenoviral infection and lesions. It is also uncertain whether the ReAdV-1 was involved in the initiation of the pneumonia or purely in progression of the pneumonia, as there were co-existent subacute lesions of aspiration pneumonia.

Mammalian adenoviruses mostly belong to the genus *Mastadenovirus*, however, atadenoviruses can also be found in ruminants such as cattle, sheep, goat or deer. In this context, we investigated which of these two genera the discovered adenovirus belonged to. The virus undoubtedly clusters into the genus *Mastadenovirus*, and practically

satisfies the AdV species demarcation criterion of having a phylogenetic distance of > 10%–15% in polymerase sequence (Harrach & Benkő, 2021). Although the closest similar AdV was the deer AdV-2, the splicing sites of deer AdV-2 genes were not predicted in the GenBank entry for comparison. A frame shift, caused by a possible sequencing mistake in the AdV-2 genome, also made identification of the splice donor and acceptor sites of the polymerase gene impossible. In spite of this, the difference between the polymerase sequences of deer AdV-2 and ReAdV-1 is clearly more than 10% (almost 15%) which means that ReAdV-1 can be considered a novel AdV species. ReAdV-1 also fulfils the criterion to have a different host species, that is, reindeer. The two criteria together propose that a new species should be established for this virus. The proposed species name must also follow the recently accepted ICTV policy for the obligatory binomial (preferably latinized or Latin) Linnaean species naming (Adriaenssens et al., 2021; Siddell et al., 2020). Thus, the Latin name of the so far unique host could be applied and then the proposed species name may be *Mastadenovirus tarandri* (genitive of tarandus, the Latin name of reindeer). Eventually, all the presently official adenovirus species names must also be changed and they could follow this or similar naming system.

Further research regarding this virus should be aimed at establishing the prevalence of wider exposure of reindeer and whether this virus may be implicated in disease processes in this species and possibly in other ruminants. These studies may also shed light on the source of this virus.

ACKNOWLEDGEMENTS

This work was partly funded by the Department of Environment, Food and Rural Affairs through the “Scanning Surveillance for Disease in Miscellaneous and Exotic farmed species and Cattle in England and Wales” (ED1500 and ED1000) projects at APHA. B.H. was supported by the National Research, Development and Innovation Office – NKFIH (NN140356).

ETHICAL APPROVAL

The authors confirm that the ethical policies of the journal, as noted on the journal’s author guidelines page, have been adhered to. All samples used for this study were collected for clinical purposes under the Veterinary Surgeons Act 1966, the United Kingdom.

CONFLICT OF INTEREST STATEMENT

The authors declare no conflict of interest.

DATA AVAILABILITY STATEMENT

The data that support the findings of this study are openly available in GenBank at <https://www.ncbi.nlm.nih.gov/nucleotide/>, accession number MZ507556.

ORCID

Akbar Dastjerdi  <https://orcid.org/0000-0001-6251-6588>

Hannah Davies  <https://orcid.org/0000-0002-9503-4427>

Márton Z. Vidovszky  <https://orcid.org/0000-0001-5153-9397>

Balázs Harrach  <https://orcid.org/0000-0002-1410-6469>

REFERENCES

- Adriaenssens, E., Dutilh, B., Harrach, B., Junglen, S., Kropinski, A., Krupovic, M., & Zerbini, M. (2021). Modify the International Code of Virus Classification and Nomenclature (ICVCN) to prospectively mandate a uniform genus-species type virus species naming format. International Committee on Taxonomy of Viruses. Approved proposals, 2018.001G.
- Boyce, W. M., Woods, L. W., Keel, M. K., MacLachlan, N. J., Porter, C. O., & Lehmkuhl, H. D. (2000). An epizootic of adenovirus-induced hemorrhagic disease in captive black-tailed deer (*Odocoileus hemionus*). *Journal of Zoo and Wildlife Medicine*, 31(3), 370–373. [https://doi.org/10.1638/1042-7260\(2000\)031\[0370:AE0AIH\]2.0.CO;2](https://doi.org/10.1638/1042-7260(2000)031[0370:AE0AIH]2.0.CO;2)
- Dastjerdi, A., Carr, J., Ellis, R. J., Steinbach, F., & Williamson, S. (2015). Porcine epidemic diarrhea virus among farmed pigs, Ukraine. *Emerging Infectious Diseases*, 21(12), 2235–2237. <https://doi.org/10.3201/eid2112.150272>
- Dastjerdi, A., Fooks, A. R., & Johnson, N. (2014). Oligonucleotide microarray: Applications for lyssavirus speciation. In C. Rupprecht, & T. Nagara-jan (Eds.), *Current laboratory techniques in rabies diagnosis, research and prevention* (Vol. 1, pp. 193–202). Academic Press.
- Davison, A. J., Benkő, M., & Harrach, B. (2003). Genetic content and evolution of adenoviruses. *Journal of General Virology*, 84(11), 2895–2908. <https://doi.org/10.1099/vir.0.19497-0>
- Felsenstein, J. (1985). Confidence limits on phylogenies: An approach using the bootstrap. *Evolution; International Journal of Organic Evolution*, 39(4), 783–791. <https://doi.org/10.1111/j.1558-5646.1985.tb00420.x>
- Gilson, T., Blanchette, P., Ballmann, M. Z., Papp, T., Péntzes, J. J., Benkő, M., Harrach, B., & Branton, P. E. (2016). Using the E4orf6-based E3 ubiquitin ligase as a tool to analyze the evolution of adenoviruses. *Journal of Virology*, 90(16), 7350–7367. <https://doi.org/10.1128/JVI.00420-16>
- Harrach, B., & Benkő, M. (2021). Adenoviruses (*Adenoviridae*). In D. Bamford & M. Zuckerman (Eds.), *Encyclopedia of virology* (Vol. 2, 4th edn., pp. 3–16). Academic Press. <https://doi.org/10.1016/B978-0-12-814515-9.00057-6>
- Harrach, B., Benkő, M., Both, G. W., Brown, M., Davison, A. J., Echavaria, M., & Wadell, G. (2011). Family *Adenoviridae*. In A. M. Q. King, M. J. Adams, E. B. Carstens, & E. J. Lefkowitz (Eds.), *Virus taxonomy: Classification and nomenclature of viruses. Ninth report of the international committee on taxonomy of viruses* (pp. 125–141). Elsevier.
- Harrach, B., Tarján, Z. L., & Benkő, M. (2019). Adenoviruses across the animal kingdom: A walk in the zoo. *FEBS Letters*, 593(24), 3660–3673. <https://doi.org/10.1002/1873-3468.13687>
- Hemmi, S., Vidovszky, M. Z., Ruminska, J., Ramelli, S., Decurtins, W., Greber, U. F., & Harrach, B. (2011). Genomic and phylogenetic analyses of murine adenovirus 2. *Virus Research*, 160(1–2), 128–135. <https://doi.org/10.1016/j.virusres.2011.05.023>
- Kohl, C., Vidovszky, M. Z., Mühlendorfer, K., Dabrowski, P. W., Radonić, A., Nitsche, A., & Harrach, B. (2012). Genome analysis of bat adenovirus 2: Indications of interspecies transmission. *Journal of Virology*, 86(3), 1888–1892. <https://doi.org/10.1128/JVI.05974-11>
- Kumar, S., Stecher, G., Li, M., Knyaz, C., & Tamura, K. (2018). MEGA X: Molecular evolutionary genetics analysis across computing platforms. *Molecular Biology and Evolution*, 35(6), 1547–1549. <https://doi.org/10.1093/molbev/msy096>
- Le, S. Q., & Gascuel, O. (2008). An improved general amino acid replacement matrix. *Molecular Biology and Evolution*, 25(7), 1307–1320. <https://doi.org/10.1093/molbev/msn067>
- Lehmkuhl, H. D., Hobbs, L. A., & Woods, L. W. (2001). Characterization of a new adenovirus isolated from black-tailed deer in California. *Archives of Virology*, 146(6), 1187–1196. <https://doi.org/10.1007/s007050170114>
- Mallory, C. D., & Boyce, M. S. (2018). Observed and predicted effects of climate change on Arctic caribou and reindeer. *Environmental Reviews*, 26(1), 13–25. <https://doi.org/10.1139/er-2017-0032>
- Podgorski, I. I., Pantó, L., Papp, T., Harrach, B., & Benkő, M. (2016). Genome analysis of four Old World monkey adenoviruses supports the proposed species classification of primate adenoviruses and reveals signs of

- possible homologous recombination. *Journal of General Virology*, 97(7), 1604–1614. <https://doi.org/10.1099/jgv.0.000465>
- Reddy, P. S., Idamakanti, N., Zakhartchouk, A. N., Baxi, M. K., Lee, J. B., Pyne, C., Babiuk, L. A., & Tikoo, S. K. (1998). Nucleotide sequence, genome organization, and transcription map of bovine adenovirus type 3. *Journal of Virology*, 72(2), 1394–1402. <https://doi.org/10.1128/JVI.72.2.1394-1402.1998>
- Ridpath, J. F., Neill, J. D., Palmer, M. V., Bauermann, F. V., Falkenberg, S. M., & Wolff, P. L. (2017). Isolation and characterization of a novel cervid adenovirus from white-tailed deer (*Odocoileus virginianus*) fawns in a captive herd. *Virus Research*, 238, 198–203. <https://doi.org/10.1016/j.virusres.2017.06.020>
- Shilton, C. M., Smith, D. A., Woods, L. W., Crawshaw, G. J., & Lehmkuhl, H. D. (2002). Adenoviral infection in captive moose (*Alces alces*) in Canada. *Journal of Zoo and Wildlife Medicine*, 33(1), 73–79. [https://doi.org/10.1638/1042-7260\(2002\)033\[0073:AIICMA\]2.0.CO;2](https://doi.org/10.1638/1042-7260(2002)033[0073:AIICMA]2.0.CO;2)
- Siddell, S. G., Walker, P. J., Lefkowitz, E. J., Mushegian, A. R., Dutilh, B. E., Harrach, B., & Davison, A. J. (2020). Binomial nomenclature for virus species: A consultation. *Archives of Virology*, 165(2), 519–525. <https://doi.org/10.1007/s00705-019-04477-6>
- Ursu, K., Harrach, B., Matiz, K., & Benkő, M. (2004). DNA sequencing and analysis of the right-hand part of the genome of the unique bovine adenovirus type 10. *Journal of General Virology*, 85, 593–601. <https://doi.org/10.1099/vir.0.19697-0>
- Verin, R., Forzan, M., Schulze, C., Rocchigiani, G., Balboni, A., Poli, A., & Mazzei, M. (2019). Multicentric molecular and pathologic study on canine adenovirus type 1 in red foxes (*Vulpes vulpes*) in three European countries. *Journal of Wildlife Diseases*, 55, 935–939.
- Vidovszky, M. Z., Szeredi, L., Doszpoly, A., Harrach, B., & Hornyák, Á. (2019). Isolation and complete genome sequence analysis of a novel ovine adenovirus type representing a possible new mastadenovirus species. *Archives of Virology*, 164, 2205–2207. <https://doi.org/10.1007/s00705-019-04299-6>
- Woods, L. W., Hanley, R. S., Chiu, P. H., Lehmkuhl, H. D., Nordhausen, R. W., Stillian, M. H., & Swift, P. K. (1999). Lesions and transmission of experimental adenovirus hemorrhagic disease in black-tailed deer fawns. *Veterinary Pathology*, 36(2), 100–110. <https://doi.org/10.1354/vp.36-2-100>
- Woods, L. W., Schumaker, B. A., Pesavento, P. A., Crossley, B. M., & Swift, P. K. (2018). Adenoviral hemorrhagic disease in California mule deer, 1990–2014. *Journal of Veterinary Diagnostic Investigation*, 30(4), 530–537. <https://doi.org/10.1177/1040638718766036>
- Woods, L. W., Swift, P. K., Barr, B. C., Horzinek, M. C., Nordhausen, R. W., Stillian, M. H., & MacLachlan, N. J. (1996). Systemic adenovirus infection associated with high mortality in mule deer (*Odocoileus hemionus*) in California. *Veterinary Pathology*, 33(2), 125–132. <https://doi.org/10.1177/030098589603300201>
- Zakhartchouk, A., Bout, A., Woods, L. W., Lehmkuhl, H. D., & Havenga, M. J. (2002). *Odocoileus hemionus* deer adenovirus is related to the members of *Atadenovirus* genus. *Archives of Virology*, 147(4), 841–847. <https://doi.org/10.1007/s007050200031>
- Zhao, H., Chen, M., & Petterson, U. (2014). A new look at adenovirus splicing. *Virology*, 456–457, 329–341. <https://doi.org/10.1016/j.virol.2014.04.006>

How to cite this article: Dastjerdi, A., Jeckel, S., Davies, H., Irving, J., Longue, C., Plummer, C., Vidovszky, M. Z., Harrach, B., Chantrey, J., Martineau, H., & Williams, J. (2021). Novel adenovirus associated with necrotizing bronchiolitis in a captive reindeer (*Rangifer tarandus*). *Transboundary and Emerging Diseases*, 1–6. <https://doi.org/10.1111/tbed.14374>