



OPEN ACCESS

# Cutaneous manifestations associated with SARS-CoV-2: an emerging topic in a pandemic era

Helena Luís , Carolina Barros, Diogo André, Alexandra Malheiro

Internal Medicine, SESARAM, Funchal, Portugal

**Correspondence to**  
Dr Helena Luís;  
helenaluiss@gmail.com

Accepted 20 July 2021

## SUMMARY

A 70-year-old man was admitted to our COVID-19 ward with thoracalgia, productive mucus cough, fatigue and erythematous–violaceous macules on the inner side of feet and interdigital regions. The patient was started on oxygen and dexamethasone. On the day of discharge, he maintained the skin changes despite the resolution of COVID-19 symptoms. A 57-year-old woman initially presented with diffuse urticarial rash on the cervical and chest region. Oral cetirizine was started, and pruritus improved. Thirty days after the discharge, the patient maintained the rash, but without pruritus. A 49-year-old man was admitted with thoracalgia, shortness of breath, dry cough and urticarial rash on the cervical and chest region. The patient was treated with cetirizine. The pruritus improved, and 5 days after discharge, the urticarial areas completely disappeared.

## BACKGROUND

In December 2019, in the Chinese city of Wuhan, were reported the first cases of unexplained pneumonia,<sup>1</sup> caused by a new infectious pathogen named SARS-CoV-2.<sup>2</sup> The resulting disease was called COVID-19<sup>3</sup> and has become a global health threat, infecting 118 058 503 individuals, and resulting in 2 621 046 deaths by 12 March 2021.<sup>4</sup>

With the global increase in the number of SARS-CoV-2 infections, there has been a rising frequency of cutaneous manifestations with different morphology types. Mechanisms responsible for the skin rash in SARS-CoV-2 have been formulated, including direct virus infection of an open wound of the skin, immune system responses or iatrogenic drug introduction.<sup>5</sup>

In a prospective nationwide case collection study in Spain conducted by Galván *et al*, which included 375 patients, the authors described five clinical patterns associated with COVID-19. These patterns comprised acral areas of erythema–oedema with some vesicles or pustules (pseudochilblain), other vesicular eruptions, urticarial lesions, other maculopapules, and livedos or necrosis.<sup>6</sup> Their frequency and timing in the disease's natural course are still challenging to determine.<sup>7</sup> However, some authors reported maculopapular eruptions, pseudochilblain and urticarial rash to be the most common mucocutaneous manifestations in COVID-19,<sup>8,9</sup> developing few days before the onset of the systemic symptoms. Erythematous rash and localised or generalised urticaria appear to be the most shared cutaneous manifestations in patients with acute severe infection, although the underlying cause, such as viral infection or drug reaction may be

challenging to identify.<sup>10</sup> For example, hydroxychloroquine, experimentally used for the treatment of COVID-19 in the early days of the pandemic, is associated with a generalised pustular rash.<sup>8,10</sup>

Since cutaneous manifestations of COVID-19 seem to be self-resolving, the treatment recommendations support symptoms control with analgesics, corticosteroids or non-steroidal anti-inflammatory drugs.<sup>11</sup>

## FIRST CASE

### Case presentation

A 70-year-old man with a medical history of arterial hypertension and type 2 diabetes mellitus was admitted to our COVID-19 ward. The diagnosis of SARS-CoV-2 infection by a positive nasopharyngeal swab test was made while he was asymptomatic, as he had high-risk contact with a family member who had been diagnosed with COVID-19. Subsequently, the patient began to experience thoracalgia, productive mucus cough and progressive fatigue and was admitted 8 days after the SARS-CoV-2 positive test to the hospital with bilateral pneumonia. He presented with erythematous–violaceous macules on the inner side of his feet (figure 1) and interdigital regions (figures 2 and 3).

### Investigations

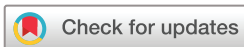Arterial blood gas analysis revealed pH 7.51, pCO<sub>2</sub> 30.5 mm Hg, pO<sub>2</sub> 59.9 mm Hg, oxygen saturation 93.7%, HCO<sub>3</sub><sup>-</sup> 26.2 mEq/L and lactate 1.2 mg/dL. Laboratory tests showed lymphopenia 800/μL, increased D-dimers (4693 ng/mL), hyponatraemia (123 mEq/L) and hypochloraemia (90 mEq/L), increased gamma-glutamyltransferase (GGT) (88.9 U/L) and lactate dehydrogenase (LDH) (392 U/L), and elevated C reactive protein (CRP) (62.50 mg/L) and ferritin (1675 ng/mL). The platelet count and renal function were both normal. Chest radiography revealed peripheral cotton infiltrates in both lung bases with greater extension in the right base (figure 4).

### Treatment

According to the recommended protocol by our government's health authority, Directorate-General of Health, the patient was started on oxygen and dexamethasone. Prophylactic enoxaparin, sodium chloride, furosemide, perindopril, paracetamol and metamizole were also administered.

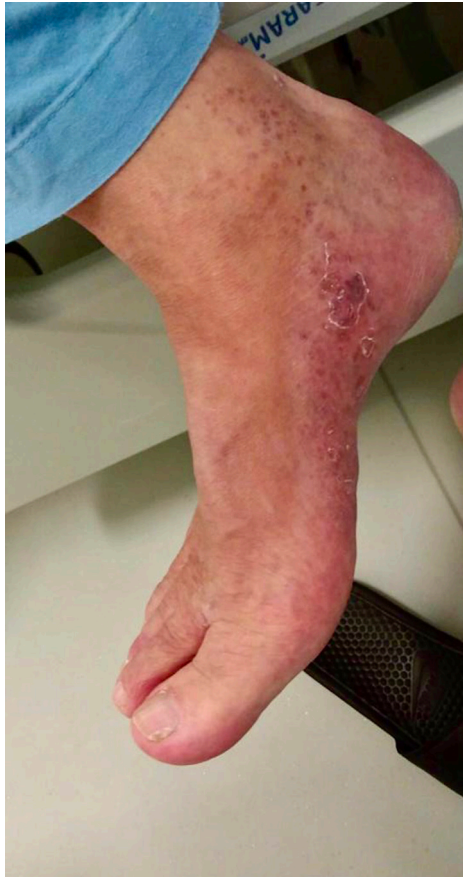### Outcome and follow-up

In the following days, the patient promptly recovered, and we have been able to gradually reduce



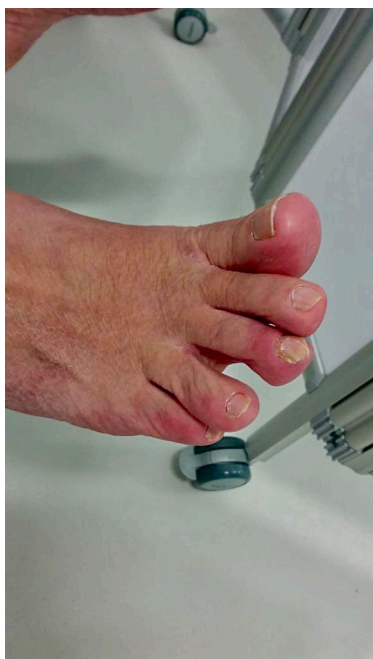© BMJ Publishing Group Limited 2021. Re-use permitted under CC BY-NC. No commercial re-use. See rights and permissions. Published by BMJ.

**To cite:** Luís H, Barros C, André D, *et al*. *BMJ Case Rep* 2021;**14**:e244763. doi:10.1136/bcr-2021-244763

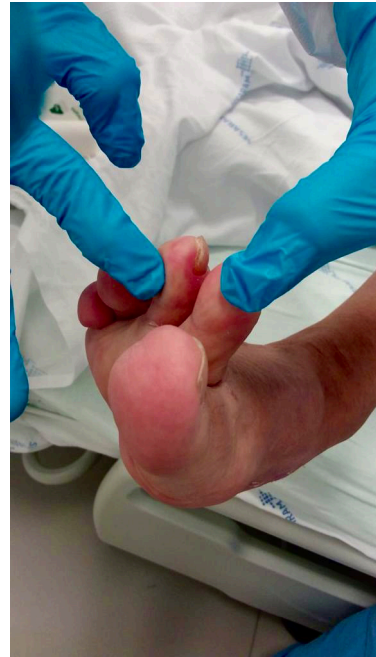

**Figure 1** Erythematous–violaceous macules on the inner side of the right foot.

oxygen flow. On the day of discharge, the patient maintained the skin changes despite the resolution of COVID-19 symptoms. In the re-evaluation consultation, 30 days after discharge, complete resolution of the dermatological manifestations was noted.



**Figure 2** Erythematous–violaceous macules in the interdigital region.



**Figure 3** Erythematous–violaceous macules in the interdigital region.

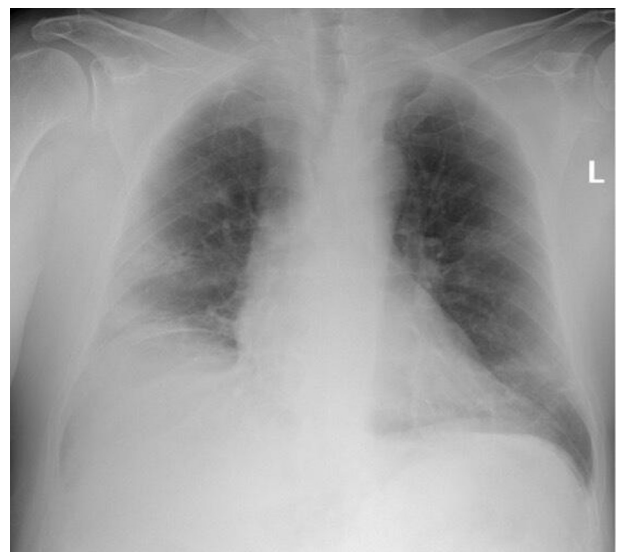
## SECOND CASE

### Case presentation

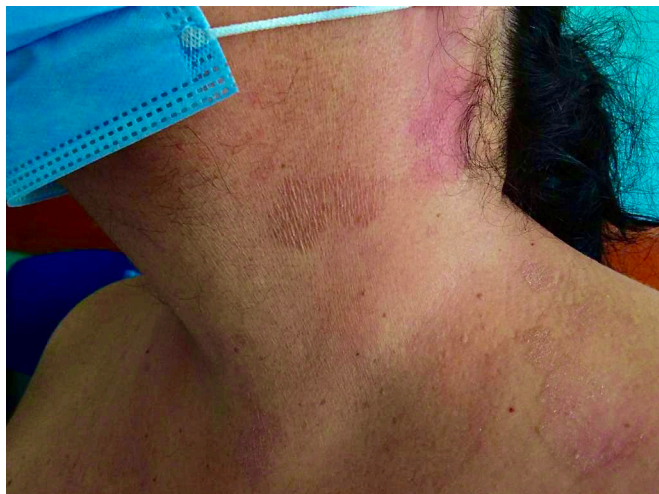A 57-year-old woman with a medical history of migraine, arterial hypertension, chronic venous insufficiency, gastro-oesophageal reflux disease and obesity, initially presented with diffuse urticarial rash on the cervical and chest region (figures 5 and 6). Three days later, she developed fever, fatigue and posterior thoracalgia.

### Investigations

Nasopharyngeal swab for SARS-CoV-2 RNA amplification came back positive on the day of admission to our COVID-19 ward. Blood test results revealed increased D-dimers (799 ng/mL), LDH (261 U/L), CRP (48.20 mg/dL) and ferritin (439 ng/mL). The white blood cells, platelet count, kidney and liver function,



**Figure 4** Chest radiography revealed peripheral cotton infiltrates in both lung bases with greater extension in the right base.



**Figure 5** Urticarial rash on the cervical region.

and ionogram were all normal. There were no signs of pneumonia on the chest X-ray.

#### Treatment

Oral cetirizine was started and the pruritus improved. Low-molecular-weight heparin in prophylactic dose (enoxaparin) and paracetamol were also administered.

#### Outcome and follow-up

Thirty days after discharge, the patient maintained the rash, but without the pruritus (figures 7 and 8).

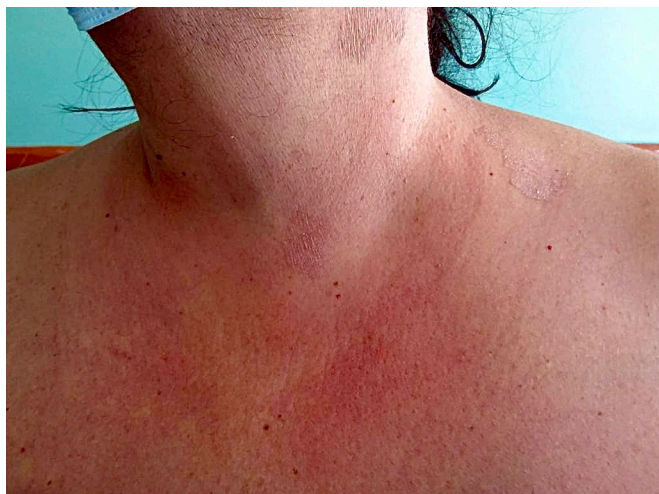### THIRD CASE

#### Case presentation

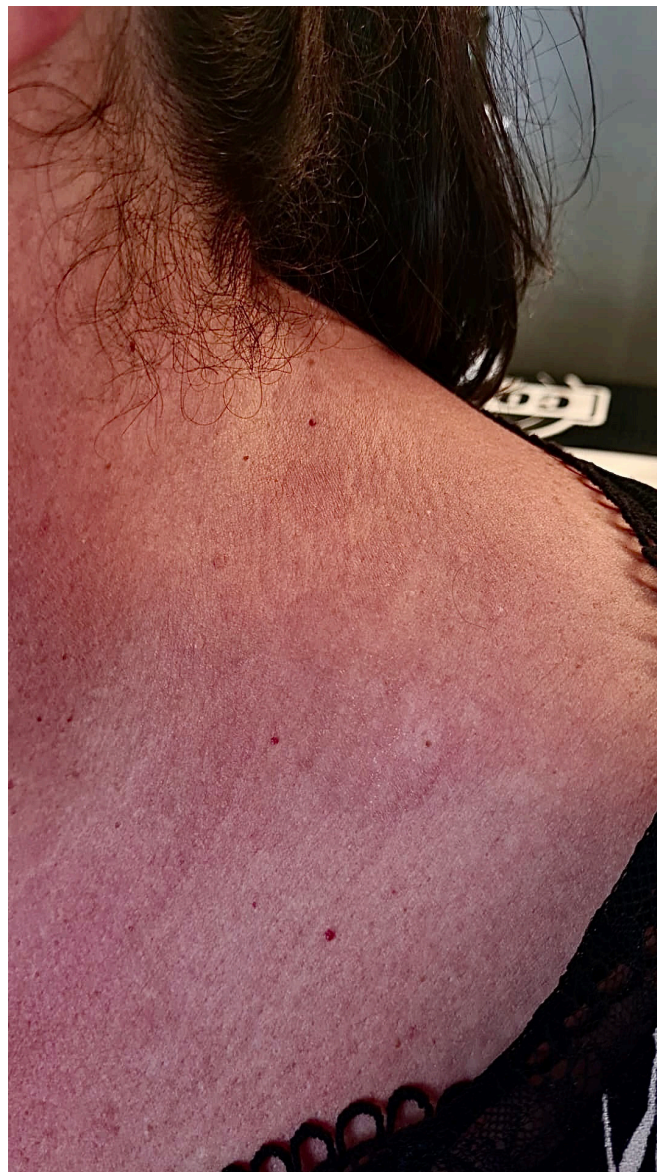A 49-year-old man with a medical history of colon tubulovillous adenoma with high-grade dysplasia was admitted with thoracalgia, worsening shortness of breath and dry cough. He also had, on the cervical and chest region, urticarial rash (figure 9), which started 5 days before.

#### Investigations

SARS-CoV-2 infection, tested for by a nasopharyngeal swab, was diagnosed. Laboratory tests showed lymphopenia (700/



**Figure 6** Urticarial rash on the cervical and chest region.



**Figure 7** Urticarial rash 1 month after discharge.

$\mu\text{L}$ ), increased D-dimers (500 ng/mL), abnormal liver function (alanine aminotransferase 60.6 U/L, aspartate aminotransferase 115.9 U/L and GGT 108.4 U/L), elevated LDH (316 U/L), CRP (106.21 mg/L) and ferritin (2886 ng/mL). Platelet count, renal function and ionogram were normal. Chest X-ray was negative for pneumonia.

#### Treatment

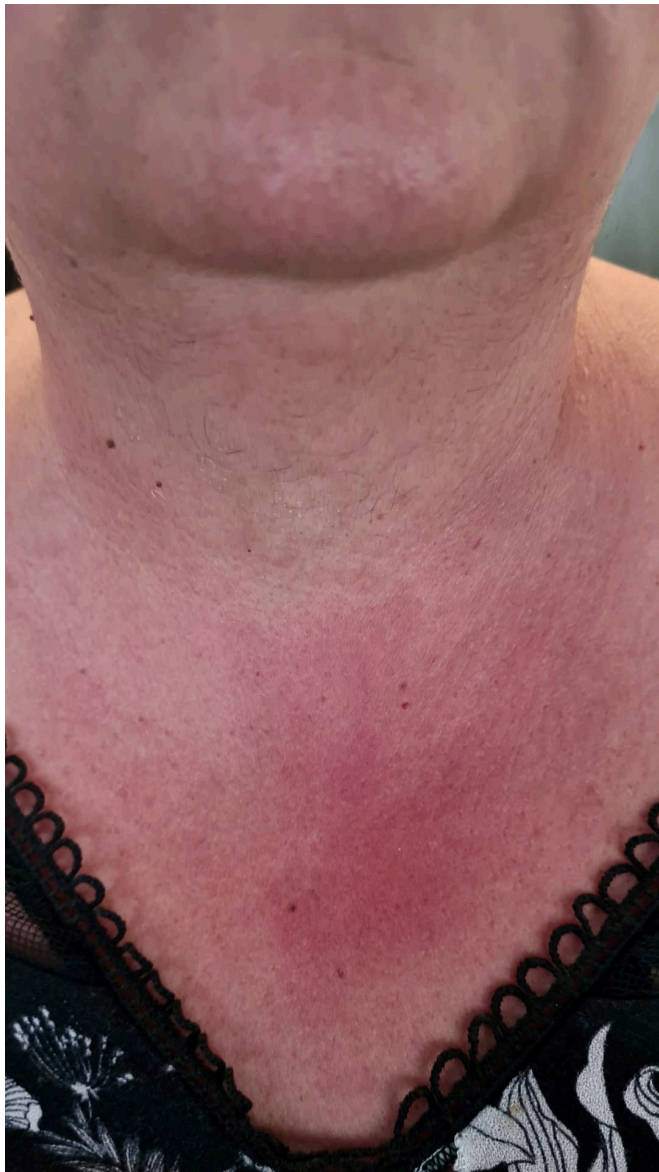The patient was treated with prophylactic enoxaparin, cetirizine and paracetamol.

#### Outcome and follow-up

The pruritus improved, and 5 days after discharge, the urticarial areas completely disappeared.

### DISCUSSION

The SARS-CoV-2 infection has caused numerous repercussions on millions of individuals worldwide, medically, financially and socially.<sup>2</sup> Also, it constituted a new challenge to recognise the extensive range of clinical manifestations of the disease for healthcare

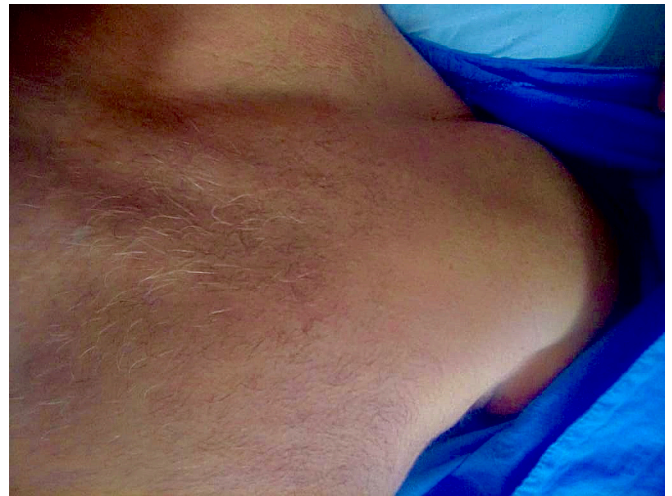


**Figure 8** Urticarial rash 1 month after discharge.

professionals. Despite all the information currently released on this virus, much remains unknown about the disease's clinical characteristics, including dermatological manifestations.

Articles from the beginning of the pandemic in Wuhan described the presence of rashes in 0.2% of 1099 confirmed cases of COVID-19,<sup>12</sup> so they were considered of little relevance for several months.<sup>12 13</sup> As the infection spread, reaching Europe, there was a vast recognition and interest in these category of manifestations.

The case series published by Recalcati in Lombardy<sup>1</sup> was the first report of the cutaneous manifestations in COVID-19 patients during the severe acute respiratory syndrome. In this study, which included 88 patients, 20.4% (n=18) had skin lesions. The patterns described included erythematous (77.8%), urticarial (16.7%) and varicella-like eruptions (5.6%).<sup>1 12</sup> After this publication, similar lesions were described in multiple clinical cases and case series, and other forms, such as petechiae lesions, perniosis-type, vasculitis, polymorphic erythema, livedo reticularis and reactivation of oral herpes simplex type 1 were also described.<sup>12 14</sup> Although most of these rashes appear to emerge from the cytopathic effect of the virus, some cutaneous



**Figure 9** Urticarial rash on the cervical and chest region.

patterns may be the result of a deregulatory response by the immune and thrombogenic systems through the uncontrolled release of interferon and proinflammatory cytokines.<sup>2 12</sup>

Acral lesions, also defined as pseudochilblain, are described as a localised inflammatory dermatological disorder presented as erythematous–violaceous or purpuric macules on fingers, elbows, toes and the lateral aspect of the feet.<sup>6</sup> These lesions have been observed to be more common in young adult patients with a milder disease course and manifesting after the onset of commonly COVID-19 symptoms.<sup>2 6</sup> However, our patient from case 1, was older and, for the presence of bilateral pneumonia requiring oxygen therapy, SARS-CoV-2 infection was considered of moderate severity. Pseudochilblain eruptions are frequently asymmetrically distributed,<sup>15</sup> and Galvan *et al* reported pain in 32% and itches in 30% of patients.<sup>6</sup> Our patient had these lesions on both feet and reported only pain on palpation. Despite Singh *et al* stating an association between these lesions and exposure to cold temperatures or damp, humid environments,<sup>16</sup> most studies did not confirm this relationship.<sup>2 7 12 17</sup>

The urticarial rash was the first dermatological pattern described in patients with SARS-CoV-2 infection<sup>12</sup> and can appear before cough and fever.<sup>15</sup> In the case series published by Recalcati, 16.7% of the 18 patients had these lesions, slightly itchy and mainly distributed over the trunk.<sup>1 12</sup> It is important to note that these skin changes did not correlate with the severity of the disease<sup>12</sup> and were described in patients with a milder clinical course and limited symptoms.<sup>13</sup> In the literature cases, this rash has improved with the introduction of oral antihistamines.<sup>12 15</sup> In our two patients with urticarial rashes, the COVID-19 had a

### Learning points

- ▶ Acral areas of erythema–oedema with some vesicles or pustules (pseudochilblain), other vesicular eruptions, urticarial lesions, other maculopapules, and livedos or necrosis are the most reported cutaneous symptoms of COVID-19.
- ▶ Clinicians should be aware of the cutaneous manifestations linked to COVID-19 as they might be the presenting sign of infection in asymptomatic or minimally symptomatic patients.
- ▶ As in most of the aspects intrinsic to this new virus, much remains to be revealed concerning cutaneous manifestations, which demands further investigations.

milder course, and the introduction of cetirizine improved the associated pruritus.

**Acknowledgements** The authors are grateful to our colleagues of COVID-19 ward, Sofia Gonçalves, Mariana Martins, João Paulo Correia, Miguel Santos, Pedro Balza, Pedro Mendes, and Ana Paula Reis, who collaborated in discussing the cases and were involved in drafting the manuscript.

**Contributors** HL carried out the conception of the manuscript, the acquisition of data on the patient in case 2, the literature search, the selection of information and the writing of the manuscript. CB carried out the literature search, the selection of information and helped in writing the manuscript. She also revised the manuscript. DA collected patient data from case 1 and 3. He helped in the literature search and the writing of the manuscript. AM carried out the literature search, analysis and interpretation of the collected data. She also contributed to the revision of the manuscript.

**Funding** The authors have not declared a specific grant for this research from any funding agency in the public, commercial or not-for-profit sectors.

**Competing interests** None declared.

**Patient consent for publication** Obtained.

**Provenance and peer review** Not commissioned; externally peer-reviewed.

**Open access** This is an open access article distributed in accordance with the Creative Commons Attribution Non Commercial (CC BY-NC 4.0) license, which permits others to distribute, remix, adapt, build upon this work non-commercially, and license their derivative works on different terms, provided the original work is properly cited and the use is non-commercial. See: <http://creativecommons.org/licenses/by-nc/4.0/>.

#### ORCID iD

Helena Luís <http://orcid.org/0000-0001-8422-3129>

#### REFERENCES

- 1 Recalcati S. Cutaneous manifestations in COVID-19: a first perspective. *J Eur Acad Dermatol Venereol* 2020;34:e210–40.
- 2 Daneshgaran G, Dubin DP, Gould DJ. Cutaneous manifestations of COVID-19: an evidence-based review. *Am J Clin Dermatol* 2020;21:627–39.
- 3 Askin O, Altunkalem RN, Altinisik DD, et al. Cutaneous manifestations in hospitalized patients diagnosed as COVID-19. *Dermatol Ther* 2020;33:e13896.
- 4 WHO coronavirus (COVID-19) Dashboard. Consulted on the 12th of March 2021. Available: <https://covid19.who.int>
- 5 Zhao Q, Fang X, Pang Z, et al. COVID-19 and cutaneous manifestations: a systematic review. *J Eur Acad Dermatol Venereol* 2020;34:2505–10.
- 6 Galván Casas C, Català A, Carretero Hernández G, et al. Classification of the cutaneous manifestations of COVID-19: a rapid prospective nationwide consensus study in Spain with 375 cases. *Br J Dermatol* 2020;183:71–7.
- 7 Feldman SR, Freeman EE. COVID-19: cutaneous manifestations as issues related to dermatologic care. UpToDate, 2021.
- 8 Seirafianpour F, Sodagar S, Pour Mohammad A, Mohammad AP, et al. Cutaneous manifestations and considerations in COVID-19 pandemic: a systematic review. *Dermatol Ther* 2020;33:e13986.
- 9 Algaadi SA. Urticaria and COVID-19: a review. *Dermatol Ther* 2020;33:e14290.
- 10 Estébanez A, Pérez-Santiago L, Silva E, et al. Cutaneous manifestations in COVID-19: a new contribution. *J Eur Acad Dermatol Venereol* 2020;34:e250–1.
- 11 Rose-Sauld S, Dua A. COVID toes and other cutaneous manifestations of COVID-19. *J Wound Care* 2020;29:486–7.
- 12 Relvas M, Calvão J, Oliveira R, et al. [Cutaneous Manifestations Associated with COVID-19: A Narrative Review]. *Acta Med Port* 2021;34:128–36.
- 13 Carrascosa JM, Morillas V, Bielsa I. Cutaneous manifestations in the context of SARS-CoV-2 infection (COVID-19). *Actas Dermosifiliogr* 2020;111:734–42.
- 14 Tang K, Wang Y, Zhang H, et al. Cutaneous manifestations of the coronavirus disease 2019 (COVID-19): a brief review. *Dermatol Ther* 2020;33:e13528.
- 15 Wollina U, Karadağ AS, Rowland-Payne C, et al. Cutaneous signs in COVID-19 patients: a review. *Dermatol Ther* 2020;33:e13549.
- 16 Singh H, Kaur H, Singh K, et al. Cutaneous manifestations of COVID-19: a systematic review. *Adv Wound Care* 2021;10:51–80.
- 17 Rahimi H, Tehraninia Z. A comprehensive review of cutaneous manifestations associated with COVID-19. *Biomed Res Int* 2020;2020:1236520.

Copyright 2021 BMJ Publishing Group. All rights reserved. For permission to reuse any of this content visit <https://www.bmj.com/company/products-services/rights-and-licensing/permissions/>  
BMJ Case Report Fellows may re-use this article for personal use and teaching without any further permission.

Become a Fellow of BMJ Case Reports today and you can:

- ▶ Submit as many cases as you like
- ▶ Enjoy fast sympathetic peer review and rapid publication of accepted articles
- ▶ Access all the published articles
- ▶ Re-use any of the published material for personal use and teaching without further permission

#### Customer Service

If you have any further queries about your subscription, please contact our customer services team on +44 (0) 207111 1105 or via email at [support@bmj.com](mailto:support@bmj.com).

Visit [casereports.bmj.com](http://casereports.bmj.com) for more articles like this and to become a Fellow