

Available online at [www.sciencedirect.com](http://www.sciencedirect.com)

ScienceDirect

journal homepage: [www.elsevier.com/locate/radcr](http://www.elsevier.com/locate/radcr)

## Case Report

# Multiple liver perforations: complication of an outpatient liposuction procedure

Julian Pohlan, MD<sup>a,\*</sup>, Hannah Miller<sup>b</sup>, Markus H. Lerchbaumer, MD<sup>a</sup>, Felix Krenzien, MD<sup>b</sup>, Christian Benzing, MD<sup>b</sup>, Martina T. Mogl, MD<sup>b</sup>, Torsten Diekhoff, MD<sup>a</sup>

<sup>a</sup> Department of Radiology, Campus Charité Mitte, Charité – Universitätsmedizin Berlin, corporate member of Freie Universität Berlin, Humboldt-Universität zu Berlin, and Berlin Institute of Health, Germany

<sup>b</sup> Surgical Department, Campus Charité Mitte, Campus Virchow-Klinikum, Charité Universitätsmedizin, Berlin, Germany

### ARTICLE INFO

#### Article history:

Received 11 January 2021

Revised 26 January 2021

Accepted 26 January 2021

Available online 6 February 2021

#### Keywords:

Liver perforation

CECT

CEUS

Liposuction

### ABSTRACT

We report on a 29-year-old woman who presented with abdominal right upper quadrant pain after an outpatient liposuction procedure. A contrast-enhanced computed tomography scan revealed 4 hepatic perforation tracts with subcapsular liver hematoma and hemoperitoneum. The patient was treated by intravenous tranexamic acid and isotonic fluids and monitored on an intensive care unit. No intervention or surgery was necessary during her hospital stay. Follow-up imaging after 3 days using contrast-enhanced ultrasound still showed the perforation tracts in the liver but no expansion of subcapsular hematoma. After 7 days, the patient was discharged home with stable hemoglobin and reduced pain. Liver perforation is a rare complication of liposuction procedures. In patients with abdominal pain after liposuction, contrast-enhanced imaging studies should be performed to identify and characterize solid organ injury. Teams with expertise in angiography and visceral surgery need to be on standby.

© 2021 The Authors. Published by Elsevier Inc. on behalf of University of Washington.

This is an open access article under the CC BY-NC-ND license (<http://creativecommons.org/licenses/by-nc-nd/4.0/>)

## Introduction

### Background

Inadvertent liver perforation is a rare complication of liposuction surgery that needs fast and adequate imaging to rule out active bleeding and detect potential damage of other parenchymal organs [1–3]. While ultrasound (US) is known

to be operator-dependent and may probably miss smaller organ lesions, contrast-enhanced computed tomography (ceCT) has emerged over the last decade as a rapid first-line imaging modality for assessing the extent of damage and deciding about the treatment strategy [4–8].

### Case report

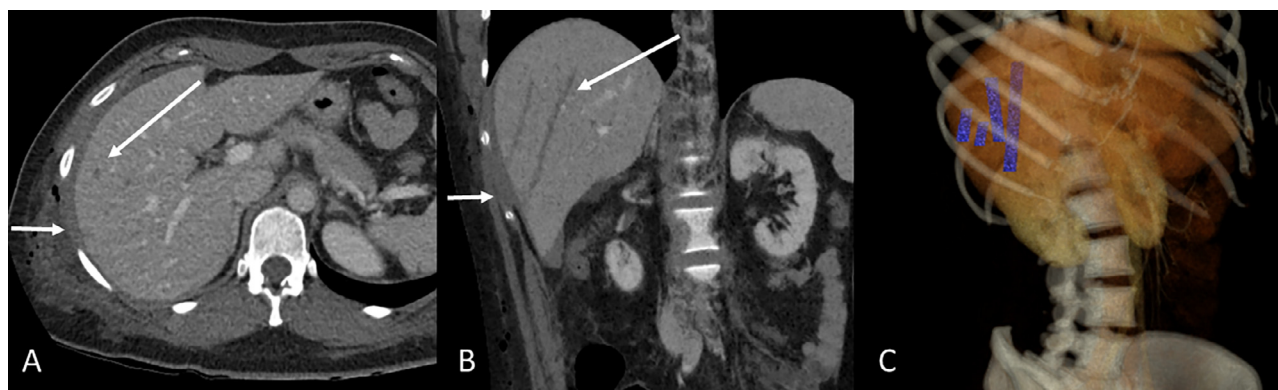
We report the case of a 29-year-old female patient who presented with rapidly progressing abdominal right upper quad-

\* Corresponding author.

E-mail address: [julian.pohlan@charite.de](mailto:julian.pohlan@charite.de) (J. Pohlan).

<https://doi.org/10.1016/j.radcr.2021.01.049>

1930-0433/© 2021 The Authors. Published by Elsevier Inc. on behalf of University of Washington. This is an open access article under the CC BY-NC-ND license (<http://creativecommons.org/licenses/by-nc-nd/4.0/>)



**Fig. 1 – Axial and coronal oblique reformation with arrows depicting the intrahepatic perforation tracts and the subcapsular hematoma (A and B). The shorter arrows point to the hematoma while the longer arrows point to one of the perforation tracts in the liver parenchyma. Virtual 3-dimensional reformation from the MinIP with depiction of all 4 perforation tracts (C). MinIP, minimum-intensity projection.**

rant pain after an outpatient liposuction procedure earlier that day. The patient suffered from chronic lipedema and underwent operative removal of subcutaneous fatty tissue using a suction cannula. The liposuction procedure took place around 12 PM and was terminated at 1 PM. In the afternoon at 3 PM, the patient developed right upper quadrant pain with radiation to the shoulder. The patient described the painful sensation as initially improving, then gradually worsening and she presented to the emergency department early in the evening at 8 PM.

Her initial examination in the emergency department revealed a small amount of free fluid in the abdominal cavity on bedside US. Hemoglobin (Hb) on admission was normal (12.6 g/dL). After triage, the surgeon on duty was consulted and pointed out the need for a prompt ceCT.

CeCT was performed in an 80-row CT scanner (Canon Aquilion Prime, Canon Medical Systems Cooperation, Otawara, Japan) after weight-adapted intravenous contrast medium administration (60 ml Ultravist 370, Bayer HealthCare, Leverkusen, Germany). The CT scan acquired in the portal-venous contrast phase detected no significant hematoma as a sign of active bleeding. Only a small subcapsular hematoma of the liver less than 2 cm in size was noted.

The minimum-intensity projection (MinIP) technique was used and visualized 4 hypodense perforation tracts in the parenchyma of the right liver lobe (Fig. 1). Unlike maximum-intensity projection, a MinIP image displays only the lowest attenuation values of a voxel in order to enhance low-density structures. This reconstruction was performed retrospectively at the second day after admission, when the case was discussed in an interdisciplinary conference. All perforation tracts began at the inferior capsule of the right liver lobe, and the longest tract extended 9 cm into the liver, that is, AAST Grade III. The patient was given 1 g tranexamic acid intravenously in order to increase coagulability and intravenous isotonic fluids for volume repletion and was admitted to an intensive care unit (ICU) for observation.

The patient's lowest hemoglobin level during the observation period was 9.2 g/dL. Based on the CT findings with no ev-

idence of major organ injury or active bleeding and a subsequent contrast-enhanced ultrasound (CEUS) examination not showing an increase in the amount of free fluid, the surgeon opted for conservative management and monitoring in the ICU without surgical repair.

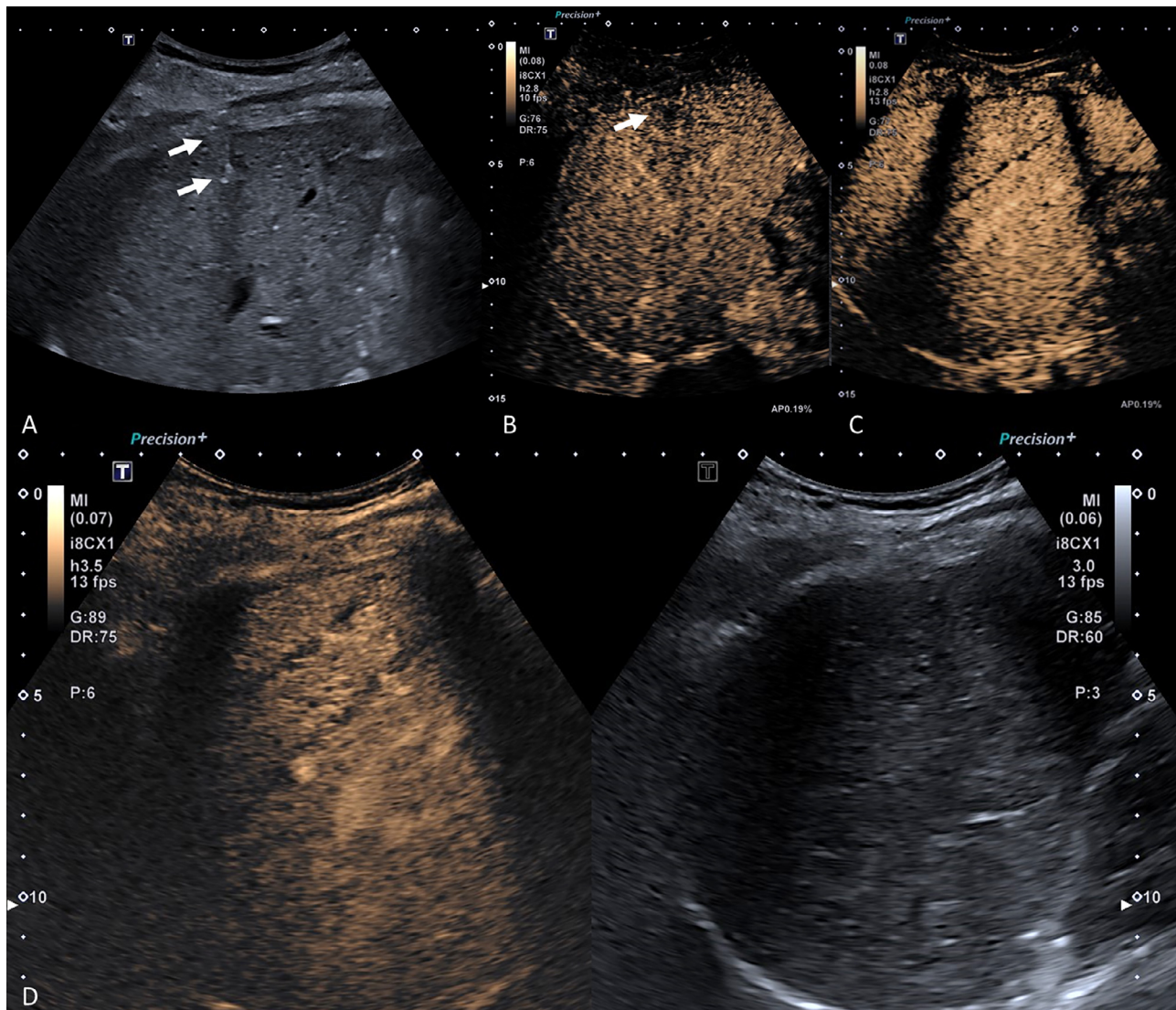
Intraperitoneal fluid was monitored by US follow-up examinations performed 1, 3 and 5 days after the liposuction procedure, including focused assessment of trauma (FAST) and imaging of the liver (Fig. 2). On the third day after trauma, additional CEUS examination was performed, using a high-end ultrasound system and a convex probe with a frequency range of 1-6 MHz (Aplio i800; Canon Medical Systems Corporation, Tochigi, Japan) with a state-of-the-art CEUS-specific protocol. The typical low mechanical index (<0.1) mode was used for CEUS to avoid early microbubble destruction. A bolus of 1.6 mL of ultrasound contrast agent (SonoVue, Bracco Imaging, Milan, Italy) was repeatedly injected. CEUS clearly depicted 3 of the 4 intrahepatic perforation tracts initially identified by ceCT, while only a subcapsular parenchymal injury was noted in region of the primary known fourth perforation tract. Moreover, complete resolution of the subcapsular hematoma was noted on day 3.

Due to the small size of the subcapsular hematoma, absence of bleeding and stable Hb, neither an angiographic intervention nor surgery were necessary during hospitalization. The patient was discharged home after 7 days with stable hemoglobin (final Hb level of 10.3 g/dL) and markedly reduced pain.

## Discussion

In this patient with clinically suspected iatrogenic complications of a liposuction procedure, imaging confirmed multiple liver perforations with subcapsular liver hematoma, and hemoperitoneum on CT but no active bleeding.

Liver perforation is a rare complication of liposuction procedures. One case report described extensive hepatic injury in a female patient with pleural fistula due to liposuction [1].



**Fig. 2 – B-mode US did not clearly identify the intrahepatic opacities but shows small hypoechoic subcapsular areas (A, B) indicating the extent of penetration tracts into the liver. CEUS (C) using split-screen with corresponding B-Mode image (D) shows subtle small nonenhancing lines within the liver during the late contrast phase after two minutes (C, D) without larger areas of parenchymal destruction. Interestingly the diameter of the perforation tracts decreased from 6 to 4 millimetres, which may be a sign of early tissue regeneration and restored blood flow. US, ultrasound; CEUS, contrast-enhanced ultrasound.**

A review presented 19 cases of liposuction-related intraperitoneal organ injuries [2]. However, the latter series did not include any liver injuries. In another review of 72 cases, sepsis was found to be the most common liposuction-related complication [3]. It was not possible to gather specific information with regards to the intervention in this patient. Generally, cannula length is reported to be 15–36 cm with a diameter of 3–5 mm [4,5]. Blunt-tip cannulas are commonly used for liposuction to minimize perforation risk [6]. As the procedure is performed with multiple rapid movements back and forth, a mislead trajectory – possibly facilitated by a deflection of the rib cage – must have led to the perforation of fascia, peritoneum and liver capsule for the cannula to

reach the liver parenchyma. No other obvious reasons were identified.

Nonsurgical management is well established in patients with blunt liver trauma confirmed by imaging [7]. This includes adequate observation during hospitalization and proper follow-up imaging such as US, CEUS or cross-sectional imaging. In patients with evidence of a vascular injury, subtraction angiography is gaining more importance as a minimally invasive and targeted treatment option [4]. Even if initial workup of abdominal injury and follow-up are performed using an optimal imaging strategy, an interdisciplinary approach and case discussion with cooperation of physicians from several subspecialties such as emergency medicine, surgery and



radiology/interventional radiology are essential to ensure optimal outcome.

Thus, patients with abdominal pain after liposuction should undergo contrast-enhanced imaging to identify solid organ laceration with vascular injury. Unstable patients may require emergency surgery, that is, packing of the liver or liver resection. In patients with active bleeding, angiography may be performed via femoral access to embolize the culprit artery using platinum coils or other materials [8]. The ladder presents the current standard of care for most hepatic bleeds due to trauma at this institution.

CEUS is an excellent tool for follow-up of liver perfusion defects as it uses a strictly intravascular contrast agent, which ensures good depiction of the microvascularization of parenchymal organs. The low rate of adverse events (0.0086%) and fast elimination of microbubbles by the lung make CEUS an optimal imaging tool that avoids radiation exposure, which is of special benefit in young patients, as in our case [9,10]. Moreover, it is a safe tool because the microbubble contrast agent has no cardiac or renal toxicity and can be used in patients with chronic renal failure and thyroid dysfunction. As demonstrated by Sessa et al in 256 patients with low-energy blunt abdominal trauma, US could be replaced by CEUS as a first-line approach due to its high sensitivity in detecting organ lesions and their grading [11]. Repeat ceCT or angiography is therefore only performed to rule out active bleeding in patients with severe CEUS findings. At this institution, a standard 3-phase ceCT protocol is used for detection of bleeding, that is, native – arterial – venous phase, though a split-bolus one-phase protocol may be performed initially.

Adhering to high standards in medical imaging as outlined above, one can determine the exact degree of liver injury and grade it based on the criteria of the American Association of Surgery for Trauma [12]. The diagnosis established with this approach leads to targeted surgical or nonsurgical treatment: if there is extravasation of contrast agent in ceCT and the patient is stable, he or she requires an emergency angiography and angioembolization. This procedure is highly effective in stopping active hemorrhage [13] and significantly lowers the mortality rate [14]. However, this minimally invasive intervention is not recommended for unstable patients with hepatic injury. Furthermore, if patients show signs of active bleeding and hemodynamic instability, they should be transferred to the operating room. The same recommendation holds for patients who rebleed after angiography [15]. Options to control bleeding intraoperatively range from coagulation procedures to temporary clamping of the inferior vena cava and hepato-duodenal ligament or even anatomical lobectomy [16]. If the patient develops any signs of coagulopathy, acidosis, or hypothermia, the damage should be controlled by packing the liver until it can be re-explored once the patient is stable. Orthotopic liver transplantation should be considered in extreme cases if the bleeding cannot be stopped and massive liver or hepatic venous injury occurs [17]. As highlighted in the case report, our patient was managed successfully by close monitoring and follow-up imaging, and there was no need for interventional or surgical management.

In conclusion, fast diagnosis of organ laceration and identification of potential vascular injury are mandatory in patients with suspected complication of liposuction. Interdisciplinary

cooperation of several subspecialties and implementation of an adequate imaging technique are essential for treatment planning and observation. Teams with expertise in angiography and visceral surgery need to be on standby.

## Patient consent

The patient provided written consent for the anonymous publication of this case report.

## REFERENCES

- [1] Ezzeddine H, Husari A, Nassar H, Kanso M, El Nounu G, Khalife M, et al. Life threatening complications post-liposuction. *Aesthetic Plast Surg* 2018;42(2):384–7.
- [2] Zakine G, Baruch J, Dardour J-C, Flageul G. Perforation of viscera, a dramatic complication of liposuction: a review of 19 cases evaluated by experts in France between 2000 and 2012. *Plast Reconstr Surg* 2015;135(3):743–50.
- [3] Lehnhardt M, Homann HH, Daigeler A, Hauser J, Palka P, Steinau H. Major and lethal complications of liposuction: a review of 72 cases in Germany between 1998 and 2002. *Plast Reconstr Surg* 2008;121(6) 396e–403e.
- [4] Young VL, Brandon HJ. The physics of suction-assisted lipoplasty. *Aesthetic Surg J* 2004;24(3):206–10. doi:10.1016/j.asj.2004.03.001.
- [5] Beck DO, Davis K, Rohrich RJ. Enhancing lipoaspirate efficiency by altering liposuction cannula design. *Plast Reconstr Surg Global Open* 2014;2(10):e222. doi:10.1097/gox.000000000000101.
- [6] Chia CT, Neinstein RM, Theodorou SJ. Evidence-based medicine: liposuction. *Plast Reconstr Surg* 2017;139(1) 267e–274e. doi:10.1097/prs.0000000000002859.
- [7] Brillantino A, Iacobellis F, Festa P, Mottola A, Acampora C, Corvino F, et al. Non-operative management of blunt liver trauma: safety, efficacy and complications of a standardized treatment protocol. *Bull Emerg Trauma* 2019;7(1):49.
- [8] Mohr AM, Lavery RF, Barone A, Bahramipour P, Magnotti L, Osband A, et al. Angiographic embolization for liver injuries: low mortality, high morbidity. *J Trauma Acute Care Surg* 2003;55(6):1077–82.
- [9] Piscaglia F, Bolondi L. The safety of Sonovue in abdominal applications: retrospective analysis of 23188 investigations. *Ultrasound Med Biol* 2006;32(9):1369–75. doi:10.1016/j.ultrasmedbio.2006.05.031.
- [10] Tang C, Fang K, Guo Y, Rui L, Xiaozhou Fan, Ping C, et al. Safety of sulfur hexafluoride microbubbles in sonography of abdominal and superficial organs: retrospective analysis of 30,222 cases. *J Ultrasound Med* 2017;36(3):531–8. doi:10.7863/ultra.15.11075.
- [11] Sessa B, Trinci M, Ianniello S, Gokalp P, Celik L, Dagdeviren B, et al. Blunt abdominal trauma: role of contrast-enhanced ultrasound (CEUS) in the detection and staging of abdominal traumatic lesions compared to US and CE-MDCT. *Radiol Med (Torino)* 2015;120(2):180–9. doi:10.1007/s11547-014-0425-9.
- [12] Moore EE, Cogbill TH, Jurkovich GJ, Malangoni M, Shackford MR, Champion HR, et al. Organ injury scaling: spleen and liver (1994 revision). *J Trauma* 1995;38(3):323–4. doi:10.1097/00005373-199503000-00001.
- [13] Sclafani SJ, Shaftan GW, McAuley J, Nayaranaswamy T, Mitchell WG, Gordon DH, et al. Interventional radiology in the management of hepatic trauma. *J Trauma* 1984;24(3):256–62. doi:10.1097/00005373-198403000-00013.

- [14] Malhotra AK, Fabian TC, Croce MA, Gavin TJ, Kenneth AK, Minard G, et al. Blunt hepatic injury: a paradigm shift from operative to nonoperative management in the 1990s. *Ann Surg*. 2000;231(6):804–13. doi:[10.1097/00000658-200006000-00004](https://doi.org/10.1097/00000658-200006000-00004).
- [15] Velmahos GC, Toutouzas KG, Radin R, Chan L, Demetriades D. Nonoperative treatment of blunt injury to solid abdominal organs: a prospective study. *Arch Surg* 2003;138(8):844–51. doi:[10.1001/archsurg.138.8.844](https://doi.org/10.1001/archsurg.138.8.844).
- [16] Ahmed N, Vernick JJ. Management of liver trauma in adults. *J Emerg Trauma Shock* 2011;4(1):114–19. doi:[10.4103/0974-2700.76846](https://doi.org/10.4103/0974-2700.76846).
- [17] Ringe B, Pichlmayr R. Total hepatectomy and liver transplantation: a life-saving procedure in patients with severe hepatic trauma. *Br J Surg* 1995;82(6):837–9. doi:[10.1002/bjs.1800820637](https://doi.org/10.1002/bjs.1800820637).