



# COVID-19 and mucormycosis superinfection: the perfect storm

Jaffar A. Al-Tawfiq<sup>1,2,3,21</sup> · Saad Alhumaid<sup>4</sup> · Abeer N. Alshukairi<sup>5</sup> · Mohamad-Hani Temsah<sup>6</sup> · Mazin Barry<sup>7</sup> · Abbas Al Mutairi<sup>8,9,10</sup> · Ali A. Rabaan<sup>11</sup> · Awadh Al-Omari<sup>12,13</sup> · Raghavendra Tirupathi<sup>14,20</sup> · Manaf AlQahtani<sup>15,16,17</sup> · Salma AlBahrani<sup>18</sup> · Kuldeep Dhama<sup>19</sup>

Received: 3 June 2021 / Accepted: 19 July 2021  
© Springer-Verlag GmbH Germany, part of Springer Nature 2021

## Abstract

**Background** The recent emergence of the Coronavirus Disease (COVID-19) disease had been associated with reports of fungal infections such as aspergillosis and mucormycosis especially among critically ill patients treated with steroids. The recent surge in cases of COVID-19 in India during the second wave of the pandemic had been associated with increased reporting of invasive mucormycosis post COVID-19. There are multiple case reports and case series describing mucormycosis in COVID-19.

**Purpose** In this review, we included most recent reported case reports and case-series of mucormycosis among patients with COVID-19 and describe the clinical features and outcome.

**Results** Many of the mucormycosis reports were reported from India, especially in COVID-19 patients who were treated and recovered patients. The most commonly reported infection sites were rhino-orbital/rhino-cerebral mucormycosis. Those patients were diabetic and had corticosteroids therapy for controlling the severity of COVID-19, leading to a higher fatality in such cases and complicating the pandemic scenario. The triad of severe acute respiratory syndrome coronavirus 2 (SARS-CoV-2), corticosteroid use and uncontrolled diabetes mellitus have been evident for significant increase in the incidence of angioinvasive maxillofacial mucormycosis. In addition, the presence of spores and other factors might play a role as well.

**Conclusion** With the ongoing COVID-19 pandemic and increasing number of critically ill patients infected with SARS-CoV-2, it is important to develop a risk-based approach for patients at risk of mucormycosis based on the epidemiological burden of mucormycosis, prevalence of diabetes mellitus, COVID-19 disease severity and use of immune modulating agents including the combined use of corticosteroids and immunosuppressive agents in patients with cancer and transplants.

**Keywords** SARS-CoV-2 · COVID-19 · Mucormycosis

## Introduction

The current Severe Acute Respiratory Syndrome Coronavirus 2 (SARS-CoV-2) infection is associated with a wide clinical spectrum of Coronavirus Disease 2019 (COVID-19) that ranges from being asymptomatic to severe disease requiring intensive care unit (ICU) admission [1–7]. The rate of admission to ICU is about 5% of all COVID-19 patients [8, 9]. Severe COVID-19 pneumonia is associated with immune dysregulation and cytokine syndrome leading to the increased use of immunomodulators [10, 11]. Emerging fungal infections such as aspergillosis were described in

critically ill patients treated with steroids [12]. The mortality rate of SARS-CoV-2 infection in critically ill patients co-infected with aspergillosis was high [13].

Since the emergence of the COVID-19 pandemic, it has been suspected that mucormycosis might cause significant morbidity to infected patients. This was based on a retrospective analysis of SARS and influenza cases as suggested by Song et al. [14]. The more vulnerable individuals are those requiring hospitalization and intensive care, which represent advanced stage of their disease [15]. The recent surge in cases of COVID-19 in India during the second wave of the pandemic had been associated with increased reporting of invasive mucormycosis post COVID-19, of up to 9000 cases and are continuously being reported to be rising, popularly known as black fungal infection [16–18]. In this review, we describe the important risk factors, clinical presentation and outcome of mucormycosis in patients infected with SARS-CoV-2.

✉ Jaffar A. Al-Tawfiq  
jaffar.tawfiq@jhah.com

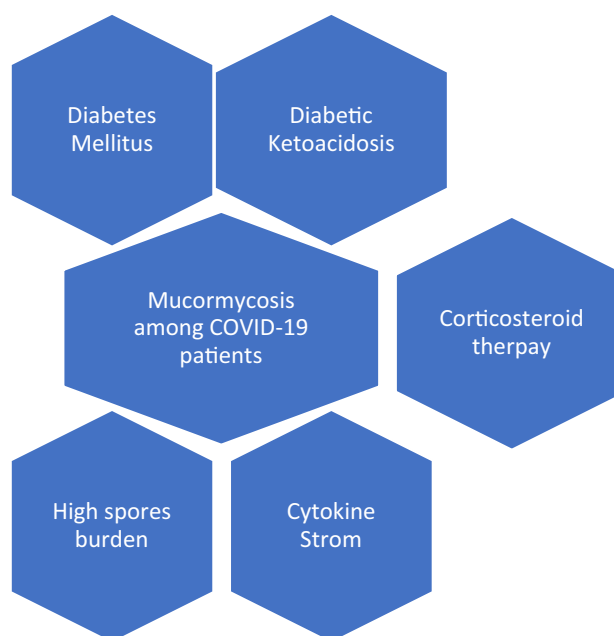
Extended author information available on the last page of the article

## Incidence and prevalence

The occurrence of mucormycosis, a rare disease, in the general population was previously cited as 0.005 to 1.7 per million population [19]. However, the incidence of mucormycosis in India was reported to be 0.14/1000 diabetic patients which is 80 times higher than that reported in other parts of the world [20] and more than that in the general population based on computational-modeling [21]. Given the large number of diabetic patients in India of almost 62 million, mucormycosis has caused large public health burden in India [20]. In one study, diabetes mellitus was the underlying disease in 54–76% of mucormycosis cases with 8–22% presenting with diabetic ketoacidosis [22]. In addition, there had been geographic difference in the rate of diabetes mellitus among patients with mucormycosis in India. Even prior to COVID-19, the prevalence of diabetes mellitus was a major risk factor with regional differences ranging from 67% in North India to 22% among patients from the South of India [23]. The true incidence of rhino-orbital mucormycosis in COVID-19 patients is not known. However, there are multiple case reports describing mucormycosis in COVID-19 and most of these case reports are presently from India, especially in COVID-19 treated and recovered patients those were diabetic and corticosteroids were administered injudiciously for controlling severity of COVID-19, leading to a higher fatality in such cases and complicating the pandemic scenario [17, 18, 24–37].

## Risk factors

There are multiple possible contributing factors for the development of mucormycosis among patients with COVID-19 and these include diabetes mellitus, obesity, use of corticosteroid, and the development of cytokine storms (Fig. 1). The triad of SARS-CoV-2, steroid and uncontrolled diabetes mellitus have contributed towards a significant increase in the incidence of angioinvasive maxillofacial mucormycosis [30]. However, the presence of spores and other factors might play a role as well [38]. The contribution of diabetes mellitus per se to the development of rhino-orbital-cerebral mucormycosis was the most common underlying comorbidity in 340 of 851 (40%) patients who were included in a meta-analysis, with an odds ratio (OR) of 2.49 (95% CI 1.77–3.54) compared to the next possible factor of having hematological malignancies with an OR of 0.76 (0.44–1.26) [19]. The role of Interleukin 6 blockers as a risk factor for mucormycosis is not clear [39]. Whether the combined use of steroids and interleukin 6 blockers will increase the risk



**Fig. 1** Possible contributing Factors for the development of Mucormycosis among COVID-19 patients

of mucormycosis compared to the use of steroids alone needs more studies.

## Clinical features and management

Literature review identified 30 publications of case reports and case series of mucormycosis among COVID-19 patients [24–26, 30, 31, 33–37, 40–55]. Of all the reports, 11 publications were from India [24–26, 30–37]. The most commonly reported infection sites were rhino-orbital/rhino-cerebral mucormycosis [24–26, 30, 32–37, 40, 42, 45, 47, 52–54]. Other presentations included pulmonary [31, 41, 43, 44, 49, 51, 55], cutaneous [46], disseminated [56] and gastrointestinal [48] diseases. The reported organisms were *Rhizopus* spp. [24, 31, 36, 41–44, 47, 49, 51, 55] and the others were reported as unspecified Mucorales [25, 26, 30, 33–35, 37, 40, 45, 48, 50, 52, 54]. The management of mucormycosis is usually difficult and requires urgent medical and surgical debridement while the choice of drug to treat mucormycosis is Amphotericin B [23, 57] and Amphotericin was used in 23 of the included studies [24–26, 30–37, 40–44, 46, 47, 49–54] and surgical debridement was reported in 20 of the included studies [24–26, 30, 32–37, 40, 44–47, 50–54]. The majority of the included patients in this review underwent surgical resection/debridement [24–26, 30, 32–37, 40, 44–47, 50–54].

**Table 1** Summary of clinical characteristics of the included studies of SARS-CoV-2 and mucormycosis co-infections, 2020–2021

Author, year, study location	Study design, setting	Age (years)	Male, n (%)	Underlying diseases	Mechanical ventilation, n (%)	Use of systemic corticosteroid therapy	Risk factors for mucormycosis	Histopathologic identification of an organism with a structure typical of Mucorales	Mucormycosis classification <sup>a</sup>	Clinical symptoms and signs of mucormycosis	Description of mucormycosis and etiologic agent
Alekseyev et al. (2021), United States [40]	Retrospective, case report, single centre	41	1 (100)	Diabetes	No	Yes	Uncontrolled diabetes, diabetic ketoacidosis	NA	Putative	Peripheral bilateral lung infiltrates with extension into the sinuses and intracranial abscess in the infratemporal fossa with cavernous sinus enhancement	Rhino-cerebral mucormycosis/ Mucorale(unspecified)
Bellanger et al. (2021), France [41]	Retrospective, case report, single centre	55	1 (100)	Lymphoma	Yes	Yes	Hematopoietic cell transplantation, steroid for SARS-CoV-2	NA	Putative	Non-specific bilateral ground glass opacities with development of pulmonary fibrosis	Pulmonary mucormycosis/ Rhizopus microsporus
Dallalza-deh et al. (2021), United States [42]	Retrospective, case reports, single centre	48	2 (100)	Diabetes (n=2)	NA	Yes (n=2)	Uncontrolled diabetes, diabetic ketoacidosis	No	Definite	Right sinonasal cavity and anterior skull base extending to bilateral frontal lobes	Rhino-orbital mucormycosis/ Rhizopus spp.

**Table 1** (continued)

Author, year, study location	Study design, setting	Age (years)	Male, n (%)	Underlying diseases	Mechanical ventilation, n (%)	Use of systemic corticosteroid therapy	Risk factors for mucormycosis	Histopathologic identification of an organism with a structure typical of Mucorales	Mucormycosis classification <sup>a</sup>	Clinical symptoms and signs of mucormycosis	Description of mucormycosis and etiologic agent
Garg et al. (2021), India [31]	Retrospective, case report, single centre	55	1 (100)	Diabetes, hypertension, coronary artery disease, cardiovascular myopathy, end-stage renal disease	Yes	Yes	Uncontrolled diabetes, steroid for SARS-CoV-2	No	Putative	Cough, expectoration, and burning micturition. A thick-walled cavity in the right upper lobe was confirmed	Pulmonary mucormycosis/ Rhizopus microsporus
Hanley et al. (2020), United Kingdom [56]	Retrospective, case series, multi-centre	22	7 (70)	Pancreatitis	Yes	Yes	Steroid for SARS-CoV-2	Yes	Definite (post-mortem)	NA	Disseminated (involving the hilar lymph nodes, heart, brain, and kidney)/ Mucorales (unspecified)
Johnson et al. (2021), United States [43]	Retrospective, case report, single centre	79	1 (100)	Diabetes, hypertension	Yes	Yes	Diabetes, steroid for SARS-CoV-2	Yes	Probable	Bilateral ground-glass opacities and infiltrates; then extensive bilateral pneumonia and new development of bilateral upper lobe cavitations were revealed	Pulmonary mucormycosis/ <i>Rhizopus arrhizus</i>

**Table 1** (continued)

Author, year, study location	Study design, setting	Age (years)	Male, n (%)	Underlying diseases	Mechanical ventilation, n (%)	Use of systemic corticosteroid therapy	Risk factors for mucormycosis	Histopathologic identification of an organism with a structure typical of Mucorales	Mucormycosis classification <sup>a</sup>	Clinical symptoms and signs of mucormycosis	Description of mucormycosis and etiologic agent
Kanwar et al. (2021), United States [44]	Retrospective, case report, single centre	56	1 (100)	End-stage renal disease (hemodialysis)	Yes	Yes	NA	Yes	Definite	Patchy ground glass infiltrates with pleural effusion with an increased area of density concerning for blood	Pulmonary mucormycosis/ <i>Rhizopus arryzo</i>
Karimi-Galouaghi et al. (2021), Iran [45]	Retrospective, case report, single centre	61	0 (0)	Diabetes	0 (0)	Yes	Uncontrolled diabetes, steroid for SARS-CoV-2	Yes	Definite	Right hemifacial pain and numbness, decreased visual acuity, chemosis, proptosis, frozen eye, complete loss of vision, and fixed mydriasis	Rhino-orbital mucormycosis/Mucorales (unspecified)

**Table 1** (continued)

Author, year, study location	Study design, setting	Age (years)	Male, n (%)	Underlying diseases	Mechanical ventilation, n (%)	Use of systemic corticosteroid therapy	Risk factors for mucormycosis	Histopathologic identification of an organism with a structure typical of Mucorales	Mucormycosis classification <sup>a</sup>	Clinical symptoms and signs of mucormycosis	Description of mucormycosis and etiologic agent
Khatri et al. (2021), United States [46]	Retrospective, case report, single centre	68	1 (100)	Diabetes, hypertension, coronary artery disease, OSA, renal failure	Yes	Yes	Diabetes, hypertension, solid organ transplantation	Yes	Definite	Purplish skin discoloration with fluctuant swelling was noted in the right axilla, at the prior IABP catheter insertion site	Cutaneous mucormycosis/ Rhizopus microsporus
Maini et al. (2021), India [32]	Retrospective, case report, single centre	38	1 (100)	None	No	Yes	Steroid for SARS-CoV-2	Yes	Definite	Patient developed chemosis and pain in the left eye	Sino-orbital mucormycosis/ Rhizopusoryzae
Mehta et al. (2020), India [33]	Retrospective, case report, single centre	60	1 (100)	Diabetes	1 (100)	Yes	Uncontrolled diabetes, steroid for SARS-CoV-2	Yes	Definite	Unilateral facial swelling, unilateral periorbital facial pain, eyelid oedema, ptosis, proptosis, right orbital cellulitis, acute vision loss	Rhino-orbital-cerebral mucormycosis/Mucorale (unspecified)

**Table 1** (continued)

Author, year, study location	Study design, setting	Age (years)	Male, n (%)	Underlying diseases	Mechanical ventilation, n (%)	Use of systemic corticosteroid therapy	Risk factors for mucormycosis	Histopathologic identification of an organism with a structure typical of Mucorales	Mucormycosis classification <sup>a</sup>	Clinical symptoms and signs of mucormycosis	Description of mucormycosis and etiologic agent
Mekonen et al. (2021), United States [47]	Retrospective, case report, single centre	60	1 (100)	Diabetes, asthma, hypertension, hyperlipidaemia	Yes	Yes	Uncontrolled diabetes, steroid for SARS-CoV-2	Yes	Definite	Right globe proptosis, oedema of the eyelids and conjunctival chemosis, extensive opacification of right maxillary, ethmoid, and frontal sinuses	Rhino-orbital mucormycosis/ <i>Rhizopus</i> spp.
Monte Junior et al. (2020), Brazil [48]	Retrospective, case report, single centre	86	1 (100)	Hypertension	Yes	Yes	Steroid for SARS-CoV-2	Yes	Definite	Gastric ulcers, acute diarrhea, melena, severe anemia, and fever	Gastrointestinal mucormycosis/Mucorales (unspecified)

**Table 1** (continued)

Author, year, study location	Study design, setting	Age (years)	Male, n (%)	Underlying diseases	Mechanical ventilation, n (%)	Use of systemic corticosteroid therapy	Risk factors for mucormycosis	Histopathologic identification of an organism with a structure typical of Mucorales	Mucormycosis classification <sup>a</sup>	Clinical symptoms and signs of mucormycosis	Description of mucormycosis and etiologic agent
Moorthy et al. (2021), India [30]	Retrospective, case series, multi-centre	Median (IQR), 55.5 (48–63)	15 (83.3)	Diabetes (n = 16)	NA	Yes (n = 16)	Uncontrolled diabetes (n = 6), steroid for SARS-CoV-2 (n = 16)	Yes	Definite (n = 17)	Patients presented with one or more of the following symptoms: facial cellulitis, maxillary sinusitis, headache, necrosis of palatal bone/mucosa or acute loss of vision	Sinusitis alone (n = 3), Rhino-orbital (n = 6), Rhino-orbital-cerebral (n = 5), Rhino-cerebral (n = 3)/Mucorales (unspecified)
Pasero et al. (2020), Italy [49]	Retrospective, case report, single centre	66	1 (100)	Hypertension	Yes	No	Lymphopenia	Yes	Putative	Pulmonary infiltrates with an increase of parenchymal thickening of the whole left lung, cavitary lesions in left lung and pleural effusion, opacification of the left maxillary sinus	Pulmonary mucormycosis/ <i>Rhizopus</i> spp.



**Table 1** (continued)

Author, year, study location	Study design, setting	Age (years)	Male, n (%)	Underlying diseases	Mechanical ventilation, n (%)	Use of systemic corticosteroid therapy	Risk factors for mucormycosis	Histopathologic identification of an organism with a structure typical of Mucorales	Mucormycosis classification <sup>a</sup>	Clinical symptoms and signs of mucormycosis	Description of mucormycosis and etiologic agent
Pauli et al. (2021), Brazil [50]	Retrospective, case report, single centre	50	0 (0)	Diabetes	NA	No	Uncontrolled diabetes	Yes	Definite	Ulcerated lesion with coagulative necrosis, hemorrhage, and abundant neutrophils	Palatal ulcer/Mucorales (unspecified)
Placik et al. (2020), United States [51]	Retrospective, case report, single centre	49	1 (100)	None	Yes	Yes	Steroid for SARS-CoV-2	Yes	Definite	Right pneumothorax, bronchopulmonary fistula, necrotic empyema	Pulmonary mucormycosis/ <i>Rhizopus</i> spp.
Rao et al. (2021), India [34]	Retrospective, case report, single centre	66	1 (100)	Diabetes	No	Yes	Uncontrolled diabetes, steroid for SARS-CoV-2	Yes	Definite	Periorbital pain followed by sudden onset of vision loss in the left eye	Rhino-orbital mucormycosis/Mucorales (unspecified)

**Table 1** (continued)

Author, year, study location	Study design, setting	Age (years)	Male, n (%)	Underlying diseases	Mechanical ventilation, n (%)	Use of systemic corticosteroid therapy	Risk factors for mucormycosis	Histopathologic identification of an organism with a structure typical of Mucorales	Mucormycosis classification <sup>a</sup>	Clinical symptoms and signs of mucormycosis	Description of mucormycosis and etiologic agent
Ravani et al. (2021), India [35]	Retrospective, case series, single centre	Mean, 56.3	NA	Diabetes (n = 19); plus, other comorbidities (hypertension/ischemic heart disease/kidney disease)	NA	Yes	Uncontrolled diabetes, steroid for SARS-CoV-2	NA	NA	The most common presentation was diminution of vision (< 6/60 in 80.64% patients) and ophthalmoplegia (77.4%). The most common imaging findings were orbital cellulitis (61.29%) and pansinusitis (77.4%)	Rhino-orbital mucormycosis/Mucorales (unspecified)
Revannavar et al. (2021), India [36]	Retrospective, case report, single centre	NA	0 (0)	Diabetes	No	No	Uncontrolled diabetes	Yes	Definite	Patient presented with left-sided facial pain, complete ptosis	Rhino-orbital mucormycosis/ <i>Rhizopus</i> spp.
Saldanha et al. (2021), India [37]	Retrospective, case report, single centre	32	0 (0)	Diabetes	No	No	Uncontrolled diabetes	Yes	Definite	Patient presented with left eye complete ptosis and left facial pain	Sino-orbital mucormycosis/Mucorales (unspecified)

**Table 1** (continued)

Author, year, study location	Study design, setting	Age (years)	Male, n (%)	Underlying diseases	Mechanical ventilation, n (%)	Use of systemic corticosteroid therapy	Risk factors for mucormycosis	Histopathologic identification of an organism with a structure typical of Mucorales	Mucormycosis classification <sup>a</sup>	Clinical symptoms and signs of mucormycosis	Description of mucormycosis and etiologic agent
Sarkar et al. (2021), India [24]	Retrospective, case series, multi-centre	Median (IQR), 46.5 (30.7–59.7)	8 (80)	Diabetes (n = 10)	Yes (n = 9)	Yes (n = 10)	Diabetic ketoacidosis (n = 9)	NA	Definite (n = 4), probable (n = 2)	NA	Rhino-orbital (n = 5), Rhino-orbital-cerebral (n = 1)/Rhizopus (n = 4), Mucor (n = 2)
Sen et al. (2021), India [25]	Retrospective, case series, multi-centre	Median (IQR), 61.4 (46.8–73.1)	6 (100)	Diabetes (n = 5), hypertension (n = 1), coronary artery disease (n = 1)	NA	All patients received systemic corticosteroids for SARS-CoV-2 except for one patient	Uncontrolled diabetes (n = 3), steroid for SARS-CoV-2 (n = 5), diabetic ketoacidosis (n = 2)	Yes	Definite (n = 5), probable (n = 1)	All patients complained of pain, redness, and periorbital swelling as initial symptoms. This was followed by acute, progressive, drooping of eyelids, limitation of ocular movements, and painful loss of vision	Rhino-orbital-cerebral mucormycosis/Mucorale (unspecified)
Sharma et al. (2021), India [26]	Prospective, case series, single centre	NA	15 (65.2)	Diabetes (n = 21), hypertension (n = 14), renal failure (n = 1)	NA	Yes (n = 23)	Uncontrolled diabetes (n = 12)	No	NA	Intra-orbital extension was seen in 43.47% of cases, while intracranial extension was only seen in 8.69%	Intra-orbital (n = 10), intra-cranial (n = 2) and palatal (n = 1)

**Table 1** (continued)

Author, year, study location	Study design, setting	Age (years)	Male, n (%)	Underlying diseases	Mechanical ventilation, n (%)	Use of systemic corticosteroid therapy	Risk factors for mucormycosis	Histopathologic identification of an organism with a structure typical of Mucorales	Mucormycosis classification <sup>a</sup>	Clinical symptoms and signs of mucormycosis	Description of mucormycosis and etiologic agent
Veisi et al. (2021), Iran [52]	Retrospective, case reports, single centre	40 (Case 1) and 54 (Case 2)	1 (50)	None (Case 1) Diabetes (Case 2)	No	Yes (n=2)	Diabetes (n=1), steroid for SARS-CoV-2 (n=2)	Yes (n=2)	Definite	Bilateral visual loss and periorbital pain with complete blepharoptosis and ophthalmoplegia together with mild proptosis (Case 1) Left orbital pain and periorbital swelling together with progressive vision loss (Case 2)	Rhino-orbital (n=1) and/or rhino-orbito-cerebral (n=1) mucormycosis/ Mucorale (unspecified)
Waizel-Haiat et al. (2021), Mexico [53]	Retrospective, case report, single centre	24	0 (0)	Diabetes	Yes	NA	Uncontrolled diabetes, diabetic ketoacidosis	No	Probable	Severe left lid edema with extension to the upper lip and malar region, left proptosis with a hyperemic conjunctiva, and an opaque cornea	Rhino-orbital mucormycosis/Lichteimia (Absidia) spp.

Table 1 (continued)

Author, year, study location	Study design, setting	Age (years)	Male, n (%)	Underlying diseases	Mechanical ventilation, n (%)	Use of systemic corticosteroid therapy	Risk factors for mucormycosis	Histopathologic identification of an organism with a structure typical of Mucorales	Mucormycosis classification <sup>a</sup>	Clinical symptoms and signs of mucormycosis	Description of mucormycosis and etiologic agent
Werthman-Ehrenreich et al. (2021), United States [54]	Retrospective, case report, single centre	33	0 (0)	Diabetes, asthma, hypertension	NA	No	Diabetic ketoacidosis	NA	Definite	Necrotic palate, necrotic nasal, left eye ptosis, altered mental status, ophthalmoplegia proptosis	Rhino-orbital-cerebral mucormycosis/ Mucorale(unspecified)
Zurl et al. (2021), Austria [55]	Retrospective, case report, single centre	53	1 (100)	Myelodysplastic syndrome, acute myeloid leukemia	Yes	Yes	Intensive chemotherapy (neutropenia), steroid for SARS-CoV-2 (n=5)	Yes	Definite (post-mortem)	Increase of bilateral infiltrates and the patient developed severe ARDS	Pulmonary mucormycosis/ Rhizopus microspores
Pakdel et al.; (2021), [78]	Cross-sectional descriptive multicenter study	Median 52 years (range 14–71)	15 and 9 (66%) male	86% diabetes mellitus	NA	7 (46.6%)	Diabetes and Steroid	Yes	Definite	Variable	Rhino-orbital
Singh et al. (2021); India [79]	Case report	48	1 M	None	No	No	NA	Yes	Definite	Abdominal pain, nausea, vomiting	Gastrointestinal mucormycosis
Arijun et al. (2021); India [80]	Case series	53.0 ± 12.1 years	10 cases (80%)	30% had coronary artery disease	NA	Yes in 80%	Corticosteroid	Yes	Definite	Headache and facial pain	Rhino-orbital
Saidha et al. (2021); India [81]	Case series	47	6 cases (66%)	Diabetes Mellitus	NA	In 1 patient	Diabetes Mellitus	Yes	Definite	Headache and facial pain	Paranasal sinusitis

**Table 1** (continued)

Author, year, study location	Study design, setting	Age (years)	Male, n (%)	Underlying diseases	Mechanical ventilation, n (%)	Use of systemic corticosteroid therapy	Risk factors for mucormycosis	Histopathologic identification of an organism with a structure typical of Mucorales	Mucormycosis classification <sup>a</sup>	Clinical symptoms and signs of mucormycosis	Description of mucormycosis and etiologic agent
Jain et al. (2021); India [82]	Case report	57	Female	Diabetes Mellitus	No	Yes	Diabetes Mellitus	Yes	Definite	Abdominal pain, nausea, vomiting	Abdominal
Baskar et al. (2021); India [83]	Case report	28	Male	None	No	No	None	Yes	Definite	Acute loss of vision	Rhino-orbital
Joshi et al. (2021), India [84]	Case series	55.2 ± 13 years	16 men, 9 women	22 had DM; 2 HIV	20 (80%)	Yes	6 (27%)	Yes (n = 10)	Radiographic and histopathology in selected patients	Variable	Rhino-orbito-cerebral
Sen et al. (2021); India [85]	Case series	Mean age 51.9 years	2826 patients; male 71%	Diabetes mellitus 78%	NA	87%	Diabetes and Steroid	NA	Definite	Variables	NA; rhino-orbital-cerebral mucormycosis

ARDS acute respiratory distress syndrome, IABP intra-aortic balloon pump, NA not available, spp. species, SARS-CoV-2 severe acute respiratory syndrome coronavirus 2, OSA obstructive sleep apnea

<sup>a</sup>Definite—if histopathologic, cytopathologic or direct microscopic examination of a specimen obtained by needle aspiration or biopsy in which hyphae or melanized yeast-like forms were seen accompanied by evidence of associated tissue damage OR Recovery of a hyaline or pigmented mold by culture of a specimen obtained by a sterile procedure from a normally sterile and clinically or radiologically abnormal site consistent with an infectious disease process, excluding BAL fluid, a paranasal or mastoid sinus cavity specimen, and urine OR Blood culture that yielded a mold (e.g., *Fusarium* species) in the context of a compatible infectious disease process OR Amplification of fungal DNA by PCR combined with DNA sequencing when molds were seen in formalin-fixed paraffin-embedded tissue. Probable—concluded as the presence of combined host factors and clinical criterion with mycological evidence and if only the criteria for a host factor and a clinical criterion were met but mycological criteria were absent, possible mucormycosis was diagnosed. Putative—if none of the criteria were met but *Mucor* is attributed as a pathogen and patient was treated for it

**Table 2** Summary of therapy and outcome of mucormycosis among SARS-CoV-2 infected patients

Author, year, study location	Time between diagnosis of SARS-CoV-2 and mucormycosis (days)	Surgical debridement made	Antifungal treatment	Treatment outcome
Alekseyev et al. (2021), United States [40]	NA	Yes	Amphotericin B	Survived
Bellanger et al. (2021), France [41]	15	NA	Amphotericin B	Died
Dallalzadeh et al. (2021), United States [42]	6	No	Amphotericin B, isavuconazole	Died ( <i>n</i> =2)
Garg et al. (2021), India [31]	17	Scheduled for right upper lobectomy	Amphotericin B	Survived
Hanley et al. (2020), United Kingdom [56]	NA	No	No	Died
Johnson et al. (2021), United States [43]	NA	NA	Amphotericin B, voriconazole	Discharged
Kanwar et al. (2021), United States [44]	16	Yes	Amphotericin B	Died
Karimi-Galougahi et al. (2021), Iran [45]	21	Yes	Systemic antifungals (Unspecified)	Survived
Khatiri et al. (2021), United States [46]	90	Yes	Amphotericin B, posaconazole	Died
Maini et al. (2021), India [32]	18	Yes	Amphotericin B, fluconazole	Survived
Mehta et al. (2020), India [33]	10	Yes	Amphotericin B	Died
Mekonnen et al. (2021), United States [47]	7	Yes	Amphotericin B, caspofungin, posaconazole;	Died
Monte Junior et al. (2020), Brazil [48]	5	No	No	Died
Moorthy et al. (2021), India [30]	NA	Yes ( <i>n</i> = 7)	Amphotericin B	Survived ( <i>n</i> = 11), died ( <i>n</i> = 6) and lost to follow-up ( <i>n</i> = 1)
Pasero et al. (2020), Italy [49]	17	No	Amphotericin B, isavuconazole	Died
Pauli et al. (2021), Brazil [50]	8	Yes	Amphotericin B	Survived
Placik et al. (2020), United States [51]	14	Yes	Amphotericin B	Died
Rao et al. (2021), India [34]	NA	Yes	Amphotericin B	Survived
Ravani et al. (2021), India [35]	NA	Yes ( <i>n</i> = 19)	Amphotericin B ( <i>n</i> = 19)	Survived ( <i>n</i> = 18), died ( <i>n</i> = 1)
Revannavar et al. (2021), India [36]	NA	Yes	Amphotericin B	Survived
Saldanha et al. (2021), India [37]	NA	Yes	Amphotericin B	Survived
Sarkar et al. (2021), India [24]	NA	Yes	Amphotericin B	Improved ( <i>n</i> = 1), died ( <i>n</i> = 4), unchanged ( <i>n</i> = 4), exenteration ( <i>n</i> = 1)
Sen et al. (2021), India [25]	Mean ± SD (minimum–maximum), 15.6 ± 9.6 (3–42)	Yes	Amphotericin B, voriconazole/posaconazole ( <i>n</i> = 5)	Survived ( <i>n</i> = 5)
Sharma et al. (2021), India [26]	NA	Yes	Amphotericin B	Survived ( <i>n</i> = 23)

Table 2 (continued)

Author, year, study location	Time between diagnosis of SARS-CoV-2 and mucormycosis (days)	Surgical debridement made	Antifungal treatment	Treatment outcome
Veisi et al. (2021), Iran [52]	8 (Case 1) and 7 (Case 2)	Yes ( $n=2$ )	Amphotericin B ( $n=2$ )	Died (Case 1) and discharged (Case 2)
Waizel-Haiat et al. (2021), Mexico [53]	6	Yes	Amphotericin B	Died
Werthman-Ehrenreich et al. (2021), United States [54]	2	Yes	Amphotericin B	Died
Zurl et al. (2021), Austria [55]	NA	No	None	Died
Pakdel et al.; (2021), Iran [78]	1–37	33%	6 (40%) combined antifungal	7 (47%) died
Singh et al. (2021); India [79]	19	Yes	Liposomal amphotericin B	Recovered
Arjun et al. (2021); India [80]	17.0 ± 3.6	Yes	Amphotericin B deoxycholate and isavuconazole	10% died
Saidha et al. (2021); India [81]	NA	Yes	Amphotericin	Recovered
Jain et al. (2021); India [82]	15	Yes	NA	Recovered
Baskar et al. (2021); India [83]	On diagnosis	Yes	Amphotericin	Recovered
Joshi et al. (2021), India [84]	Not indicated	yes in 10 (45%)	Amphotericin	14 (63%) died
Sen et al. (2021); India [85]	10–15	56% had functional endoscopic sinus surgery (FESS)/paranasal sinus (PNS) debridement, 15% orbital exenteration in 15%, 17% both FESS/PNS debridement and orbital exenteration	Amphotericin B in 73%	Mortality 14%



## Outcomes and prognosis

Before the COVID-19 era, mucormycosis is known for its poor prognosis, especially with delayed management may lead to a high mortality rate. There was no difference in the mortality between solid organ transplants and diabetes mellitus with a mortality of about 28%, (2/7 (28.57%) vs 5/18 (27.78%);  $p=0.66$  in patients with solid organ transplant and diabetes mellitus, respectively) [58]. However, another study showed higher mortality of 49% among diabetes mellitus patients compared to 30% among non-diabetic patients [58]. Morbidity and mortality were linked to the invasive nature of the underlying disease [59]. However, even with COVID-19, early intravenous anti-fungal treatment and surgical debridement were associated with favorable outcomes [26].

## Discussion

The etiologic agent of mucormycosis are ubiquitous in nature and thus may easily be acquired, and its global epidemiology has been studied by several investigators, and may pose a threat during ongoing pandemic as has been observed in India [17, 23, 27, 57, 60, 61]. Due to the steep rise in cases of mucormycosis (black fungus infection) amid the second COVID-19 pandemic wave and its association with severe complications and associated higher fatality rate in post COVID-19 patients, this rare disease is now a notifiable disease in India. It is postulated that the use of non-sterile medical supplies might be associated with spore contamination and higher exposure of patients to mucormycosis [62, 63]. As summarized in Tables 1 and 2, most patients had severe COVID-19 pneumonia requiring intensive care, intubation and ventilation. In addition, most patients had underlying diabetes mellitus and received steroids [28, 64, 65]. The presence of diabetes mellitus is a major predisposing factor for mucormycosis as described in a meta-analysis among 600 (70%) of 851 patients with rhino-orbital-cerebral mucormycosis [19]. The presence of diabetes mellitus among patients with COVID-19 was estimated to be 17% in one study [66] and 9% in another study [67]. However, the presence of diabetes mellitus might be higher in other populations and may be more than 50% [4–6]. One meta-analysis showed that diabetes mellitus was associated with an odds ratio (OR) of 2.40 (95% CI 1.98–2.91) for severe disease [68], OR of 1.64 (95% CI 2.30–1.08) in a second meta-analysis [69], and an OR of 2.04, 95% CI 1.67–2.50 in a third meta-analysis [66]. Corticosteroid are currently the only medication that had shown conclusively to be effective in the treatment of COVID-19 in clinical trials therapy [70–72]. The RECOVERY trial utilized dexamethasone at

a dose of 6 mg intravenous or oral once a day for treatment of COVID-19 [73]. Systemic steroids could further exaggerate the underlying glycemic control as well as impede the body's immune system. The use of high dose corticosteroid had been used in patients with COVID-19 disease [74] and the use of such medications required assessment [75]. One study showed that adherence to the use of low dose corticosteroid and good glycemic control were important in having no mucormycosis among 1027 ICU patients despite the use of corticosteroids in 89% and that 40% had diabetes mellitus [76]. The presence of these pre-disposing factors in association with high fungal spore burden in certain localities and communities may set the perfect storm for the development of mucormycosis in patients with COVID-19 patients.

The outcome was favorable for patients who had surgical debridement in three case series [25, 26, 35]. With the ongoing COVID-19 pandemic and increasing number of critically ill patients infected with SARS-CoV-2, it is important to develop a risk-based approach for patients at risk of mucormycosis based on the epidemiological burden of mucormycosis, prevalence of diabetes mellitus, COVID-19 disease severity and use of immune modulating agents including the combined use of steroids and immunosuppressive agents in patients with cancer and transplants. A suggested approach for aspergillosis in COVID-19 was developed [77] and a similar approach is needed for mucormycosis in SARS-CoV-2 infected patients. Whether a mold prophylaxis is required in high-risk patients need further studies.

Early diagnosis of cases of mucormycosis, timely treatment with prescribed drugs and surgical operations, checking glycemic levels and judicious use of corticosteroids in patients with COVID-19 along with adopting appropriate hygienic and sanitization measures would aid in limiting the rising cases of this fungal infection. In-depth studies are required to investigate how COVID-19 is triggering mucormycosis infections in patients and why mainly most cases are being reported from India as compared to other countries amidst second wave of ongoing pandemic.

## Declarations

**Conflict of interest** All authors declare that they have no conflict of interest.

## References


1. Chen N, Zhou M, Dong X, Qu J, Gong F, Han Y, et al. Epidemiological and clinical characteristics of 99 cases of 2019 novel coronavirus pneumonia in Wuhan, China: a descriptive study. *Lancet*. 2020;395:507–13. [https://doi.org/10.1016/S0140-6736\(20\)30211-7](https://doi.org/10.1016/S0140-6736(20)30211-7).

2. Zhou F, Yu T, Du R, Fan G, Liu Y, Liu Z, et al. Clinical course and risk factors for mortality of adult inpatients with COVID-19 in Wuhan, China: a retrospective cohort study. *Lancet*. 2020;6736:1–9. [https://doi.org/10.1016/S0140-6736\(20\)30566-3](https://doi.org/10.1016/S0140-6736(20)30566-3).
3. Nicastrì E, D’Abramo A, Faggioni G, De Santis R, Mariano A, Lepore L, et al. Coronavirus disease (COVID-19) in a paucisymptomatic patient: Epidemiological and clinical challenge in settings with limited community transmission, Italy, February 2020. *Eurosurveillance*. 2020. <https://doi.org/10.2807/1560-7917.ES.2020.25.11.2000230>.
4. Al-Omari A, Alhuqbani WN, Zaidi ARZ, Al-Subaie MF, AlHindi AM, Abogosh AK, et al. Clinical characteristics of non-intensive care unit COVID-19 patients in Saudi Arabia: a descriptive cross-sectional study. *J Infect Public Health*. 2020;13:1639–44. <https://doi.org/10.1016/j.jiph.2020.09.003>.
5. Al Mutair A, Alhumaid S, Alhuqbani WN, Zaidi ARZ, Alkoraisi S, Al-Subaie MF, et al. Clinical, epidemiological, and laboratory characteristics of mild-to-moderate COVID-19 patients in Saudi Arabia: an observational cohort study. *Eur J Med Res*. 2020;25:61. <https://doi.org/10.1186/s40001-020-00462-x>.
6. AlJishi JM, Alhajjaj AH, Alkhabbaz FL, AlAbduljabar TH, Alsaif A, Alsaif H, et al. Clinical characteristics of asymptomatic and symptomatic COVID-19 patients in the Eastern Province of Saudi Arabia. *J Infect Public Health*. 2021;14:6–11. <https://doi.org/10.1016/j.jiph.2020.11.002>.
7. Dhama K, Khan S, Tiwari R, Sircar S, Bhat S, Malik YS, et al. Coronavirus disease 2019–COVID-19. *Clin Microbiol Rev*. 2020;33:1–48. <https://doi.org/10.1128/CMR.00028-20>.
8. Tirupathi R, Muradova V, Shekhar R, Salim SA, Al-Tawfiq JA, Palabindala V. COVID-19 disparity among racial and ethnic minorities in the US: a cross sectional analysis. *Travel Med Infect Dis*. 2020;38:101904. <https://doi.org/10.1016/j.tmaid.2020.101904>.
9. Al-Tawfiq JA, Leonardi R, Fasoli G, Rigamonti D. Prevalence and fatality rates of COVID-19: what are the reasons for the wide variations worldwide? *Travel Med Infect Dis*. 2020;35:101711. <https://doi.org/10.1016/j.tmaid.2020.101711>.
10. Giamarellos-Bourboulis EJ, Netea MG, Rovina N, Akinosoglou K, Antoniadou A, Antonakos N, et al. Complex immune dysregulation in COVID-19 patients with severe respiratory failure. *Cell Host Microbe*. 2020;27:992–1000.e3. <https://doi.org/10.1016/j.chom.2020.04.009>.
11. Guaraldi G, Meschiari M, Cozzi-Lepri A, Milic J, Tonelli R, Menozzi M, et al. Tocilizumab in patients with severe COVID-19: a retrospective cohort study. *Lancet Rheumatol*. 2020;2:e474–84. [https://doi.org/10.1016/S2665-9913\(20\)30173-9](https://doi.org/10.1016/S2665-9913(20)30173-9).
12. Arastehfar A, Carvalho A, van de Veerdonk FL, Jenks JD, Koehler P, Krause R, et al. COVID-19 associated pulmonary aspergillosis (CAPA)—from immunology to treatment. *J Fungi*. 2020;6:1–17. <https://doi.org/10.3390/jof6020091>.
13. Lahmer T, Kriescher S, Herner A, Rothe K, Spinner CD, Schneider J, et al. Invasive pulmonary aspergillosis in critically ill patients with severe COVID-19 pneumonia: results from the prospective AspCOVID-19 study. *PLoS ONE*. 2021. <https://doi.org/10.1371/journal.pone.0238825>.
14. Song G, Liang G, Liu W. Fungal co-infections associated with global COVID-19 pandemic: a clinical and diagnostic perspective from China. *Mycopathologia*. 2020;185:599–606. <https://doi.org/10.1007/s11046-020-00462-9>.
15. Gangneux JP, Bougnoux ME, Dannaoui E, Cornet M, Zahar JR. Invasive fungal diseases during COVID-19: we should be prepared. *J Mycol Med*. 2020. <https://doi.org/10.1016/j.mycmed.2020.100971>.
16. BBC. Black fungus: India reports nearly 9,000 cases of rare infection—BBC News 2021. 2021. <https://www.bbc.com/news/world-asia-india-57217246>. Accessed 28 May 2021.
17. Singh AK, Singh R, Joshi SR, Misra A. Mucormycosis in COVID-19: a systematic review of cases reported worldwide and in India. *Diabetes Metab Syndr Clin Res Rev*. 2021. <https://doi.org/10.1016/j.dsx.2021.05.019>.
18. Biswas S. Mucormycosis: The “black fungus” maiming Covid patients in India—BBC News 2021. 2021. <https://www.bbc.com/news/world-asia-india-57027829>. Accessed 29 May 2021.
19. Jeong W, Keighley C, Wolfe R, Lee WL, Slavin MA, Kong DCM, et al. The epidemiology and clinical manifestations of mucormycosis: a systematic review and meta-analysis of case reports. *Clin Microbiol Infect*. 2019;25:26–34. <https://doi.org/10.1016/j.cmi.2018.07.011>.
20. Chander J, Kaur M, Singla N, Punia RPS, Singhal SK, Attri AK, et al. Mucormycosis: battle with the deadly enemy over a five-year period in India. *J Fungi*. 2018. <https://doi.org/10.3390/jof4020046>.
21. A. Chakrabarti, P. Sood DWD. Estimating fungal infection burden in India using computational models: mucormycosis burden as a case study. *ESCMID*. 2021.
22. Prakash H, Chakrabarti A. Epidemiology of mucormycosis in India. *Microorganisms*. 2021;9:1–12. <https://doi.org/10.3390/microorganisms9030523>.
23. Prakash H, Ghosh AK, Rudramurthy SM, Singh P, Xess I, Savio J, et al. A prospective multicenter study on mucormycosis in India: epidemiology, diagnosis, and treatment. *Med Mycol*. 2019;57:395–402. <https://doi.org/10.1093/mmy/myy060>.
24. Sarkar S, Gokhale T, Choudhury S, Deb A. COVID-19 and orbital mucormycosis. *Indian J Ophthalmol*. 2021;69:1002–4. [https://doi.org/10.4103/ijo.IJO\\_3763\\_20](https://doi.org/10.4103/ijo.IJO_3763_20).
25. Sen M, Lahane S, Lahane TP, Parekh R, Honavar SG. Mucor in a viral land: a tale of two pathogens. *Indian J Ophthalmol*. 2021;69:244–52. [https://doi.org/10.4103/ijo.IJO\\_3774\\_20](https://doi.org/10.4103/ijo.IJO_3774_20).
26. Sharma S, Grover M, Bhargava S, Samdani S, Kataria T. Post coronavirus disease mucormycosis: a deadly addition to the pandemic spectrum. *J Laryngol Otol*. 2021. <https://doi.org/10.1017/S0022215121000992>.
27. Chegini Z, Didehdar M, Khoshbayan A, Rajaeih S, Salehi M, Shariati A. Epidemiology, clinical features, diagnosis and treatment of cerebral mucormycosis in diabetic patients: a systematic review of case reports and case series. *Mycoses*. 2020;63:1264–82. <https://doi.org/10.1111/myc.13187>.
28. Bhatt K, Agolli A, Patel MH, Garimella R, Devi M, Garcia E, et al. High mortality co-infections of COVID-19 patients: mucormycosis and other fungal infections. *Discoveries*. 2021;9:e126. <https://doi.org/10.15190/d.2021.5>.
29. Dyer O. COVID-19: India sees record deaths as “black fungus” spreads fear. *BMJ*. 2021;373:n1238. <https://doi.org/10.1136/bmj.n1238>.
30. Moorthy A, Gaikwad R, Krishna S, Hegde R, Tripathi KK, Kale PG, et al. SARS-CoV-2, uncontrolled diabetes and corticosteroids—an unholy trinity in invasive fungal infections of the maxillofacial region? A retrospective, multi-centric analysis. *J Maxillofac Oral Surg*. 2021. <https://doi.org/10.1007/s12663-021-01532-1>.
31. Garg D, Muthu V, Sehgal IS, Ramachandran R, Kaur H, Bhalla A, et al. Coronavirus disease (Covid-19) associated mucormycosis (CAM): case report and systematic review of literature. *Mycopathologia*. 2021;186:289–98. <https://doi.org/10.1007/s11046-021-00528-2>.
32. Maini A, Tomar G, Khanna D, Kini Y, Mehta H, Bhagyasree V. Sino-orbital mucormycosis in a COVID-19 patient: a case report. *Int J Surg Case Rep*. 2021. <https://doi.org/10.1016/j.ijscr.2021.105957>.
33. Mehta S, Pandey A. Rhino-orbital mucormycosis associated with COVID-19. *Cureus*. 2020. <https://doi.org/10.7759/cureus.10726>.
34. Rao R, Shetty AP, Nagesh CP. Orbital infarction syndrome secondary to rhino-orbital mucormycosis in a case of COVID-19:

- clinico-radiological features. *Indian J Ophthalmol.* 2021;69:1627–30. [https://doi.org/10.4103/ijo.IJO\\_1053\\_21](https://doi.org/10.4103/ijo.IJO_1053_21).
35. Ravani SA, Agrawal GA, Leuva PA, Modi PH, Amin KD. Rise of the phoenix: Mucormycosis in COVID-19 times. *Indian J Ophthalmol.* 2021;69:1563–8. [https://doi.org/10.4103/ijo.IJO\\_310\\_21](https://doi.org/10.4103/ijo.IJO_310_21).
  36. Revannavar SM, Supriya P, Samaga L, Vineeth K. COVID-19 triggering mucormycosis in a susceptible patient: a new phenomenon in the developing world? *BMJ Case Rep.* 2021. <https://doi.org/10.1136/bcr-2021-241663>.
  37. Saldanha M, Reddy R, Vincent MJ. Title of the article: paranasal mucormycosis in COVID-19 patient. *Indian J Otolaryngol Head Neck Surg.* 2021. <https://doi.org/10.1007/s12070-021-02574-0>.
  38. Skiada A, Pavleas I, Drogari-Apiranthitou M. Epidemiology and diagnosis of mucormycosis: an update. *J Fungi.* 2020;6:1–20. <https://doi.org/10.3390/jof6040265>.
  39. Candel FJ, Peñuelas M, Tabares C, Garcia-Vidal C, Matesanz M, Salavert M, et al. Fungal infections following treatment with monoclonal antibodies and other immunomodulatory therapies. *Rev Iberoam Micol.* 2020;37:5–16. <https://doi.org/10.1016/j.riam.2019.09.001>.
  40. Alekseyev K, Didenko L, Chaudhry B. Rhinocerebral mucormycosis and COVID-19 pneumonia. *J Med Cases.* 2021;12:85–9. <https://doi.org/10.14740/jmc3637>.
  41. Bellanger A-P, Navellou J-C, Lepiller Q, Brion A, Brunel A-S, Millon L, et al. Mixed mold infection with *Aspergillus fumigatus* and *Rhizopus microsporus* in a severe acute respiratory syndrome Coronavirus 2 (SARS-CoV-2) patient. *Infect Dis Now.* 2021. <https://doi.org/10.1016/j.idnow.2021.01.010>.
  42. Dallalzadeh LO, Ozzello DJ, Liu CY, Kikkawa DO, Korn BS. Secondary infection with rhino-orbital cerebral mucormycosis associated with COVID-19. *Orbit (London).* 2021. <https://doi.org/10.1080/01676830.2021.1903044>.
  43. Johnson AK, Ghazarian Z, Cendrowski KD, Persichino JG. Pulmonary aspergillosis and mucormycosis in a patient with COVID-19. *Med Mycol Case Rep.* 2021;32:64–7. <https://doi.org/10.1016/j.mmcr.2021.03.006>.
  44. Kanwar A, Jordan A, Olewiler S, Wehberg K, Cortes M, Jackson BR. A fatal case of rhizopus azygosporus pneumonia following covid-19. *J Fungi.* 2021;7:1–6. <https://doi.org/10.3390/jof7030174>.
  45. Karimi-Galougahi M, Arastou S, Haseli S. Fulminant mucormycosis complicating coronavirus disease 2019 (COVID-19). *Int Forum Allergy Rhinol.* 2021. <https://doi.org/10.1002/alar.22785>.
  46. Khatri A, Chang KM, Berlinut I, Wallach F. Mucormycosis after Coronavirus disease 2019 infection in a heart transplant recipient—case report and review of literature. *J Med Mycol.* 2021. <https://doi.org/10.1016/j.mycmed.2021.101125>.
  47. Mekonnen ZK, Ashraf DC, Jankowski T, Grob SR, Vagefi MR, Kersten RC, et al. Acute invasive rhino-orbital mucormycosis in a patient with COVID-19-associated acute respiratory distress syndrome. *Ophthal Plast Reconstr Surg.* 2021;37:E40–2. <https://doi.org/10.1097/IOP.0000000000001889>.
  48. Do Monte ES, Dos Santos MEL, Ribeiro IB, De Oliveira LG, Baba ER, Hirsch BS, et al. Rare and fatal gastrointestinal mucormycosis (Zygomycosis) in a COVID-19 patient: a case report. *Clin Endosc.* 2020;53:746–9. <https://doi.org/10.5946/CE.2020.180>.
  49. Pasero D, Sanna S, Liperi C, Piredda D, Pietro BG, Casadio L, et al. A challenging complication following SARS-CoV-2 infection: a case of pulmonary mucormycosis. *Infection.* 2020. <https://doi.org/10.1007/s15010-020-01561-x>.
  50. Pauli MA, Pereira LM, Monteiro ML, de Camargo AR, Rabelo GD. Painful palatal lesion in a patient with COVID-19. *Oral Surg Oral Med Oral Pathol Oral Radiol.* 2021. <https://doi.org/10.1016/j.oooo.2021.03.010>.
  51. Placik DA, Taylor WL, Wnuk NM. Bronchopleural fistula development in the setting of novel therapies for acute respiratory distress syndrome in SARS-CoV-2 pneumonia. *Radiol Case Rep.* 2020;15:2378–81. <https://doi.org/10.1016/j.radcr.2020.09.026>.
  52. Veisi A, Bagheri A, Eshaghi M, Rikhtehgar MH, Rezaei Kanavi M, Farjad R. Rhino-orbital mucormycosis during steroid therapy in COVID-19 patients: A case report. *Eur J Ophthalmol.* 2021. <https://doi.org/10.1177/11206721211009450>.
  53. Waizel-Haiat S, Guerrero-Paz JA, Sanchez-Hurtado L, Calleja-Alarcon S, Romero-Gutierrez L. A case of fatal rhino-orbital mucormycosis associated with new onset diabetic ketoacidosis and COVID-19. *Cureus.* 2021. <https://doi.org/10.7759/cureus.13163>.
  54. Werthman-Ehrenreich A. Mucormycosis with orbital compartment syndrome in a patient with COVID-19. *Am J Emerg Med.* 2021;42:264.e5-264.e8. <https://doi.org/10.1016/j.ajem.2020.09.032>.
  55. Zurl C, Hoenigl M, Schulz E, Hatzl S, Gorkiewicz G, Krause R, et al. Autopsy proven pulmonary mucormycosis due to *Rhizopus microsporus* in a critically ill COVID-19 patient with underlying hematological malignancy. *J Fungi.* 2021;7:1–4. <https://doi.org/10.3390/jof7020088>.
  56. Hanley B, Naresh KN, Roufousse C, Nicholson AG, Weir J, Cooke GS, et al. Histopathological findings and viral tropism in UK patients with severe acute COVID-19: a post-mortem study. *Lancet Microbe.* 2020;1:e245–53. [https://doi.org/10.1016/S2666-5247\(20\)30115-4](https://doi.org/10.1016/S2666-5247(20)30115-4).
  57. Cornely OA, Alastruey-Izquierdo A, Arenz D, Chen SCA, Dannaoui E, Hochhegger B, et al. Global guideline for the diagnosis and management of mucormycosis: an initiative of the European Confederation of Medical Mycology in cooperation with the Mycoses Study Group Education and Research Consortium. *Lancet Infect Dis.* 2019;19:e405–21. [https://doi.org/10.1016/S1473-3099\(19\)30312-3](https://doi.org/10.1016/S1473-3099(19)30312-3).
  58. Al-Obaidi M, Youssefi B, Bardwell J, Bouzigard R, Le CH, Zangeneh TT. A comparative analysis of mucormycosis in immunosuppressed hosts including patients with uncontrolled diabetes in the Southwest United States. *Am J Med.* 2021. <https://doi.org/10.1016/j.amjmed.2021.04.008>.
  59. Bellazreg F, Hattab Z, Meksi S, Mansouri S, Hachfi W, Kaabia N, et al. Outcome of mucormycosis after treatment: report of five cases. *New Microbes New Infect.* 2015;6:49–52. <https://doi.org/10.1016/j.nmni.2014.12.002>.
  60. Camara-Lemarroy CR, González-Moreno EI, Rodríguez-Gutiérrez R, Rendón-Ramírez EJ, Ayala-Cortés AS, Fraga-Hernández ML, et al. Clinical features and outcome of mucormycosis. *Interdiscip Perspect Infect Dis.* 2014. <https://doi.org/10.1155/2014/562610>.
  61. Szarpak L. Mucormycosis - a serious threat in the COVID-19 pandemic? *J Infect.* 2021. <https://doi.org/10.1016/j.jinf.2021.05.015>.
  62. Hartnett KP, Jackson BR, Perkins KM, Glowicz J, Kerins JL, Black SR, et al. A guide to investigating suspected outbreaks of mucormycosis in healthcare. *J Fungi.* 2019;5:69. <https://doi.org/10.3390/jof5030069>.
  63. Alsuwaida K. Primary cutaneous mucormycosis complicating the use of adhesive tape to secure the endotracheal tube. *Can J Anesth.* 2002;49:880–2. <https://doi.org/10.1007/BF03017426>.
  64. John TM, Jacob CN, Kontoyiannis DP. When uncontrolled diabetes mellitus and severe covid-19 converge: the perfect storm for mucormycosis. *J Fungi.* 2021. <https://doi.org/10.3390/jof7040298>.
  65. Verma DK, Bali RK. COVID-19 and mucormycosis of the craniofacial skeleton: causal, contributory or coincidental? *J*

- Maxillofac Oral Surg. 2021;20:165–6. <https://doi.org/10.1007/s12663-021-01547-8>.
66. Giri M, Puri A, Wang T, Guo S. Comparison of clinical manifestations, pre-existing comorbidities, complications and treatment modalities in severe and non-severe COVID-19 patients: a systematic review and meta-analysis. *Sci Prog.* 2021. <https://doi.org/10.1177/00368504211000906>.
  67. Yin T, Li Y, Ying Y, Luo Z. Prevalence of comorbidity in Chinese patients with COVID-19: systematic review and meta-analysis of risk factors. *BMC Infect Dis.* 2021. <https://doi.org/10.1186/s12879-021-05915-0>.
  68. Li X, Zhong X, Wang Y, Zeng X, Luo T, Liu Q. Clinical determinants of the severity of COVID-19: A systematic review and meta-analysis. *PLoS ONE.* 2021. <https://doi.org/10.1371/journal.pone.0250602>.
  69. Cheng S, Zhao Y, Wang F, Chen Y, Kaminga AC, Xu H. Comorbidities' potential impacts on severe and non-severe patients with COVID-19: A systematic review and meta-analysis. *Medicine (Baltimore).* 2021;100:e24971. <https://doi.org/10.1097/MD.00000000000024971>.
  70. Zhang W, Zhao Y, Zhang F, Wang Q, Li T, Liu Z, et al. The use of anti-inflammatory drugs in the treatment of people with severe coronavirus disease 2019 (COVID-19): the experience of clinical immunologists from China. *Clin Immunol.* 2020. <https://doi.org/10.1016/j.clim.2020.108393>.
  71. McCreary EK, Coronavirus PJM, Disease, . Treatment: a review of early and emerging options. *Open Forum Infect Dis.* 2019;2020:7. <https://doi.org/10.1093/ofid/ofaa105>.
  72. Russell CD, Millar JE, Baillie JK. Clinical evidence does not support corticosteroid treatment for 2019-nCoV lung injury. *Lancet.* 2020;395:473–5. [https://doi.org/10.1016/S0140-6736\(20\)30317-2](https://doi.org/10.1016/S0140-6736(20)30317-2).
  73. RECOVERY Collaborative Group. Dexamethasone in hospitalized patients with COVID-19—preliminary report. *N Engl J Med.* 2020. <https://doi.org/10.1056/nejmoa2021436>.
  74. AlBahrani S, Al-Tawfiq JA, Jebakumar AZ, Alghamdi M, Zakary N, Seria M, et al. Clinical features and outcome of low and high corticosteroids in admitted COVID-19 patients. *J Epidemiol Glob Health.* 2021. <https://doi.org/10.2991/jegh.k.210521.001>.
  75. Rodriguez-Morales AJ, Sah R, Millan-Oñate J, Gonzalez A, Montenegro-Idrogo JJ, Scherger S, et al. COVID-19 associated mucormycosis: the urgent need to reconsider the indiscriminate use of immunosuppressive drugs. *Ther Adv Infect Dis.* 2021. <https://doi.org/10.1177/20499361211027065>.
  76. Mulakavalupil B, Vaity C, Joshi S, Misra A, Pandit RA. Absence of Case of Mucormycosis (March 2020–May 2021) under strict protocol driven management care in a COVID-19 specific tertiary care intensive care unit. *Diabetes Metab Syndr Clin Res Rev.* 2021;15:102169. <https://doi.org/10.1016/j.dsx.2021.06.006>.
  77. Koehler P, Bassetti M, Chakrabarti A, Chen SCA, Colombo AL, Hoenigl M, et al. Defining and managing COVID-19-associated pulmonary aspergillosis: the 2020 ECMM/ISHAM consensus criteria for research and clinical guidance. *Lancet Infect Dis.* 2021. [https://doi.org/10.1016/S1473-3099\(20\)30847-1](https://doi.org/10.1016/S1473-3099(20)30847-1).
  78. Pakdel F, Ahmadikia K, Salehi M, Tabari A, Jafari R, Mehrparvar G, et al. Mucormycosis in patients with COVID-19: a cross-sectional descriptive multicenter study from Iran. *Mycoses.* 2021. <https://doi.org/10.1111/myc.13334>.
  79. Singh RP, Gupta N, Kaur T, Gupta A. Rare case of gastrointestinal mucormycosis with colonic perforation in an immunocompetent patient with COVID-19. *BMJ Case Rep.* 2021;14:e244096. <https://doi.org/10.1136/bcr-2021-244096>.
  80. Arjun R, Felix V, Niyas VKM, Kumar MAS, Krishnan RB, Mohan V, et al. COVID-19 associated rhino-orbital mucormycosis: a single centre experience of ten cases. *QJM An Int J Med.* 2021. <https://doi.org/10.1093/qjmed/hcab176>.
  81. Saidha PK, Kapoor S, Das P, Gupta A, Kakkar V, Kumar A, et al. Mucormycosis of paranasal sinuses of odontogenic origin post COVID19 infection: a case series. *Indian J Otolaryngol Head Neck Surg.* 2021. <https://doi.org/10.1007/s12070-021-02638-1>.
  82. Jain M, Tyagi R, Tyagi R, Jain G. Post-COVID-19 gastrointestinal invasive mucormycosis. *Indian J Surg.* 2021. <https://doi.org/10.1007/s12262-021-03007-6>.
  83. Baskar HC, Chandran A, Reddy CS, Singh S. Rhino-orbital mucormycosis in a COVID-19 patient. *BMJ Case Rep.* 2021;14:e244232. <https://doi.org/10.1136/bcr-2021-244232>.
  84. Patankar SH, Joshi AR, Muthe MM, Athawale A, Achhapalia Y. CT and MRI findings of invasive mucormycosis in the setting of COVID-19: experience from a single center in India. *Am J Roentgenol.* 2021. <https://doi.org/10.2214/AJR.21.26205>.
  85. Sen M, Honavar SG, Bansal R, Sengupta S, Rao R, Kim U, et al. Epidemiology, clinical profile, management, and outcome of COVID-19-associated rhino-orbital-cerebral mucormycosis in 2826 patients in India - Collaborative OPAI-IJO Study on Mucormycosis in COVID-19 (COSMIC), Report 1. *Indian J Ophthalmol.* 2021;69:1670–92. [https://doi.org/10.4103/ijo.IJO\\_1565\\_21](https://doi.org/10.4103/ijo.IJO_1565_21).

## Authors and Affiliations

Jaffar A. Al-Tawfiq<sup>1,2,3,21</sup>  · Saad Alhumaid<sup>4</sup> · Abeer N. Alshukairi<sup>5</sup> · Mohamad-Hani Tamsah<sup>6</sup> · Mazin Barry<sup>7</sup> · Abbas Al Mutairi<sup>8,9,10</sup> · Ali A. Rabaan<sup>11</sup> · Awadh Al-Omari<sup>12,13</sup> · Raghavendra Tirupathi<sup>14,20</sup> · Manaf AlQahtani<sup>15,16,17</sup> · Salma AlBahrani<sup>18</sup> · Kuldeep Dhama<sup>19</sup>

<sup>1</sup> Infectious Disease Unit, Specialty Internal Medicine, Johns Hopkins Aramco Healthcare, Dhahran, Saudi Arabia

<sup>2</sup> Infectious Diseases Division, Department of Medicine, Indiana University School of Medicine, Indianapolis, IN, USA

<sup>3</sup> Infectious Diseases Division, Department of Medicine, Johns Hopkins University School of Medicine, Baltimore, MD, USA

<sup>4</sup> Administration of Pharmaceutical Care, Alahsa Health Cluster, Ministry of Health, Alahsa, Saudi Arabia

<sup>5</sup> Department of Medicine, King Faisal Specialist Hospital and Research Center, Jeddah, Saudi Arabia

<sup>6</sup> Pediatric Department, College of Medicine, King Saud University, Riyadh, Saudi Arabia

<sup>7</sup> Division of Infectious Diseases, Department of Internal Medicine, College of Medicine, King Saud University and King Saud University Medical City, Riyadh, Saudi Arabia

<sup>8</sup> Research Center, Almoosa Specialist Hospital, Alahsa, Saudi Arabia

- <sup>9</sup> School of Nursing, Wollongong University, Wollongong, Australia
- <sup>10</sup> College of Nursing, Princess Norah Bint Abdul Rahman University, Riyadh, Saudi Arabia
- <sup>11</sup> Molecular Diagnostics Laboratory, Johns Hopkins Aramco Healthcare, Dhahran, Saudi Arabia
- <sup>12</sup> College of Medicine, Alfaisal University, Riyadh, Saudi Arabia
- <sup>13</sup> Research Center, Dr. Sulaiman Al Habib Medical Group, Riyadh, Saudi Arabia
- <sup>14</sup> Department of Medicine Keystone Health, Penn State University School of Medicine, Hershey, PA, USA
- <sup>15</sup> National Taskforce for Combating the Corona Virus, Riffa, Bahrain
- <sup>16</sup> Royal College of Surgeons in Ireland-Bahrain, Muharraq, Bahrain
- <sup>17</sup> Internal Medicine, Infectious Diseases and Clinical Microbiology, Bahrain Defense Force Hospital, Riffa, Bahrain
- <sup>18</sup> King Fahad Military Medical Complex, Dhahran, Saudi Arabia
- <sup>19</sup> Division of Pathology, ICAR-Indian Veterinary Research Institute, Izatnagar, Bareilly, Uttar Pradesh, India
- <sup>20</sup> Department of Medicine, Wellspan Chambersburg and Waynesboro Hospitals, Chambersburg, PA, USA
- <sup>21</sup> Dhahran Health Center, Johns Hopkins Aramco Healthcare, Rm A-420, Building 61, P.O. Box 76, Dhahran 31311, Saudi Arabia