

Stereoscopy in Dental Education: An Investigation

Shumei Murakami, PhD, DDS; Rinus G. Verdonschot, PhD; Sven Kreiborg, PhD, DDS; Naoya Kakimoto, PhD, DDS; Asuka Kawaguchi, DDS

Abstract: The aim of this study was to investigate whether stereoscopy can play a meaningful role in dental education. The study used an anaglyph technique in which two images were presented separately to the left and right eyes (using red/cyan filters), which, combined in the brain, give enhanced depth perception. A positional judgment task was performed to assess whether the use of stereoscopy would enhance depth perception among dental students at Osaka University in Japan. Subsequently, the optimum angle was evaluated to obtain maximum ability to discriminate among complex anatomical structures. Finally, students completed a questionnaire on a range of matters concerning their experience with stereoscopic images including their views on using stereoscopy in their future careers. The results showed that the students who used stereoscopy were better able than students who did not to appreciate spatial relationships between structures when judging relative positions. The maximum ability to discriminate among complex anatomical structures was between 2 and 6 degrees. The students' overall experience with the technique was positive, and although most did not have a clear vision for stereoscopy in their own practice, they did recognize its merits for education. These results suggest that using stereoscopic images in dental education can be quite valuable as stereoscopy greatly helped these students' understanding of the spatial relationships in complex anatomical structures.

Dr. Murakami is Associate Professor, Department of Oral and Maxillofacial Radiology, Osaka University Graduate School of Dentistry, Suita, Osaka, Japan; Dr. Verdonschot is Research Fellow, Department of Oral and Maxillofacial Radiology, Osaka University Graduate School of Dentistry, Suita, Osaka, Japan; Dr. Kreiborg is Professor, 3D Craniofacial Image Research Laboratory, University of Copenhagen, Copenhagen, Denmark; Dr. Kakimoto is Associate Professor, Department of Oral and Maxillofacial Radiology, Osaka University Graduate School of Dentistry, Suita, Osaka, Japan; and Dr. Kawaguchi is a postgraduate student, Department of Prosthodontics, Osaka University Graduate School of Dentistry, Suita, Osaka, Japan. Direct correspondence to Dr. Rinus G. Verdonschot, Department of Oral and Maxillofacial Radiology, Osaka University, Graduate School of Dentistry, Yamadaoka, Suita, Osaka 565-0871, Japan; +81 (0)6-6879-5111; rinusverdonschot@gmail.com.

Keywords: dental education, oral and maxillofacial radiology, radiograph, anaglyph, stereoscopy

*Submitted for publication 8/1/16; accepted 9/16/16
doi: 10.21815/JDE.016.002*

For dental students, acquisition of clinical competence is one of the most important factors of their education. One crucial and difficult part in attaining this expertise is a thorough understanding of the anatomy and especially the spatial relationships among structures in the oral and maxillofacial region. This region has a complex structure containing various kinds of hard tissues, which readily allow for two-dimensional (2D) or three-dimensional (3D) diagnostic imaging using CT/MRI, so the use of these images in educational settings is widespread. However, genuine depth information—which is, for instance, available in 3D plaster models in the form of stereopsis—is typically lacking. In other words, the awareness of depth that originates from differences in patterns of light projected on the retinas for both eyes is not available. This absence occasionally hampers students' detailed understanding when trying to comprehend difficult 3D relationships among complex structures in the oral and maxillofacial region.

The aim of this study was to assess the potential use of stereoscopy in dental education by evaluating

the practical use of anaglyph images. We assessed whether these images were readily applicable and may have particular educational benefits over standard 2D or non-stereoscopic 3D images since students can observe these structures in a visually similar way to a genuine anatomical situation. After describing the anaglyph technique using CT data, we will describe the study and its results.

The Anaglyph Technique

Although there are other, more sophisticated, and typically more complicated and expensive techniques to show 3D images, the anaglyph technique is inexpensive and easy to understand. The stereoscopic effect is achieved by allowing different images to reach each eye using filters of different colors (usually red and cyan). For instance, in Figure 1 one can see two images on the screen (red and cyan cylinders). The anaglyph glasses have a red (left) and cyan (right) filter; this allows the red image to be seen

only by the right eye (as the red filter blocks red for the left eye) and vice versa for the blue image. Upon viewing these images, the brain will start to integrate both images and merge them into a 3D view. One can change the specific characteristics of the stereoscopic 3D effect by manipulating the angle between the differently colored images. In this case, the resultant state is that the person viewing this anaglyph image would perceive the cylinder as “floating” in front of the screen to a particular degree that depends on the angle of rotation between the red and cyan images.

Anaglyph Images Outside Dental Education

Stereoscopic images have already been shown to benefit education in academic fields in which depth perception and depth relations between structures play a role. For instance, in teaching earth science to university students, one study found that it was easier for students to read and work with stereoscopic (i.e., anaglyph) contour maps than non-stereoscopic maps and that students’ accuracy on problems relating to map geometry increased significantly.¹ In chemistry education, in which it is often necessary to understand intricate 3D arrangements of molecular structures, stereopsis has been shown to play a beneficial educational role.² Likewise, in engineering courses, such as architectural courses, stereoscopic visualization has been found to help students understand principles of architectural design, which could lead, for instance, to better detection of design flaws in structures.³

In medical education, one study suggested that stereoscopic displays could play a vital role in enhancing the understanding of complex spatial relationships and, additionally, that stereopsis might increase the skills desirable for successful application of surgical techniques.⁴ Stereoscopy in medical education could be particularly useful for developing students’ understanding concerning spatial relationships between anatomical structures in the body. For instance, Luursema et al. found that computer-implemented stereopsis during a learning phase resulted in significantly higher accuracy on a subsequent anatomical localization task.⁵ Likewise, Ferdig et al. investigated whether stereoscopy could play a useful role as an instructional method in teaching anatomy to students.⁶ In that study, part of the curriculum included instruction about brain anatomy as well as general anatomy. For the brain anatomy classes, which had only one exam at the end of the instruction period, students were divided into two

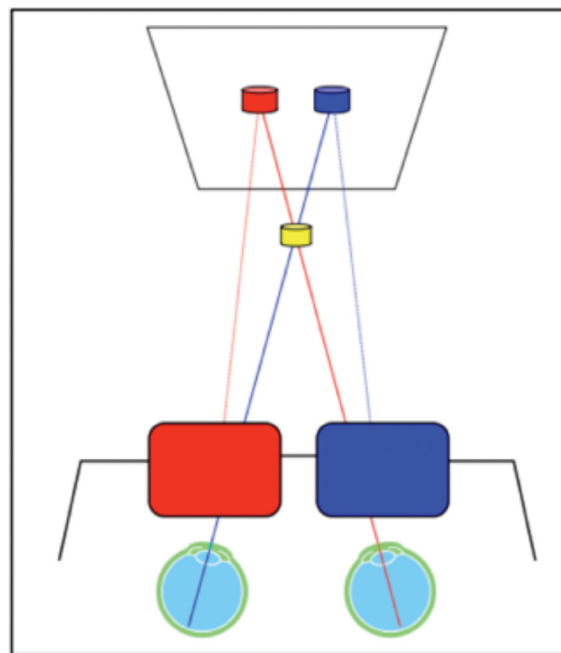


Figure 1. Principle behind the anaglyph technique

groups presented with anatomical images (CT/MRI), either in traditional 2D format (non-3D group) or in stereoscopic 3D (3D group). For the general anatomy classes, which had two exams (first halfway through the classes, second at the end), the procedure was the same, but groups were reversed after the first exam (i.e., the non-3D group became the 3D group and vice versa). Both the brain anatomy and the first general anatomy exam results showed that students in the stereoscopic 3D groups performed better than their peers in the non-3D groups. However, unexpectedly, for the second general anatomy exam, the non-3D group scored 10% higher than on the previous exam they took (i.e., when instructed using stereoscopic 3D). This may perhaps have been due to this group’s students’ having pre-existing study abilities and knowledge or that some specific anatomical materials do not benefit from stereoscopic presentation.

Anaglyph Images in Dental Education

In dental curricula, students have to learn and understand complex anatomy and be aware of a variety of disorders involving the oral and maxillofacial region (e.g., ectopic eruption of teeth fractures of jaws and teeth, tumor growth, developmental

defects, and periodontal disease). The first step in learning how to treat pathology is to learn to assess the underlying cause in order to make an accurate diagnosis and treatment plan. In many cases, this process involves examining CT and/or MR images to evaluate the state and location of the underlying physical structures and pathology. Instead of looking at 2D slices, developments in volumetric imaging have made it possible to show 3D rendered images on 2D monitors, which allows for enhanced anatomical discrimination of particular regions/boundaries of specific pathologies.

Although the use of 3D rendered images is a great leap forward, it still does not convey the genuine depth information that we experience in daily life, such as the information arising from stereopsis (two slightly different images projected to the retina of each eye). This perception could be challenging when structures of interest are overlapping or intermingled with one another. To the extent of our knowledge, it seems that only very few academic dental institutions make use of stereoscopic images in their curricula.

There seem to be no practical reasons why the use of anaglyph images in dental education could not be implemented. For instance, most medical images displayed on printouts or monitors can be shown stereoscopically. Additionally, classroom lectures in dental education are typically held in rooms equipped with beamers that are able to display full-color images. Paper framed anaglyph glasses are inexpensive (<0.50 USD) and could even be made on the fly if necessary using transparent colored plastic. Importantly, the construction of the anaglyph images themselves is also quite straightforward. The construction of anaglyph images involves the following five steps: 1) obtain CT scans of the anatomical structure of interest; 2) perform a 3D rendering of the scans using the software provided by the CT scanner; 3) rotate the 3D image to a certain desired angle (e.g., 2-6 degrees) to the right to obtain the right eye image; 4) rotate the 3D image a certain angle (e.g., 2-6 degrees) to the left to obtain the left eye image; and 5) merge these images together into an anaglyph using specialized software (e.g., Anaglyph Workshop by Sandy Knoll Software; tabberer.com/sandyknoll/more/3dmaker/anaglyph-software.html).

Materials and Methods

For all three experiments conducted in this study, we obtained approval from the Ethics Com-

mittee at Osaka University Graduate School of Dentistry (protocol nr: H21-E16). As the use of anaglyph images in dental education should not be hampered due to practical reasons, this study assessed whether stereoscopic images might play a useful role in dental education. In Experiment 1, we investigated whether stereoscopic images enhanced students' ability to detect spatial relationships between objects in a 3D rendering. We assessed that by placing globes of different sizes at particular positions in a 3D image and asking students to judge their relative positions. In Experiment 2, we investigated which rotational angle best delivered a stereoscopic view in a scene involving an anatomical image of the oral and maxillofacial region. In Experiment 3, we conducted a survey of students' opinions concerning the use and feasibility of anaglyphs in dental practice.

Experiment 1

To assess whether stereoscopic images could enhance the students' ability to detect the position of particular 3D objects, we devised a simple classroom experiment in which students had to assess the position of three globes presented on a screen. The images were shown both stereoscopically with students wearing anaglyph glasses and in non-stereoscopic 3D. The globes had either equal or different sizes and occupied one of three positions. We opted for this simple test as it did not involve anatomical structures for which differential proficiency levels among students could influence judgments, as assessed by Ferdig et al.⁶

In total, 50 dental students at Osaka University (27 females and 23 males with an average age of 22.7 ± 0.8 years) were tested. Out of these students, 84% wore a visual aid (contact lenses or glasses). We created six sequences (F=farthest, M=middle, C=closest) for equal and unequal sized globes separately (12 sequences in total). We changed the position of the globes using 3D software (Shade 3D v.14, Mirye Software; mirye.net/shade-3d). These sequences were administered separately with and without anaglyph glasses totaling 24 trials. Figure 2 shows the four separate conditions for an example sequence (e.g., closest-farthest-middle; CFM). Students had to judge which globe was closest or farthest away and which one was in the middle.

Experiments 2 and 3

The stereoscopic effect exists in a rather limited disparity range, meaning that if the angle




Figure 2. All versions of closest, farthest, middle sequence: equal and unequal globe size and with and without stereoscopy

Note: Each sequence was presented separately.

between the two images forming the anaglyph image transcends certain boundaries, the stereoscopic effect diminishes until it disappears. This is particularly evident when viewing increasingly complex structures. Therefore, in the second experiment we asked dental students to evaluate which rotational angle was optimal when conveying stereoscopic anatomical images of the OMR.

In total, 57 dental students of Osaka University from the same population as in Experiment 1 were tested. The interpupillary distance (M) was measured for each student who participated in this test. Students were found to be in the typical range ($M=60.3\pm 3.7$ mm) and therefore should be able to judge this metric effectively.

We created stereoscopic anatomical images of the oral and maxillofacial region at different rotational degrees (1-20 degrees in one degree steps) at three sizes (full screen, half screen, quarter screen size) reflecting the different image sizes typically found on CT imaging systems (Figure 3). Students were tested individually. Images were shown in a ran-

dom order for degree but blocked for size. For each image, students had to choose which of the following options suited the image best: very well conveyed, fairly well conveyed, not very well conveyed, not conveyed at all. For Experiment 3, the same students who took part in the positional judgment experiment (Experiment 1) participated in the survey, except for two students who opted out (leaving $N=48$).

Results

Experiment 1

In this part of the study, stereoscopy had a positive effect, showing fewer errors than without stereoscopy (Table 1). A mixed-logit analysis showed that students were more accurate in determining the correct sequence when they used the anaglyph glasses, $z(1200)=2.3$, $SE=0.28$, $p<0.05$.⁷ Also, the globe size showed an effect (with unequally sized globes being more difficult), $z(1200)=10.4$, $SE=0.22$,

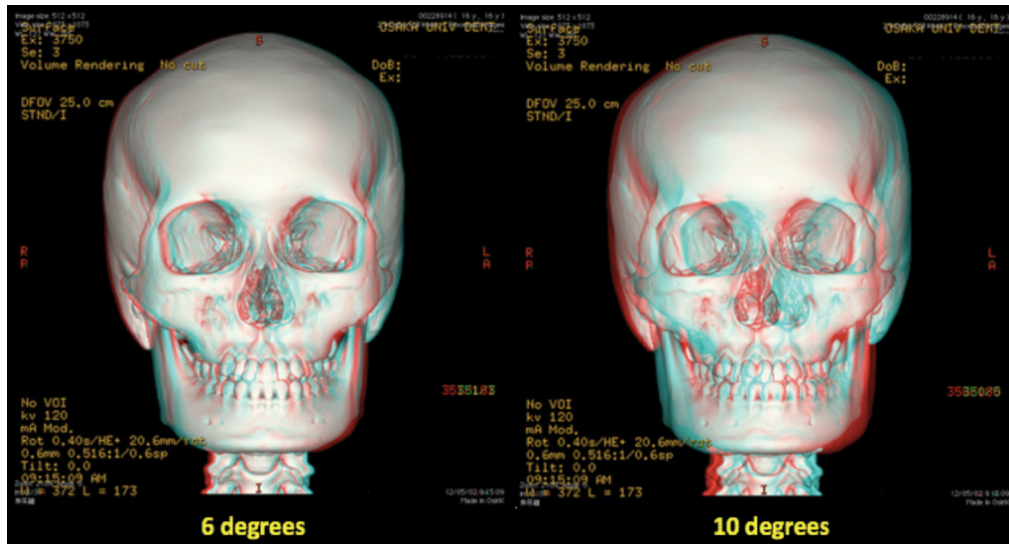


Figure 3. Two full-screen oral and maxillofacial radiology images with varying rotational degrees (six and ten degrees)

Note: Images were presented separately.

$p < 0.001$, but there was no interaction between the two, $z(1200) = 0.2$, $SE = 0.31$, $p = 0.9$.

The experiment showed that, on a simple positional judgment task, stereoscopy had a positive influence. Students were better able to see the spatial relationships between globes, and this effect was most pronounced for the differently sized globes. Not unexpectedly, it seems that stereoscopy had a beneficial effect in judging relative positions between 3D structures presented in 2D. These sorts

of judgments are quite important and abundant when understanding spatial relationships in complex anatomical structures in the human body (such as the oral and maxillofacial region).

The next step was to apply stereoscopy to anatomical images, which can be used in dental curricula. However, as these structures are significantly more complex than simple globes, it is important to assess the optimal degree of rotation to obtain the greatest ability to discriminate between individual structures when creating these types of images. This metric was investigated in the next experiment.

Table 1. Correct responses for various sequences: C=closest, F=farthest, M=middle

Size Ball	Sequence	Non-Stereoscopic 3D Correct	Stereoscopic 3D Correct
Different	FMC	0	4
Different	FCM	0	5
Different	MFC	0	7
Different	MCF	2	10
Different	CFM	1	12
Different	CMF	42	40
Equal	FMC	36	32
Equal	FCM	30	32
Equal	MFC	26	37
Equal	MCF	36	29
Equal	CFM	34	40
Equal	CMF	15	46

Experiment 2

For each image, we calculated how many subjects (out of 57) chose each of the options. This number was then amplified by a multiplication factor—3 for very well conveyed, 2 for fairly well conveyed, and 1 for not well conveyed—to obtain the total score for that image size and degree. The number for not conveyed at all did not contribute to the score (it was multiplied by 0). For instance, for “full screen/1 degree rotation” the total score was 97 (obtained by $14 \times 3 + 23 \times 2 + 9 \times 1 + 11 \times 0$). See Figure 4 for the total scores per degree for each image size.

We found that the overall perceived stereoscopic effect was not identical for each image size. A Friedman rank sign test, $\chi(2) = 19.1$, $p < 0.001$, showed

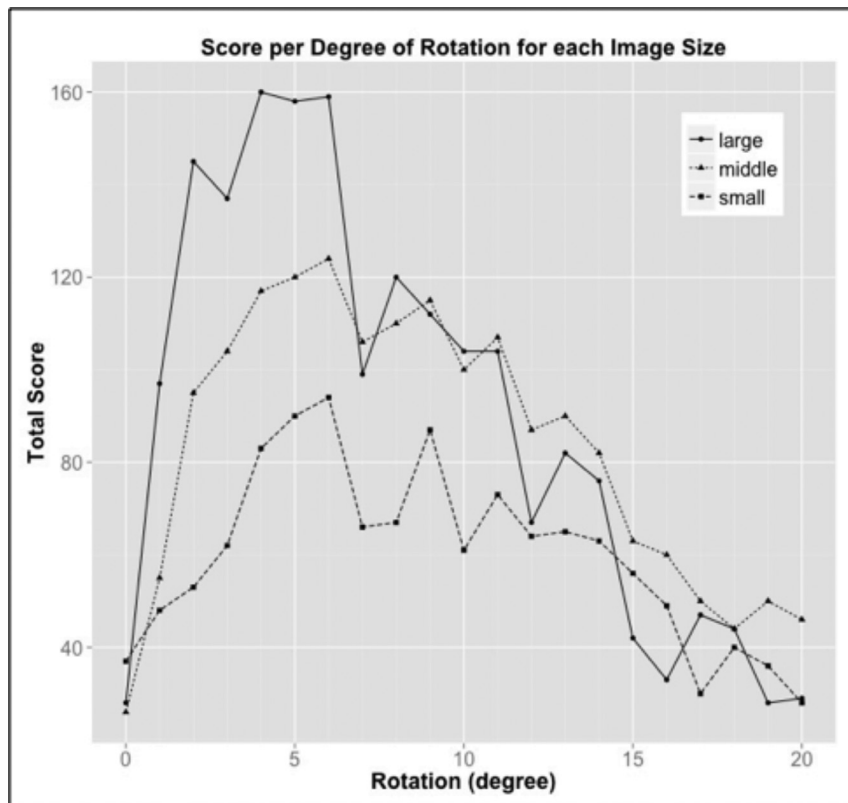


Figure 4. Students’ 3D depth conveyance scores concerning stereoscopic anatomical images

Note: Rotational angle was 1-20 degrees, for three image sizes: full, half, quarter.

that larger image sizes elicited stronger stereoscopic effects (full > half > quarter). Importantly, for constructing images to be used in dental education, we found that the depth of the stereoscopic image was perceived as “best conveyed” (i.e., highest overall scores) when the degree of rotation was between 2 and 6 degrees (Figure 4). When creating stereoscopic images to be used in dental education, we recommend using a rotational angle between 2 and 6 degrees to obtain the highest stereoscopic effect. In other words, when viewing a 3D structure, such as the oral and maxillofacial region, this specific range provided the optimal ability to discriminate between anatomical structures and hence is appropriate for use in an educational setting.

Experiment 3

It was also important to assess the students’ opinions on how they actually experienced the use of stereoscopic images and whether they would consider

using those images in their future clinical practice. Table 2 shows the students’ average responses on the survey questions. Most students (98%) reported that they were able to clearly see the 3D effect elicited by the stereoscopic images through the anaglyph glasses. The use of stereoscopic images was reported to be beneficial for perceiving and understanding complex structures as well as enhancing clinical diagnoses in particular cases.

Also, the students reported that they considered the use of stereoscopic images to be beneficial for their dental education and clinical practice (score: 4.0 on a 1-7 scale) as well as potentially informing patients about their condition. However, most students said they did not feel comfortable wearing the glasses (possibly implying that they may not feel comfortable being seen wearing them) and seemed uncertain (score: 3.3, leaning towards “disagree”) whether they would really use anaglyph images and glasses after graduation. Although speculative, this latter result might indicate the students’ perception

Table 2. Mean responses to survey questions

Question	Result (SD)
1. Have you used 3D anaglyph glasses before? (Yes/No)	98%/2%
2. If so, how many times?	10.1 (15.7)
3. Are you able to see 3D images clearly using 3D anaglyph glasses? (Yes/No)	94%/6%
4. Do you feel comfortable wearing 3D anaglyph glasses? ^a	2.8 (0.9)
5. Do you think that presenting information using 3D glasses (anaglyph) helps you perceive and understand complex structures better? ^a	4.1 (0.6)
6. Do you think you are able to make better clinical diagnoses in certain cases using 3D glasses (anaglyph) compared to normal diagnosis methods? ^a	4.0 (0.7)
7. Do you think that the use of 3D glasses (anaglyph) may impair clinical diagnosis (i.e., make it more difficult)? ^a	2.7 (0.7)
8. Would you consider using 3D glasses (anaglyph) and 3D images after you graduate and start working as a dentist or radiologist? ^a	3.3 (0.7)
9. Do you think anaglyph glasses could be beneficial for dental education or clinical practice? (Yes/No)	100%/0
10. If so, which area you think they are most suitable for? ^b	4.0 (1.2)
11. Do you think anaglyph glasses could be used for patient education—for example, to help them understand their disease better? ^a	4.1 (1.0)
12. Do you feel comfortable if other people see you wearing anaglyph glasses during medical diagnosis? ^a	3.2 (0.9)

^aResponse options were 5=strongly agree, 4=agree, 3=neither agree or disagree, 2=disagree, and 1=strongly disagree.

^bResponse options were on a seven-point scale from 1=education to 7=clinical.

SD=standard deviation

that, in daily clinical practice through their extensive training, anaglyph glasses might provide no real benefit over the knowledge of an experienced practitioner despite Experiment 1 showing a benefit for stereoscopic images.

Discussion

This study asked whether the use of stereoscopic images constituted an opportunity to augment existing teaching methods in dental education to study complex anatomical structures. After having established that there were no practical hurdles to using anaglyph glasses as well as constructing the required stereoscopic images, we assessed whether the use of stereoscopy enhanced students' depth perception. We found that their performance on a simple positional judgment task was improved when using stereoscopy. Subsequently, we evaluated the optimum angle to obtain maximum stereoscopic ability to discriminate among anatomical images typically occurring in dental education. According to these 57 students, the optimum angle was between 2 and 6 degrees irrespective of size of image on screen. Finally, we assessed students' opinion on a variety of matters related concerning their experience with

stereoscopic images as well as their reflections on using them for their future clinical practice.

The students' general experience with the stereoscopic anaglyph technique was positive and potentially beneficial for understanding complex 3D anatomical structures. However, most students did not seem comfortable (being seen) wearing the glasses and were neither really positive nor negative on using anaglyph images in their future practice, although most students judged the technique may have merit when explaining particular (anatomical) details to patients in order to understand their illness better.

One limitation regarding our findings is that the positional judgment task may have been too simple to warrant any conclusion concerning the role stereoscopy could play in the dental curriculum. However, as our current aim was to determine whether spatial discrimination would be enhanced for these students when using stereoscopic images, we do think that it is valuable to have used an unbiased task with respect to students' anatomical knowledge. Ferdig et al. found that the non-3D trained group outperformed the trained 3D group on their final general anatomy test, which could have been due to pre-existing group differences or because not all anatomic topics equally benefit from stereoscopic presentation.⁶ Furthermore, it seems problematic to

judge any particular anatomical spatial relationship without bias in successive presentations (once with and once without stereoscopy) to a similar extent as the positional judgment task using globes does. Nevertheless, a novel problem set, preferably using clinical case pathology suitable for the dental curriculum, in which stereoscopy is assumed to play a beneficial role, should be developed to strengthen our conclusions and we aim to undertake this task in the near future.

We have been using stereoscopic images for many years in our dental curriculum to enhance our students' understanding of the basic anatomy of the craniofacial bones and the pathologic conditions that occur in the craniofacial region. In basic anatomy classes, we usually find that students greatly benefit from stereoscopy when trying to understand the relationship between the hyoid bone and the other bones (as the hyoid bone is separated). Similarly, students report anecdotally that their understanding of the location of salivary stones (which are also separated) benefits from stereoscopic presentation. However, these benefits do not hold for other, easier to understand, anatomical relationships, such as between the nasal bone and the zygoma. We also use stereoscopic images when we teach students about mandibular fractures, a well-known fracture site. If the fracture occurs at the condylar neck, small fragments can be pulled toward to the anterior, medial, and inferior directions because of the muscle tension. Although students are aware of the direction of the displacement of these fragments, they never report a full understanding of their actual movement. When we present students with these particular clinical situations using a stereoscopic technique, they report that it is very easy to for them to grasp the exact direction. Also, when using stereoscopic images, they

report gaining improved understanding of the location of impacted and supernumerary teeth. In all, our students have seemed to benefit greatly from stereoscopy compared to standard 2D or non-stereoscopic 3D teaching materials especially for specific cases such as those mentioned in this study.

Conclusion

The results of this study suggest there could be a significant role to play for stereoscopic images in dental and perhaps also patient education. Stereoscopic techniques were found to contribute to students' understanding of complex 3D structures such as anatomical images found on CT scans.

REFERENCES

1. Rapp DN, Culpepper SA, Kirkby K, Morin P. Fostering students' comprehension of topographic maps. *J Geosci Educ* 2007;55(1):5-16.
2. Garcia-Ruiz MA, Santana PC, Molina I. Using effective stereoscopic molecular model visualizations in undergraduate classrooms. *Int J Cross Disc Subjects Educ* 2014;5(1):1593-8.
3. Dvorak J, Hamata V, Skacilik J, Benes B. Boosting up architectural design education with virtual reality. *Central Eur Multimedia Virtual Reality Conf* 2005;5:95-200.
4. Owczarczyk J, Owczarczyk B. Evaluation of true 3 D display systems for visualizing medical volume data. *Visual Comput* 1990;6(4):219-26.
5. Luursema JM, Verwey WB, Kommers PA, Annema JH. The role of stereopsis in virtual anatomical learning. *Interacting Comput* 2008;20(4-5):455-60.
6. Ferdig R, Blank J, Kratoski A, Clements R. Using stereoscopy to teach complex biological concepts. *Adv Physiol Educ* 2015;39(3):205-8.
7. Jaeger TF. Categorical data analysis: away from ANOVAs (transformation or not) and towards logit mixed models. *J Memory Language* 2008;59(4):434-46.