



Universiteit  
Leiden  
The Netherlands

## **Retinal oximetry with a prototype handheld oximeter during hyperoxia**

Vehmeijer, W.B.; Jonkman, K.; Hardarson, S.H.; Aarts, L.; Stefansson, E.; Dahan, A.; Schalij-Delfos, N.E.

### **Citation**

Vehmeijer, W. B., Jonkman, K., Hardarson, S. H., Aarts, L., Stefansson, E., Dahan, A., & Schalij-Delfos, N. E. (2021). Retinal oximetry with a prototype handheld oximeter during hyperoxia. *Acta Ophthalmologica*, 99(8), e1390-e1395. doi:10.1111/aos.14817

Version: Publisher's Version

License: [Creative Commons CC BY-NC-ND 4.0 license](https://creativecommons.org/licenses/by-nc-nd/4.0/)

Downloaded from: <https://hdl.handle.net/1887/3213215>

**Note:** To cite this publication please use the final published version (if applicable).

# Retinal oximetry with a prototype handheld oximeter during hyperoxia

Wouter B. Vehmeijer,<sup>1</sup> Kelly Jonkman,<sup>2</sup> Sveinn H. Hardarson,<sup>3</sup> Leon Aarts,<sup>2</sup> Einar Stefansson,<sup>3,4</sup> Albert Dahan<sup>2</sup> and Nicoline E. Schalijs-Delfos<sup>1</sup>

<sup>1</sup>Department of Ophthalmology, Leiden University Medical Center, Leiden, The Netherlands

<sup>2</sup>Department of Anesthesiology, Leiden University Medical Center, Leiden, The Netherlands

<sup>3</sup>Department of Physiology, University of Iceland, Reykjavik, Iceland

<sup>4</sup>Department of Ophthalmology, University of Iceland, Landspítali, Reykjavik, Iceland

## ABSTRACT.

**Purpose:** Retinal oximetry measures oxygen saturation in retinal vessels. With the introduction of a mobile handheld prototype oximeter, this technique will become available for a broader patient population including bedridden patients and newborn babies. The objective is to determine the sensitivity of this handheld oximeter in room air and during isocapnic hyperoxia. A comparison is made between the handheld oximeter and the Oxymap T1.

**Methods:** Thirteen young healthy subjects with a mean age of  $25 \pm 2$  years were recruited at the Leiden University Medical Center. Retinal oximetry images were acquired during normoxia and during isocapnic hyperoxia for both the prototype oximeter and the OxymapT1. Isocapnic hyperoxia was induced with the dynamic end-tidal forcing technique. For both oximeters, the oxygen saturation and vessel width were measured with Oxymap Analyzer software. The hyperoxic state was verified with blood gas analysis.

**Results:** The mean oxygen saturation measured with the handheld oximeter in arterioles was  $91.3\% \pm 3.9\%$  during normoxia and  $94.6\% \pm 3.9\%$  during hyperoxia ( $p = 0.001$ ). Oxygen saturation in venules was  $56.3\% \pm 9.8\%$  during normoxia and  $82.2 \pm 7.4\%$  during hyperoxia ( $p < 0.001$ ). For the Oxymap T1, the mean oxygen saturation for arterioles was  $94.0\% \pm 2.6\%$  during normoxia and  $95.4\% \pm 3.2\%$  during hyperoxia ( $p = 0.004$ ). For the venules, the oxygen saturation was during normoxia  $58.9\% \pm 3.2\%$  and  $84.3 \pm 4.0\%$  during hyperoxia ( $p < 0.001$ ).

**Conclusion:** The handheld retinal oximeter is sensitive to the changes in inhaled oxygen concentration. A small increase in oxygen saturation was measured in the arterioles and a larger increase in the venules. The handheld oximeter gives similar values as the 'gold standard' Oxymap T1 oximeter.

**Key words:** retinal oximetry – fundus imaging – handheld oximeter – hyperoxia

Acta Ophthalmol. 2021; 99: e1390–e1395

© 2021 The Authors. Acta Ophthalmologica published by John Wiley & Sons Ltd on behalf of Acta Ophthalmologica Scandinavica Foundation.

This is an open access article under the terms of the Creative Commons Attribution-NonCommercial-NoDeriv License, which permits use and distribution in any medium, provided the original work is properly cited, the use is non-commercial and no modifications or adaptations are made.

doi: 10.1111/aos.14817

## Introduction

The metabolic need of the retina is extremely high, and any malfunction in the supply of oxygen and nutrients can lead to a variety of retinal diseases. Oxygen and other nutrients are supplied to the retina through both the retinal vessels and the choroid. Oxygen diffuses from the choroid to the outer retina, while the inner retina is mainly supplied with oxygen by the retinal vessels. The mechanism of blood flow regulation differs in the choroid and retinal vessels. Blood flow in the choroid is minimally influenced by the oxygen concentration (Geiser et al. 2000). In comparison, the retinal vessel diameters are highly influenced by oxygen concentration (Hickam & Frayser 1966; Deutsch et al. 1983; Pakola & Grunwald 1993; Gilmore et al. 2004; Palkovits et al. 2014; Olafsdottir et al. 2015).

In recent years, it has been possible to measure oxygen saturation of the retinal vessels by retinal oximetry. Retinal oximetry is a noninvasive spectrophotometric imaging technique, in which the difference in light absorbance of deoxyhaemoglobin and oxyhaemoglobin is utilized to measure percentage of oxygen saturation of haemoglobin. The history of retinal oximetry and its development have been described by Beach (2014). Commercial oximeters (DVA, Imedos UG., Jena, Germany and the Oxymap T1, Oxymap ehf., Reykjavik, Iceland) use the dual wavelength principle. Images

are acquired at two wavelengths of light. One of the wavelengths is sensitive to changes in oxygen saturation, while the other is an isosbestic (insensitive) wavelength (Beach 2014). A recent review shows how this technology has provided insight into the pathophysiology of retinal diseases (Stefansson et al. 2017). Currently, these oximeters are based on a stationary fundus camera and are restricted to patients who can be positioned upright. In supine patients, such as young children, comatose or sedated patients, measurement of retinal saturation is not possible using current devices. Therefore, a prototype, handheld, mobile retinal oximeter which we have named 'Corimap Camera' (Demcon Focal B.V., Enschede, The Netherlands) has been developed for use in supine patients. The Corimap Camera has been more extensively described in an earlier publication by Vehmeijer et al. (2018)

It is essential that a retinal oximeter is sensitive to change in retinal oxygenation. In several studies, an abundance of 100% oxygen in breathing air (hyperoxia) has been used to determine the sensitivity of oximeters. In previous hyperoxia studies, a large increase in venous saturation and a small response in the arterioles have been reported (Hardarson et al. 2006; Kristjansdottir et al. 2014; Olafsdottir et al. 2015). Administered oxygen has a more pronounced effect on constriction of the retinal vessels in comparison to minimal vessel constriction of the choroid (Riva et al. 1983; Pournaras et al. 2008; Schmidl et al. 2011). Hyperoxia leads to constriction of the retinal arterioles, which reduces the blood flow in the retinal vessels. However, this reduction in blood flow does not prevent the retina from receiving abundance of oxygen, in large part from the choroidal circulation (Stefansson et al. 1981; Stefansson et al. 1983; Wolbarsht et al. 1987; Linsenmeier & Yancey 1989; Pournaras et al. 1989).

The objective of this study is to explore the sensitivity of the handheld oximeter and compare it with the 'gold standard' Oxymap T1. Therefore, we measure oxygen saturation in retinal vessels during normoxia and isocapnic hyperoxia with the handheld oximeter and the Oxymap T1 retinal oximeter in the same subjects.

## Methods

This study was approved by the Medical Ethical Review Committee of the Leiden University Medical Centre, the Netherlands (NL56086.058.16) and adhered to the tenets of the Declaration of Helsinki. All subjects provided written informed consent prior to start of the study.

For this study, healthy subjects (18–35 years) were recruited at the Leiden University Medical Centre. Subjects were excluded in case of any ocular opacity, a refractive error greater than  $\pm 6$  diopters or a cylindrical error of  $> 1.5$  diopters, a history of ocular disease, a history of systemic disease, which could affect the eye or oxygen levels, and a familial history of glaucoma. The subjects were asked to abstain for twelve hours from caffeinated drinks prior to the investigation. After ophthalmological examination, one eye was randomly selected for the study. The pupil of this eye was dilated before investigation and final inclusion in this study.

Retinal oximetry is a noninvasive method to measure the relative oxygen saturation of the retinal vessels. In this study, a comparison was made between the Corimap Camera (Demcon Focal B.V., Enschede, Netherlands) and Oxymap T1 (Oxymap ehf., Reykjavik, Iceland) during normoxia (end-tidal oxygen pressure,  $P_{etO_2} = 14.5$  kPa) and during isocapnic hyperoxia ( $P_{etO_2} = 90$  kPa). Both oximeters work according to the dual wavelength principle and take images at wavelengths 570 nm and 600 nm.

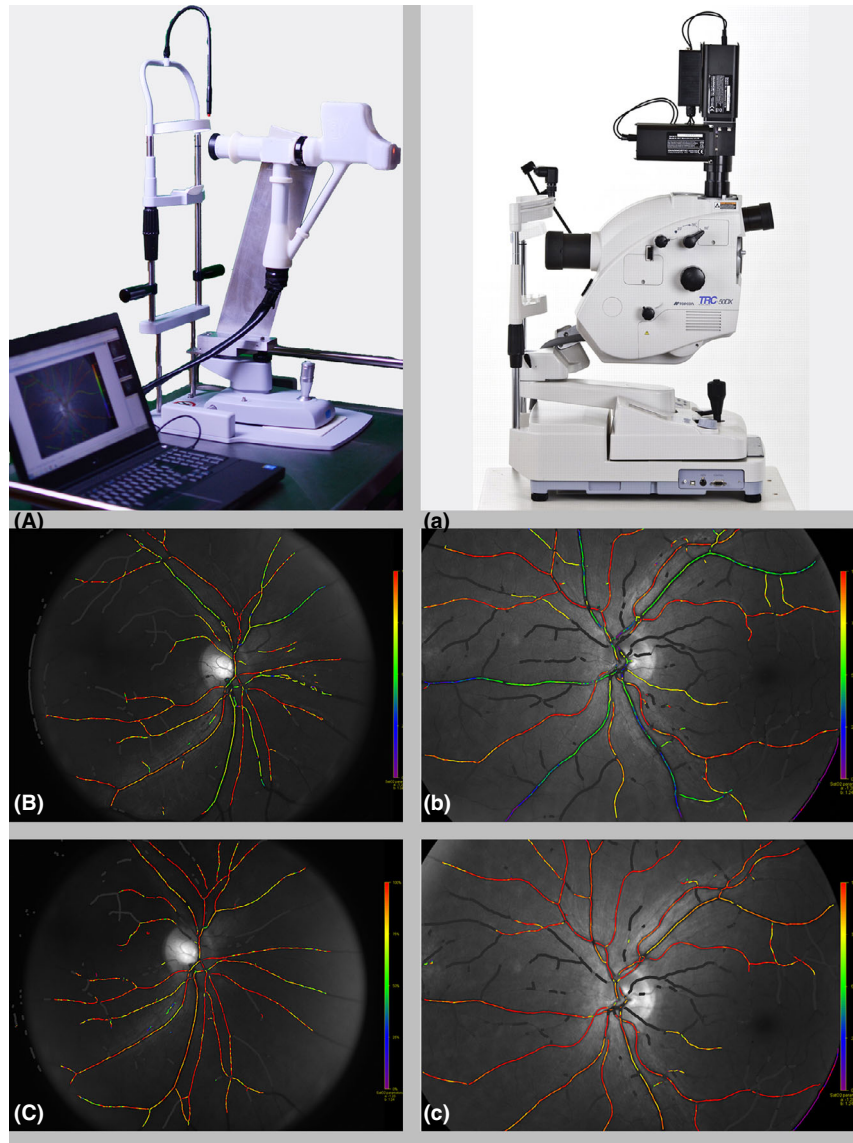
The Corimap Camera is a custom-built dual wavelength oximeter and consists of two digital cameras (Cameleon 3, with a Sony ICX818 sensor, resolution 1928 x 1448, PointGrey, Richmond, Canada) for the simultaneous capturing of two images at two wavelengths of light. Two Xenon flashes with 570 nm and 600 nm filters with a half maximum bandwidth of 6 nm (Chroma Technology Corp, Vermont, USA) are built into a lightbox. The camera uses near-infrared light for the alignment and focusing. The three light sources are connected through twelve glass fibres (POF, CK-60, Mitsubishi Rayon CO, LTD, Japan). The glass fibres for the light sources within the Corimap Camera are posited in a ring for the illumination of the retina.

For this study, the Corimap Camera was mounted to a chinrest while it can also be used in a handheld manner. The Oxymap T1 is composed of two digital cameras (Insight IN1800,  $1600 \times 1200$  square pixels; Diagnostic Instruments Inc., Sterling Heights, MI, USA), a custom optical adapter and an image splitter as an addition to a fundus camera (Topcon TRC-50DX; Topcon Corporation). (Fig. 1).

After the dilation of the pupils with Tropicamide 0.5% (Thea, Clermont-Ferrand, France), one oximeter was randomly selected to start the image acquisition both in normoxia and during hyperoxia. The images were aligned with the optic disc in the centre of the frame. The images were disregarded if they were out of focus or off-centre.

The first procedure was to image the retina in room air (normoxia) with the randomly selected oximeter. Subsequently, this procedure was repeated for the second oximeter. The hyperoxia procedure started with the fitting of a rebreathing facemask. As hyperoxia may cause hyperventilation, hyperoxia was induced (fraction of inspired oxygen,  $FiO_2 = 0.9$ ) while maintaining a constant end-tidal  $PCO_2$  by means of the 'dynamic end-tidal forcing technique' (Dahan et al. 2007). This technique manipulates inspired gas concentrations of oxygen and carbon dioxide to ensure a constant end-tidal concentration throughout the experiment. In the current study, the end-tidal  $CO_2$  concentrations were kept constant at baseline level. The gas mixtures were administered to the subjects via the face mask. The oxygen saturation was constantly monitored through the index finger with of a pulse oximeter (Masimo Corporation, Irvine, CA, USA).

After approximately five minutes of baseline measurements (respiratory rate, tidal volume (mL), heart rate (bpm), pulse oximetry (%), inspired carbon dioxide ( $PiCO_2$ , kPa), end-tidal carbon dioxide ( $P_{etCO_2}$ , kPa), inspired oxygen ( $PiO_2$ , kPa), end-tidal oxygen ( $P_{etO_2}$ , kPa)), the subject was placed in a comfortable seated position on a bed. Subjects remained in seated position for 30 min to reach a steady state of hyperoxia ( $P_{etO_2} 90$  kPa). To verify hyperoxia, arterial blood samples were drawn from the arteria radialis after 25 min for measurement of arterial oxygen concentrations using the i-STAT device



**Fig. 1.** Retinal oximetry in normoxia and hyperoxia with both oximeters. (A) Mobile Handheld Oximeter (Corimap Camera) in its stationary mode. Retinal oximetry images with the Handheld Oximeter (A = normoxia, C = hyperoxia). (a) The current ‘gold’ standard Oxymap T1. Retinal oximetry with the Oxymap T1 (b = normoxia and c = hyperoxia).

**Table 1.** Physiological variables during normoxia, hyperoxia and recovery for both oxygenation sessions

	Session I			Session II		
	Baseline	Hyperoxia	Recovery	Baseline	Hyperoxia	Recovery
Physiological variables						
Ventilation (L/min)	9.4 ± 1.4	15.6 ± 3.0	13.5 ± 4.1	10.0 ± 1.9	17.4 ± 3.8	13.8 ± 3.5
Tidal volume (ml) normoxia	723.6 ± 170	915 ± 168	800 ± 249	671 ± 107	935 ± 171	756 ± 307
Inspired carbon dioxide (PiCO <sub>2</sub> )	0.17 ± 0.2	2.05 ± 0.7	1.77 ± 5.9	0.14 ± 0.2	2.4 ± 0.8	2.9 ± 6.7
End-tidal carbon dioxide (PetCO <sub>2</sub> )	4.8 ± 1.5	5.3 ± 0.5	6.0 ± 5.4	4.9 ± 0.4	5.07 ± 0.9	6.2 ± 5.1
Inspired oxygen (PiO <sub>2</sub> )	20.0 ± 4.5	87.27 ± 2.5	23.0 ± 1.5	21.0 ± 1.1	81.7 ± 17.5	26.2 ± 5.6
Expired oxygen (PeO <sub>2</sub> )	15.3 ± 0.8	82.5 ± 2.3	20.7 ± 1.9	15.5 ± 0.9	77.3 ± 16.8	23.6 ± 5.7
Heart rate (bpm)	62 ± 12	62 ± 9	70 ± 18	57 ± 41	61 ± 11	71 ± 14
Oxygen saturation (%)	98.5 ± 1.2	99.8 ± 0.4	98.9 ± 1.9	99.0 ± 1.4	99.5 ± 0.6	99.2 ± 1.2

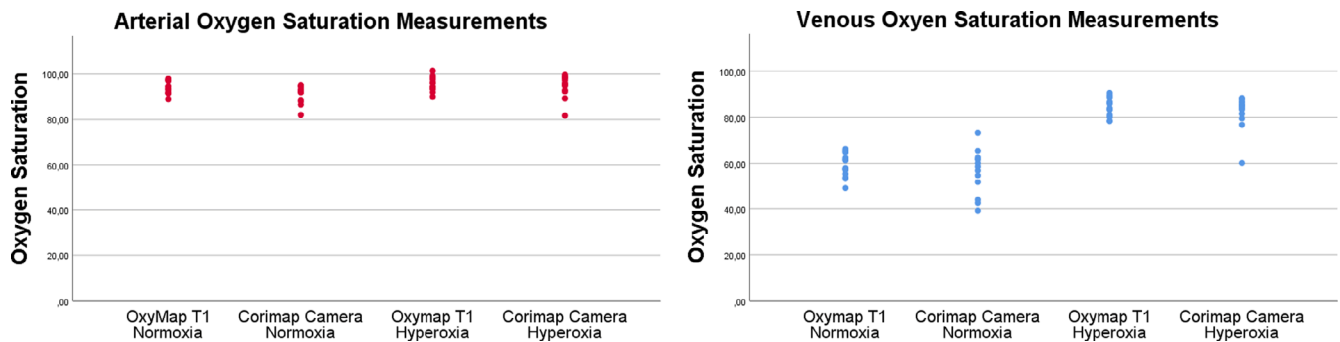
(Abbott, Chicago, IL, USA) with Cartridges CG4+. One of the retinal oximeters was randomly selected to capture

retinal images. Subjects were positioned with a face mask in the chinrest of the camera, and then, the imaging procedure

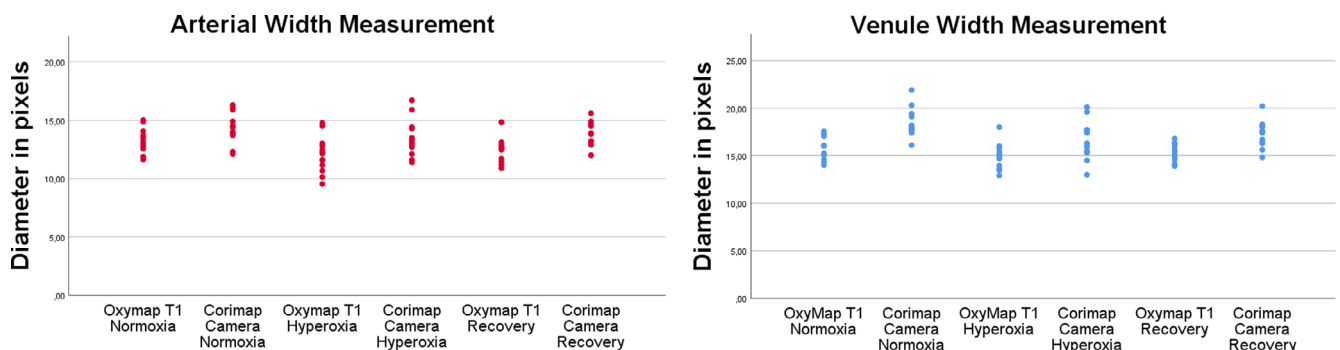
was started for the hyperoxia images. When these hyperoxia images were acquired, while the subject remained in

**Table 2.** Retinal saturation and vessel diameter in normoxia, hyperoxia and after recovery

	Normoxia		Hyperoxia		Recovery	
	Corimap camera	Oxymap T1	Corimap camera	Oxymap T1	Corimap camera	Oxymap T1
<b>Oxygen saturation (Mean ± SD)</b>						
Arterioles	91.3% ± 3.9%	94.0% ± 2.8%	94.6% ± 4.9%	95.4% ± 3.2%	89.2% ± 5.2%	93.2% ± 2.6%
Venules	56.3% ± 9.8%	58.9% ± 5.3%	82.2% ± 7.4%	84.3% ± 4.0%	54.9% ± 12.8%	61.8% ± 5.5%
AV difference	35.0% ± 7.3%	35.0% ± 5.6%	12.3% ± 4.2%	11.2% ± 3.4%	34.3% ± 9.3%	31.4% ± 5.1%
<b>Diameter (Pixels, Mean ± SD)</b>						
Arterioles	14.4 ± 1.3	13.08 ± 1.18	13.5 ± 1.6	12.08 ± 1.51	13.6 ± 1.1	12.60 ± 1.20
Venules	18.4 ± 1.4	15.83 ± 1.22	16.7 ± 2.0	14.92 ± 1.34	17.3 ± 1.4	15.36 ± 0.99



**Fig. 2.** This scatterplot shows oxygen saturation measurement for both the Corimap Camera and Oxymap T1 during normoxia and hyperoxia. Each dot represents a mean value from a single eye (13 eyes in 13 individuals).



**Fig. 3.** This scatterplot shows vessel width for both the Corimap Camera and Oxymap T1 during normoxia, hyperoxia and recovery phase. Each dot represents a mean value from a single eye (13 eyes in 13 individuals).

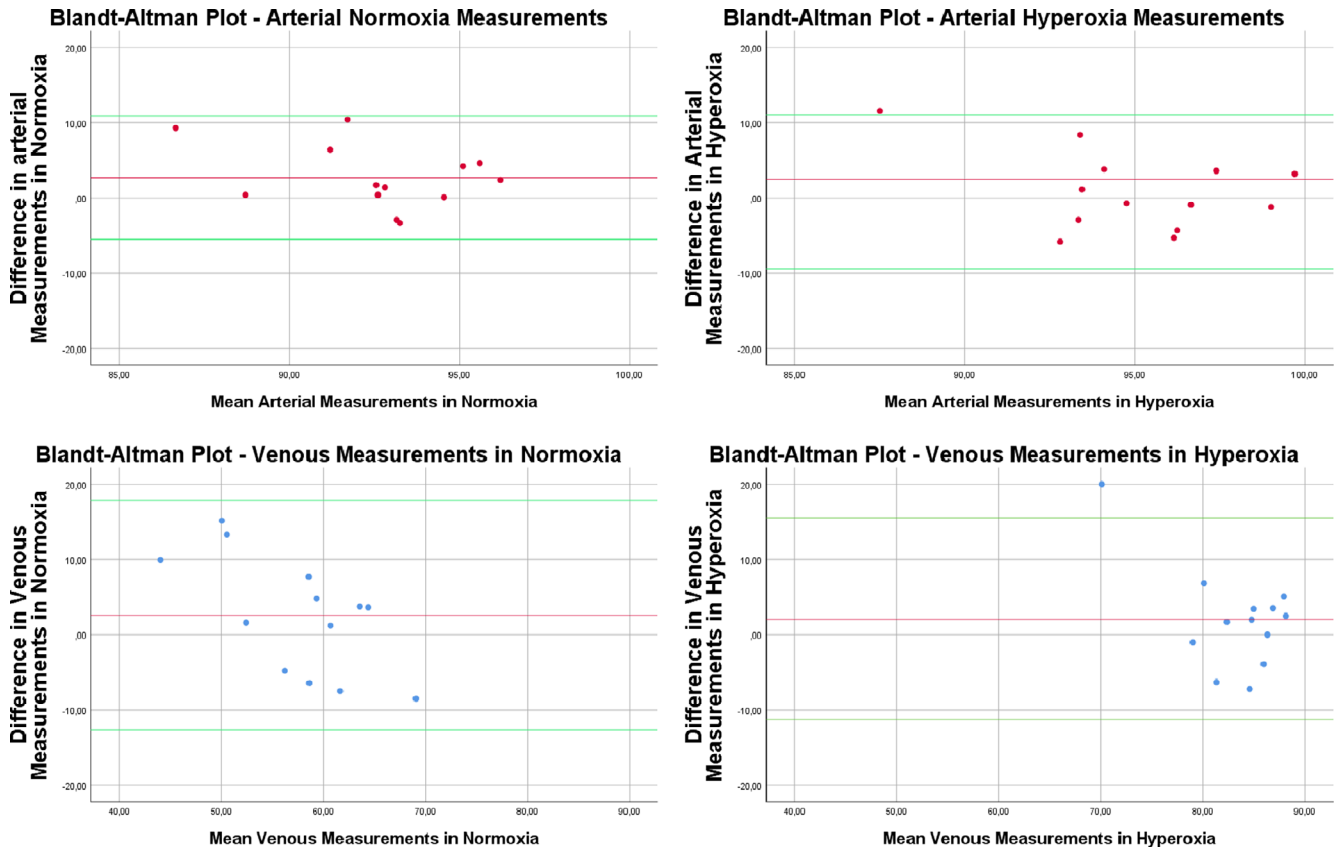
the chinrest, the supply of surplus oxygen was disabled, thereby returning to normoxia. When oxygen saturation normalized, the third imaging procedure started to measure the saturation and vessel width in recovery.

**Images analysis**

For measurements of oxygen saturation and vessel width, the images were analysed with the Oxymap Analyzer software (version 2.5.1, Oxymap ehf.,

Reykjavik, Iceland). The software was modified to analyse the images of the Corimap Camera. The software also measured focus and contrast automatically. For comparison between images and cameras, images were selected if they had high grades for focus and contrast. Subjects with images graded with an overall image quality score lower than 6.0 (out of 10) by the Oxymap Analyzer software were excluded. The major blood vessels segments close to the optic disc were

measured for oxygen saturation, according to the standardized Oxymap T1 analysis protocol. Measurements were taken in a predefined standardized area around the optic disc. Circles were drawn on the images around the optic disc with the tools of the Oxymap Analyzer software. The circles were 1.5 times and 3 times the size of the optic disc, and the area between the circle was the area of measurements. Vessels were measured if 6 pixels or more in diameter and between 50 and 200 pixels



**Fig. 4.** Bland–Altman plots for the comparison and level of agreement between the Corimap Camera and the Oxymap T1 during normoxia and hyperoxia. The red line is mean difference between the Oxymap T1 and the Corimap Camera, and the green line is  $\pm 1.96$  standard deviation. The difference was calculated as values from Oxymap T1 minus values from the Corimap.

in length and could be matched between cameras. The measured vessels were first-degree vessels or second degree if the length of the vessels of the first-degree vessels was less than 50 pixels (Palsson et al. 2012; Olafsdottir et al. 2015; Vehmeijer et al. 2018). For the comparison between the Corimap Camera and the Oxymap T1 analysis, Bland–Altman plots were constructed for the level of agreement between both cameras. The calibration factors for the Corimap Camera were found in a previous study by Vehmeijer et al. (2018) in which the optical density ratio was matched to oxygen saturation within the retinal vessels in healthy volunteers in a study by Schweitzer et al. (1999).

## Results

In this study, thirteen healthy individuals were included (78% female) with a mean age  $\pm$  SD of  $25 \pm 2$  years. The Snellen visual acuity of the participants had a median of 1.2 (range 1.1–1.2). Baseline data are shown in Table 1.

Oxygen saturation in retinal arterioles was mildly increased during hyperoxia. This increase was measured with both oximeters ( $p = 0.001$  for the Corimap and  $p < 0.001$  for the Oxymap T1), see Table 2 and Fig 2. Table 2 also shows that a large change in venous oxygen saturation and in arteriovenous difference was measured with both oximeters ( $p < 0.001$  for both oximeters) and the normalized measurements during the recovery stages with a significant difference between the arterioles and venules. ( $p < 0.001$  for both oximeters) Moreover, there is a significant decrease in vessel width of the vessels both in arterioles and in the venules in pixels during hyperoxia for both oximeters ( $p < 0.05$ ) (Fig. 3) The sensitivity has been plotted in the Bland–Altman plots (Fig.4 and shows comparable sensitivity.

## Discussion

The handheld Corimap Camera shows a significant difference between images obtained during normoxia (room air)

and hyperoxia with an increase of 3.3 percentage points of the arterioles and a larger increase of 25.9 percentage points for the venules. This is compared to an increase of 1.4 percentage points for the arterioles and 25.4 percentage points for venules measured with the Oxymap T1. Hence, the Corimap Camera is sensitive to changes in oxygen saturation. Also, the performance of the Corimap Camera compares well to the current ‘gold’ standard of retinal oximetry, the Oxymap T1.

As is shown in the Bland–Altman Plots (Fig.4, the measurements of both oximeters cameras are comparable and in agreement with minimal outliers.

Although the dual wavelength principle for retinal oximetry is similar for both oximeters, the prototype Corimap camera has some additional features. First, the Corimap Camera can be used in a handheld manner and as such is applicable to a wider patient population. Second, it is mobile and stand alone for transportation within the hospital. Third, the use of polarized



light of this prototype oximeter could have a beneficial effect on the oxygen measurements due to the reduction of vascular reflections. Finally, for the reduction light exposure, infrared light is used for the alignment which is preferable over continuous white light. In the future, the infrared light may allow for nonmydriatic imaging. These features allow for a broader application of retinal oximetry and can overcome some of the current limitations of commercially available (fundus-based camera) retinal oximeters. This allows application of retinal oximetry in a broader population, for example in infants with retinopathy of prematurity in which oxygen plays a pivotal role, young children, and sedated or comatose patients.

In an earlier study (Vehmeijer et al. 2018), the handheld Corimap Camera was calibrated and compared to the current standard, the Oxymap T1. The Corimap Camera is in several ways different from the T1 camera. A first discriminating feature is that the illumination pathway of the Corimap Camera consists of twelve glass fibres in a ring formation within the camera unit. The glass fibre ring set-up might influence on the measurements if not properly aligned with the pupil. Improper alignment makes the illumination of the retina less even. Second, a modified version of the Oxymap Analyzer software is used. In the Oxymap Analyzer software, saturation values derived from the Oxymap T1 are corrected for the effect of vessel diameters, whereas the saturation values of the Corimap Camera are calculated directly from the optical density ratio. In the future, hardware and software modifications could enhance the performance of the Corimap camera.

In a recent study with the Oxymap T1, Olafsdottir et al. showed comparable results to the current study with modest increase of oxygen saturation in arterioles and large increase in venules during 100% O<sub>2</sub> breathing compared to normoxia (Olafsdottir et al. 2015). In the former study, a decrease in width of the vessels was found during the hyperoxia state of the subjects. The current study also showed a decrease in vessel width during the isocapnic hyperoxia stage of the study.

The autoregulation of the retinal blood flow consists of the adjustment in vascular resistance, which follows a

balanced equilibrium of a metabolic and myogenic component. The myogenic component limits fluctuations in blood flow, despite variations in blood pressure. Earlier studies with several mixtures of oxygen, both hyperoxia and hypoxia, showed an effect of oxygen on the vessel width. Besides the role of oxygen for the regulation of the vessel diameter, there is also a role for carbon dioxide in the regulation of the blood flow of the eye (Hickam & Frayser 1966; Pakola & Grunwald 1993; Luksch et al. 2002; Gilmore et al. 2005).

In summary, the handheld Corimap Camera is sensitive to oxygen changes in retinal vessels and reliably measures oxygen saturation in retinal vessels in both normoxia and hyperoxia oxygen environments. The Corimap Camera performs well in comparison with the current gold standard of retinal oximetry, the Oxymap T1.

## References

- Beach J (2014): Pathway to retinal oximetry. *Translat Vision Sci Technol* 3: 2.
- Dahan A, Nieuwenhuijs D & Teppema L (2007): Plasticity of central chemoreceptors: effect of bilateral carotid body resection on central CO<sub>2</sub> sensitivity. *PLoS Med* 4: e239.
- Deutsch TA, Read JS, Ernest JT & Goldstick TK (1983): Effects of oxygen and carbon dioxide on the retinal vasculature in humans. *Arch Ophthalmol* 101: 1278–1280.
- Geiser MH, Riva CE, Dorner GT, Diermann U, Luksch A & Schmetterer L (2000): Response of choroidal blood flow in the foveal region to hyperoxia and hyperoxia-hypercapnia. *Curr Eye Res* 21: 669–676.
- Gilmore ED, Hudson C, Preiss D & Fisher J (2005): Retinal arteriolar diameter, blood velocity, and blood flow response to an isocapnic hyperoxic provocation. *American journal of physiology. Heart Circulat Physiol* 288: H2912–2917.
- Gilmore ED, Hudson C, Venkataraman ST, Preiss D & Fisher J (2004): Comparison of different hyperoxic paradigms to induce vasoconstriction: implications for the investigation of retinal vascular reactivity. *Invest Ophthalmol Vis Sci* 45: 3207–3212.
- Hardarson SH, Harris A, Karlsson RA et al. (2006): Automatic retinal oximetry. *Invest Ophthalmol Vis Sci* 47: 5011–5016.
- Hickam JB & Frayser R (1966): Studies of the retinal circulation in man. Observations on vessel diameter, arteriovenous oxygen difference, and mean circulation time. *Circulation* 33: 302–316.
- Kristjansdottir JV, Hardarson SH, Halldorsson GH, Karlsson RA, Eliasdottir TS & Stefansson E (2014): Retinal oximetry with a scanning laser ophthalmoscope. *Invest Ophthalmol Vis Sci* 55: 3120–3126.
- Linsenmeier RA & Yancey CM (1989): Effects of hyperoxia on the oxygen distribution in the intact cat retina. *Invest Ophthalmol Vis Sci* 30: 612–618.
- Luksch A, Garhofer G, Imhof A et al. (2002): Effect of inhalation of different mixtures of O<sub>2</sub> and CO<sub>2</sub> on retinal blood flow. *Br J Ophthalmol* 86: 1143–1147.
- Olafsdottir OB, Eliasdottir TS, Kristjansdottir JV, Hardarson SH & Stefansson E (2015): Retinal vessel oxygen saturation during 100% oxygen breathing in healthy individuals. *PLoS One* 10: e0128780.
- Pakola SJ & Grunwald JE (1993): Effects of oxygen and carbon dioxide on human retinal circulation. *Invest Ophthalmol Vis Sci* 34: 2866–2870.
- Palkovits S, Lasta M, Told R et al. (2014): Retinal oxygen metabolism during normoxia and hyperoxia in healthy subjects. *Invest Ophthalmol Vis Sci* 55: 4707–4713.
- Palsson O, Geirsdottir A, Hardarson SH, Olafsdottir OB, Kristjansdottir JV & Stefansson E (2012): Retinal oximetry images must be standardized: a methodological analysis. *Invest Ophthalmol Vis Sci* 53: 1729–1733.
- Pournaras CJ, Riva CE, Tsacopoulos M & Strommer K (1989): Diffusion of O<sub>2</sub> in the retina of anesthetized miniature pigs in normoxia and hyperoxia. *Exp Eye Res* 49: 347–360.
- Pournaras CJ, Rungger-Brändle E, Riva CE, Hardarson SH & Stefansson E (2008): Regulation of retinal blood flow in health and disease. *Prog Retin Eye Res* 27: 284–330.
- Riva CE, Grunwald JE & Sinclair SH (1983): Laser Doppler Velocimetry study of the effect of pure oxygen breathing on retinal blood flow. *Invest Ophthalmol Vis Sci* 24: 47–51.
- Schmidl D, Garhofer G & Schmetterer L (2011): The complex interaction between ocular perfusion pressure and ocular blood flow – relevance for glaucoma. *Exp Eye Res* 93: 141–155.
- Schweitzer D, Hammer M, Kraft J, Thamm E, Konigsdorffer E & Strobel J (1999): In vivo measurement of the oxygen saturation of retinal vessels in healthy volunteers. *IEEE Trans Biomed Eng* 46: 1454–1465.
- Stefansson E, Landers MB 3rd & Wolbarsht ML (1981): Increased retinal oxygen supply following pan-retinal photocoagulation and vitrectomy and lensectomy. *Trans Am Ophthalmol Soc* 79: 307–334.
- Stefansson E, Olafsdottir OB, Einarsdottir AB et al. (2017): Retinal oximetry discovers novel biomarkers in retinal and brain diseases. *Invest Ophthalmol Vis Sci* 58: Bio227-bio233.
- Stefansson E, Wolbarsht ML & Landers MB 3rd (1983): In vivo O<sub>2</sub> consumption in rhesus monkeys in light and dark. *Exp Eye Res* 37: 251–256.
- Vehmeijer W, Hardarson SH, Jonkman K, Aarts L, Dahan A, Stefansson E & Schalijs-Delfos N (2018): Handheld retinal oximetry in healthy young adults. *Translational vision science & technology* 7: 19.
- Wolbarsht ML, Stefansson E & Landers MB 3rd (1987): Retinal oxygenation from the choroid in hyperoxia. *Experimental Biol* 47: 49–52.

Received on February 27th, 2020.

Accepted on February 4th, 2021.

### Correspondence:

Nicoline E. Schalijs-Delfos

Albinusdreef 2

2300 RC Leiden

The Netherlands

Tel: +31 71 5262374

Fax: +31 71 5266576

Email: n.e.schalijs-delfos@lumc.nl

Grant provided by ODAS foundation, The Netherlands, (*Nonprofit*). ES and SHH are shareholders and board members in Oxymap ehf., which produces retinal oximeters.