



Universiteit  
Leiden  
The Netherlands

## **Hepatocellular adenoma in men: a nationwide assessment of pathology and correlation with clinical course**

Rosmalen, B.V. van; Furumaya, A.; Klompenhouwer, A.J.; Tushuizen, M.E.; Braat, A.E.; Reinten, R.J.; ... ; PALGA Grp








### **Citation**

Rosmalen, B. V. van, Furumaya, A., Klompenhouwer, A. J., Tushuizen, M. E., Braat, A. E., Reinten, R. J., ... Verheij, J. (2021). Hepatocellular adenoma in men: a nationwide assessment of pathology and correlation with clinical course. *Liver International*, 41(10), 2474-2484. doi:10.1111/liv.14989

Version: Publisher's Version  
License: [Creative Commons CC BY-NC-ND 4.0 license](https://creativecommons.org/licenses/by-nc-nd/4.0/)  
Downloaded from: <https://hdl.handle.net/1887/3203810>

**Note:** To cite this publication please use the final published version (if applicable).

# Hepatocellular adenoma in men: A nationwide assessment of pathology and correlation with clinical course

Belle V. van Rosmalen<sup>1\*</sup>  | Alicia Furumaya<sup>1\*</sup>  | Anne J. Klompenhouwer<sup>2</sup>  |  
 Maarten E. Tushuizen<sup>3</sup>  | Andries E. Braat<sup>4</sup>  | Roy J. Reinten<sup>5</sup> | Marjolein A. P. Ligthart<sup>6</sup> |  
 Martijn P. D. Haring<sup>7</sup>  | Vincent E. de Meijer<sup>7</sup> | Theo van Voorthuizen<sup>8</sup> |  
 R. Bart Takkenberg<sup>9</sup> | Cornelis H. C. Dejong<sup>6,10</sup> | Robert A. de Man<sup>2</sup> | Jan N. M. IJzermans<sup>11</sup>  |  
 Michail Doukas<sup>12†</sup> | Thomas M. van Gulik<sup>1†</sup> | Joanne Verheij<sup>5†</sup> | on behalf of the Dutch  
 Benign Liver Tumor Group and the PALGA group

<sup>1</sup>Department of Surgery, Cancer Center Amsterdam, Amsterdam UMC, University of Amsterdam, Amsterdam, the Netherlands

<sup>2</sup>Department of Gastroenterology and Hepatology, Erasmus MC, University Medical Center Rotterdam, Rotterdam, the Netherlands

<sup>3</sup>Department of Gastroenterology and Hepatology, LUMC, Leiden University, Leiden, the Netherlands

<sup>4</sup>Department of Surgery, LUMC, Leiden University, Leiden, the Netherlands

<sup>5</sup>Department of Pathology, Cancer Center Amsterdam, Amsterdam UMC, University of Amsterdam, Amsterdam, the Netherlands

<sup>6</sup>Department of Surgery and School of Nutrition and Translational Research in Metabolism, Maastricht University Medical Center, Maastricht, the Netherlands

<sup>7</sup>Department of Surgery, University Medical Center Groningen, University of Groningen, Groningen, the Netherlands

<sup>8</sup>Department of Oncology, Rijnstate hospital, Arnhem, the Netherlands

<sup>9</sup>Department of Gastroenterology and Hepatology, Cancer Center Amsterdam, Amsterdam UMC, University of Amsterdam, Amsterdam, the Netherlands

<sup>10</sup>Department of Surgery, Universitätsklinikum Aachen, Aachen, Germany

<sup>11</sup>Department of Surgery, Erasmus MC, University Medical Center Rotterdam, Rotterdam, the Netherlands

<sup>12</sup>Department of Pathology, Erasmus MC, University Medical Center Rotterdam, Rotterdam, the Netherlands

## Correspondence

Belle Vivica van Rosmalen, Department of Surgery, Cancer Center Amsterdam, Amsterdam UMC, University of Amsterdam, Meibergdreef 9, 1105 AZ Amsterdam, the Netherlands.  
 Email: b.v.vanrosmalen@gmail.com

## Funding information

The study was supported by a personal grant of the Amsterdam UMC, location AMC to B. V. van Rosmalen. For the remaining

## Abstract

**Background & Aims:** Hepatocellular adenomas (HCA) rarely occur in males, and if so, are frequently associated with malignant transformation. Guidelines are based on small numbers of patients and advise resection of HCA in male patients, irrespective of size or subtype. This nationwide retrospective cohort study is the largest series of HCA in men correlating (immuno)histopathological and molecular findings with the clinical course.

**Abbreviations:** B<sup>ex3</sup>HCA, B-catenin activated adenoma with exon 3 mutation; B<sup>ex3</sup>IHCA, B-catenin activated inflammatory adenoma with exon 3 mutation; B<sup>ex7,8</sup>HCA, B-catenin activated adenoma with exon 7/8 mutation; B<sup>ex7,8</sup>IHCA, B-catenin activated inflammatory adenoma with exon 7/8 mutation; CTNNB1, catenin beta 1, encoding B-catenin; HCA, hepatocellular adenoma; HCC, hepatocellular carcinoma; H-HCA, HNF-1a (hepatocyte nuclear factor-1 alpha) inactivated adenoma; hTERT, human telomerase reverse transcription; I-HCA, inflammatory adenoma; NGS, next generation sequencing; U-HCA, unclassified adenoma.

\*Shared first authorship.

†Shared senior authorship.

Preliminary findings were presented at the IHPBA 2020 Virtual Congress, the 14th World Congress of the International Hepato-Pancreato-Biliary Association, 27-29 November 2020.

This is an open access article under the terms of the Creative Commons Attribution-NonCommercial-NoDerivs License, which permits use and distribution in any medium, provided the original work is properly cited, the use is non-commercial and no modifications or adaptations are made.

© 2021 The Authors. *Liver International* published by John Wiley & Sons Ltd.

authors, none were declared.  
The research was not preregistered in an independent, institutional registry.

**Handling Editor:** Pierre Nahon

**Methods:** Dutch male patients with available histological slides with a (differential) diagnosis of HCA between 2000 and 2017 were identified through the Dutch Pathology Registry (PALGA). Histopathology and immunohistochemistry according to international guidelines were revised by two expert hepatopathologists. Next generation sequencing (NGS) was performed to confirm hepatocellular carcinoma (HCC) and/or subtype HCA. Final pathological diagnosis was correlated with recurrence, metastasis and death.

**Results:** A total of 66 patients from 26 centres fulfilling the inclusion criteria with a mean ( $\pm$ SD) age of  $45.0 \pm 21.6$  years were included. The diagnosis was changed after expert revision and NGS in 33 of the 66 patients (50%). After a median follow-up of 9.6 years, tumour-related mortality of patients with accessible clinical data was 1/18 (5.6%) in HCA, 5/14 (35.7%) in uncertain HCA/HCC and 4/9 (44.4%) in the HCC groups ( $P = .031$ ). Four B-catenin mutated HCA were identified using NGS, which were not yet identified by immunohistochemistry and expert revision.

**Conclusions:** Expert revision with relevant immunohistochemistry may help the challenging but prognostically relevant distinction between HCA and well-differentiated HCC in male patients. NGS may be more important to subtype HCA than indicated in present guidelines.

#### KEYWORDS

high-throughput nucleotide sequencing, immunohistochemistry, liver cell adenoma, male

## 1 | INTRODUCTION

Hepatocellular adenoma (HCA) is a benign liver tumour, occurring predominantly in females, but sporadically in males. The incidence of HCA in females who use oral contraceptives is estimated at 3–4 per 100 000 females.<sup>1</sup> Ten percent of all HCAs occur in men.<sup>2–4</sup> Over the past decades, however, the incidence of HCA in males appears to be rising mainly because of an increase in HCA-related risk factors, such as the use of anabolic steroids, and the prevalence of obesity and metabolic syndrome.<sup>5–11</sup>

HCA in general features different pathomolecular subtypes: inflammatory adenoma (I-HCA, 30% of all HCA), HNF-1 $\alpha$  (hepatocyte nuclear factor-1  $\alpha$ ) inactivated adenoma (H-HCA, 34%), B-catenin activated adenoma with *CTNNB1* exon 3 mutation (B<sup>ex3</sup>HCA, 8%), B-catenin activated adenoma with *CTNNB1* exon 7/8 mutation (B<sup>ex7,8</sup>HCA, 4%), B-catenin activated inflammatory adenoma with *CTNNB1* exon 3 mutation (B<sup>ex3</sup>IHCA, 8%), B-catenin activated inflammatory adenoma with *CTNNB1* exon 7/8 mutation (B<sup>ex7,8</sup>IHCA, 5%) and sonic hedgehog adenoma (sh-HCA, 4%).<sup>12</sup> When no known mutation is found, an HCA is termed unclassified (U-HCA, <7% of all HCA).<sup>13,14</sup>

The overall reported risk of malignant transformation of HCA is estimated at 4.2%.<sup>15</sup> Malignant transformation generally occurs in B<sup>ex3</sup>(I)HCA, with an odds ratio of 9.3 in the total, predominantly female, population.<sup>12,13</sup> Cases of malignant transformation of B<sup>ex7,8</sup>(I)HCA have also been reported.<sup>16</sup> There appears to be an overrepresentation of the B<sup>ex3</sup>(I)HCA subtype among men.<sup>12</sup> In males, up to 47% of HCA are described as having

### Lay summary

In the tissue of 66 Dutch male patients with potential HCA, we demonstrated that a histopathological diagnosis of HCA in male patients is difficult. Expert pathology revision, additional stainings and NGS are very helpful. NGS may be more important than indicated in current guidelines, especially to identify B-catenin activated HCA.

### Key points

- HCA in men without malignant features and favourable clinical outcomes may exist.
- Expert revision according to international guidelines aids adequate diagnosis.
- Next generation sequencing improves identification of high risk (B-catenin activated) subtypes.

undergone malignant transformation into hepatocellular carcinoma (HCC).<sup>13,17,18</sup>

According to European (European Association for the Study of the Liver, EASL) guidelines, HCA in men calls for different management as compared to HCA in females. In females with HCA, treatment including resection is only advocated in case of B(I)HCA and in HCA >5 cm that do not adequately regress after cessation of oral

contraceptives.<sup>3,12</sup> In males with HCA, however, resection is advised irrespective of molecular subtype or tumour size. Although this recommendation is based on a limited number of patients and the precise definition of malignant transformation remains debatable,<sup>19–25</sup> the recommendation to always resect HCA in males is generally accepted based on the high risk of and challenging differentiation with HCC.<sup>3,17,18</sup> The aim of the current study is to provide a nationwide overview of diagnosis and management of HCA in men in the Netherlands, correlating histopathological, immunohistochemical and molecular findings with the clinical course of the disease, thus providing one of the largest series of HCA in men to date.

## 2 | METHODS

### 2.1 | Study design

A nationwide observational cohort study was performed by searching the nationwide network and registry of histopathology and cytopathology in the Netherlands (PALGA: Dutch Pathology Registry) for pathology reports between 2000 and 2017.<sup>26</sup> Dutch search terms were 'liver' or 'hepatocellular' combined with 'adenoma' or 'carcinoma'. All male patients were included in whom a (differential) diagnosis of HCA was suspected on pathology (biopsy or resection specimens) at some point in the work-up and as such retrievable in the PALGA registry. Patients were excluded if no histological slides could be obtained for revision.

This study adheres to the ethical guidelines of the 1975 Declaration of Helsinki. The need for ethical approval was waived by the medical ethics committee of the Erasmus Medical Center (MEC-2017-405). The medical ethics committee of the Amsterdam University Medical Center (Amsterdam UMC) waived the need for a second assessment. Written informed consent was not required as clinical data were acquired anonymously from treating physicians. STROBE-guidelines were adhered to.

### 2.2 | Pathological classification

The diagnosis made in the primary centre was classified as HCA, uncertain HCA/HCC or preferential HCC. The term preferential HCC was used to underline that although these tumours were eventually diagnosed as HCC, the diagnosis of these patients was not straightforward and HCA was suspected at some point in the work-up.

Histological slides (hematoxylin and eosin [H&E]) and additional immunohistochemistry (if available) from biopsies and resection specimens were requested from the primary centre in which the patient was originally diagnosed. If available, resection specimens were used over biopsies to ensure the appropriate amount of tissue for additional stainings and next generation sequencing (NGS). Subsequently, additional stainings aiming to distinguish HCA and HCC and/or subclassify HCA, if not primarily performed, were performed (i.e., Gomorri, glutamine synthetase (GS), glypican-3, heat shock protein-70 (HSP70), B-catenin, liver fatty acid binding protein,

C-reactive protein and serum amyloid A).<sup>3,27,28</sup> Histology slides were revised in tandem by two expert liver pathologists (JV and MD), who were blinded for the diagnosis in the primary centre and clinical outcomes. Technical details are described in Supplementary Table 1.

### 2.3 | Next generation sequencing

If enough material was available, NGS was performed. For NGS, a liver-oriented gene panel was constructed using Ion AmpliSeq Designer version 7.06 (Thermo Fisher Scientific, Waltham, MA, USA), targeting genes were selected based on their suggested relevance in HCA and development to HCC in previous studies.<sup>12,29–33</sup> Template preparation was facilitated by the Ion Chef™ system and library preparation was performed manually according to instructions by the manufacturer (Thermo Fisher Scientific, Waltham, MA, USA). Sequencing was performed using the Ion GeneStudio™ S5 system (Thermo Fisher Scientific, Waltham, MA, USA), with an Ion 530 Chip (Thermo Fisher Scientific, Waltham, MA, USA). The target sequencing depth was 1500 reads. If the library concentration was below 100 ng/μL, the DNA was considered low quality. A mutation was considered significant if it was present in more than 5% of the reads and was not present in the reference genome hg19/GRCh37 (Genome Reference Consortium, February 2009).<sup>34,35</sup> Analyses of relevant DNA variants were performed using SEQNEXT version 4.2.1 (JSI medical systems GmbH, Ettenheim, Germany).

### 2.4 | Final diagnosis and subtype classification

Based on expert revision of morphology, additional immunohistochemistry and (eventually) NGS, final diagnoses were formulated. Tumours were classified as HCA, uncertain HCA/HCC or HCC. According to the WHO classification, tumours were classified as HCC if features were present such as small cell change, nuclear atypia, pseudoglandular formation and/or loss of reticulin fibres.<sup>36</sup> Moreover, if performed, two out of three positive stainings for GS, HSP70 and/or positive glypican-3 (GPC3) were considered to be diagnostic for HCC.<sup>27,28,37–39</sup> On the molecular level, human telomerase reverse transcription (*hTERT*) promoter mutation supported malignant transformation towards HCC, being a late genetic event in the mutational process of malignant transformation of HCA.<sup>28,30,40,41</sup> The diagnosis of HCA was reserved for hepatocellular tumours without any features indicative of malignancy.

Hepatocellular tumours were classified as uncertain HCA/HCC if they had increased cytonuclear atypia, small cell changes, increase in thickness of the liver cell plates ('reticulin loss') and/or pseudoglandular formation not sufficiently convincing for the diagnosis of HCC, yet too atypical to be classified as HCA, without expression of two out of three diagnostic HCC markers (GS, HSP70, GPC3) and without *hTERT* mutations. Uniform terminology and definitions of tumours in which the diagnosis is inconclusive remain an important topic of debate.<sup>19–25</sup> In the current study, if a focus or foci of unequivocal HCC within a tumour were seen that fulfilled the HCC criteria, these lesions were classified

in toto as HCC, because surrounding lesional tissue could not be classified reliably into either (atypical) HCA or well-differentiated HCC.

Diagnostic methods to confirm sh-HCA were unavailable. Classification of the other HCA subtypes (I-HCA, H-HCA, B<sup>ex3</sup>HCA, B<sup>ex7,8</sup>HCA, B<sup>ex3</sup>IHCA, B<sup>ex7,8</sup>IHCA, U-HCA) was based on the World Health Organization criteria and EASL-guidelines.<sup>3,42</sup>

## 2.5 | Phenotype data

Clinical data were requested from the treating physicians and were stored anonymously. The following data were collected: age at diagnosis, body mass index (BMI), (history of) sex hormone usage, underlying liver disease, initial size of the tumour on imaging (largest diameter according to the revised RECIST guidelines 1.1), presence of solitary or multiple tumours and date of diagnosis.<sup>43</sup> Primary outcomes were liver-only tumour recurrence, distant metastasis and death. If these outcomes occurred, available data on the timing of recurrence, metastasis and death were recorded.

## 2.6 | Statistical analyses

Statistical analyses were performed with IBM SPSS Statistics for Windows, version 25.0 (IBM Corp., Armonk, NY, USA). Visual representation of the data was designed using GraphPad Prism version 8.0.2 for Windows (GraphPad Software, San Diego, CA, USA).

Baseline characteristics and outcomes were reported according to the revised pathology diagnosis (HCA, uncertain HCA/HCC or HCC). Dichotomous variables (i.e., presence of hormone use and underlying liver disease, or occurrence of recurrence, metastasis, and death) were reported as numerators and denominators, and percentages were calculated. Normality of continuous data (i.e., age at diagnosis, BMI, tumour size and follow-up time) was assessed by histograms, Q-Q plots and a Kolmogorov-Smirnov test. These data were reported as medians with their interquartile range (IQR), or means with their standard deviation (SD), as appropriate.

Dichotomous variables were compared across the three revised diagnosis groups using a Fisher-Freeman-Halton exact test for dichotomous variables. Normally distributed continuous data were compared across the three groups using a one-way ANOVA for continuous variables. For the primary analyses, *P*-values <.05 were considered statistically significant. If a statistically significant difference was found, post-hoc pairwise comparisons were performed with Bonferroni correction.

Analyses of the primary outcomes (liver-only tumour recurrence, distant metastases and death) were treated as dichotomous variables. As this was a descriptive study and this method of analysis adequately reflected the presence of patients who reached the primary outcome with an unclear time to event, this was considered more appropriate than a survival analysis (added as a supplementary analysis). Follow-up times were calculated as the date of diagnosis until date of last hospital visit or death. If available, data on timing of recurrence and metastases in relation to the date of surgery or date of diagnosis was reported separately.

## 3 | RESULTS

### 3.1 | Patient selection and baseline clinical characteristics

The search yielded a total of 5971 patients, identifying 104 male patients with a (differential) diagnosis of HCA. Several centres did not supply material or data, resulting in a total of 66 inclusions from 26 centres (Figure 1). Of the 32 patients of whom resection specimens were available, nine eventually underwent liver transplantation and thirteen had undergone biopsy prior to resection. In 34 patients, only biopsies of the tumour were available.

Clinical data were available for 41/66 patients (62%) from 12 centres (Table 1, baseline characteristics). Mean age at diagnosis was 45.0 ± 21.6 years, mean BMI 25.8 ± 5.6 kg/m<sup>2</sup> and mean tumour size was 6.1 ± 3.9 cm. In 18/41 (44%) patients, any type of underlying liver disease coexisted. The underlying liver diseases across all groups were diverse as shown in Supplementary Table 4. Only two patients had a history of hormone use. Solitary tumours were found in 19/41 (46%) patients.

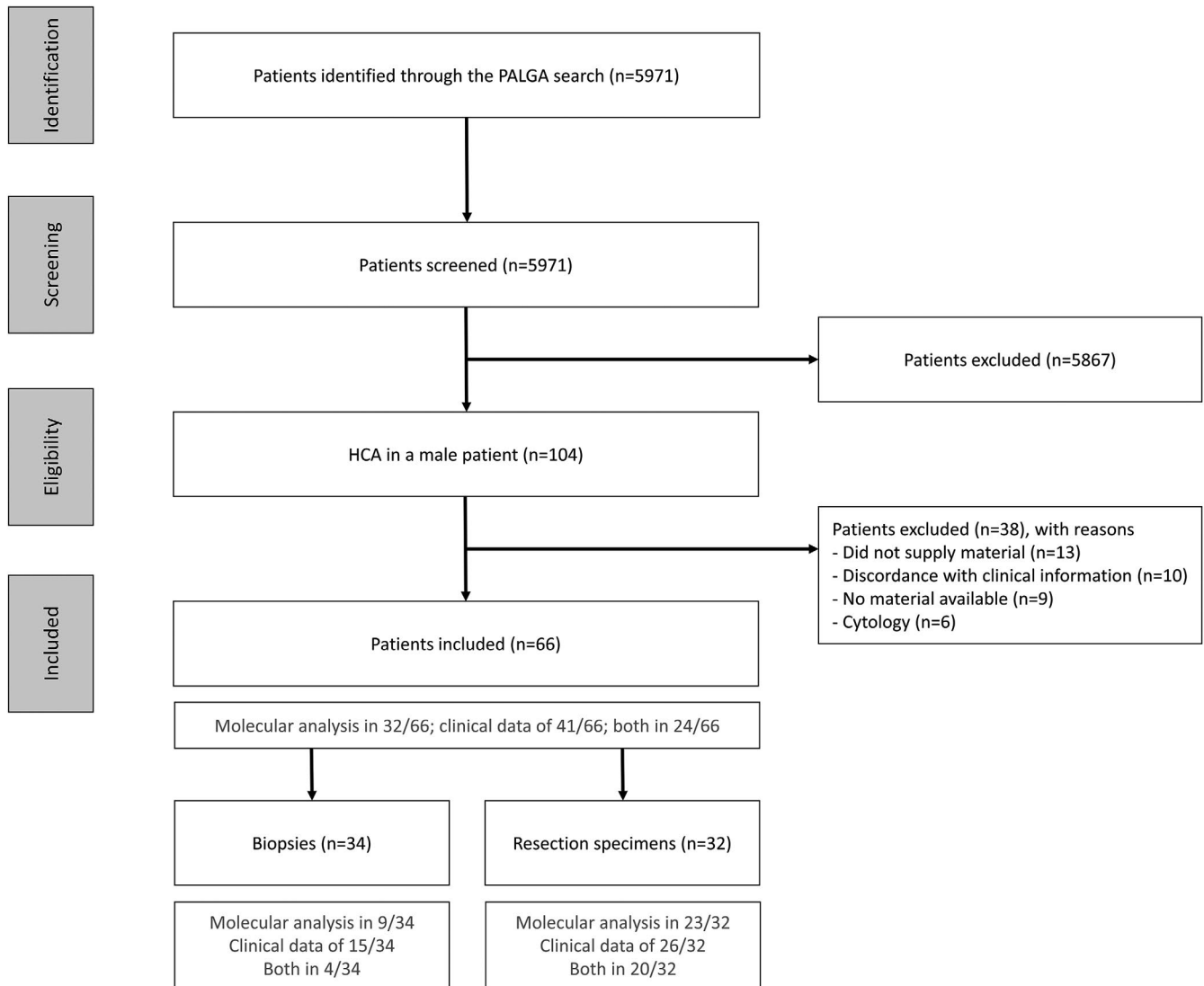
### 3.2 | Primary diagnosis and revised diagnosis

In the primary centre, the initial diagnoses were 22 HCA (33%), 34 uncertain HCA/HCC (52%) and 10 preferential HCC (15%). In total, 33/66 (50%) of the diagnoses made in the primary centre were revised to any extent after expert revision with aid of additional immunohistochemistry and NGS. In 3/22 lesions (14%) defined as HCA in the primary centre, the diagnosis of HCC was established after expert revision. Six HCA patients (27%) were reclassified as uncertain HCA/HCC. Five of the ten patients with a preferential HCC diagnosis (50%) were classified as uncertain HCA/HCC. Nineteen of the 34 (56%) uncertain lesions could be definitively classified as either HCA (*n* = 7) or HCC (*n* = 12). To summarise, tumours were reclassified as follows: 20 HCA (30%), 26 uncertain HCA/HCC (39%) and 20 HCC (30%). These changes of diagnosis are depicted in Figure 2.

Expert revision and immunohistochemistry contributed significantly to these changes in diagnosis. An overview of immunohistochemistry performed in the primary centres is shown in Supplementary Figure 1. In only 8/66 (12%) of patients, all markers considered diagnostic for HCC (GS, GPC3 and HSP70) were indeed all performed. After expert revision, in 55/66 (83%) patients GS, GPC3 and HSP70 stainings could be completed in the study.

In most patients with uncertain HCA/HCC, all stainings were performed after expert revision (19/26, 73%). These stainings were generally all negative in this group; only four cases had diffuse heterogeneous GS-staining with a negative HSP70 and GPC3.

Additional NGS was performed on materials of 32/66 patients (48%) and contributed to the final classification in one patient. This patient had a tumour that was classified as uncertain HCA/HCC based on morphology, yet a *hTERT* mutation was found which resulted in a reclassification to HCC as final diagnosis. Although the



**FIGURE 1** Flowchart of the inclusion of patients and availability of data

diagnosis of the other 31 patients did not change after NGS, it did aid in subclassification of HCA which will be discussed below.

### 3.3 | Hepatocellular adenoma: Subtypes and next generation sequencing

After immunohistochemistry and NGS, the 20 HCA were categorised into H-HCA ( $n = 4$ ), I-HCA ( $n = 3$ ), B<sup>ex3</sup>IHCA ( $n = 3$ ), B<sup>ex8</sup>IHCA ( $n = 4$ ) and U-HCA ( $n = 6$ ) (Figure 3 and Supplementary Table 2). Three patients had not enough tissue to complete all stainings and NGS: two were classified as U-HCA and the third was suspected to be H-HCA solely based on morphology. Five patients were classified as H-HCA ( $n = 1$ ), I-HCA ( $n = 2$ ) and U-HCA ( $n = 2$ ) on immunohistochemistry without NGS.

In 12 HCA patients with a sufficient amount of tissue, NGS complemented immunohistochemistry. In five of these patients, the suspected subtypes were in line with the findings on NGS. These

were H-HCA ( $n = 2$ ), I-HCA ( $n = 1$ ) and U-HCA ( $n = 2$ ). NGS yielded additional value in 7/12 HCA. In 3 patients, the type (exon) of an immunohistochemically suspected *CTNNB1* mutation was determined. In 4 patients with suspected I-HCA, additional *CTNNB1* mutations were found; 2 in exon 3 and 2 in exon 8. However, in 2 cases, immunohistochemically suspected inflammatory mutations could not be identified. Notably, all B-catenin activated HCA were accompanied by an inflammatory component and no B<sup>ex7</sup>(I)HCA was identified.

### 3.4 | Uncertain HCA/HCC: Next generation sequencing

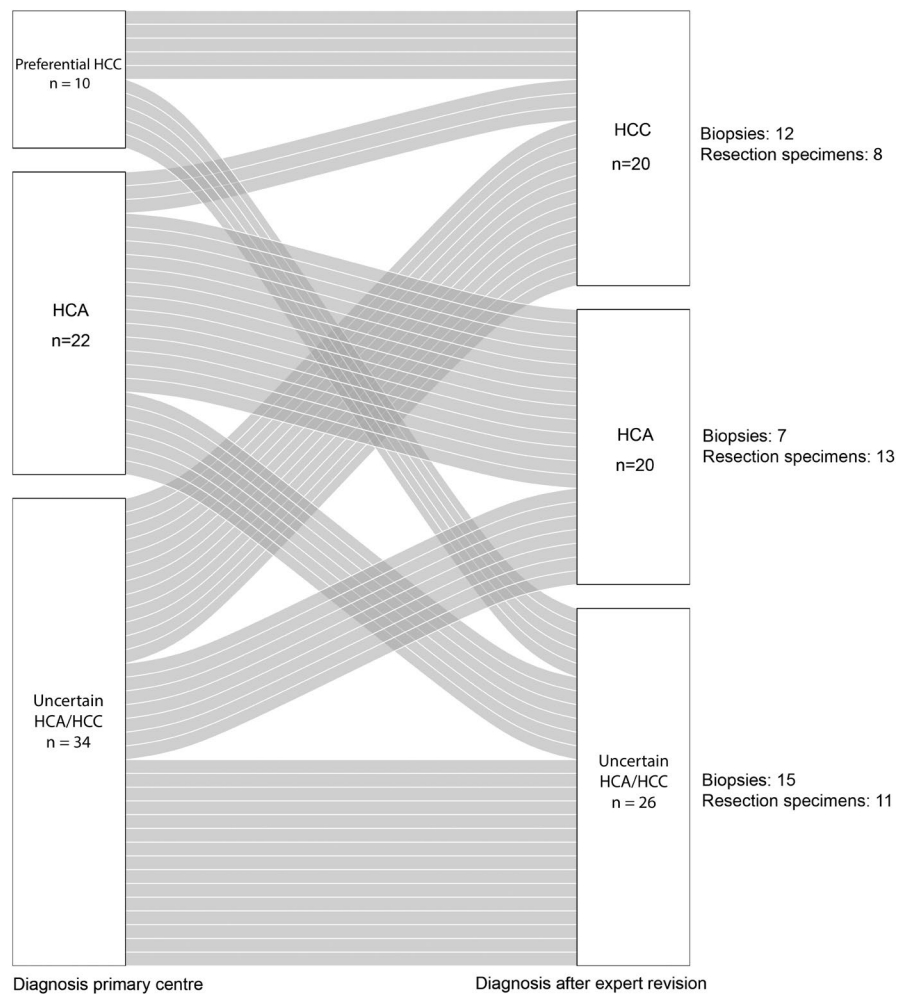
Some of the 26 uncertain HCA/HCC showed characteristics on immunohistochemistry or NGS attributable to certain HCA subtypes. One uncertain HCA/HCC showed features resembling a BIHCA on immunohistochemistry, including a positive GS staining, with NGS indeed showing *CTNNB1* exon 7 and *IL6ST* (interleukin 6 signal

**TABLE 1** Baseline characteristics of patients with a final diagnosis of HCA, uncertain HCA/HCC and HCC

	Total (n = 66)		HCA (n = 20)		Uncertain (n = 26)		HCC (n = 20)		P value
	Value	N	Value	n	Value	n	Value	n	
Age in years (mean, SD)	45.0 (21.6)	40	37.4 (18.0)	17	43.7 (23.0)	14	61.4 (18.3)	9	<b>.021</b>
BMI in kg/m <sup>2</sup> (mean, SD)	25.8 (5.6)	32	24.5 (4.8)	14	25.8 (6.7)	12	28.9 (4.1)	6	.289
Tumour size in cm (mean, SD)	6.1 (3.9)	39	6.3 (3.9)	18	6.6 (4.6)	13	4.7 (2.7)	8	.524
Hormone use (n, %)	2 (4.9)	41	1 (5.6)	18	0 (0)	14	1 (11)	9	.693
Underlying liver disease (n, %)	18 (44)	41	6 (33)	18	10 (71)	14	2 (22)	9	<b>.035</b>
Solitary tumours (n, %)	19 (46)	41	9 (50)	18	5 (36)	14	5 (56)	9	.666

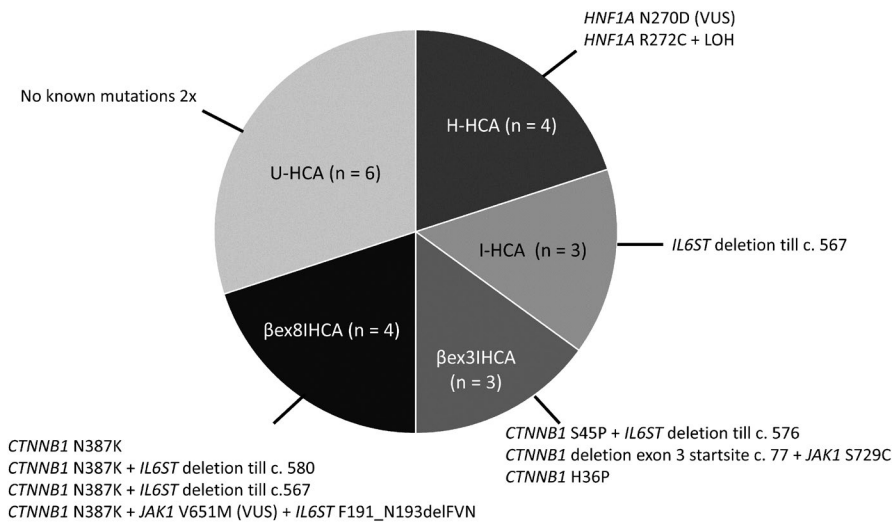
Values in bold indicate statistically significant results ( $P < .05$ ).

Abbreviations: HCA, hepatocellular adenoma; HCC, hepatocellular carcinoma; Uncertain, uncertain HCA/HCC.

**FIGURE 2** Diagnosis in the primary centre, compared to the revised diagnosis

transducer) mutations. Another showed features of B-HCA on immunohistochemistry, with positive GS- and B-catenin stainings, with NGS showing only an *IL6ST* mutation. In addition, mutations were identified by NGS in the following genes (Supplementary Table 3):

*HNF1A* (hepatocyte nuclear factor 1 homeobox A, n = 2), *CTNNB1* exon 7 (n = 1), *MTOR* (mammalian target of rapamycin) and *IL6ST* (n = 1) and *CDKN2A* (cyclin-dependent kinase inhibitor 2A, n = 1). The patient with the *CTNNB1* exon 7 mutation identified on NGS



**FIGURE 3** Subtypes of the 20 patients with HCA. The pie chart shows found subtypes and their occurrence. Around the pie chart, the results of NGS of 12 patients are shown. Abbreviations: LOH, loss of heterozygosity; VUS, variant of uncertain significance identified

**TABLE 2** Treatment and outcomes of patients with a final diagnosis of HCA, uncertain HCA/HCC and HCC

	Total (n = 66)		HCA (n = 20)		Uncertain (n = 26)		HCC (n = 20)		P value
	Value	n	Value	n	Value	N	Value	n	
Follow-up in months (mean, SD)	53 (47)	41	45 (36)	18	50 (50)	14	71 (61)	9	.416
Treatment with curative intent (n, %)	34 (83)	41	15 (83)	18	11 (79)	14	8 (89)	9	1.000
Recurrence or metastasis (n, %)	6 (15)	41	0 (0)	18	3 (21)	14	3 (33)	9	.023
All-cause mortality (n, %)	10 (24)	41	1 (5.6)	18	5 (36)	14	4 (44)	9	.031

Values in bold indicate statistically significant results ( $P < .05$ ).

Abbreviations: HCA, hepatocellular adenoma; HCC, hepatocellular carcinoma; Uncertain, uncertain HCA/HCC.

had negative GS- and B-catenin stainings. Mutations in *CTNNB1* exon 7 were exclusively found in the uncertain HCA/HCC group.

### 3.5 | Hepatocellular carcinoma: Next generation sequencing

In 4 of 9 HCCs undergoing NGS, *hTERT* promotor mutations were found. In 3 patients, the diagnosis of HCC was already definitive, based on morphological criteria and relevant stainings without additional NGS. In 1 patient, finding the *hTERT* mutation was decisive. Two patients had additional mutations accompanying the *hTERT* mutation; in *CTNNB1* exon 3 and *ALB* (albumin) respectively. One other patient showed a mutation in *CTNNB1* exon 3 without *hTERT* mutation. Both HCC patients with proven *CTNNB1* exon 3 mutations showed GS-positivity, and one also had a positive B-catenin staining. All results of NGS are shown in Supplementary Table 3.

### 3.6 | Baseline characteristics, treatment and clinical outcomes across the revised diagnosis groups

Across the three revised diagnosis groups, no differences were seen in BMI, tumour size, hormone use or the number of tumours

(solitary vs multiple). A difference in age ( $P = .021$ ) was seen across the three groups, mostly because of the older age of patients with HCC ( $61.4 \pm 18.3$  years) as compared to patients with HCA ( $37.4 \pm 18.0$  years, Supplementary Table 5 and Supplementary Figure 2). Across the 3 groups, a difference was also seen in the presence of underlying liver disease ( $P = .033$ ). Uncertain HCA/HCC appeared to show an overrepresentation of underlying liver disease (10/41 patients, 71%), as compared to HCA (6/18, 33%) and HCC (2/9, 22%, Supplementary Tables 4 and 5). In the uncertain HCA/HCC group, both HCA risk factors (glycogen storage disease [GSD] type 1) as well as known HCC risk factors (hepatitis-based cirrhosis) were observed. Viral hepatitis was not observed in the HCA group, and alcoholic liver disease was not seen in any patients.

Clinical outcomes of patients across the 3 revised diagnosis groups are shown in Table 2. Patients ( $n = 41$ ) underwent the following treatments: surgical resection (total  $n = 17$ , HCA  $n = 9$ ), liver transplantation (total  $n = 9$ , HCA  $n = 4$ ), radiofrequency ablation (total  $n = 3$ , HCA  $n = 0$ ), transarterial (chemo-)embolization (total  $n = 2$ , HCA  $n = 1$ ), a combination of surgical treatment and other type of treatment (total  $n = 3$ , HCA  $n = 1$ ) or no treatment (total  $n = 7$ , HCA  $n = 3$ ). Almost all (8/9) patients undergoing liver transplantation had underlying liver disease. In Supplementary Table 4, the occurrence of liver transplantation is shown according to the



type of underlying liver disease and final diagnosis group. No metastasis or death was observed in the HCA patients who did not receive treatment. Details are described in Table 3.

After a median follow-up of 117 (IQR; 55-173), 99.5 (IQR; 40.5-158) and 145 (IQR; 77.5-179.5) months, recurrence or metastasis occurred in 0/18 (0%), 3/14 (21%) and 3/9 (33%) of the patients with a revised diagnosis of HCA, uncertain HCA/HCC and HCC respectively ( $P = .023$ ). Death differed across the three groups ( $P = .031$ ) and was observed in 1/18 (5.6%), 5/14 (36%) and 4/9 (44%) of patients with HCA, uncertain HCA/HCC and HCC respectively (Supplementary Table 5 shows post-hoc analyses). The cause of death of the patient who died in the HCA group was a complication related to his liver

transplantation. Supplementary Figure 3 shows survival analyses within the diagnosis groups. Details on all patients with recurrence or metastasis and patients who died are shown in Table 3.

## 4 | DISCUSSION

The occurrence of HCA in men is extremely rare. In this study, tissue of 66 male cases were studied and 20 patients with a final diagnosis of HCA were identified in a course of 18 years in the Netherlands. Thus, this is the largest cohort of HCA focused on male patients correlating pathological findings with the clinical course to date. Fifty

**TABLE 3** Description of 14 patients with recurrence, metastasis or death in clinical follow-up, according to final diagnosis

Nr	Age (y)	S/M	Size (mm)	Underlying liver disease	Treatment	Recurrence or metastasis	Death (time after diagnosis)
HCA							
1	38	M	38	Peliosis hepatitis	LTx	No	Because of LTx (1.5 y)
Uncertain HCA/HCC							
1	63	M	37	No	TAE	R: time unknown M: time unknown, to lymph nodes	Cause unknown (4 y)
2	70	S	65	No	No	N/A	Because of HCC (unknown)
3	45	S	22	Cirrhosis, hepatitis C	No	N/A	Because of sepsis (2.5 y)
4	62	S	34	No	No	N/A	Because of heart attack (2 wk)
5	26	S	20	Cirrhosis, hepatitis B	RFA	No	Cause unknown (1 y)
6	72	M	50	Hepatitis B	RFA and open resection	R: 6 mo after surgery MT: 5.5 y after surgery, to thoracic wall	No
7	70	S	120	NASH	Sorafenib and open resection	MT: 2 y after surgery, to lung	No
HCC							
1	69	M	20	Cirrhosis, hepatitis C	RFA	R: 10 mo after diagnosis	Because of HCC (3.5 y)
2	62	M	NA	No	LTx	No	Because of HCC (unknown)
3	76	S	59	No	Open resection	No	Cause unknown (>5 y)
4	79	S	85	No	Open resection	No	Cause unknown (unknown)
5	35	M	70	No	Laparoscopic resection and TAE	R: 5 y after surgery, treated by LTx MT: 10 y after surgery, to peritoneum	No
6	69	S	51	No	Open resection	R: 8 y after surgery	No

Abbreviations: HCA, hepatocellular adenoma; HCC, hepatocellular carcinoma; LTx, liver transplantation; M, multiple; MT, metastasis; N/A, not applicable; NASH, non-alcohol steatohepatitis; R, recurrence; RFA, radiofrequency ablation; S, solitary; S/M, solitary or multiple tumours; TAE, transarterial embolization; wk, weeks; y, years.

percent of the initial diagnoses were revised to any extent, which reflects the difficulty in the differentiation between HCA and well-differentiated HCC. In 1 patient, NGS identified a *hTERT* mutation in a tumour classified as unknown HCA/HCC on morphological and immunohistochemical grounds, thereafter revised to HCC. All other changes in diagnosis were attributable to expert revision, including additional immunohistochemistry, with an increase in percentage of patients with complete stainings from 12% (primary centre) to 83% (after expert revision). Even after expert revision and with additional relevant stainings and/or NGS, in 39% (26/66) of the patients, HCC could not be distinguished from HCA with certainty.

Current EASL-guidelines consider HCA in male patients high-risk for malignancy, and therefore advocate resection.<sup>3</sup> In the current study, the group with final diagnosis of HCA showed no tumour-related mortality and no tumour recurrence. The low recurrence and mortality rates in male HCA patients suggest that with adequate classification, a low-risk subgroup in men may exist. However, considering the small cohort size of this study and the risk of sampling error at biopsy, it is not safe to assume that HCA in male patients can be treated conservatively.

Considering the higher age in the HCC and uncertain HCA/HCC group, one could argue that the malignant potential of HCA is underestimated because the process of malignant transformation takes many years, far beyond the follow-up time of this (and any other) study. However, HCC associated with other HCC risk factors may also take years to develop. Thus, this also suggests that in older male patients the preferred diagnosis of HCC should be considered.<sup>44</sup> This is further supported by the finding that viral hepatitis was only seen in the uncertain HCA/HCC and HCC groups. An unequivocal HCA diagnosis in patients with underlying liver disease, remarkably seen in 6 patients in the current study, has previously been described.<sup>45</sup> Despite the presence of underlying liver disease, recurrence and mortality rates remained low in this group. It is possible that the presence of underlying liver disease guided the choice for liver transplantation rather than oncological curative resection, and thus may have prevented recurrences in susceptible livers. The only death in the HCA group was caused by complications related to a liver transplantation. Moreover, underlying liver disease may include known HCA risk factors.

In the present cohort, NGS showed additional value mainly in the identification of *CTNNB1* mutations encoding B-catenin. In 4 HCA patients and one uncertain HCA/HCC patient in whom immunohistochemistry (GS and B-catenin) was negative, NGS identified additional *CTNNB1* mutations. These were two exon 3 and two exon 8 *CTNNB1* mutations in the HCA patients, and an exon 7 *CTNNB1* mutation in the uncertain HCA/HCC patient. The identification of a B-catenin mutation has important prognostic value, indicating a higher risk of malignant transformation. In female patients, HCA subtyping has a major impact on treatment decisions.

This study has several strengths. First, the PALGA registry has provided us with means to identify all patients across the Netherlands, resulting in a representative population of Dutch males

diagnosed with HCA over the last 2 decades. Second, focusing on this specific group enabled a detailed data accumulation of this extremely rare entity, culminating in (one of) the largest series focusing on male HCA patients.<sup>2,12,17,46</sup> Finally, the used combination of expert revision, including relevant immunohistochemistry, and NGS provided a successful strategy to correctly classify hepatocellular tumours in men.

A limitation of this study is that it was not possible to detect sonic hedgehog HCA. Staining of prostaglandin D2 synthase (PTGDS) and argininosuccinate synthetase 1 (*ASS1*) were not performed.<sup>12,47-49</sup> Moreover, the *INHBE/GLI1* (inhibin B E/glioma-associated oncogene 1) fusion gene, characterised by focal deletions that fuse the promoter of *INHBE* with *GLI1* which activates the sonic hedgehog pathway, is undetectable by NGS, as NGS is unable to detect large deletions. Although NGS was helpful in the identification of additional B-catenin mutations, we can also not exclude that NGS might have missed other large deletions, including those of the *CTNNB1* gene. Other imperfections were introduced by the design, retrospectively including patients in 26 centres across a period of 20 years: not all clinical data were retrievable, and available tissue of biopsies was limited in amount, so there was not always enough tissue left to perform full assessment, especially NGS.

In conclusion, expert revision together with immunohistochemistry according to guidelines was shown to help in the adequate differentiation and subtyping of HCA and HCC in male patients. NGS may be more important than indicated in current guidelines, especially to identify B-catenin mutated HCA, both exon 3 and exon 7/8, that may be missed otherwise. Although resection of all HCA in male patients remains advisable, after expert revision and NGS, HCA without signs of malignancy may exist in men with more favorable outcomes than uncertain HCA/HCC and HCC. To enable future research in this extremely rare group of patients, international collaboration is essential.

## ACKNOWLEDGEMENTS

Collaborators on behalf of the Dutch Benign Liver Tumor Group:

Amsterdam UMC, Location AMC (University of Amsterdam), Amsterdam: *Dr J I Erdmann (surgeon)*, *T G J M Dirksen (technician histopathology)*; Deventer Hospital, Deventer: *Dr H Torrenge (surgeon)*; Amphia Hospital, Breda: *Dr P D Gobardhan (surgeon)*; Diakonessenhuis Hospital, Utrecht: *Dr L van Huis-Tanja (oncologist)*, *Dr Smakman (surgeon)*; Leiden University Medical Center, Leiden: *Dr A Inderson (gastroenterologist)*, *Prof. Dr B van Hoek (gastroenterologist)*; Maasstad Hospital, Rotterdam: *Dr M C Buis (gastroenterologist)*; Northwest Clinics, Location Alkmaar, Alkmaar: *Dr A P J Houdijk (surgeon)*; OLVG Hospital, Location Oost, Amsterdam: *Dr H A Marsman (surgeon)*; Gelderse Vallei Hospital in Ede: *Dr C Sietses (surgeon)*; University Medical Center Groningen: *Prof. Dr A S H Gouw (pathologist)*.

## CONFLICTS OF INTEREST

None declared.

## AUTHOR CONTRIBUTIONS

BVvR, AJK, RAdM, JNMIJ, MD, TMvG and JV conceived the ideas or experimental design of the study; BVvR, AF, AJK, MET, AEB, RJR, MAPL, MPDH, VEdM, TvV, RBT, CHCD, RAdM, JNMIJ, MD, TMvG and JV performed data collection; BVvR, AF, RJR, MD and JV performed data analyses and interpretation; BVvR, AF, AJK, RJR, MD, TMvG and JV drafted the paper; BVvR, AF, AJK, MET, AEB, RJR, MAPL, MPDH, VEdM, TvV, RBT, CHCD, RAdM, JNMIJ, MD, TMvG and JV provided revisions to scientific content to the manuscript and gave final approval of the version to be published.

## ORCID

Belle V. van Rosmalen  <https://orcid.org/0000-0002-4507-7189>

Alicia Furumaya  <https://orcid.org/0000-0001-5897-0438>

Anne J. Klompenhouwer  <https://orcid.org/0000-0002-6740-3862>

Maarten E. Tushuizen  <https://orcid.org/0000-0001-6342-9056>

Andries E. Braat  <https://orcid.org/0000-0003-3615-2690>

Martijn P. D. Haring  <https://orcid.org/0000-0003-4789-3910>

Jan N. M. IJzermans  <https://orcid.org/0000-0003-3558-1039>

## REFERENCES

- Rooks JB, Ory HW, Ishak KG, et al. Epidemiology of hepatocellular adenoma: the role of oral contraceptive use. *JAMA*. 1979;242(7):644-648. <https://doi.org/10.1001/jama.1979.03300070040020>
- Bossen L, Grønbaek H, Lykke Eriksen P, Jepsen P. Men with biopsy-confirmed hepatocellular adenoma have a high risk of progression to hepatocellular carcinoma: a nationwide population-based study. *Liver Int*. 2017;37(7):1042-1046. <https://doi.org/10.1111/liv.13423>
- EASL clinical practice guidelines on the management of benign liver tumours. *J Hepatol*. 2016;65(2):386-398. <https://doi.org/10.1016/j.jhep.2016.04.001>
- Ronald M, Woodfield J, McCall J, Koea J. Hepatic adenomas in male patients. *HPB (Oxford)*. 2004;6(1):25-27. <https://doi.org/10.1080/13651820310020846>
- Bioulac-Sage P, Taouji S, Possenti L, Balabaud C. Hepatocellular adenoma subtypes: the impact of overweight and obesity. *Liver Int*. 2012;32(8):1217-1221. <https://doi.org/10.1111/j.1478-3231.2012.02786.x>
- Bunchorntavakul C, Bahirwani R, Drazek D, et al. Clinical features and natural history of hepatocellular adenomas: the impact of obesity. *Aliment Pharmacol Ther*. 2011;34(6):664-674. <https://doi.org/10.1111/j.1365-2036.2011.04772.x>
- Cohen C, Lawson D, DeRose PB. Sex and androgenic steroid receptor expression in hepatic adenomas. *Hum Pathol*. 1998;29(12):1428-1432. [https://doi.org/10.1016/S0046-8177\(98\)90011-9](https://doi.org/10.1016/S0046-8177(98)90011-9)
- Creagh TM, Rubin A, Evans DJ. Hepatic tumours induced by anabolic steroids in an athlete. *J Clin Pathol*. 1988;41(4):441. <https://doi.org/10.1136/jcp.41.4.441>
- Dokmak S, Belghiti J. Will weight loss become a future treatment of hepatocellular adenoma in obese patients? *Liver Int*. 2015;35(10):2228-2232. <https://doi.org/10.1111/liv.12925>
- Grangé JD, Guéchet J, Legendre C, Giboudeau J, Darnis F, Poupon R. Liver adenoma and focal nodular hyperplasia in a man with high endogenous sex steroids. *Gastroenterology*. 1987;93(6):1409-1413. [https://doi.org/10.1016/0016-5085\(87\)90273-3](https://doi.org/10.1016/0016-5085(87)90273-3)
- Chang CY, Hernandez-Prera JC, Roayaie S, Schwartz M, Thung SN. Changing epidemiology of hepatocellular adenoma in the United States: review of the literature. *Int J Hepatol*. 2013;2013:1-7. <https://doi.org/10.1155/2013/604860>
- Nault JC, Couchy G, Balabaud C, et al. Molecular classification of hepatocellular adenoma associates with risk factors, bleeding, and malignant transformation. *Gastroenterology*. 2017;152(4):880-894. <https://doi.org/10.1053/j.gastro.2016.11.042>
- Nault JC, Paradis V, Cherqui D, Vilgrain V, Zucman-Rossi J. Molecular classification of hepatocellular adenoma in clinical practice. *J Hepatol*. 2017;67(5):1074-1083. <https://doi.org/10.1016/j.jhep.2017.07.009>
- Vedie AL, Sutter O, Zioli M, Nault JC. Molecular classification of hepatocellular adenomas: impact on clinical practice. *Hepat Oncol*. 2018;5(1):HEP04. <https://doi.org/10.2217/hep-2017-0023>
- Stoot JH, Coelen RJ, De Jong MC, Dejong CH. Malignant transformation of hepatocellular adenomas into hepatocellular carcinomas: a systematic review including more than 1600 adenoma cases. *HPB (Oxford)*. 2010;12(8):509-522. <https://doi.org/10.1111/j.1477-2574.2010.00222.x>
- Klompenhouwer AJ, Thomeer MGJ, Dinjens WNM, de Man RA, IJzermans JNM, Doukas M. Phenotype or genotype: decision-making dilemmas in hepatocellular adenoma. *Hepatology*. 2019;70(5):1866-1868. <https://doi.org/10.1002/hep.30812>
- Dokmak S, Paradis V, Vilgrain V, et al. A single-center surgical experience of 122 patients with single and multiple hepatocellular adenomas. *Gastroenterology*. 2009;137(5):1698-1705. <https://doi.org/10.1053/j.gastro.2009.07.061>
- Farges O, Ferreira N, Dokmak S, Belghiti J, Bedossa P, Paradis V. Changing trends in malignant transformation of hepatocellular adenoma. *Gut*. 2011;60(1):85-89. <https://doi.org/10.1136/gut.2010.222109>
- Balabaud C, Bioulac-Sage P, Ferrell L, et al. Well-differentiated hepatocellular neoplasm of uncertain malignant potential. *Hum Pathol*. 2015;46(4):634-635. <https://doi.org/10.1016/j.humpath.2014.10.029>
- Bedossa P, Burt AD, Brunt E, et al. Well-differentiated hepatocellular neoplasm of uncertain malignant potential—reply. *Hum Pathol*. 2015;46(4):635-636. <https://doi.org/10.1016/j.humpath.2014.10.030>
- Bedossa P, Burt AD, Brunt EM, et al. Well-differentiated hepatocellular neoplasm of uncertain malignant potential: proposal for a new diagnostic category. *Hum Pathol*. 2014;45(3):658-660. <https://doi.org/10.1016/j.humpath.2013.09.020>
- Evason KJ, Grenert JP, Ferrell LD, Kakar S. Atypical hepatocellular adenoma-like neoplasms with beta-catenin activation show cytogenetic alterations similar to well-differentiated hepatocellular carcinomas. *Hum Pathol*. 2013;44(5):750-758. <https://doi.org/10.1016/j.humpath.2012.07.019>
- Kakar S, Evason KJ, Ferrell LD. Well-differentiated hepatocellular neoplasm of uncertain malignant potential: proposal for a new diagnostic category—reply. *Hum Pathol*. 2014;45(3):660-661. <https://doi.org/10.1016/j.humpath.2013.09.019>
- Kakar S, Grenert JP, Paradis V, Pote N, Jakate S, Ferrell LD. Hepatocellular carcinoma arising in adenoma: similar immunohistochemical and cytogenetic features in adenoma and hepatocellular carcinoma portions of the tumor. *Mod Pathol*. 2014;27(11):1499-1509. <https://doi.org/10.1038/modpathol.2014.50>
- Beaufrière A, Paradis V. Hepatocellular adenomas: review of pathological and molecular features. *Hum Pathol*. 2020. <https://doi.org/10.1016/j.humpath.2020.11.016>
- Casparie M, Tiebosch AT, Burger G, et al. Pathology databanking and biobanking in the Netherlands, a central role for PALGA, the nationwide histopathology and cytopathology data network and archive. *Cell Oncol*. 2007;29(1):19-24. <https://doi.org/10.1155/2007/971816>
- Pathologic diagnosis of early hepatocellular carcinoma: a report of the international consensus group for hepatocellular neoplasia. *Hepatology*. 2009;49(2):658-664. <https://doi.org/10.1002/hep.22709>

28. Galle PR, Forner A, Llovet JM, et al. EASL clinical practice guidelines: management of hepatocellular carcinoma. *J Hepatol*. 2018;69(1):182-236. <https://doi.org/10.1016/j.jhep.2018.03.019>
29. Bluteau O, Jeannot E, Bioulac-Sage P, et al. Bi-allelic inactivation of TCF1 in hepatic adenomas. *Nat Genet*. 2002;32(2):312-315. <https://doi.org/10.1038/ng1001>
30. Nault JC, Mallet M, Pilati C, et al. High frequency of telomerase reverse-transcriptase promoter somatic mutations in hepatocellular carcinoma and preneoplastic lesions. *Nat Commun*. 2013;4:2218. <https://doi.org/10.1038/ncomms3218>
31. Pilati C, Amessou M, Bihl MP, et al. Somatic mutations activating STAT3 in human inflammatory hepatocellular adenomas. *J Exp Med*. 2011;208(7):1359-1366. <https://doi.org/10.1084/jem.20110283>
32. Pilati C, Letouze E, Nault JC, et al. Genomic profiling of hepatocellular adenomas reveals recurrent FRK-activating mutations and the mechanisms of malignant transformation. *Cancer Cell*. 2014;25(4):428-441. <https://doi.org/10.1016/j.ccr.2014.03.005>
33. Zucman-Rossi J, Jeannot E, Nhieu JT, et al. Genotype-phenotype correlation in hepatocellular adenoma: new classification and relationship with HCC. *Hepatology*. 2006;43(3):515-524. <https://doi.org/10.1002/hep.21068>
34. Lander ES, Linton LM, Birren B, et al. Initial sequencing and analysis of the human genome. *Nature*. 2001;409(6822):860-921. <https://doi.org/10.1038/35057062>
35. Rhead B, Karolchik D, Kuhn RM, et al. The UCSC genome browser database: update 2010. *Nucleic Acids Res*. 2010;38(Database issue):D613-D619. <https://doi.org/10.1093/nar/gkp939>
36. WHO. *Classification of Tumours: Digestive System Tumours*. Vol 1. 5th ed. Lyon: International Agency for Research on Cancer; 2019.
37. Di Tommaso L, Destro A, Seok JY, et al. The application of markers (HSP70 GPC3 and GS) in liver biopsies is useful for detection of hepatocellular carcinoma. *J Hepatol*. 2009;50(4):746-754. <https://doi.org/10.1016/j.jhep.2008.11.014>
38. Di Tommaso L, Franchi G, Park YN, et al. Diagnostic value of HSP70, glypican 3, and glutamine synthetase in hepatocellular nodules in cirrhosis. *Hepatology*. 2007;45(3):725-734. <https://doi.org/10.1002/hep.21531>
39. Tremosini S, Forner A, Boix L, et al. Prospective validation of an immunohistochemical panel (glypican 3, heat shock protein 70 and glutamine synthetase) in liver biopsies for diagnosis of very early hepatocellular carcinoma. *Gut*. 2012;61(10):1481-1487. <https://doi.org/10.1136/gutjnl-2011-301862>
40. Nault JC, Zucman-Rossi J. TERT promoter mutations in primary liver tumors. *Clin Res Hepatol Gastroenterol*. 2016;40(1):9-14. <https://doi.org/10.1016/j.clinre.2015.07.006>
41. Quaas A, Oldopp T, Tharun L, et al. Frequency of TERT promoter mutations in primary tumors of the liver. *Virchows Arch*. 2014;465(6):673-677. <https://doi.org/10.1007/s00428-014-1658-7>
42. Bioulac-Sage P, Cubel G, Balabaud C, Zucman-Rossi J. Revisiting the pathology of resected benign hepatocellular nodules using new immunohistochemical markers. *Semin Liver Dis*. 2011;31(1):91-103. <https://doi.org/10.1055/s-0031-1272837>
43. Eisenhauer EA, Therasse P, Bogaerts J, et al. New response evaluation criteria in solid tumours: revised RECIST guideline (version 1.1). *Eur J Cancer*. 2009;45(2):228-247. <https://doi.org/10.1016/j.ejca.2008.10.026>
44. Michielsen PP, Francque SM, van Dongen JL. Viral hepatitis and hepatocellular carcinoma. *World J Surg Oncol*. 2005;3:27. <https://doi.org/10.1186/1477-7819-3-27>
45. Calderaro J, Nault JC, Balabaud C, et al. Inflammatory hepatocellular adenomas developed in the setting of chronic liver disease and cirrhosis. *Mod Pathol*. 2016;29(1):43-50. <https://doi.org/10.1038/modpathol.2015.119>
46. Bioulac-Sage P, Rebouissou S, Thomas C, et al. Hepatocellular adenoma subtype classification using molecular markers and immunohistochemistry. *Hepatology*. 2007;46(3):740-748. <https://doi.org/10.1002/hep.21743>
47. Nault JC, Couchy G, Caruso S, et al. Argininosuccinate synthase 1 and periportal gene expression in sonic hedgehog hepatocellular adenomas. *Hepatology*. 2018;68(3):964-976. <https://doi.org/10.1002/hep.29884>
48. Henriët E, Abou Hammoud A, Dupuy JW, et al. Argininosuccinate synthase 1 (ASS1): a marker of unclassified hepatocellular adenoma and high bleeding risk. *Hepatology*. 2017;66(6):2016-2028. <https://doi.org/10.1002/hep.29336>
49. Sala M, Gonzales D, Leste-Lasserre T, et al. ASS1 overexpression: a hallmark of sonic hedgehog hepatocellular adenomas; recommendations for clinical practice. *Hepatol Commun*. 2020;4(6):809-824. <https://doi.org/10.1002/hep4.1514>

## SUPPORTING INFORMATION

Additional supporting information may be found online in the Supporting Information section.

**How to cite this article:** van Rosmalen BV, Furumaya A, Klompenhouwer AJ, et al. Hepatocellular adenoma in men: A nationwide assessment of pathology and correlation with clinical course. *Liver Int*. 2021;41:2474–2484. <https://doi.org/10.1111/liv.14989>