

UMass Chan Medical School

eScholarship@UMassChan

COVID-19 Publications by UMMS Authors

2021-05-20

Is Microthrombosis the Main Pathology in Coronavirus Disease 2019 Severity?-A Systematic Review of the Postmortem Pathologic Findings

Omar H. Fahmy
University of Louisville

Et al.

Let us know how access to this document benefits you.

Follow this and additional works at: <https://escholarship.umassmed.edu/covid19>



Part of the [Cardiovascular Diseases Commons](#), [Critical Care Commons](#), [Infectious Disease Commons](#), [Pathology Commons](#), and the [Virus Diseases Commons](#)

Repository Citation

Fahmy OH, Daas FM, Salunkhe V, Petrey JL, Cosar EF, Ramirez J, Akca O. (2021). Is Microthrombosis the Main Pathology in Coronavirus Disease 2019 Severity?-A Systematic Review of the Postmortem Pathologic Findings. COVID-19 Publications by UMMS Authors. <https://doi.org/10.1097/CCE.000000000000427>. Retrieved from <https://escholarship.umassmed.edu/covid19/249>

Creative Commons License



This work is licensed under a [Creative Commons Attribution-NonCommercial-No Derivative Works 4.0 License](#). This material is brought to you by eScholarship@UMassChan. It has been accepted for inclusion in COVID-19 Publications by UMMS Authors by an authorized administrator of eScholarship@UMassChan. For more information, please contact Lisa.Palmer@umassmed.edu.

Is Microthrombosis the Main Pathology in Coronavirus Disease 2019 Severity?—A Systematic Review of the Postmortem Pathologic Findings

OBJECTIVES: This systematic review attempts to retrieve and report the findings of postmortem studies including the histopathologic data of deceased coronavirus disease 2019 patients and to review the manifestations of coronavirus disease 2019–associated thrombotic pathologies reported in the recent literature.

DATA SOURCES: PubMed, Excerpta Medica Database, and Cochrane library between December 1, 2019, and August 26, 2020.

STUDY SELECTION: Investigators screened 360 unique references, retrieved published autopsy series, and report on the postmortem histopathologic information on patients who had died of coronavirus disease 2019.

DATA EXTRACTION: Investigators independently abstracted all available data including study design, participant demographics, key histopathologic findings, disease severity markers, duration of hospital stay, and cause of death.

DATA SYNTHESIS: From the 65 eligible studies, 691 total completed autopsies were included in evidence synthesis. Histopathologic evaluation of the lungs revealed presence of diffuse alveolar damage in 323 of 443 patients and pulmonary microthrombi in 242 of 326 patients. Deep venous thrombosis and pulmonary embolism were found in 41% and ~15%, respectively, of the cadavers examined for thromboembolic events. D-dimer levels were generally higher in patients with severe clinical course of coronavirus disease 2019. Plasma levels of ferritin, lactate dehydrogenase, interleukin-6, and C-reactive protein were higher in non-survivors when compared with survivors. Overall, microthrombi and extensive angiogenesis of lung vasculature were the most common pathologic findings in the lungs and microthrombi in most of the assessed organ-tissue.

CONCLUSIONS: Diffuse alveolar damage was the most predominant feature in the lungs of coronavirus disease 2019 patients who underwent postmortem assessment. Widespread pulmonary microthrombosis and extensive pulmonary angiogenesis, in addition to frequent pulmonary and extrapulmonary microthrombotic and thromboembolic findings in patients with coronavirus disease 2019, appear to be consistent with the disease-specific hypercoagulability. Further discovery efforts in assessing the link between coronavirus disease 2019, hypercoagulable state, and immunothrombosis are warranted. In the interim, increased attention to anti-coagulant treatment approaches in coronavirus disease 2019 patients is needed.

KEY WORDS: coronavirus disease 2019; D-dimer; diffuse alveolar damage; microvascular thrombosis; postmortem; severe acute respiratory syndrome coronavirus 2

Omar H. Fahmy, MD^{1,2}

Farah M. Daas, MD^{1,2}

Vidyulata Salunkhe, MPH, MD^{1,2}

Jessica L. Petrey, MSLS³

Ediz F. Cosar, MD⁴

Julio Ramirez, MD, FACP^{1,2}

Ozan Akca, MD, FCCM^{5,6}

Copyright © 2021 The Authors. Published by Wolters Kluwer Health, Inc. on behalf of the Society of Critical Care Medicine. This is an open-access article distributed under the terms of the Creative Commons Attribution-Non Commercial-No Derivatives License 4.0 (CCBY-NC-ND), where it is permissible to download and share the work provided it is properly cited. The work cannot be changed in any way or used commercially without permission from the journal.

DOI: 10.1097/CCE.0000000000000427

Coronavirus disease 2019 (COVID-19) has been diagnosed in more than 42 million people and has taken the lives of more than 1.1 million people globally (1). COVID-19 mainly presents as pneumonia. Within

the hospitalized patients, about 20% developed critical pneumonia similar to acute respiratory distress syndrome (ARDS) (2). Severe lung disease manifestation of COVID-19—whether true pneumonia, ARDS, or a distinct pneumonitis—has been serving as the main cause of the disease-related morbidity and mortality (3, 4). Although at the beginning of the pandemic, critically ill COVID-19 patients' mortality was as high as 70%, as in our city's example, it mostly averaged less than 40% (5).

To expand the medical knowledge about COVID-19 pneumonia, autopsy results of deceased COVID-19 patients were deemed to be crucial and of great interest in exploring the details of the disease pathogenesis. Knowing the pathology behind the severe illness and its postmortem findings will help to understand the disease process better and will likely lead to efforts of therapeutic discovery.

Diffuse alveolar damage (DAD) and thrombotic disease processes appear to contribute to the mortality of severe COVID-19. In this systematic review, we aimed to report the postmortem findings of deceased COVID-19 patients. Specific emphasis was given to pulmonary microthrombosis and widespread thrombotic manifestations in hospitalized COVID-19 patients.

Although similar systematic reviews have been published regarding postmortem pathologic manifestations of COVID-19 (6–8), in the present analysis, we aimed to include a larger number of studies with fewer restrictions by biopsy site or manifestation type for a more comprehensive and generalizable picture of the disease. Additionally, published postmortem reviews did not direct the focus to critical illness. Providing all available postmortem pathologic evidence in an abstracted form to the physicians managing these patients will likely have potential treatment implications.

METHODS

This study followed the Preferred Reporting Items for Systematic Reviews and Meta-analyses guidelines. Between December 1, 2019, and August 26, 2020, literature searches were conducted in PubMed, Cochrane, and Excerpta Medica Database. The following strategy was used in PubMed and adapted as appropriate for the other databases: (“COVID-19”[All Fields] OR “COVID-2019”[All Fields] OR

“severe acute respiratory syndrome coronavirus 2”[Supplementary Concept] OR “severe acute respiratory syndrome coronavirus 2”[All Fields] OR “2019-nCoV”[All Fields] OR “SARS-CoV-2”[All Fields] OR “2019nCoV”[All Fields] OR (“Wuhan”[All Fields] AND (“coronavirus”[MeSH Terms] OR “coronavirus”[All Fields])) AND (2019/12[PDAT] OR 2020[PDAT])) AND (“autopsy”[MeSH Terms] OR “autopsy”[All Fields] OR “autopsies”[All Fields] OR “postmortem”[All Fields] OR “postmortems”[All Fields] OR “post-mortem”[All Fields]). Results were filtered to English-language human studies published after December 2019. Content experts also screened reference lists of included trials and relevant narrative reviews. A total of 549 references were retrieved. After duplicates were extracted, 360 unique records remained for screening. To reduce the risk of bias, two researchers (O.H.F., F.M.D.) screened these remaining references according to the following inclusion criteria:

- 1) Studies presenting pathology, histology and/or laboratory findings.
- 2) Patients with positive reverse transcriptase-polymerase chain reaction for severe acute respiratory syndrome coronavirus 2 (SARS-CoV-2).
- 3) Articles written in English or with an available translation.

Narrative reviews, editorials, and other publications without original data were excluded, although publications with incomplete data were included if additional data were provided by corresponding authors upon request. Studies were excluded from the data synthesis if SARS-CoV-2 was not confirmed in the deceased patients. Any screening conflicts were discussed with a third content expert reviewer available for resolution as needed. Of the 360 distinct references identified through database searching, 58 studies were eligible for inclusion. Seven additional studies were identified through hand search, for a total of 65 studies included in the evidence synthesis (Fig. 1). These studies were appraised for bias, methodological quality, and significance of results but were not excluded based on their individual limitations. Data were extracted and summarized in table form (Table 1). Methodological details of the reviewed articles are included in Supplemental Table 1 (<http://links.lww.com/CCX/A616>). The heterogeneous nature of published literature did not allow for a full meta-analysis.

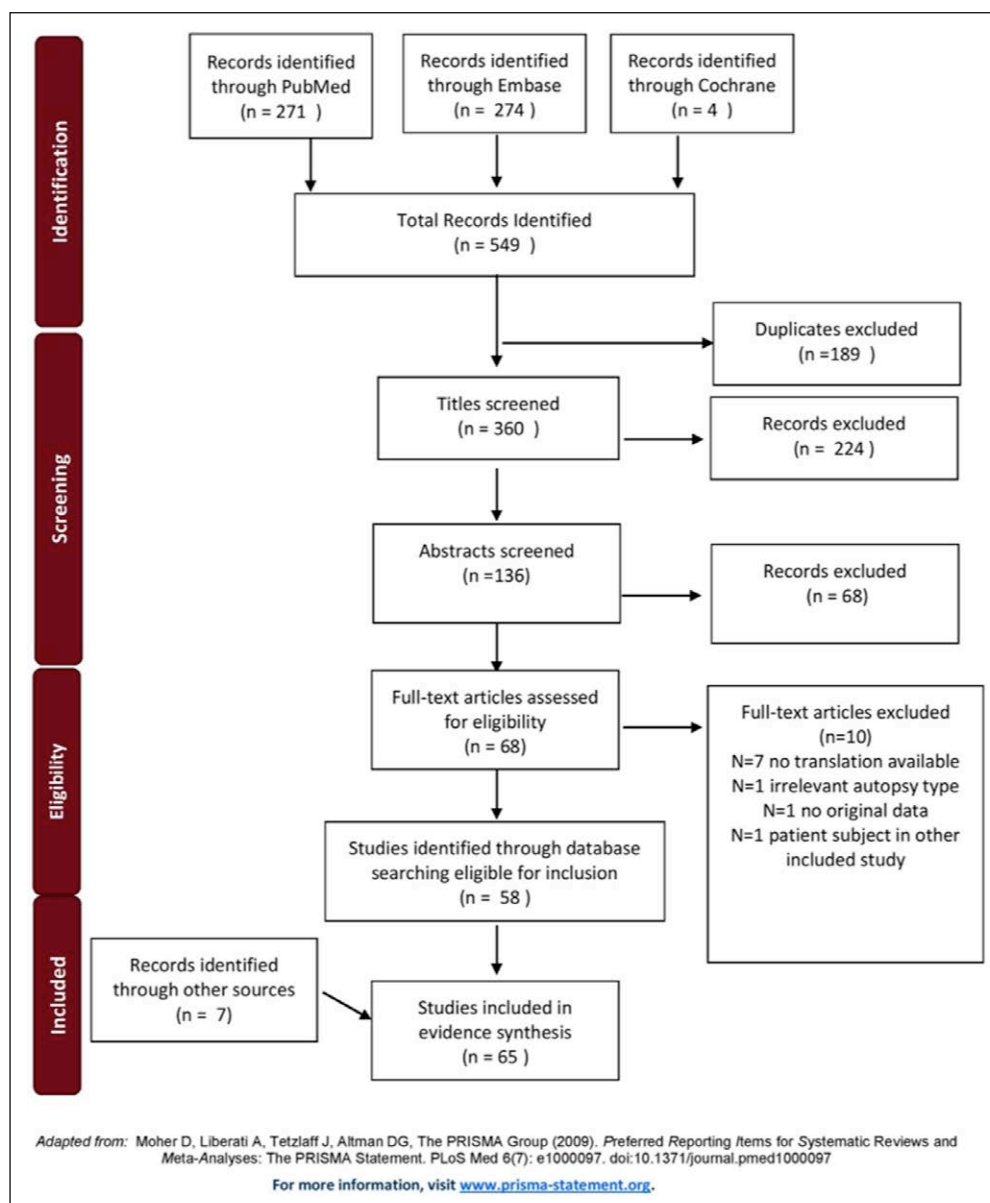


Figure 1. The Preferred Reporting Items for Systematic Reviews and Meta-analyses flow diagram.

RESULTS

The 65 included studies reported pathologic and histological findings of a combined total of 691 patients, of which 677 were deceased due to COVID-19. Three of these studies (Edler et al [37], Lindner et al [62], and Wichmann et al [19]) reported data from the same cohort of patients, although any duplicate data were counted only once in our analysis. Additionally, Varga et al (15), Magro et al (14), and Sharma et al (56) presented the histological findings of biopsies obtained from 14 alive COVID-19 patients during their hospital stay, and we included these data as they provided valuable information about the involvement of the endothelium,

kidneys, and other organs in patients with COVID-19.

As represented in the published clinical reports, the majority of pathologic findings were seen in the lungs ($n = 443$). However, many other histopathologic findings were reported from other organ systems, including heart ($n = 262$), brain ($n = 129$), liver ($n = 263$), kidneys ($n = 281$), prostate, testes, vascular system, and cutaneous tissue. Details related to the major organ systems were summarized below as well as in tables and figures (Tables 2–4) (Supplemental Table S2, <http://links.lww.com/CCX/A617>; Supplemental Table S3, <http://links.lww.com/CCX/A618>; Supplemental Table S4, <http://links.lww.com/CCX/A619>; Supplemental Table S5, <http://links.lww.com/CCX/A620>).

Respiratory System

Out of 443 patients with postmortem lung tissue samples evaluated histologically, 86% showed features of DAD in exudative and proliferative phases, characterized by alveolar edema, hyaline membrane (HM) formation, as well as some other changes such as intraalveolar fibrin deposition, and proliferation of pneumocytes and fibroblasts. DAD is a known hallmark feature of ARDS.

Another frequently observed key finding was the presence of vascular pathology including fibrin thrombi inside the pulmonary vasculature. Pulmonary thrombi were found in 242 of 326 autopsies examined (~74%). The thrombi were more often seen in the small and mid-sized vessels of the lung, in areas where DAD existed (40).

TABLE 1.
Systematic Review of Postmortem Findings in Coronavirus Disease 2019

References	Date of Publication	Study Design	No. of Participants	Males, %	Age, yr	In-Hospital Deaths, %	Country
Xu et al (9)	February 17, 2020	Autopsy report	1	100	50	100	China
Zhang et al (10)	March 12, 2020	Case report	1	100	72	100	China
Su et al (11)	April 09, 2020	Autopsy series	26	73.1	Median: 68 (range: 39–87)	NR	China
Tian et al (12)	April 14, 2020	Autopsy series	4	75	Median: 76 (range: 59–81)	100	China
Dolhnikoff et al (13)	April 15, 2020	Autopsy series	10	50	Mean: 67.8 (range: 33–83)	NR	Brazil
Magro et al (14)	April 15, 2020	Case series	5	60	Median: 62 (range: 32–73)	100 (<i>n</i> = 2) ^a	United States
Varga et al (15)	April 20, 2020	Case series	3	66.7	Median: 69 (range: 58–71)	50 (<i>n</i> = 2) ^a	Switzerland
Konopka et al (16)	April 28, 2020	Autopsy report	1	100	37	100	United States
Menter et al (17)	May 04, 2020	Autopsy series	21	81	Mean: 76 (range: 53–96)	100	Switzerland
Barton et al (18)	May 05, 2020	Autopsy series	2	100	Range: 42–77	50	United States
Wichmann et al (19)	May 06, 2020	Prospective cohort study	12	75	Median: 73 (range: 52–87)	83.3	Germany
Buja et al (20)	May 07, 2020	Autopsy series	3	100	Median: 48 (range: 34–62)	33.3	United States
Navarro Conde et al (21)	May 11, 2020	Autopsy report	1	100	69	100	Spain
Grimes et al (22)	May 12, 2020	Autopsy series	2	100	NR	100	United States
Craver et al (23)	May 03, 2020	Autopsy report	1	100	17	0	United States
Lax et al (24)	May 14, 2020	Prospective autopsy series	11	72.7	Mean: 80.55 (range: 66–91)	100	Austria
Adachi et al (25)	May 15, 2020	Autopsy report	1	0	84	100	Japan
Yan et al (26)	May 18, 2020	Autopsy report	1	0	44	100	United States
Ackermann et al (27)	May 21, 2020	Comparative study	7	71.4	Range: 66–96	100	Germany
		Coronavirus disease 2019	7	71.4	Range: 45–74	100	
		H1N1	10	50	Range: 62–83	100	
Schaller et al (28)	May 21, 2020	Autopsy series	10	70	Median: 79 (range: 64–90)	100	Germany
Bryce et al (29)	May 22, 2020	Autopsy series	67	56.7	Median: 69 (range: 34–94)	100	United States
Duarte-Neto et al (30)	May 22, 2020	Autopsy series	10	50	Median: 69 (range: 33–83)	100	Brazil

(Continued)

TABLE 1. (Continued).
Systematic Review of Postmortem Findings in Coronavirus Disease 2019

References	Date of Publication	Study Design	No. of Participants	Males, %	Age, yr	In-Hospital Deaths, %	Country	
The COVID-19 Autopsy Project (31)	May 23, 2020	Autopsy series	1	100	54	100	Spain	
Reichard et al (32)	May 24, 2020	Autopsy report	1	100	71	100	United States	
Aguiar et al (33)	May 26, 2020	Autopsy report	1	0	31	0	Switzerland	
Sekulic et al (34)	May 26, 2020	Autopsy series	2	100	Range: 54–81	100	United States	
Fox et al (35)	May 27, 2020	Autopsy series	10	NR	Median: 64.5 (range: 44–78)	100	United States	
Yang et al (36)	May 31, 2020	Autopsy series	12	100	Mean: 65 (range: 42–87)	NR	China	
Edler et al (37)	June 04, 2020	Autopsy series	80	57.5	Median: 82.4 (range: 52–96)	63.8	Germany	
von Weyhern et al (38)	June 04, 2020	Autopsy series	6	66.7	Range: 58–82	100	Germany	
Suess et al (39)	06/05, 2020	Autopsy report	1	100	59	0	Switzerland	
Carsana et al (40)	June 08, 2020	Autopsy series	38	86.8	Mean: 69 (range: 32–86)	100	Italy	
Solomon et al (41)	June 12, 2020	Autopsy series	18	77.8	Median: 62 (range: 53–75)	100	United States	
Konopka et al (42)	June 15, 2020	Autopsy series	SARS-CoV-2 (positive)	8	62.5	Range: 37–79	50	United States
			SARS-CoV-2 (negative)	8				
Beigmohammadi et al (43)	June 19, 2020	Autopsy series	7	71.4	Mean: 67.85 (range: 46–84)	100	Iran	
Schaefer et al (44)	June 19, 2020	Autopsy series	7	71.4	Median: 66 (range: 50–77)	100	United States	
Wang et al (45)	June 21, 2020	Autopsy series	2	50	Range: 53–62	100	China	
Rapkiewicz et al (46)	June 25, 2020	Autopsy series	7	42.9	Range: 44–65	71.4	United States	
Tombolini et al (47)	June 29, 2020	Autopsy series	2	0	Range: 61–67	0	Italy	
Bosmuller et al (48)	June 30, 2020	Autopsy series	4	75	Range: 59–79	75	Germany	
Youd et al (49)	June 30, 2020	Autopsy series	3b	33.3	Range: 73–88	0	United Kingdom	
Prieto-Perez et al (50)	July 3, 2020	Autopsy series	33	63.6	Median: 79 (range: 53–98)	100	Spain	
Santana et al (51)	July 3, 2020	Autopsy report	1	100	71	100	Brazil	
Dorward et al (52)	July 04, 2020	Autopsy series	11	90.9	Mean: 77 (range: 64–97)	NR	United Kingdom	
Flikweert et al (53)	July 08, 2020	Autopsy series	7	71.4	Median: 74 (range: 58–83)	100	Netherlands	

(Continued)

TABLE 1. (Continued).
Systematic Review of Postmortem Findings in Coronavirus Disease 2019

References	Date of Publication	Study Design	No. of Participants	Males, %	Age, yr	In-Hospital Deaths, %	Country
Stone et al (54)	July 08, 2020	Autopsy report	1	0	76	100	United States
Sonzogni et al (55)	July 12, 2020	Autopsy series	48	NR	Mean: 71 (range: 32–86)	NR	Italy
Sharma et al (56)	July 13, 2020	Case series	10	50	Mean: 65 (range: 45–77)	50c	United States
Bradley et al (57)	July 16, 2020	Autopsy series	14	42.9	Median: 73.5 (range: 42–84)	100	United States
Grosse et al (58)	July 16, 2020	Autopsy series	14	64.3	Median: 81 (range: 55–94)	100	Austria
Prilutskiy et al (59)	July 18, 2020	Autopsy series	4	75	Range: 64–91	100	United States
Golmai et al (60)	August 31, 2020	Autopsy series	12	83.3	Range: 49–92	100	United States
Conklin et al (61)	July 24, 2020	Retrospective cohort study	16	NR	NR	100	United States
Lindner et al (62)	July 27, 2020	Autopsy series	39	41	Median: 83 (interquartile range: 78–89)	NR	Germany
Schwensen et al (63)	July 28, 2020	Autopsy report	1	0	In her 80s	100	Denmark
Santoriello et al (64)	July 29, 2020	Autopsy series	42	69	Median: 71.5 (range: 38–97)	85.7	United States
Cirstea et al (65)	August 05, 2020	Autopsy report	1	0	30	0	Romania
Ducloyer et al (66)	August 06, 2020	Autopsy report	1	100	75	0	France
Kantonen et al (67)	August 06, 2020	Autopsy series	4	75	Range: 38–90	100 (<i>n</i> = 2)	Finland
Cipolloni et al (68)	August 09, 2020	Autopsy series	2d	100	Range: 42–70	50	Italy
Remmelink et al (69)	August 12, 2020	Autopsy series	17	70.6	Median: 72 (range: 49–91)	100	Belgium
Okudela et al (70)	August 13, 2020	Autopsy report	1	0	93	100	Japan
Skok et al (71)	August 20, 2020	Autopsy series	19e	60.7	Median: 82.5 (range: 66–96)	100	Austria
Roden et al (72)	August 21, 2020	Autopsy series	8	87.5	Median: 79 (range: 69–96)	100	United States
Nadkarni et al (73)	August 26, 2020	Autopsy series	26	61.5	NR	100	United States

NR = not reported, SARS-CoV-2 = severe acute respiratory syndrome coronavirus 2.

^aAlive subjects were included in the study.

^bThe study included nine participants; however, only three tested positive for SARS-CoV-2 and included in the review.

^cBiopsies were taken from alive patients; however, on follow-up, five patients died, and five patients survived.

^dThe study included two SARS-CoV-2 positive patients in addition to one control.

^eThe study included 28 participants; however, only 19 were autopsied and included in the review.

Heart

Intravascular and intramural fibrin thrombi as well as areas of infarcts were observed in a few patients (24, 29, 30, 46, 65, 73). In a study by Lindner et al

(62), a high viral load of SARS-CoV-2 RNA was identified in the myocardial tissue of 16 patients of the 24 evaluated. Myocarditis and myocardial infarction were reported only in 4.2% and 3.8% of the examined

patients, respectively. Microthrombi were found in 7.3% of the patients (Table 3). Although these numbers are prevalent enough to be reported in here, they are less prevalent than expected when compared with the clinical reports from patients recovering from COVID-19 (74).

Brain

Microthrombi were seen in postmortem brain tissue samples of 4.7% of the patients. Encephalitis was reported only in one study (38). Encephalitis and/or meningitis were reported in 5.4% of evaluated patients. Hemorrhagic lesions were seen in six of 129 examined brains. Ischemic lesions and infarcts were reported in 9.3% of patients.

Kidneys

Microthrombi were reported in the kidney tissue samples of 12.1% of the patients.

Liver

Postmortem examination of the liver revealed thrombosis and microthrombosis in 27.4% of evaluated cases.

Vascular System

Intravascular thrombi were reported in various organ systems. We presented these findings for each organ system under the respective section in Tables 2–4 and reported endothelial and thrombotic changes under the vascular system section separately in Supplemental Table S5 (<http://links.lww.com/CCX/A620>).

In addition to the microthrombi, 41% of 110 postmortem assessments reported deep vein thrombosis (DVT). Wichmann et al (19) reported bilateral leg involvement in all patients who developed DVT. In total, pulmonary embolism (PE) was reported in 39 of 257 deceased COVID-19 patients. Interestingly, prostatic vein plexus thrombosis was observed in 15 male patients (37). Three patients demonstrated cutaneous coagulopathy (14).

DISCUSSION

Similarly with SARS-CoV and other viruses from the same family, major pathologic respiratory system

finding of this COVID-19 cohort of autopsies was epithelial changes. Mainly, DAD and HM formation, which generally corresponds to the clinical course of ARDS. PEs were reported in 15% of the patients, but a coexisting DVT was not necessarily found in patients who had documented PE (24, 75). Another peculiar finding was the type or observed shape of pulmonary emboli, which conformed to the walls of pulmonary arteries. This finding led many to hypothesize that these pulmonary emboli are in fact pulmonary thrombi, which were formed in the lung vasculature (24, 46, 75).

Possibly, the most interesting finding of this report is the abundance of microvascular damage, which was reported as microvascular thrombi. Interestingly, microthrombi was not only reported in the lungs, but it was also shown in the other organ systems including brain, kidneys, spleen, heart, and liver at significant prevalence. In addition to interesting predominance of microthrombi, multiple reports presented various levels of endothelial injury. Endothelial injury may suggest a triggering mechanism, which may possibly be initiated by hypercoagulable and hyperinflammatory pathways. Patterns of endothelial injury and microthrombi formation may happen simultaneously, or one may follow the other (8). Immunothrombotic dysregulation appears to strongly contribute to the disease severity in COVID-19 (76).

Intravascular microthrombosis is not specific to COVID-19; it is seen in ARDS due to various other causes, such as sepsis and trauma. However, the prevalence and extensiveness of microthrombi in patients with COVID-19-associated DAD is more prominent compared with other severe disease states (27). Microthrombi in the lungs were observed in up to 42% of evaluated patients with nontraumatic ARDS of other causes, whereas our review detected pulmonary (micro) thrombosis in 74% of patients with COVID-19 (77). To shed more light on the difference of SARS-CoV-2 from other respiratory viruses, Ackermann et al (27) examined the lungs of deceased patients with COVID-19 and compared them with the lungs of patients who died of H1N1-associated ARDS as well as to the uninfected lungs that were donated but not transplanted. First, the mean lung weight was found to be much higher in patients who died of influenza compared with those who died of SARS-CoV-2 infection, and this was explained by the extensive interstitial edema and severe

TABLE 2.
Summary of Postmortem Findings in the Lung Tissue

References	No. of Evaluated Deceased Patients With Laboratory Confirmed Coronavirus Disease 2019	Diffuse Alveolar Damage/Hyaline Membrane, <i>n</i>	Vascular (micro)Thrombi, <i>n</i>	PE/Infarct, <i>n</i>
Xu et al (9)	1	1	NR	NR
Zhang et al (10)	1	1	NR	NR
Tian et al (12)	4	4	2	NR
Dolhnikoff et al (13)	10	10	8	NR
Magro et al (14)	2	1	NR	NR
Varga et al (15)	2	2	NR	NR
Konopka et al (16)	1	1	1	NR
Menter et al (17)	21	16	5/11	PE (4)
Barton et al (18)	2	1	1	PE (0)
Wichmann et al (19)	12	8	5	PE (5)
Buja et al (20)	3	2	1	PE (1)
Navarro Conde et al (21)	1	1	Mid-sized PAT (1)	NR
Grimes et al (22)	2	0	2	PE (2)
Craver et al (23)	1	0	0	PE (0)
Lax et al (24)	11	10	PAT (11)	Infarcts (9) PE (0)
Adachi et al (25)	1	1	NR	NR
Yan et al (26)	1	1	NR	NR
Ackermann et al (27)	7	7	7	PE (0)
Schaller et al (28)	10	10	NR	NR
Bryce et al (29)	25a	22	21/23	PE (4)
Duarte-Neto et al (30)	10	10	8	NR
The COVID-19 Autopsy Project (31)	1	1	1	NR
Aguiar et al (33)	1	1	NR	NR
Sekulic et al (34)	2	2	0	NR
Fox et al (35)	10	10	10	NR
Edler et al (37)	80	8/12b	NR	PE (17)
von Weyhern et al (38)	6	5	NR	Infarct (1) PE (0)

C-Reactive Protein, mg/L	Interleukin-6, pg/mL	D-dimer, ng/mL
NR	NR	NR
NR	NR	NR
NR	NR	NR
NR	NR	NR
NR	NR	NR
NR	NR	NR
NR	NR	NR
NR	NR	NR
NR	Range: 103–278 (<i>n</i> = 5)	Range: 400–10,400 (<i>n</i> = 5)
NR	NR	NR
Median: 189 (range: 18–348) (<i>n</i> = 10)	NR	Median: 23,100 (range: 5,700 to > 200,000) (<i>n</i> = 5)
NR	NR	NR
NR	NR	NR
Range: 43–272	NR	NR
NR	NR	NR
Range: 238–3,467	NR	Range: 439–15,532 (<i>n</i> = 7)
Range: 1.32–3.4	NR	NR
114	At T0: undetectable At death: 397	781
NR	NR	NR
NR	NR	NR
Mean at T0: 139 (range: 15–529) (<i>n</i> = 28)	Mean at T0: 379 (range: 45–1,406) (<i>n</i> = 14)	Mean at T0: 4,400 (range: 600–17,200) (<i>n</i> = 22)
Mean at death: 235 (range: 26–476) (<i>n</i> = 35)	Mean at death: 451 (range: 10–3,181) (<i>n</i> = 26)	Mean at death: 7,400 (range: 700–19,200) (<i>n</i> = 32)
Median: 81 (range: 23–110.5)	NR	Range: 28–89 (<i>n</i> = 2)
NR	NR	NR
Postmortem: 48	NR	NR
NR	NR	NR
NR	NR	Range: 249–47,559 (<i>n</i> = 6)
NR	NR	NR
Range: 67.5–304.4	180.4–1,226	NR

(Continued)

TABLE 2. (Continued).
Summary of Postmortem Findings in the Lung Tissue

References	No. of Evaluated Deceased Patients With Laboratory Confirmed Coronavirus Disease 2019	Diffuse Alveolar Damage/Hyaline Membrane, <i>n</i>	Vascular (micro)Thrombi, <i>n</i>	PE/Infarct, <i>n</i>
Suess et al (39)	1	1	1	NR
Carsana et al (40)	38	38	33	NR
Konopka et al (42)	8	7	7	NR
Beigmohammadi et al (43)	7	5	NR	NR
Schaefer et al (44)	7	7	5	NR
Wang et al (45)	2	2	2	NR
Rapkiewicz et al (46)	7	7	4	PE (0)
Tombolini et al (47)	2	2	2	NR
Bosmuller et al (48)	4	2	3	NR
Youd et al (49)	3	3	0	NR
Prieto-Perez et al (50)	20	20	12	NR
Santana et al (51)	1	0	1	NR
Dorward et al (52)	11	8	8	NR
Flikweert et al (53)	7	1	6	NR
Stone et al (54)	1	1	1	NR
Bradley et al (57)	14	12	5	PE (2)
Grosse et al (58)	14	14	Microthrombi (11) Mid-sized PAT (5)	Infarcts (2) PE (1)
Prilutskiy et al (59)	4	4	NR	NR
Schwensen et al (63)	1	1	0	PE (1)
Cirstea et al (65)	1	1	1	NR
Ducloyer et al (66)	1	1	NR	NR
Cipolloni et al (68)	2	2	2	NR
Rommelink et al (69)	17	15	11	Infarcts (4) PE (3)
Okudela et al (70)	1	1	1	PE (0)
Skok et al (71)	19	19	PAT (19)	Infarcts (16) PE (0)
Roden et al (72)	8	6	Microthrombi (5) PAT (2)	NR
Nadkarni et al (73)	26	15	15	PE (4)
Summary	443	323/375 (86.1%)	242/326 (74.2%)	PE: 39/257 (15.2%)

NR = not reported, PAT = pulmonary arterial thrombi, PE = pulmonary embolism, T0 = at admission.

^aOf a total pool of 67 patients.

^bHistological examination of lungs was performed in only 12 of the 80 study participants.

C-Reactive Protein, mg/L	Interleukin-6, pg/mL	D-dimer, ng/mL
NR	NR	NR
NR	NR	> 10× the upper limit of normal range (<i>n</i> = 26)
NR	NR	NR
NR	NR	NR
NR	NR	NR
Range at peak: 125.8–148.3	Range at peak: 20.28–27.9	NR
Range at peak: 169–379 (<i>n</i> = 5)	Range at peak: < 5 to 834 (<i>n</i> = 5)	Range at peak: 320 to > 52,926 (<i>n</i> = 4)
NR	NR	NR
NR	NR	NR
NR	NR	NR
Median: 10.9 (range: 0.5–40.1)	Median: 40.6 (range: 6.7–241.4)	Median: 3,114 (522–64,533)
12		
NR	NR	NR
NR	NR	NR
NR	NR	At T0: 3,592
NR	NR	NR
Range at T0: 0.3–39 (<i>n</i> = 14)	Range at T0: 34.1–1,133 (<i>n</i> = 9)	Range at T0: 1,240–13,100 (<i>n</i> = 14)
Range at death: 2–40.3 (<i>n</i> = 14)	Range at death: 34.4–13,000 (<i>n</i> = 9)	Range at death: 950 to > 35,200 (<i>n</i> = 14)
Range: 77.7–365.1	NR	NR
NR	NR	NR
NR	NR	NR
163	NR	NR
NR	NR	NR
Range: 27–270 (<i>n</i> = 17)	NR	899–8,531 (<i>n</i> = 8)
NR	NR	NR
NR	NR	NR
NR	NR	NR
NR	NR	NR

TABLE 3.
Summary of Postmortem Findings in the Heart and Brain Tissues

Cardiac System–Heart					
References	No. of Patients Evaluated	Main Pathologic Findings	Potential Mechanistic Biomarkers		
			CRP, mg/L	IL-6, pg/mL	D-dimer, ng/mL
Menter et al (17)	21	Acute MI (1)	NR	Range: 103–278 (n = 5)	Range: 400–10,400 (n = 5)
Barton et al (18)	2	Acute ischemic injury (1)	NR	NR	NR
	3	Lymphocytic myocarditis (1) Lymphocytic pericarditis (3)	NR	NR	NR
Craver et al (23)	1	Eosinophilic myocarditis (1)	NR	NR	NR
Lax et al (24)	11	Endocardial mural thrombi in left ventricle (1) Thrombosis of a myocardial vein (1) Focal lymphocytic infiltrate (1)	Range: 238.1–3,466.7 (n = 11)	NR	Range: 439–15,532 (n = 7)
Schaller et al (28)	10	Mild lymphocytic myocarditis (4) Epicarditis (2)	NR	NR	NR
Bryce et al (29)	25a	Small vessel thrombi in areas of epicardial inflammatory infiltrates (3)	Mean at T0: 139.1 (range: 15.1–528.9) (n = 28)	Mean at T0: 375.8 (range: 45.5–1,406) (n = 14)	Mean at T0: 4,400 (range: 600–17,200) (n = 22)
		Patchy epicardial mononuclear infiltrate (15)	Mean at death: 235 (range: 26.2–475.8) (n = 35)	Mean at death: 450.7 (range: 10.4–3,181) (n = 26)	Mean at death: 7,400 (range: 700–19,200) (n = 32)
Duarte-Neto et al (30)	10	Mild lymphomononuclear myocarditis (2) Fibrin microthrombi (2)	Median: 8.12 (range: 23–110.5)	NR	Range: 28.435–89.513 (n = 2)
Edler et al (37)	12	Lymphocytic myocarditis (1)	NR	NR	NR
Beigmohammadi et al (43)	7	Interstitial inflammation (4)	NR	NR	NR
Rapkiewicz et al (46)	7	Platelet-rich fibrin microthrombi (7) Cardiac venous thrombosis (2) Early ischemic injury (3) Mural fibrin thrombi (2) Focal lymphocytic myocarditis (1)	Range at peak: 169–379 (n = 5)	Range at peak: < 5 to 834 (n = 5)	Range at peak: 320 to > 52,926 (n = 4)
Bradley et al (57)	14	Focal lymphocytic myocarditis (1)	NR	NR	NR

(Continued)

TABLE 3. (Continued).
Summary of Postmortem Findings in the Heart and Brain Tissues

Cardiac System–Heart					
References	No. of Patients Evaluated	Main Pathologic Findings	Potential Mechanistic Biomarkers		
			CRP, mg/L	IL-6, pg/mL	D-dimer, ng/mL
Grosse et al (58)	14	Acute MI (3)	Range at T0: 0.3–39 (n = 14) Range at death: 2–40.3 (n = 14)	Range at T0: 34.1–1,133 (n = 9) Range at death: 34.4–13,000 (n = 9)	Range at T0: 1,240–13,100 (n = 14) Range at death: 950 to > 35,200 (n = 14)
Lindner et al (62)	39	SARS-CoV-2 RNA in myocardial tissue (24) with viral load more than 1,000 copies per µg RNA in (16)	NR	NR	NR
Cirstea et al (65)	1	Intracardiac thrombus (1)	NR	NR	NR
Rommelink et al (69)	17	Acute MI (2)	Range: 27–270 (n = 17)	NR	899–8,531 (n = 8)
Nadkarni et al (73)	26	Microthrombi (4)	NR	NR	NR
Summary	26b	Myocarditis (4.2%), MI (3.8%), microvascular/mural thrombi (7.3%)			
Neurologic System–Brain					
References	No. of Patients Evaluated	Main Pathologic Findings	Potential Mechanistic Biomarkers		
			CRP, mg/L	IL-6, pg/mL	D-dimer, ng/mL
Bryce et al (29)	20a	Widespread microthrombi, often associated with acute, small, and patchy infarction (6)	Mean at T0: 139.1 (range: 15.1–528.9) (n = 28) Mean at death: 235 (range: 26.2–475.8) (n = 35)	Mean at T0: 375.8 (range: 45.5–1,406) (n = 14) Mean at death: 450.7 (range: 10.4–3,181) (n = 26)	Mean at T0: 4,400 (range: 600–17,200) (n = 22) Mean at death: 7,400 (range: 700–19,200) (n = 32)
Reichard et al (32)	1	Acute disseminated encephalomyelitis-like picture (1) Cerebral white matter hemorrhagic lesions (1) Cortical microscopic infarcts (1)	NR	NR	NR
von Weyhern et al (38)	6	Encephalitis (5) Lymphocytic meningitis (6)	Range: 67.5–304.4	Range: 180.4–1,226	NR
Solomon et al (41)	18	Nonspecific acute ischemic hypoxic injury (18)	NR	NR	NR

(Continued)

TABLE 3. (Continued).
Summary of Postmortem Findings in the Heart and Brain Tissues

Cardiac System–Heart					
References	No. of Patients Evaluated	Main Pathologic Findings	Potential Mechanistic Biomarkers		
			CRP, mg/L	IL-6, pg/mL	D-dimer, ng/mL
Bradley et al (57)	5c	Punctate subarachnoid hemorrhages and punctate brainstem hemorrhages (1)	NR	NR	NR
Grosse et al (58)	7	Acute cerebral infarction (1)	Range at T0: 0.3–39 (n = 14)	Range at T0: 34.1–1,133 (n = 9)	Range at T0: 1,240–13,100 (n = 14)
			Range at death: 2–40.3 (n = 14)	Range at death: 34.4–13,000 (n = 9)	Range at death: 950 to > 35,200 (n = 14)
Conklin et al (61)	1	Widespread microvascular injury (petechial hemorrhages and microscopic ischemic lesions) (1)	NR	NR	NR
Kantonen et al (67)	4	Ischemic injuries, widespread micro-hemorrhages in white and deep gray matter (1) Mild to moderate hypoxic injuries (3)	NR	NR	NR
Remmelink et al (69)	11d	Cerebral focal necrosis (3) Cerebral hemorrhage (2) SARS-CoV-2 in the brain by reverse transcriptase-polymerase chain reaction (9)	Range: 27–270 (n = 17)	NR	Range: 899–8,531 (n = 8)
Nadkarni et al (73)	26	Cerebral infarction (2)	NR	NR	NR
Summary	129b	Encephalitis/meningitis (5.4%) Hemorrhage (4.7%) Ischemia/infarct/stroke (9.3%) Thrombosis/microvascular thrombi (4.7%)			

CRP = C-reactive protein, IL-6 = interleukin-6, MI = myocardial infarction, NR = not reported, SARS-CoV-2 = severe acute respiratory syndrome coronavirus 2, T0 = at admission.

^aOf a total pool of 67 patients.

^bThis number includes organs that were examined and did not show significant histopathologic findings; however, those were counted toward the total number of organs examined.

^cOf a total pool of 14 patients.

^dOf a total pool of 17 patients with significant histopathologic findings.

fibrin deposition in the influenza lungs. Intravascular thrombi were found in pulmonary arteries and alveolar capillaries in all of the patients in both the COVID-19 and H1N1 groups. However, the thrombi were nine times more widespread in the COVID-19 cohort, and the extent of angiogenesis was nearly three times higher in the COVID-19 lungs. Possibly, the profound

immunothrombosis in the lungs of COVID-19 patients is the cause of ischemia and subsequent angiogenesis (78). Newly formed blood vessels will further increase inflammation. Pulmonary microthrombosis can justify the near-normal compliance, high-elastance phenotype of COVID-19, but with ventilation perfusion mismatch, and severe hypoxemia (79).

TABLE 4.
Summary of Postmortem Findings in the Kidneys and Liver Tissues

Renal System–Kidneys					
References	No. of Patients Evaluated	Main Pathologic Findings	Potential Mechanistic Biomarkers		
			CRP, mg/L	IL-6, pg/mL	D-dimer, ng/mL
Su et al (11)	26	Glomerular segmental fibrin thrombi and endothelial injury (3) ATI (26)	NR	NR	Median: 2,860 (range: 900 to > 8,000) (<i>n</i> = 20)
Menter et al (17)	17	DIC with small fibrin thrombi in glomerular capillaries (3)	NR	Range: 103–278 (<i>n</i> = 5)	Range: 400–10,400 (<i>n</i> = 5)
Wichmann et al (19)	12	Kidney infarctions (1) Shock kidneys (1)	Median: 189 (range: 18–348) (<i>n</i> = 10)	NR	Median: 23,100 (range: 5,700 to > 200,000) (<i>n</i> = 5)
Bryce et al (29)	25a	Thromboemboli (1)	Mean at T0: 139.1 (range: 15.1–528.9) (<i>n</i> = 28) Mean at death: 235 (range: 26.2–475.8) (<i>n</i> = 35)	Mean at T0: 375.8 (range: 45.5–1,406) (<i>n</i> = 14) Mean at death: 450.7 (range: 10.4–3,181) (<i>n</i> = 26)	Mean at T0: 4,400 (range: 600–17,200) (<i>n</i> = 22) Mean at death: 7,400 (range: 700–19,200) (<i>n</i> = 32)
Buja et al (20)	3	Fibrin-platelet thrombus in kidney (1)	NR	NR	NR
Adachi et al (25)	1	Glomerular microthrombi (suggestive of early DIC) (1)	Range during admission: 1.32–3.4	NR	NR
Duarte-Neto et al (30)	8b	Fibrin microthrombi in glomeruli (6)	Median: 8.12 (range: 23–110.5)	NR	Range: 28.435–89.513 (<i>n</i> = 2)
Rapkiewicz et al (46)	7	Platelet-rich fibrin microthrombi in scattered peritubular capillaries and venules (7) Thrombotic microangiopathy in glomeruli (1)	Range at peak: 169–379 (<i>n</i> = 5)	Range at peak: < 5 to 834 (<i>n</i> = 5)	Range at peak: 320 to > 52,926 (<i>n</i> = 4)
Sharma et al (56)	10	Acute tubular necrosis (10) Thrombotic microangiopathy (2) Endothelial injury (4)	NR	NR	NR
Bradley et al (57)	14	Organizing thrombus in a small renal vein (1)	NR	NR	NR
Golmai et al (60)	12	Acute tubular necrosis (12)	NR	NR	NR
Santoriello et al (64)	42	Fibrin thrombi (6) ATI (19)	Median: 245.7 (range: 82.07 to > 300) (<i>n</i> = 30)	Median: > 315 pg/mL (range: 36 to > 315 pg/mL) (<i>n</i> = 26)	Median: 10,200 ng/mL (range: 580 to > 20,000 ng/mL) (<i>n</i> = 28)

(Continued)

TABLE 4. (Continued).
Summary of Postmortem Findings in the Kidneys and Liver Tissues

Renal System–Kidneys					
References	No. of Patients Evaluated	Main Pathologic Findings	Potential Mechanistic Biomarkers		
			CRP, mg/L	IL-6, pg/mL	D-dimer, ng/mL
Cirstea et al (65)	1	Widespread focal microthrombi (1)	NR	NR	NR
Nadkarni et al (73)	26	Microthrombi (2)	NR	NR	NR
Summary	281 ^c	Microthrombi (12.1%)			
Hepatobiliary System–Liver					
Study	No of Patients Evaluated	Main Pathologic Findings	Potential Mechanistic Biomarkers		
			CRP, mg/L	IL-6, pg/mL	D-dimer, ng/mL
Menter et al (17)	17	Liver shock necrosis (5)	NR	Range: 103–278 (n = 5)	Range: 400–10,400 (n = 5)
Wichmann et al (19)	12	Shock liver (3)	Median: 189 (range: 18–348) (n = 10)	NR	Median: 23,100 (range: 5,700 to > 200,000) (n = 5)
Lax et al (24)	11	Central vein thrombosis (1)	Range: 238.1–3,466.7	NR	Range: 439–15,532 (n = 7)
Bryce et al (29)	22 ^a	Early organizing thrombi in portal venules (15) Acute venous outflow obstruction (5)	Mean at T0: 139.1 (range: 15.1–528.9) (n = 28) Mean at death: 235 (range: 26.2–475.8) (n = 35)	Mean at T0: 375.8 (range: 45.5–1,406) (n = 14) Mean at death: 450.7 (range: 10.4–3,181) (n = 26)	Mean at T0: 4,400 (range: 600–17,200) (n = 22) Mean at death: 7,400 (range: 700–19,200) (n = 32)
Duarte-Neto et al (30)	10	Fibrin microthrombi in hepatic sinusoids (1)	Median: 8.12 (range: 23–110.5)	NR	Range: 28.435–89.513 (n = 2)
Rapkiewicz et al (46)	7	Platelet-fibrin microthrombi in hepatic sinusoids (6), Ischemic hepatic necrosis (2)	Range at peak: 169–379 (n = 5)	Range at peak: < 5 to 834 (n = 5)	Range at peak: 320 to > 52,926 (n = 4)
Sonzogni et al (55)	48	Complete portal thrombosis (11), partial portal thrombosis (24), complete sinusoidal thrombosis (6), partial sinusoidal thrombosis (7)	NR	NR	NR
Nadkarni et al (73)	26	Microthrombi (1)	NR	NR	NR
Summary	263 ^c	Thrombosis/microvascular thrombi (27.4%)			

ATI = acute tubular injury, CRP = C-reactive protein, DIC = disseminated intravascular coagulation, IL-6 = interleukin-6, NR = not reported, T0 = at admission.

^aOf a total pool of 67 patients.

^bOf a total pool of 10 patients.

^cThis number includes organs that were examined and did not show significant histopathologic findings; however, those were counted toward the total number of organs examined.

Critically ill patients with COVID-19 were found to have elevated circulating markers of endothelial dysfunction (80). Furthermore, higher levels of endothelial biomarkers, including interleukin (IL)-6, tumor necrosis factor- α , inter-cellular adhesion molecule 1, and caspase-1, were present in the lungs of deceased patients with COVID-19 compared with H1N1 lungs (81). There is a number of possible explanations for the causes of observed endothelial dysfunction in the patients with severe COVID-19. First, SARS-CoV-2 was found in endothelial cells in several autopsies, where it caused diffuse endothelial inflammation and endotheliitis (15, 48). This endothelial disruption activates the proinflammatory and procoagulant pathways (82). COVID-19-related endotheliitis may serve as a trigger for generalized microcirculatory dysfunction and related microthrombi. Predisposing factors to endothelial dysfunction such as male sex, smoking, hypertension, diabetes, obesity, and cardiovascular disease are also associated with severe COVID-19, and these factors may contribute to profound endotheliitis (15).

Significant proinflammatory state exhibited in patients with severe COVID-19, and the considerable cytokine production are evidenced by elevated IL-6, C-reactive protein (CRP), and ferritin as demonstrated by multiple retrospective cohort studies (**Supplemental Table S6**, <http://links.lww.com/CCX/A621>). Five studies categorized patients with COVID-19 as survivors and nonsurvivors and reported their laboratory values and anticoagulant administration during the hospitalization (83–87). A summary of these data is available in Supplemental Table S6 (<http://links.lww.com/CCX/A621>). The significant inflammatory state and cytokine production activate the endothelium. This activation turns on the coagulation cascade and results in hypercoagulable state. IL-6, CRP, and D-dimer levels were significantly higher in nonsurvivors compared with survivors. IL-6 was reported in two studies (83, 85), and the range of median IL-6 was 11–152.4 pg/mL in nonsurvivors compared with 6.3–45.8 in survivors. CRP, which was reported in two studies (84, 85), ranged from 130 to 174.4 in nonsurvivors, compared with a range of 40.9–93.9 mg/L in survivors. D-dimer levels were significantly higher in the nonsurvivor group of COVID-19 patients; ranging from 1.74 to 5.2 μ g/mL compared with the survivors where laboratory values were ranging from 0.6 to 1.47 μ g/mL (83–87).

Another factor that causes endothelial disruption is hyperviscosity (88). Fibrinogen, a glycoprotein complex

and clotting factor (Factor I), is a major contributor of plasma viscosity (89). An elevation in plasma fibrinogen levels leads to higher blood viscosity and subsequent increase in thrombotic risk. Elevated fibrinogen levels in patients with COVID-19 cause hyperviscosity, which plays a significant factor in the pathophysiology of COVID-19-induced coagulopathy. Bowles et al (90) reported positive lupus anticoagulant test in 31 of 34 patients with COVID-19 who had prolonged activated partial thromboplastin time (with a mean of 35.5s). Lupus anticoagulant is known to be associated with high risk of thrombosis. That is one more element that might be contributing to the profound hypercoagulability associated with COVID-19 (90).

These elements can also explain the growing recognition of the extrapulmonary microthrombi and thromboemboli. Microthrombi were observed occasionally in the vasculature of the kidneys and the liver. The exclusion of these organs from many autopsy reports, as well as minimally invasive (biopsy-like) autopsies of these organs, renders the histological evidence insufficient. More extensive open autopsies will likely lead to a better understanding behind the reported elevated liver biomarkers (55, 91), as well as acute kidney injury, hematuria, and proteinuria in COVID-19 patients (56). Although possible credible explanations are available such as direct viral injury and the considerable elevated cytokine production, determining the exact pathway is critical.

Despite one study reporting five patients under the age of 50 presenting with strokes and later found to be SARS-CoV-2 positive (92), our review of brain autopsies revealed infrequent thrombotic complications in brain. However, when compared with influenza, stroke risk was 7.6 times higher (0.2% vs 1.6%) in COVID-19 (93). COVID-19 was recently reported as an independent risk factor for stroke and increased mortality in hospitalized patients (94). Interestingly, nonspecific neurologic symptoms such as dizziness, headache, and impaired consciousness are common (~36%) in COVID-19, and even more common (~46%) in severe cases (95). Overall, the incidence of meningoencephalopathy was reportedly very low.

Cardiac dysfunction and arrhythmias have been reported in patients with unfavorable COVID-19 course (96–98). SARS-CoV-2 was reported to be present in myocardial cells, with a significant viral load of more than 1,000 copies per microgram RNA in 41% of the evaluated

patients (62). None of these heart tissue samples revealed the expected inflammatory response to the viral presence in the myocardial tissue nor were the clinical signs and symptoms of myocarditis observed. There is a paucity of histological evidence of myocarditis in the autopsies that we compiled in our review in spite of the fact that myocardial cells highly express angiotensin-converting enzyme 2 receptors (99). Very few recent work reported lymphocytic infiltrate in the heart (20, 35, 37, 46, 57, 100). However, a cardiovascular magnetic resonance assessment of 100 patients who recovered from COVID-19–related ARDS showed that 78% of patients had ongoing cardiac involvement, and 60% of the patients had ongoing myocardial inflammation (74). These findings may suggest that some of the postmortem cardiac assessments possibly missed discovering an existing focal myocarditis site. Of note, troponin was found to be elevated in many patients with COVID-19, and it was associated with a poorer prognosis (96–98). In light of the insufficient histological findings to support myocarditis, the elevated troponin can also be explained by mechanisms other than inflammation and myocarditis. For example, right ventricular strain due to PM and/or thrombosis or cardiac vein thrombosis (20, 101).

Limitations of this report need to be addressed. First, although this systematic review includes data from previously published postmortem reports of COVID-19 deaths, the systematic review protocols may have been insufficient to capture autopsy data published in other study types. More importantly, knowing that globally COVID-19–related deaths passed the one million mark, our total number of 691 postmortem reports may not necessarily accurately represent the complete pathology of severe disease. Second, a postmortem examination may bias results toward an exaggerated pathology, which may not be seen in an average patient experiencing a less severe course of the same disease process. Third, autopsy reports may not always be specifically focused on the clinical cause of death or the presumed clinical mechanisms behind it. Histopathologic examination of alive patients with a less severe course of COVID-19, albeit challenging, might reveal more in depth data that can provide comprehensive and plausible pathophysiologic explanation of the course of COVID-19.

In this systematic review, we aimed to abstract all available postmortem data from 65 studies representing a total of 691 patients. Postmortem findings of

COVID-19 patients summarize the final stages of disease in critically ill. Understanding the pathology behind these cases is crucial for critical care professionals. Multiple studies demonstrated evidence supporting the importance of anticoagulation and antiplatelet therapy (86, 102–104). In a large trial, Paranjpe et al (103) studied mechanically ventilated COVID-19 and reported nearly double number of deaths in patients who did not receive therapeutic-dose of anticoagulation. In an observational study by Chow et al (102), aspirin use—defined as receiving aspirin within the 7 days prior to hospitalization and/or the 24 hours following admission—was associated with a significant reduction in ICU admission and invasive mechanical ventilation needs. It is possible that antiplatelet agents may have beneficial effect, but this is neither tested under prospective controlled studies at this point nor any significant effect of such therapy was assessed in the setting where anticoagulation therapy was applied.

Therefore, highlighting the impact of thrombotic pathology is paramount in extrapolating the mechanism of disease and will likely lead to potential therapeutic approaches. We believe that reporting widespread occurrence of thrombotic complications will draw attention to the urgent need of performing randomized controlled trials addressing the benefits of administering various doses of anticoagulant and—possibly—antiplatelet therapies in critically ill COVID-19 patients.

CONCLUSIONS

In this systematic review of postmortem data, we are reporting an association between widespread thrombotic process and mortality. Although microvascular thrombi were abundant in the lung tissue, they were observed at significant percentages in most tissue and organs including liver, kidneys, brain, and heart.

ACKNOWLEDGMENTS

We very much appreciate the extreme hard work of all members of the Center of Excellence for Research in Infectious Diseases.

- 1 *Division of Infectious Diseases, University of Louisville School of Medicine, Louisville, KY.*
- 2 *Center of Excellence for Research in Infectious Diseases, University of Louisville School of Medicine, Louisville, KY.*

- 3 Kornhauser Health Sciences Library, University of Louisville, Louisville, KY.
- 4 Department of Pathology, University of Massachusetts Medical School, UMass Memorial Medical Center, Worcester, MA.
- 5 Departments of Anesthesiology and Perioperative Medicine, University of Louisville School of Medicine, Louisville, KY.
- 6 Comprehensive Stroke Clinical Research Program (CSCR), University of Louisville School of Medicine, Louisville, KY.

Drs. Fahmy and Daas contributed equally to the study and share the primary authorship. All authors made substantive contributions to the design, data collection and interpretation, writing of the article, and approval of the work.

The authors have disclosed that they do not have any potential conflicts of interest.

REFERENCES

1. Johns Hopkins University & Medicine: COVID-19 Dashboard by the Center for Systems Science and Engineering (CSSE) at Johns Hopkins University (JHU), 2020. Available at: <https://coronavirus.jhu.edu/map.html>. Accessed November 3, 2020
2. Wiersinga WJ, Rhodes A, Cheng AC, et al: Pathophysiology, transmission, diagnosis, and treatment of coronavirus disease 2019 (COVID-19): A review. *JAMA* 2020; 324:782–793
3. Grasselli G, Greco M, Zanella A, et al: COVID-19 Lombardy ICU Network: Risk factors associated with mortality among patients with COVID-19 in intensive care units in Lombardy, Italy. *JAMA Intern Med* 2020; 180:1345–1355
4. Zhao S, Lin Y, Zhou C, et al: Short-term outcomes of patients with COVID-19 undergoing invasive mechanical ventilation: A retrospective observational study from Wuhan, China. *Front Med (Lausanne)* 2020; 7:571542
5. Ramirez J, Bordon J, Cavallazzi R, et al: Characteristics and outcomes of adults hospitalized with SARS-CoV-2 community-acquired pneumonia in Louisville, Kentucky. *Univ Louisville J Respir Infect* 2020; 4:72
6. D'Errico S, Zanon M, Montanaro M, et al: More than pneumonia: Distinctive features of SARS-Cov-2 infection. From autopsy findings to clinical implications: A systematic review. *Microorganisms* 2020; 8:E1642
7. Hariri LP, North CM, Shih AR, et al: Lung histopathology in coronavirus disease 2019 as compared with severe acute respiratory syndrome and H1N1 influenza: A systematic review. *Chest* 2020; 159:73–84
8. Polak SB, Van Gool IC, Cohen D, et al: A systematic review of pathological findings in COVID-19: A pathophysiological timeline and possible mechanisms of disease progression. *Mod Pathol* 2020; 33:2128–2138
9. Xu Z, Shi L, Wang Y, et al: Pathological findings of COVID-19 associated with acute respiratory distress syndrome. *Lancet Respir Med* 2020; 8:420–422
10. Zhang H, Zhou P, Wei Y, et al: Histopathologic changes and SARS-CoV-2 immunostaining in the lung of a patient with COVID-19. *Ann Intern Med* 2020; 172:629–632
11. Su H, Yang M, Wan C, et al: Renal histopathological analysis of 26 postmortem findings of patients with COVID-19 in China. *Kidney Int* 2020; 98:219–227
12. Tian S, Xiong Y, Liu H, et al: Pathological study of the 2019 novel coronavirus disease (COVID-19) through postmortem core biopsies. *Mod Pathol* 2020; 33:1007–1014
13. Dolhnikoff M, Duarte-Neto AN, de Almeida Monteiro RA, et al: Pathological evidence of pulmonary thrombotic phenomena in severe COVID-19. *J Thromb Haemost* 2020; 18:1517–1519
14. Magro C, Mulvey JJ, Berlin D, et al: Complement associated microvascular injury and thrombosis in the pathogenesis of severe COVID-19 infection: A report of five cases. *Transl Res* 2020; 220:1–13
15. Varga Z, Flammer AJ, Steiger P, et al: Endothelial cell infection and endotheliitis in COVID-19. *Lancet* 2020; 395:1417–1418
16. Konopka KE, Wilson A, Myers JL. Postmortem lung findings in a patient with asthma and coronavirus disease 2019. *Chest* 2020; 158:e99–e101
17. Menter T, Haslbauer JD, Nienhold R, et al: Postmortem examination of COVID-19 patients reveals diffuse alveolar damage with severe capillary congestion and variegated findings in lungs and other organs suggesting vascular dysfunction. *Histopathology* 2020; 77:198–209
18. Barton LM, Duval EJ, Stroberg E, et al: COVID-19 autopsies, Oklahoma, USA. *Am J Clin Pathol* 2020; 153:725–733
19. Wichmann D, Sperhake JP, Lütgehetmann M, et al: Autopsy findings and venous thromboembolism in patients with COVID-19: A prospective cohort study. *Ann Intern Med* 2020; 173:268–277
20. Buja LM, Wolf DA, Zhao B, et al: The emerging spectrum of cardiopulmonary pathology of the coronavirus disease 2019 (COVID-19): Report of 3 autopsies from Houston, Texas, and review of autopsy findings from other United States cities. *Cardiovasc Pathol* 2020; 48:107233
21. Navarro Conde P, Alemany Monrahal P, Medina Medina C, et al: Autopsy findings from the first known death from severe acute respiratory syndrome SARS-CoV-2 in Spain. *Rev Esp Patol* 2020; 53:188–192
22. Grimes Z, Bryce C, Sordillo EM, et al: Fatal pulmonary thromboembolism in SARS-CoV-2-infection. *Cardiovasc Pathol* 2020; 48:107227
23. Craver R, Huber S, Sandomirsky M, et al: Fatal eosinophilic myocarditis in a healthy 17-Year-Old male with severe acute respiratory syndrome coronavirus 2 (SARS-CoV-2c). *Fetal Pediatr Pathol* 2020; 39:263–268
24. Lax SF, Skok K, Zechner P, et al: Pulmonary arterial thrombosis in COVID-19 with fatal outcome: Results from a prospective, single-center, clinicopathologic case series. *Ann Intern Med* 2020; 173:350–361
25. Adachi T, Chong JM, Nakajima N, et al: Clinicopathologic and immunohistochemical findings from autopsy of patient with COVID-19, Japan. *Emerg Infect Dis* 2020; 26:2157–2161
26. Yan L, Mir M, Sanchez P, et al: Autopsy report with clinical pathological correlation. *Arch Pathol Lab Med* 2020; 144:1041–1047
27. Ackermann M, Verleden SE, Kuehnel M, et al: Pulmonary vascular endotheliitis, thrombosis, and angiogenesis in Covid-19. *N Engl J Med* 2020; 383:120–128

28. Schaller T, Hirschtbühl K, Burkhardt K, et al: Postmortem examination of patients with COVID-19. *JAMA* 2020; 323:2518–2520
29. Bryce C, Grimes Z, Pujadas E, et al: Pathophysiology of SARS-CoV-2: Targeting of endothelial cells renders a complex disease with thrombotic microangiopathy and aberrant immune response. The Mount Sinai COVID-19 autopsy experience. *medRxiv*. 2020
30. Nunes Duarte-Neto A, de Almeida Monteiro RA, da Silva LFF, et al: Pulmonary and systemic involvement of COVID-19 assessed by ultrasound-guided minimally invasive autopsy. *Histopathology* 2020; 77:186–197
31. The first COVID-19 autopsy in Spain performed during the early stages of the pandemic. *Revista Española de Patología* 2020; 53:182–187
32. Reichard RR, Kashani KB, Boire NA, et al: Neuropathology of COVID-19: A spectrum of vascular and acute disseminated encephalomyelitis (ADEM)-like pathology. *Acta Neuropathol* 2020; 140:1–6
33. Aguiar D, Lobrinus JA, Schibler M, et al: Inside the lungs of COVID-19 disease. *Int J Legal Med* 2020; 134:1271–1274
34. Sekulic M, Harper H, Nezami BG, et al: Molecular detection of SARS-CoV-2 infection in FFPE samples and histopathologic findings in fatal SARS-CoV-2 cases. *Am J Clin Pathol* 2020; 154:190–200
35. Fox SE, Akmatbekov A, Harbert JL, et al: Pulmonary and cardiac pathology in African American patients with COVID-19: An autopsy series from New Orleans. *Lancet Respir Med* 2020; 8:681–686
36. Yang M, Chen S, Huang B, et al: Pathological findings in the testes of COVID-19 patients: Clinical implications. *Eur Urol Focus* 2020; 6:1124–1129
37. Edler C, Schröder AS, Aepfelbacher M, et al: Dying with SARS-CoV-2 infection—an autopsy study of the first consecutive 80 cases in Hamburg, Germany. *Int J Legal Med* 2020; 134:1275–1284
38. von Weyhern CH, Kaufmann I, Neff F, et al: Early evidence of pronounced brain involvement in fatal COVID-19 outcomes. *Lancet* 2020; 395:e109
39. Suess C, Hausmann R: Gross and histopathological pulmonary findings in a COVID-19 associated death during self-isolation. *Int J Legal Med* 2020; 134:1285–1290
40. Carsana L, Sonzogni A, Nasr A, et al: Pulmonary post-mortem findings in a series of COVID-19 cases from northern Italy: A two-centre descriptive study. *Lancet Infect Dis* 2020; 20:1135–1140
41. Solomon IH, Normandin E, Bhattacharyya S, et al: Neuropathological features of Covid-19. *N Engl J Med* 2020; 383:989–992
42. Konopka KE, Nguyen T, Jentzen JM, et al: Diffuse alveolar damage (DAD) from coronavirus disease 2019 infection is morphologically indistinguishable from other causes of DAD. *Histopathology* 2020; 77:570–578
43. Beigmohammadi MT, Jahanbin B, Safaei M, et al: Pathological findings of postmortem biopsies from lung, heart, and liver of 7 deceased COVID-19 patients. *Int J Surg Pathol* 2021; 29:135–145
44. Schaefer IM, Padera RF, Solomon IH, et al: In situ detection of SARS-CoV-2 in lungs and airways of patients with COVID-19. *Mod Pathol* 2020; 33:2104–2114
45. Wang C, Xie J, Zhao L, et al: Alveolar macrophage dysfunction and cytokine storm in the pathogenesis of two severe COVID-19 patients. *EBioMedicine* 2020; 57:102833
46. Rapkiewicz AV, Mai X, Carsons SE, et al: Megakaryocytes and platelet-fibrin thrombi characterize multi-organ thrombosis at autopsy in COVID-19: A case series. *EClinicalMedicine* 2020; 24:100434
47. Tombolini A, Scendoni R: SARS-CoV-2-related deaths in routine forensic autopsy practice: Histopathological patterns. *Int J Legal Med* 2020; 134:2205–2208
48. Bösmüller H, Traxler S, Bitzer M, et al: The evolution of pulmonary pathology in fatal COVID-19 disease: An autopsy study with clinical correlation. *Virchows Arch* 2020; 477:349–357
49. Youd E, Moore L: COVID-19 autopsy in people who died in community settings: The first series. *J Clin Pathol* 2020; 73:840–844
50. Prieto-Pérez L, Fortes J, Soto C, et al: Histiocytic hyperplasia with hemophagocytosis and acute alveolar damage in COVID-19 infection. *Mod Pathol* 2020; 33:2139–2146
51. Santana MF, Pivoto G, Alexandre MAA, et al: Confirmed invasive pulmonary aspergillosis and COVID-19: The value of postmortem findings to support antemortem management. *Rev Soc Bras Med Trop* 2020; 53:e20200401
52. Dorward DA, Russell CD, Um IH, et al: Tissue-specific tolerance in fatal Covid-19. *medRxiv*. 2020
53. Flikweert AW, Grootenboers MJH, Yick DCY, et al: Late histopathologic characteristics of critically ill COVID-19 patients: Different phenotypes without evidence of invasive aspergillosis, a case series. *J Crit Care* 2020; 59:149–155
54. Stone JR, Tran KM, Conklin J, et al: Case 23-2020: A 76-Year-Old woman who died from Covid-19. *N Engl J Med* 2020; 383:380–387
55. Sonzogni A, Previtali G, Seghezzi M, et al: Liver histopathology in severe COVID 19 respiratory failure is suggestive of vascular alterations. *Liver Int* 2020; 40:2110–2116
56. Sharma P, Uppal NN, Wanchoo R, et al: Northwell Nephrology COVID-19 Research Consortium: COVID-19-associated kidney injury: A case series of kidney biopsy findings. *J Am Soc Nephrol* 2020; 31:1948–1958
57. Bradley BT, Maioli H, Johnston R, et al: Histopathology and ultrastructural findings of fatal COVID-19 infections in Washington State: A case series. *Lancet* 2020; 396:320–332
58. Grosse C, Grosse A, Salzer HJF, et al: Analysis of cardiopulmonary findings in COVID-19 fatalities: High incidence of pulmonary artery thrombi and acute suppurative bronchopneumonia. *Cardiovasc Pathol* 2020; 49:107263
59. Prilutskiy A, Kritselis M, Shevtsov A, et al: SARS-CoV-2 infection-associated hemophagocytic lymphohistiocytosis. *Am J Clin Pathol* 2020; 154:466–474
60. Golmai P, Larsen CP, DeVita MV, et al: Histopathologic and ultrastructural findings in postmortem kidney biopsy material in 12 patients with AKI and COVID-19. *J Am Soc Nephrol* 2020; 31:1944–1947
61. Conklin J, Frosch MP, Mukerji S, et al: Cerebral microvascular injury in severe COVID-19. *medRxiv*. 2020
62. Lindner D, Fitzek A, Bräuninger H, et al: Association of cardiac infection with SARS-CoV-2 in confirmed COVID-19 autopsy cases. *JAMA Cardiol* 2020; 5:1281–1285

63. Schwensen HF, Borreschmidt LK, Storgaard M, et al: Fatal pulmonary fibrosis: A post-COVID-19 autopsy case. *J Clin Pathol* 2020 Jul 28. [online ahead of print]
64. Santoriello D, Khairallah P, Bomback AS, et al: Postmortem kidney pathology findings in patients with COVID-19. *J Am Soc Nephrol* 2020; 31:2158–2167
65. Cîrstea AE, Buzulică RL, Pirici D, et al: Histopathological findings in the advanced natural evolution of the SARS-CoV-2 infection. *Rom J Morphol Embryol* 2020; 61:209–218
66. Ducloyer M, Gaborit B, Toquet C, et al: Complete post-mortem data in a fatal case of COVID-19: Clinical, radiological and pathological correlations. *Int J Legal Med* 2020; 1–6
67. Kantonen J, Mahzabin S, Mäyränpää MI, et al: Neuropathologic features of four autopsied COVID-19 patients. *Brain Pathol* 2020; 30:1012–1016
68. Cipolloni L, Sessa F, Bertozzi G, et al: Preliminary post-mortem COVID-19 evidence of endothelial injury and factor VIII hyperexpression. *Diagnostics (Basel)* 2020; 10:E575
69. Rimmelink M, De Mendonça R, D'Haene N, et al: Unspecific post-mortem findings despite multiorgan viral spread in COVID-19 patients. *Crit Care* 2020; 24:495
70. Okudela K, Hayashi H, Yoshimura Y, et al: A Japanese case of COVID-19: An autopsy report. *Pathol Int* 2020; 70:820–824
71. Skok K, Stelzl E, Trauner M, et al: Post-mortem viral dynamics and tropism in COVID-19 patients in correlation with organ damage. *Virchows Arch* 2020; 1–11
72. Roden AC, Bois MC, Johnson TF, et al: The spectrum of histopathologic findings in lungs of patients with fatal COVID-19 infection. *Arch Pathol Lab Med* 2020; 145:11–21
73. Nadkarni GN, Lala A, Bagiella E, et al: Anticoagulation, bleeding, mortality, and pathology in hospitalized patients with COVID-19. *J Am Coll Cardiol* 2020; 76:1815–1826
74. Puntmann VO, Carerj ML, Wieters I, et al: Outcomes of cardiovascular magnetic resonance imaging in patients recently recovered from coronavirus disease 2019 (COVID-19). *JAMA Cardiology* 2020; 5:1265–1273
75. Poissy J, Goutay J, Caplan M, et al; Lille ICU Haemostasis COVID-19 Group: Pulmonary embolism in patients with COVID-19: Awareness of an increased prevalence. *Circulation* 2020; 142:184–186
76. Nicolai L, Leunig A, Brambs S, et al: Immunothrombotic dysregulation in COVID-19 pneumonia is associated with respiratory failure and coagulopathy. *Circulation* 2020; 142:1176–1189
77. Vesconi S, Rossi GP, Pesenti A, et al: Pulmonary microthrombosis in severe adult respiratory distress syndrome. *Crit Care Med* 1988; 16:111–113
78. Teuwen LA, Geldhof V, Pasut A, et al: COVID-19: The vasculature unleashed. *Nat Rev Immunol* 2020; 20:389–391
79. Gattinoni L, Chiumello D, Rossi S: COVID-19 pneumonia: ARDS or not? *Crit Care* 2020; 24:154
80. Meizlish M, Pine A, Goshua G, et al: Circulating markers of angiogenesis and endotheliopathy in COVID-19. *medRxiv* 2020
81. Nagashima S, Mendes MC, Martins APC, et al: Endothelial dysfunction and thrombosis in patients with COVID-19. *Arterioscler Thromb Vasc Biol* 2020; 40:2404–2407
82. Bonetti PO, Lerman LO, Lerman A: Endothelial dysfunction: A marker of atherosclerotic risk. *Arterioscler Thromb Vasc Biol* 2003; 23:168–175
83. Zhou F, Yu T, Du R, et al: Clinical course and risk factors for mortality of adult inpatients with COVID-19 in Wuhan, China: A retrospective cohort study. *Lancet* 2020; 395:1054–1062
84. Giacomelli A, Ridolfo AL, Milazzo L, et al: 30-day mortality in patients hospitalized with COVID-19 during the first wave of the Italian epidemic: A prospective cohort study. *Pharmacol Res* 2020; 158:104931
85. Mikami T, Miyashita H, Yamada T, et al: Risk factors for mortality in patients with COVID-19 in New York City. *J Gen Intern Med* 2020; 36:17–26
86. Tang N, Bai H, Chen X, et al: Anticoagulant treatment is associated with decreased mortality in severe coronavirus disease 2019 patients with coagulopathy. *J Thromb Haemost* 2020; 18:1094–1099
87. Tang N, Li D, Wang X, et al: Abnormal coagulation parameters are associated with poor prognosis in patients with novel coronavirus pneumonia. *J Thromb Haemost* 2020; 18:844–847
88. Maier CL, Truong AD, Auld SC, et al: COVID-19-associated hyperviscosity: A link between inflammation and thrombophilia? *Lancet* 2020; 395:1758–1759
89. Kwaan HC: Role of plasma proteins in whole blood viscosity: A brief clinical review. *Clin Hemorheol Microcirc* 2010; 44:167–176
90. Bowles L, Platton S, Yartey N, et al: Lupus anticoagulant and abnormal coagulation tests in patients with Covid-19. *N Engl J Med* 2020; 383:288–290
91. Fan Z, Chen L, Li J, et al: Clinical features of COVID-19 related liver damage. *medRxiv*. 2020
92. Oxley TJ, Mocco J, Majidi S, et al: Large-vessel stroke as a presenting feature of Covid-19 in the young. *N Engl J Med* 2020; 382:e60
93. Merkler AE, Parikh NS, Mir S, et al: Risk of ischemic stroke in patients with coronavirus disease 2019 (COVID-19) vs patients with influenza. *JAMA Neurology* 2020; 77:1–7
94. Katz JM, Libman RB, Wang JJ, et al: Cerebrovascular complications of COVID-19. *Stroke* 2020; 51:e227–e231
95. Mao L, Jin H, Wang M, et al: Neurologic manifestations of hospitalized patients with coronavirus disease 2019 in Wuhan, China. *JAMA Neurol* 2020; 77:683–690
96. Guo T, Fan Y, Chen M, et al: Cardiovascular implications of fatal outcomes of patients with coronavirus disease 2019 (COVID-19). *JAMA Cardiol* 2020; 5:811–818
97. Chen T, Wu D, Chen H, et al: Clinical characteristics of 113 deceased patients with coronavirus disease 2019: retrospective study. *BMJ* 2020; 368:m1091
98. Shi S, Qin M, Shen B, et al: Association of cardiac injury with mortality in hospitalized patients with COVID-19 in Wuhan, China. *JAMA Cardiol* 2020; 5:802–810
99. Ryan PM, Caplice N: COVID-19 and relative angiotensin-converting enzyme 2 deficiency: Role in disease severity and therapeutic response. *Open Heart* 2020; 7:e001302
100. Sala S, Peretto G, Gramegna M, et al: Acute myocarditis presenting as a reverse Tako-Tsubo syndrome in a patient with SARS-CoV-2 respiratory infection. *Eur Heart J* 2020; 41:1861–1862

101. Szekely Y, Lichter Y, Taieb P, et al: Spectrum of cardiac manifestations in COVID-19: A Systematic Echocardiographic Study. *Circulation* 2020; 142:342–353
102. Chow JH, Khanna AK, Kethireddy S, et al: Aspirin use is associated with decreased mechanical ventilation, ICU admission, and in-hospital mortality in hospitalized patients with COVID-19. *Anesth Analg* 2021; 132:930–941
103. Paranjpe I, Fuster V, Lala A, et al: Association of treatment dose anticoagulation with in-hospital survival among hospitalized patients with COVID-19. *J Am Coll Cardiol* 2020; 76:122–124
104. Viecca M, Radovanovic D, Forleo GB, et al: Enhanced platelet inhibition treatment improves hypoxemia in patients with severe Covid-19 and hypercoagulability. A case control, proof of concept study. *Pharmacol Res* 2020; 158:104950